

Retinal and Choroidal Vascular Diseases: Past, Present, and Future: The 2021 Proctor Lecture

Peter A. Campochiaro

Departments of Ophthalmology and Neuroscience, The Wilmer Eye Institute, The Johns Hopkins University School of Medicine, Baltimore, Maryland, United States

Correspondence: Peter A. Campochiaro, Maunee 815, The Wilmer Eye Institute, Johns Hopkins University School of Medicine, 600 N Wolfe St, Baltimore, MD 21287, USA; pcampo@jhmi.edu.

Citation: Campochiaro PA. Retinal and choroidal vascular diseases: Past, present, and future: The 2021 proctor lecture. *Invest Ophthalmol Vis Sci.* 2021;62(14):26. <https://doi.org/10.1167/iovs.62.14.26>

Retinal and choroidal vascular diseases are highly prevalent causes of visual disability. The most common choroidal vascular disease is neovascular AMD (nAMD). AMD was estimated to have a world-wide prevalence of 196 million in 2020 and because the world's population is aging, 288 million is projected for 2040.¹ Roughly 10% of patients with AMD develop neovascularization (NV) and hence the prevalence of nAMD was about 20 million in 2020. Diabetic retinopathy is the most common retinal vascular disease and in 2012 the world-wide prevalence of any diabetic retinopathy, proliferative diabetic retinopathy (PDR), and diabetic macular edema (DME) was 93 million, 17 million, and 21 million, respectively.² Retinal vein occlusion (RVO) is the second most common retinal vascular disease with a world-wide prevalence of 16.4 million in 2008, and a large percentage of patients with RVO develop macular edema.³ These three disorders account for a large proportion of global severe and moderate vision loss.

WHAT IS nAMD AND HOW WAS IT TREATED IN THE PAST?

AMD is a complex disease for which the risk of occurrence is increased by age, multiple genetic variants, and environmental exposures.⁴ Most patients with AMD have early or intermediate stages characterized by deposits on Bruch's membrane called drusen and pigmentary changes in the macula, which is usually associated with mild vision loss that is worse in dim illumination.⁵ Roughly 10% of patients develop choroidal NV (CNV), which leaks fluid into the macula, causing a rapid loss of vision. If untreated, the new vessels recruit other cells, resulting in subretinal fibrosis that damages photoreceptors and RPE cells, causing permanent loss of central vision. Early treatments sought to ablate CNV with laser photocoagulation focusing on lesions not involving the fovea.⁶ This treatment spared central vision in some patients for a time, but recurrences were common and almost always involved the fovea, causing the loss of central vision. Because the majority of patients presented with foveal involvement or developed foveal involvement from recurrent CNV after laser ablation, subfoveal CNV was treated with laser, which sacrificed central vision, but prevented profound vision loss from continued lesion growth and subretinal fibrosis.⁷ Another

approach was the surgical removal of CNV, which damaged the central retina and RPE and was found to be ineffective.^{8,9} Laser ablation of the fovea or surgical removal of CNV that also removed adherent RPE and photoreceptors provide insight into the desperation that was engendered by nAMD. Photodynamic therapy used the intravascular injection of a photosensitizing dye to minimize laser power and provide more selective damage to NV, but still caused substantial bystander damage to photoreceptors and the RPE, slowing but not eliminating the loss of central vision.^{10,11}

MOLECULAR PATHOGENESIS OF nAMD

Elucidation of the molecular pathogenesis of CNV turned the tide regarding the treatment of nAMD. The first step was the isolation and cloning of VEGF-A, a potent hypoxia-regulated angiogenic factor.¹² Intraocular levels of VEGF-A were found to be elevated in patients with various types of ocular NV¹³ and blockade of VEGF-A suppressed ischemia-induced retinal or iris NV.^{14,15} Transgenic mice in which the *rhodopsin* promoter drives expression of VEGF₁₆₅ in photoreceptors (*rho/Vegf* mice) demonstrated that increased expression of VEGF₁₆₅ in the outer retina was sufficient to cause CNV.¹⁶ In these mice, the expression of VEGF₁₆₅ begins at postnatal day (P) 7; at P14, endothelial cells begin migrating into the outer retina from the deep capillary bed, and by P21 there are perfused vessels extending from the deep retinal capillaries to the subretinal space. This type of CNV that originates from the deep retinal capillaries occurs in 30% to 40% of patients with nAMD and has been named retinal angioma-tous proliferation and more recently type 3 CNV.¹⁷ The tet/on inducible expression system was used to generate double transgenic mice with doxycycline-inducible expression of VEGF₁₆₅ in photoreceptors (*Tet/opsin/Vegf* mice).¹⁸ When treated with 2 mg/mL of doxycycline in drinking water, the expression of VEGF₁₆₅ in photoreceptors is so high (10-fold higher than that in *rho/Vegf* mice) that there is not only type 3 CNV, but there is also severe retinal vascular leakage resulting in exudative retinal detachment.¹⁸

Rupture of Bruch's membrane with laser photocoagulation in primates resulted in CNV that extends from the choroid into the subretinal space.¹⁹ This process is referred to as type 2 CNV and is the most common type seen in nAMD. Generation of this model in mice made it possi-

ble to use knockout and transgenic mice to investigate the effect of gene products in the pathogenesis of CNV and made screening of pharmacologic agents more feasible.²⁰ At the time, fibroblast growth factor 2 was hypothesized to be a contributor to CNV, but fibroblast growth factor 2 knockout mice showed no difference in the amount of CNV at Bruch's membrane rupture sites compared with wild-type mice, suggesting against this hypothesis.²⁰ Because the targeted disruption of even one *Vegfa* allele is embryonic lethal,²¹ it was not possible to use a similar approach to test the contribution of VEGF-A; therefore, pharmacologic inhibitors of VEGF were used and found to strongly suppress CNV at Bruch's membrane rupture sites.²² Bevacizumab is a full-length monoclonal antibody and ranibizumab is a Fab that each specifically neutralize primate VEGF-A and do not cross-react with murine VEGF-A,^{23,24} and therefore could not be tested in the mouse model. Ranibizumab was demonstrated to suppress CNV at Bruch's membrane rupture sites in primates.²⁵ Aflibercept is a recombinant protein containing binding domains from VEGF receptors 1 and 2, and does not exhibit species specificity with regard to the neutralization of VEGF-A; it strongly suppressed CNV at Bruch's membrane rupture sites in mice.²⁶ These studies suggested that VEGF-A is a major contributor to CNV and this finding was confirmed to be the case in patients with nAMD in clinical trials in which monthly injections of ranibizumab or injections of aflibercept every 2 months suppressed exudation and markedly improved visual acuity.²⁷⁻²⁹ The value of an animal model is determined in part by its ability to predict outcomes in patients, and thus the mouse model of CNV following rupture of Bruch's membrane has become widely used in academic laboratories and industry.

CURRENT TREATMENT OF nAMD

Since the demonstration that monthly injections of ranibizumab provide substantial visual benefit in patients with nAMD,^{27,28} there have been studies demonstrating that other anti-VEGF-A agents are noninferior,^{29,30} but there have been no major advances. Most attention has focused on reducing treatment burden and the most widely used regimen to do that is treat and extend, in which a patient is given an anti-VEGF-A injection at every visit while trying to increase the duration between visits to identify the maximum time between injections that avoids recurrent exudation.³¹ Although this approach works well for some patients, in others, missed visits and/or miscalculations result in recurrent bouts of exudation, subretinal fibrosis, and a gradual decrease in vision. Observational studies have shown that injection frequency is much less and visual outcomes are substantially worse in clinical practice than in clinical trials.^{32,33}

DIABETIC RETINOPATHY AND DME: ABLATIVE TREATMENTS

Hyperglycemia is a critical factor in the development of diabetic retinopathy.³⁴ Prolonged hyperglycemia promotes damage to pericytes and endothelial cells, causing closure of some retinal vessels visualized on fluorescein angiograms as areas of retinal nonperfusion. Retinal ischemia from nonperfusion results in PDR, in which retinal NV often causes vitreous hemorrhage and growth of fibrovascular tissue on the surface of the retina that contracts and detaches the retina. Panretinal photocoagulation (PRP) decreases retinal

ischemia, causes regression of retinal NV, and, if given in a timely manner, prevents retinal detachment and severe loss of vision.^{35,36} PRP is an effective treatment for PDR that continues to be used today to prevent severe vision loss and provide long-term stability. However, PRP does not prevent excessive vascular leakage from the posterior retinal vessels, which causes DME, the most common cause of moderate vision loss in diabetics. Focal laser treatments to ablate microaneurysms and macular grid laser avoiding the fovea decreased vision loss from DME,^{37,38} but was ineffective in many patients. Elucidation of the molecular pathogenesis of PDR and DME was critical for development of more effective treatments.

MOLECULAR PATHOGENESIS OF ISCHEMIC RETINOPATHIES

Oxygen-induced ischemic retinopathy (OIR) recapitulates critical features of diabetic retinopathy, including retinal nonperfusion.^{39,40} As noted elsewhere in this article, VEGF-A plays an important role in the stimulation of retinal NV in the mouse model of OIR.⁴¹ Hypoxia-inducible factor-1 α (HIF-1 α) is responsible for the increased expression of VEGF-A in ischemic retinopathies.⁴² Two hours after the onset of retinal hypoxia in the OIR model, there was a marked increase in HIF-1 α in the inner retina, and 4 hours later there was a dramatic increase in *Vegfa* mRNA in the same cells.⁴² Twenty-four hours after the subretinal injection of an adenoviral vector expressing a constitutively active form of HIF-1 α in adult mice, there were increased ocular levels of mRNA for HIF-1 α , VEGF-A, and other angiogenic factors, and after 3 days, there was strong staining for HIF-1 α in the RPE and type 3 CNV like that seen in *rho/VEGF* transgenic mice.⁴³ Six days after the intravitreal injection of the adenoviral vector expressing constitutively active HIF-1 α , there was retinal NV on the surface of the retina and anterior segment NV and thus, depending on its location, increased levels of HIF-1 α in the eye are sufficient to cause choroidal, retinal, or anterior segment NV.⁴³ The Semenza laboratory screened a library of approved drugs in a high-throughput assay of HIF-1 transcriptional activity and found strong inhibition by digoxin, daunorubicin, and acriflavine.⁴⁴⁻⁴⁶ Each of these drugs blocked the upregulation of VEGF-A and other angiogenic factors in ischemic retina, strongly suppressed ischemia-induced retinal NV, and strongly suppressed CNV at Bruch's membrane rupture sites.⁴⁷⁻⁴⁹ These data demonstrate that HIF-1 plays a central role in the development of both retinal NV and CNV.

Tyrosine kinase with immunoglobulin and epidermal growth factor homology domains-2 (Tie2) is a tyrosine kinase receptor that is expressed on endothelial cells and some bone marrow-derived cells that is critical for vascular development.^{50,51} Angiopoietin 1 is an agonist for Tie2 that is also required for vascular development.^{52,53} Angiopoietin 2 binds Tie2, but does not stimulate its phosphorylation and thus acts as an endogenous Tie2 antagonist.⁵⁴ The expression of angiopoietin 2 is increased in ischemic retina in the OIR model and is localized around retinal NV.⁵⁵ Like VEGF-A, angiopoietin 2 is upregulated by HIF-1.⁴³ Double transgenic mice with doxycycline-inducible expression of angiopoietin 2 in photoreceptors (*Tet/opsin/ang2* mice) have provided a useful tool to investigate the role of angiopoietin 2 in ocular NV.^{56,57} In the OIR model, the induced expression of angiopoietin 2 during the ischemic period between P12 and P17 when VEGF-A levels are high, resulted

in a marked increase in retinal NV at P17, but the induced expression of angiopoietin 2 between P20 and P23, when VEGF-A levels are low, caused a rapid regression of retinal NV.⁵⁷ In adult mice, induced expression of angiopoietin 2 caused no identifiable change to retinal vessels, but when it was combined with an intravitreal injection of an adenoviral vector expressing VEGF-A, it resulted in a marked increase in retinal NV compared with mice in which the vector was injected without the induced expression of angiopoietin 2.⁵⁶ These data indicated that angiopoietin 2 increases the sensitivity of endothelial cells in retinal vessels to VEGF-A, and, in the absence of VEGF-A, it promotes the regression of new vessels, but not mature vessels. Vascular endothelial protein tyrosine phosphatase (VE-PTP) dephosphorylates Tie2 and is a second Tie 2 inhibitor that, like angiopoietin 2, is increased by hypoxia; it is not detectable in normal retinal vessels, but is highly expressed in endothelial cells participating in NV in mice with OIR.⁵⁸ A small molecule inhibitor of VE-PTP, AKB-9778, stimulated phosphorylation of Tie2 in endothelial cells in vitro or in vivo and suppressed hypoxia-induced retinal NV, CNV at Bruch's membrane rupture sites, and VEGF-A-induced vascular leakage, and had an additive effect with aflibercept.⁵⁸ Thus, blocking either of two Tie2 inhibitors provides added benefit to VEGF-A suppression in models of retinal and choroidal vascular disease. An alternative strategy to stabilize retinal and choroidal vessels and decrease their sensitivity to pathologic effects of VEGF-A is overexpression of angiopoietin 1.^{59,60}

Figures 1 and 2 are schematics summarizing the molecular pathogenesis of ischemic retinopathies and nAMD. In ischemic retinopathies, progressive closure of some retinal vessels causes retinal hypoxia and the stabilization of HIF-1, which stimulates the transcription of several vasoactive proteins and their receptors. VEGF-A plays a central role stimulating retinal NV, but other VEGF family members, angiopoietin 2, and VE-PTP also contribute. HIF-1 also plays a central role stimulating CNV and hence nAMD. Because HIF-1 is involved in both disease processes, the same vasoactive factors are involved in each.

MOLECULAR PATHOGENESIS OF DME

As noted elsewhere in this article, DME often occurs independent of PDR, and although it was clear that retinal hypoxia played a critical role in PDR, it was not known whether hypoxia played a role in DME or whether it was solely due to structural damage to blood vessels resulting in leaking microaneurysms. There are no animal models of DME to investigate this question and therefore a small clinical trial was designed to address it. Patients with chronic DME despite focal laser treatment were given oxygen by nasal cannula around the clock for 3 months and all eyes showed improvement in central subfield thickness measured by optical coherence tomography.⁶¹ Oxygen was withdrawn and over the next 3 months the edema worsened. This study suggests that retinal hypoxia contributes to DME.

VEGF-A was a strong candidate for a hypoxia-regulated gene product that contributes to DME, because the sustained release of VEGF₁₆₅ in the eyes of nonhuman primates caused severe leakage from retinal vessels.⁶² A clinical trial testing oral PKC412, a VEGF receptor tyrosine kinase inhibitor, for 3 months in patients with DME showed a dose-dependent decrease in macular edema measured by optical coherence tomography that recurred after the drug was stopped.⁶³ This

Ischemic Retinopathies

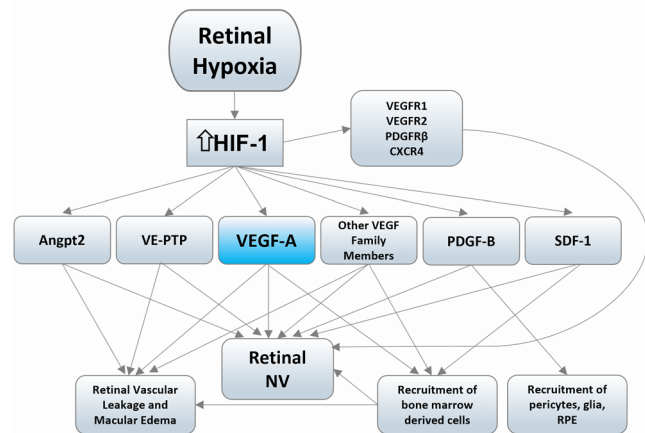


FIGURE 1. Molecular pathogenesis of ischemic retinopathies. Damage to retinal vessels results in decreased perfusion and retinal hypoxia causing stabilization of HIF-1. Increased levels of HIF-1 in the inner retina cause increased expression of multiple vasoactive factors and their receptors. The most important stimulator of retinal NV and excessive vascular leakage leading to macular edema is VEGF-A, but other VEGF family members, including VEGF-C and -D, which can stimulate VEGF receptor 2 (VEGFR2), and placental growth factor and VEGF-B, which stimulate VEGF receptor-1 (VEGFR1) may also contribute. Angiopoietin-2 (Angpt2) and vascular endothelial-protein tyrosine phosphatase (VE-PTP) inhibit Tie2, which decreases its stabilizing effect on endothelial cells, making them more responsive to VEGF family members. Recruitment of bone marrow-derived cells provides additional vasoactive stimulators and promotes leukostasis, which can further compromise perfusion. This recruitment occurs because leukocytes contain CXCR4, the receptor for stromal-derived factor-1 (SDF-1), and VEGFR1, which is activated by VEGF-A, VEGF-B, and placental growth factor. Activated endothelial cells release platelet-derived growth factor-B (PDGF-B) which recruits pericytes, glial cells, and RPE, which promote scarring.

work provided proof of concept for targeting VEGF-A for the treatment of DME, but systemic suppression of VEGF is not the best approach because of the risk of hypertension and thromboembolism. A clinical trial testing intravitreal injections of 0.5 mg ranibizumab in patients with DME demonstrated a mean improvement of 12 Early Treatment Diabetic Retinopathy Study (ETDRS) letters and an 85% decrease in excess foveal thickness at the month 7 primary end point.⁶⁴ The READ2 multicenter randomized trial demonstrated that compared with focal/grid laser therapy, which was the standard of care at the time, intravitreal injections of ranibizumab caused significantly greater improvement in best corrected visual acuity and a decrease in DME.^{65,66} This finding was subsequently confirmed by the Diabetic Retinopathy Clinical Research Network.⁶⁷ The RIDE and RISE trials showed prolonged benefit from ranibizumab injections and led to its approval for DME.⁶⁸

ROLE OF VEGF-A IN RVO

In diabetic retinopathy, the onset of retinal nonperfusion is gradual, but in central RVO (CRVO) or branch RVO (BRVO), the onset of retinal nonperfusion and hence retinal ischemia is abrupt. The onset of retinal vascular leakage is also acute in RVO, and edema is often severe. A clinical trial testing the effect of ranibizumab injections showed even more dramatic effects in CRVO and BRVO than in DME, with

Neovascular AMD

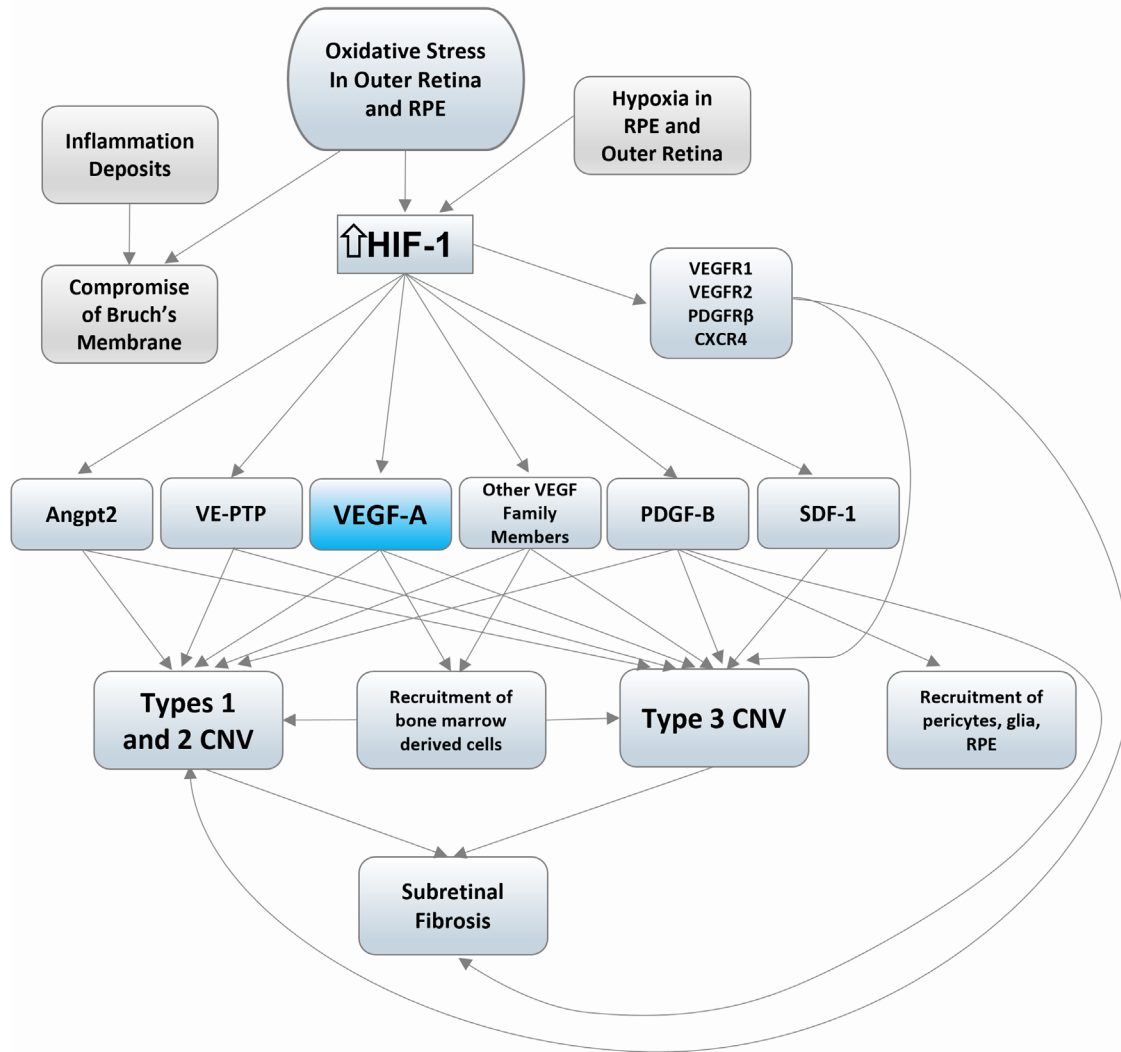


FIGURE 2. Molecular pathogenesis of nAMD. HIF-1 is stabilized by oxidative stress and hypoxia, and both have been implicated in nAMD. Complement activation on choriocapillaris (CC) has been shown to cause CC drop out and hypoxia in the RPE and outer retina. Bruch's membrane is compromised by focal and diffuse deposits. Increased levels of HIF-1 in the outer retina and RPE cause increased expression of the same vasoactive factors and their receptors as seen in ischemic retinopathies. The most important stimulator of growth and leakiness of types 1, 2, and 3 CNV is vascular endothelial growth factor-A (VEGF-A), but other VEGF family members including VEGF-C and -D which can stimulate VEGF receptor 2 (VEGFR2), and placental growth factor and VEGF-B which stimulate VEGF receptor-1 (VEGFR1) may also contribute. Angiopoietin-2 (Angpt2) and vascular endothelial-protein tyrosine phosphatase (VE-PTP) inhibit Tie2, which decreases its stabilizing effect on endothelial cells, making them more responsive to VEGF family members. The recruitment of bone marrow-derived cells provides additional vasoactive stimulators. This recruitment occurs because leukocytes contain CXCR4, the receptor for stromal-derived factor-1 (SDF-1), and VEGFR1, which is activated by VEGF-A, VEGF-B, and placental growth factor. Activated endothelial cells release platelet-derived growth factor-B (PDGF-B), which recruits pericytes, glial cells, and RPE, which promotes subretinal fibrosis.

almost complete elimination of excess foveal thickness and a mean improvement in the best corrected visual acuity of about 15 ETDRS letters in both CRVO and BRVO.^{69,70} The phase III BRAVO and CRUISE trials showed prolonged benefit from ranibizumab injections in BRVO and CRVO and led to its approval.⁷¹⁻⁷⁴

EFFECT OF VEGF-A SUPPRESSION ON RETINAL NONPERFUSION IN ISCHEMIC RETINOPATHIES

When the results from the initial study testing ranibizumab in patients with RVO were presented,⁶⁹ some clinicians and

investigators raised the concern that, because VEGF-A is a survival factor for endothelial cells and retinal vascular endothelial cells are so distressed by widespread ischemia in RVO, the suppression of VEGF-A might further compromise the endothelial cells and worsen retinal nonperfusion. In fact, several reports were published suggesting that the intraocular injection of an anti-VEGF-A agent had caused worsening of retinal nonperfusion in patients with RVO.⁷⁵⁻⁷⁸ Therefore in BRAVO and CRUISE, fluorescein angiograms were obtained at baseline and every 3 months, and retinal nonperfusion was measured by an independent reading center within a template centered on the fovea and consisting of the center, inner, and outer ETDRS subfields.

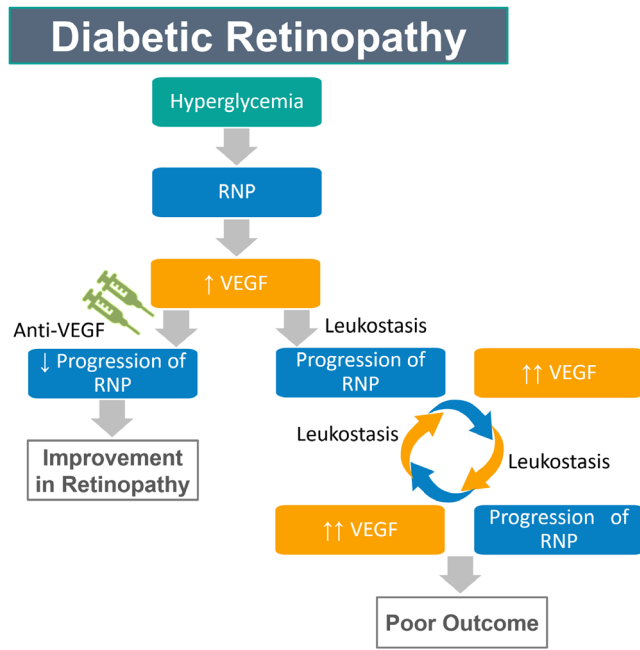


FIGURE 3. Role of VEGF-A in the progression of diabetic retinopathy. Hyperglycemia results in high glucose in the retina that, over a long period of time, causes damage to pericytes and endothelial cells of retinal vessels resulting in closure of retinal vessels. The slowly progressive retinal nonperfusion (RNP) eventually causes sufficient retinal hypoxia to stabilize HIF-1 increasing expression of VEGF-A then put the arrow and VEGF-A in parenthesis ↑VEGF-A and other hypoxia-regulated gene products. Once increased expression of VEGF occurs, it becomes the driver of the disease causing it to accelerate because it stimulates leukostasis causing progression of RNP further increasing VEGF expression (↑↑VEGF), resulting in a positive feedback loop for disease progression. Frequent anti-VEGF injections can interrupt the positive feedback loop by suppressing leukostasis thereby slowing progression of RNP and improving retinopathy. Reprinted with permission from Campochiaro PA, Akhlaq A. Sustained suppression of VEGF for treatment of retinal/choroidal vascular diseases. *Prog Retin Eye Res.* 2021;83:100921. Copyright © 2020 Elsevier Ltd.

The percentage of patients with no posterior retinal nonperfusion decreased in the sham groups, indicating worsening of nonperfusion, whereas it was relatively stable in the ranibizumab groups resulting in a significant difference at the 6-month primary end point.⁷⁹ After 6 months, all treatment groups received ranibizumab as needed and the differences were eliminated. Similar measurements of retinal nonperfusion were done in patients with DME who participated in the RISE and RIDE trials. During the first 24 months, when the ranibizumab groups received monthly injections and the sham group had no treatment, there was little change in nonperfusion in the ranibizumab groups, but there was a steady decrease in the percentage of patients with no posterior nonperfusion in the sham group, indicating worsening of nonperfusion.⁸⁰ After month 24, all treatment groups received ranibizumab as needed and the difference was eliminated. These data indicate that high levels of VEGF-A promote the progressive worsening of retinal nonperfusion in patients with ischemic retinopathy and that VEGF-A suppression does not worsen nonperfusion, but instead slows it and even causes improvement in some patients. The beneficial effect of VEGF-A suppression on retinal nonperfusion in RVO was confirmed in the COPERNICUS

and GALILEO phase III trials testing aflibercept in CRVO. In those trials, ultrawide angle fluorescein angiograms were used to measure the total area of retinal nonperfusion per retina. Monthly injections of aflibercept caused an improvement in the percentage of patients with 10 or more disc areas of nonperfusion from 23.5% at baseline to 11.6% at week 24, which was significantly different from the sham group, in which there was no improvement.⁸¹ To investigate the mechanism by which VEGF promotes retinal nonperfusion, intravascular leukocytes were visualized by perfusion with concanavalin A after the intravitreal injection of 1 µg of VEGF in adult mice. There was a striking increase in leukostasis 24 hours after VEGF injection, which returned to baseline by 48 hours.⁸² A sustained, increased expression of VEGF₁₆₅ in the retinas of *Tet/opsin/Vegf* double transgenic mice by the administration of doxycycline resulted in sustained leukostasis, leukocytic plugging, and retinal nonperfusion. Mice in which nonperfusion was visualized by fluorescein angiography after 3 days of doxycycline administration showed reperfusion of the closed vessels 14 days after stopping doxycycline. Thus, in both diabetic retinopathy and RVO, there are initial insults that cause retinal nonperfusion, retinal ischemia, and increased levels of VEGF-A. Once VEGF-A is increased, it becomes an important driver of disease progression by promoting leukostasis and the plugging of blood vessels. This process results in a positive feedback loop, causing the progressive worsening of nonperfusion and other outcomes (Figures 3 and 4).

DOES VEGF-A SUPPRESSION CAUSE RETINAL DAMAGE?

Like ischemic retinopathies, nAMD is chronic, and the chronicity of these diseases results in a high treatment burden, which often leads to undertreatment and poor outcomes. A potential solution is the sustained suppression of VEGF-A, but some investigators and clinicians have cautioned against this strategy because they contend that VEGF-A is a survival factor for photoreceptors and sustained suppression of VEGF-A could kill photoreceptors and cause geographic atrophy.^{83,84} Another concern is that the knockout of VEGF-A in RPE cells causes loss of the choriocapillaris and retinal degeneration, and it has been suggested that treatments that block VEGF-A could mimic the effect of VEGF-A knockout.⁸⁵ However, there is ample evidence suggesting that the strong, sustained suppression of VEGF-A does not cause retinal damage. Transgenic mice with induced high-level expression for up to 7 months of a potent VEGF-binding protein, sVEGFR1-Fc, have marked suppression of NV or retinal vascular leakage, but have no functional or ultrastructural evidence of retinal damage.⁸⁶ The prolonged pharmacologic blockade of VEGF receptors also failed to decrease ERG function or cause any thinning of the outer nuclear layer.⁸⁷ Photoreceptor survival factors such as fibroblast growth factor 2 or brain-derived neurotrophic factors promote photoreceptor survival and function in rats or mice with inherited photoreceptor degeneration, but VEGF does not.⁸⁸⁻⁹⁰ Injections of VEGF₁₆₅ or prolonged blockade of VEGF receptors in *rd10* mice had no effect on photoreceptor ERG function or photoreceptor survival.⁹⁰ These data suggest against VEGF-A being a survival factor for photoreceptors, but then why do photoreceptors have type 2 VEGFR? This question was answered by Okabe et al.,⁹¹ who showed that the conditional knockout

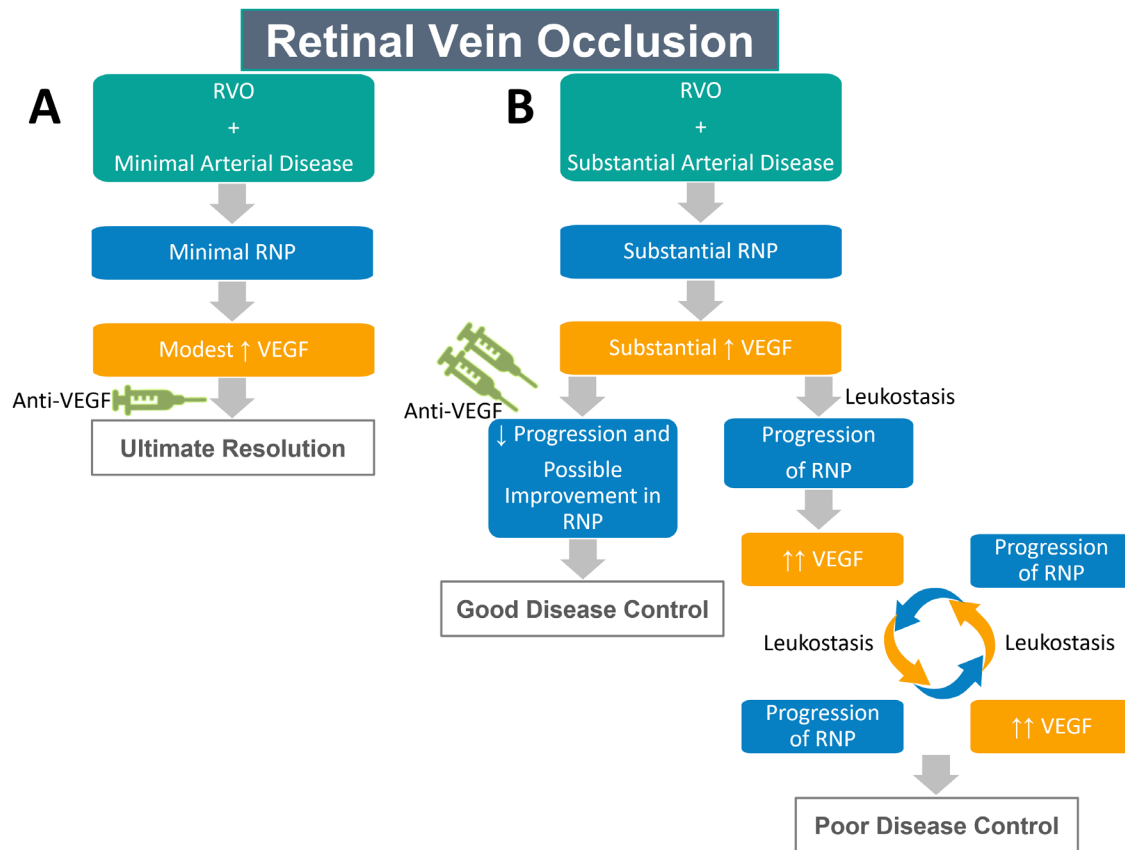


FIGURE 4. Role of VEGF-A in progression of retinopathy due to RVO. RVO causes increased resistance in the retinal circulation. If there is little or no preexistent arterial disease, the increased resistance causes decreased blood flow and some retinal hypoxia, but little retinal nonperfusion (RNP) and modest increase in VEGF-A expression. The increase in VEGF results in macular edema, but it is easily controlled with anti-VEGF injections and after a moderate number of VEGF injections, they may no longer be needed. This course is common in young patients who on average have less retinal arterial disease than older patients. If there is substantial preexistent retinal arterial disease, the increased resistance from RVO results in closure of many capillaries and small arterioles which causes substantial increase in VEGF expression. The high levels of VEGF become the driver of the disease by stimulating leukostasis causing progression of RNP and further increasing VEGF expression ($\uparrow\uparrow$ VEGF), resulting in a positive feedback loop for disease progression. If untreated or insufficiently treated, there is a poor outcome. Frequent anti-VEGF injections suppress leukostasis which decreases the progression of RNP and often causes it to improve. Some patients may eventually stabilize and no longer require injections, but the majority require long-term anti-VEGF injections to prevent the worsening of RNP and to suppress macular edema, which can result in a good visual outcome. Reprinted with permission from Campochiaro PA, Akhlaq A. Sustained suppression of VEGF for treatment of retinal/choroidal vascular diseases. *Prog Retin Eye Res.* 2021;83:100921. Copyright © 2020 Elsevier Ltd.

of VEGFR2 in photoreceptors had no deleterious effects on photoreceptor structure or function, but decreased VEGF internalization and degradation, thereby disrupting the reverse VEGF gradient surrounding retinal neurons and causing vessels to grow closer. Thus, the function of VEGFR2 on retinal neurons is to make blood vessels socially distance from photoreceptors and other retinal neurons, not to promote photoreceptor survival.

Warnings that anti-VEGF-A injection frequency should be moderated to decrease the risk of macular atrophy in patients with nAMD⁸⁴ have been controversial, because of a lack of any evidence of a causal link, the occurrence of macular atrophy as part of the natural history of AMD, and the potential for poor outcomes from undertreatment.⁹² Patients with type 3 CNV have a particularly high incidence of macular atrophy.⁸⁴ *Rbo/Vegf* transgenic mice develop type 3 CNV and, as new vessels grow from deep retinal capillaries through the outer nuclear layer to the subretinal space, photoreceptors adjacent to the vessels stain for a specific marker of oxidative damage, after which the

outer nuclear layer becomes thin and irregular indicating outer retinal atrophy visualized as hypopigmented spots on fundus photographs. The atrophy is prevented by treatment with the potent antioxidant *N*-acetylcysteine, confirming that it is caused by oxidative damage. Aflibercept did not decrease or exacerbate the retinal atrophy. These data indicate that type 3 CNV, in which there are perfused vessels carrying oxygen through the photoreceptor layer, causes oxidative damage to photoreceptors resulting in retinal atrophy and that VEGF-A suppression plays no role.

CURRENT TREATMENT FOR nAMD, DME, AND RVO

The current treatment for nAMD, DME, and RVO is intravitreal anti-VEGF-A injections. The acute effects are dramatic in that there is a rapid decrease in macular fluid and improvement in visual acuity in most patients. These benefits are maintained through the 1- and 2-year end points in clinical

trials by mandated repeated injections.^{27–29,68,71–74} However, these diseases are chronic and there is sustained increased expression of VEGF-A in most patients. After each injection, VEGF-A is neutralized for a finite period of time that varies depending on the level of expression and local factors that influence the responsiveness of retinal/choroidal vessels and new vessels to VEGF-A. Because these factors vary among patients, the time between an anti-VEGF-A injection and recurrent exudation varies among patients. Our current treatment regimens depend on identifying that interval in each patient and leaving patients uncovered, hoping that it will remain constant over time. Unfortunately, the interval does not remain constant over time, resulting in intermittent episodes of recurrent exudation (and progression of nonperfusion in ischemic retinopathies), which are increased in frequency by missed visits. Although one or a few recurrences may have little effect on vision, damaging effects from multiple recurrences mount over time, resulting in the gradual loss of peak vision.^{93,94}

FUTURE TREATMENTS FOR nAMD, DME, AND RVO

Because retinal and choroidal vascular diseases are chronic and persistent high expression of VEGF-A drives disease progression and causes gradual loss of vision in many patients, there is strong rationale for sustained suppression of VEGF-A or all VEGF family members. Several strategies are being tested. The approach that is furthest along in development is the port delivery system (PDS), a surgically implanted refillable reservoir that constantly releases ranibizumab into the vitreous cavity. The phase II Ladder trial compared the PDS filled with 10, 40, or 100 mg/mL ranibizumab with monthly injections of ranibizumab in patients with previously treated nAMD. The primary end point was the median time to the recurrence of macular fluid requiring a refill, and in the 100 mg/mL PDS group it was 15 months.⁹⁵ The mean change from baseline best corrected visual acuity at 9 months was +5.0 ETDRS letters in the 100 mg/mL PDS group, which was comparable with the +3.9 letters in the monthly injection group. The phase III Archway trial met its primary outcome by demonstrating that, compared with eyes of patients with nAMD that received monthly injections of ranibizumab, visual outcomes were equivalent in eyes implanted with the PDS containing 100 mg/mL ranibizumab and refilled every 6 months.⁹⁶ The PDS was approved by the FDA in October 2021 and will be available for clinical use in 2022.

Another approach is to incorporate a VEGF receptor tyrosine kinase inhibitor into a biodegradable polymer and generate microparticles that can provide sustained delivery of the inhibitor to the retina and RPE after intravitreal injection. This approach is appealing because it provides a means of blocking all VEGF family members, which may have greater efficacy than specific VEGF-A antagonists. Microparticles composed of blends of poly-lactic-co-glycolic acid and poly-lactic-co-glycolic acid conjugated to polyethylene glycol when injected into the vitreous of mice or minipigs self-aggregated to form a depot that slowly eroded to provide therapeutic levels in the retinas of minipigs for 6 months and the suppression of CNV in mice for at least 6 months.⁹⁷ Clinical trials showed evidence of prolonged suppression of exudation in patients with nAMD, but the microparticle depot was not as firm in human vitreous as

it had been in minipigs and mice, allowing the dispersion of clumps of microparticles that clouded the media in some patients. Modifications to this formulation or new sustained delivery platforms will be needed to take advantage of the potential of VEGF receptor tyrosine kinase inhibitors.

Another strategy for the sustained delivery of therapeutic proteins is gene therapy. The initial approach was to express an endogenous antiangiogenic protein and a proof-of-concept clinical trial using an adenoviral vector to express pigment epithelial-derived factor showed some evidence of therapeutic activity.⁹⁸ Subretinal injection of a lentiviral vector expressing endostatin and angiostatin in patients with nAMD resulted in sustained transgene expression for at least 4.5 years, but little signs of efficacy.⁹⁹ Because VEGF-A is a validated target in nAMD and retinal vascular diseases, the gene transfer of a VEGF-A antagonist is a less risky approach than expressing an unvalidated antiangiogenic protein. The subretinal injection of an adeno-associated viral vector 2 expressing soluble VEGFR1 in patients with nAMD showed some initial positive effects,¹⁰⁰ but ultimately failed; expression data were never reported and it is not clear that sufficient levels of soluble VEGFR1 were obtained to achieve efficacy in the majority of patients with nAMD. The intravitreal injection of an adeno-associated viral vector 2 expressing modified soluble VEGFR1 suppressed exudation in some patients with nAMD, but not others, suggesting that higher expression is needed. The subretinal injection of RGX-314, an adeno-associated viral vector 8 expressing an anti-VEGF Fab similar to ranibizumab, strongly suppressed type 3 CNV in *rho/VEGF* mice¹⁰¹ and in a phase I/IIa clinical trial testing subretinal injection of RGX-314 in patients with nAMD, has shown a dose-dependent and prolonged expression of the RGX-314 protein, suppression of exudation, and stable or improved visual acuity (ClinicalTrials.gov Identifier: NCT03066258). Suprachoroidal injection is a new route of delivery for ocular gene therapy that is less invasive than a subretinal injection and can be done in an outpatient setting without surgery.¹⁰² Clinical trials are underway testing suprachoroidal gene transfer of RGX-314 in patients with nAMD (ClinicalTrials.gov Identifier: NCT04514653) or diabetic retinopathy (ClinicalTrials.gov Identifier: NCT04567550).

Despite compelling evidence in animal models that other hypoxia-regulated gene products in addition to VEGF-A contribute to retinal and choroidal vascular diseases, blocking VEGF-A has been so effective in clinical trials that it has been challenging to demonstrate any added benefit by inhibiting other targets. However, three phase II trials have suggested that the activation of Tie2 may provide added benefit in patients with DME. The TIME2 trial showed that, compared with ranibizumab alone, ranibizumab combined with the VE-PTP inhibitor, AKB-9778, caused greater reduction in DME.¹⁰³ In the RUBY Trial, compared with aflibercept alone, aflibercept plus an anti-Ang2 antibody caused a greater decrease in edema (ClinicalTrials.gov Identifier: NCT02712008). Neither of these trials showed greater improvement in visual acuity by the combination therapy, but they included patients with chronic edema in whom visual improvement is limited by photoreceptor damage. In the Boulevard trial, Faricimab, a bispecific anti-VEGF and anti-Ang2 antibody, showed a greater decrease in edema and a greater improvement in visual acuity than ranibizumab in patients with new-onset DME.¹⁰⁴ Faricimab also caused greater improvement in background diabetic retinopathy. In the recently completed phase III Yosemite

and Rhine trials (ClinicalTrials.gov Identifiers: NCT03622580 and NCT03622593), compared with aflibercept, Faricimab showed evidence of a greater decrease in edema, but not greater visual improvement at the 9-month primary end point. Over a longer treatment period, greater control of edema may translate into better visual acuity.

In summary, retinal and choroidal vascular diseases are prevalent causes of vision loss treated in the past by ablative treatments that provided minimal benefit with the exception of PRP for PDR. Presently, they are treated by repeated injections of anti-VEGF-A neutralizing proteins, which provide substantial benefit when injections are given frequently and regularly, but in clinical practice undertreatment is common and leads to poor outcomes. In the future, these diseases will be treated by one of a variety of approaches that provide the sustained suppression of VEGF-A or multiple VEGF family members. This treatment strategy will be sufficient for most patients, but in those with an incomplete response, it will be supplemented by agents that activate Tie2 or target other hypoxia-regulated vasoactive proteins, not yet validated in clinical trials, such as integrins $\alpha_v\beta_3$ and $\alpha_5\beta_1$.¹⁰⁵

Acknowledgments

I thank Joseph T. Coyle, MD, Brian P. Conway, MD, Morton F. Goldberg, MD, and Donald J. Zack, MD, PhD, for mentorship, collaboration, and friendship. I thank all of the post-doctoral fellows, students, and technicians who have spent time in my laboratory for their hard work and inspiration. I thank my family, especially my wife Elizabeth Campochiaro, for constant support. I am grateful to numerous collaborators and colleagues who have helped me to cultivate ideas, formulate studies, and carry them out.

Disclosure: **P.A. Campochiaro**, Aerpio Pharmaceuticals (C); Allegro (C, I); Asclepix Therapeutics (C); Ashvattha Therapeutics (C, F); Bausch & Lomb (C); Clearside (C); Exonate Ltd (C); Genentech/Roche Inc (C, F); Graybug Vision (C, I); Gyroscope Therapeutics (C); Mallinckrodt Pharmaceuticals (F); Merck & Co Inc (C); Perfuse (C); Oxford Biomedica (F); Regeneron Pharmaceuticals (C); RegenxBio Inc (F); Sanofi Genzyme (F); Wave Life Sciences (C)

References

1. Wong WL, Su X, Li X, et al. Global prevalence of age-related macular degeneration and disease burden projection for 2020 and 2040: a systematic review and meta-analysis. *Lancet Glob Health*. 2014;2:e106–e116.
2. Yau JW, Rogers SL, Kawasaki R, et al. Global prevalence and major risk factors of diabetic retinopathy. *Diabetes Care*. 2012;35:556–564.
3. Song P, Xu Y, Zha M, Zhang Y, Rudan I. Global epidemiology of retinal vein occlusion: a systematic review and meta-analysis of prevalence, incidence, and risk factors. *J Glob Health*. 2019;9:e1020–e1030, doi:10.7189/jogh.7109.010427.
4. Fritsche LG, Fariss RN, Stambolian D, Abecasis GR, Curcio CA, Swaroop A. Age-related macular degeneration: genetics and biology coming together. *Annu Rev Genomics Hum Genet*. 2014;15:151–171.
5. Ferris FL, Davis MD, Clemons TE, et al. A simplified severity scale for age-related macular degeneration: AREDS report no. 18. *Arch Ophthalmol*. 2005;123:1570–1574.
6. Macular Photocoagulation Study Group. Argon laser photocoagulation for neovascular maculopathy: Five year results from randomized clinical trials. *Arch Ophthalmol*. 1991;109:1109–1114.
7. Macular Photocoagulation Study Group. Visual outcome after laser photocoagulation for subfoveal choroidal neovascularization for subfoveal choroidal neovascularization secondary to age-related macular degeneration. *Arch Ophthalmol*. 1994;112:480–488.
8. Hawkins BS, Bressler NM, Miskala PH, et al. Surgery for subfoveal choroidal neovascularization in age-related macular degeneration: ophthalmic findings: SST report no. 11. *Ophthalmology*. 2004;111:1967–1980.
9. Bressler NM, Bressler SB, Childs AL, et al. Surgery for hemorrhagic choroidal neovascular lesions of age-related macular degeneration: ophthalmic findings: SST report no. 13. *Ophthalmology*. 2004;111:1993–2006.
10. Miller JW, Walsh AW, Kramer M, et al. Photodynamic therapy of experimental choroidal neovascularization using lipoprotein-delivered benzoporphyrin. *Arch Ophthalmol*. 1995;113:810–818.
11. Treatment of Age-related Macular Degeneration with Photodynamic Therapy (TAP) Study Group. Photodynamic therapy of subfoveal choroidal neovascularization in age-related macular degeneration with verteporfin: one-year results of 2 randomized clinical trials- TAP report. *Arch Ophthalmol*. 1999;117:1329–1345.
12. Leung DW, Cachianes G, Kuang W-J, Goeddel DV, Ferrara N. Vascular endothelial growth factor is a secreted angiogenic mitogen. *Science*. 1989;246:1306–1309.
13. Aiello LP, Avery RL, Arrigg PG, et al. Vascular endothelial growth factor in ocular fluid of patients with diabetic retinopathy and other retinal disorders. *N Engl J Med*. 1994;331:1480–1487.
14. Aiello LP, Pierce EA, Foley ED, et al. Suppression of retinal neovascularization in vivo by inhibition of vascular endothelial growth factor (VEGF) using soluble VEGF-receptor chimeric proteins. *Proc Natl Acad Sci USA*. 1995;92:10457–10461.
15. Adamis AP, Shima DT, Tolentino MJ, et al. Inhibition of vascular endothelial growth factor prevents retinal ischemia-associated iris neovascularization. *Arch Ophthalmol*. 1996;114:66–71.
16. Okamoto N, Tobe T, Hackett SF, et al. Transgenic mice with increased expression of vascular endothelial growth factor in the retina: a new model of intraretinal and subretinal neovascularization. *Am J Pathol*. 1997;151:281–291.
17. Yannuzzi LA, Negrao S, Iida T, et al. Retinal angiomatous proliferation in age-related macular degeneration. *Retina*. 2001;21:416–434.
18. Ohno-Matsui K, Hirose A, Yamamoto S, et al. Inducible expression of vascular endothelial growth factor in photoreceptors of adult mice causes severe proliferative retinopathy and retinal detachment. *Am J Pathol*. 2002;160:711–719.
19. Ryan SJ. Subretinal neovascularization: natural history of an experimental model. *Arch Ophthalmol*. 1982;100:1804–1809.
20. Tobe T, Ortega S, Luna JD, et al. Targeted disruption of the *FGF2* gene does not prevent choroidal neovascularization in a murine model. *Am J Pathol*. 1998;153:1641–1646.
21. Ferrara N, Carver-Moore K, Chen H, et al. Heterozygous embryonic lethality induced by targeted inactivation of the VEGF gene. *Nature*. 1996;380:439–442.
22. Kwak N, Okamoto N, Wood JM, Campochiaro PA. VEGF is an important stimulator in a model of choroidal neovascularization. *Invest Ophthalmol Vis Sci*. 2000;41:3158–3164.
23. Ferrara N, Hillan KJ, Gerber HP, Novotny W. Discovery and development of bevacizumab, an anti-VEGF antibody for treating cancer. *Nat Rev Drug Discov*. 2004;3:391–400.

24. Ferrara N, Damico L, Shams N, Lowman H, Kim R. Development of ranibizumab, an anti-vascular endothelial growth factor antigen binding fragment, as therapy for neovascular age-related macular degeneration. *Retina*. 2006;26:859–870.
25. Kryzstolik MG, Afshari MA, Adamis AP, et al. Prevention of experimental choroidal neovascularization with intravitreal anti-vascular endothelial growth factor antibody fragment. *Arch Ophthalmol*. 2002;120:338–346.
26. Saishin Y, Saishin Y, Takahashi K, et al. VEGF-TRAP_{R1R2} suppresses choroidal neovascularization and VEGF-induced breakdown of the blood-retinal barrier. *J Cell Physiol*. 2003;195:241–248.
27. Rosenfeld PJ, Brown DM, Heier JS, et al. Ranibizumab for neovascular age-related macular degeneration. *N Engl J Med*. 2006;355:1419–1431.
28. Brown DM, Kaiser PK, Michels M, et al. Ranibizumab versus verteporfin for neovascular age-related macular degeneration. *N Engl J Med*. 2006;355:1432–1444.
29. Heier JS, Brown DM, Chong V, et al. Intravitreal Aflibercept (VEGF Trap-Eye) in wet age-related macular degeneration. *Ophthalmology*. 2012;119:2537–2548.
30. CATT Research Group, Martin DF, Maguire MG, et al. Ranibizumab and bevacizumab for neovascular age-related macular degeneration. *N Engl J Med*. 2011;364:1897–1908.
31. Silva R, Berta A, Larsen M, et al. Treat-and-Extend versus monthly regimen in neovascular age-related macular degeneration: results with ranibizumab from the TREND Study. *Ophthalmology*. 2018;125:57–65.
32. Holz FG, Tadayoni R, Beatty S, et al. Multi-country real-life experience of anti-vascular endothelial growth factor therapy for wet age-related macular degeneration. *Br J Ophthalmol*. 2015;99:220–226.
33. Rao P, Lum F, Wood K, et al. Real-world vision in age-related macular degeneration patients treated with single anti-VEGF drug type for 1 year in the IRIS registry. *Ophthalmology*. 2018;125:522–528.
34. Diabetes Control and Complications Trial Research Group. The effect of intensive treatment of diabetes on the development and progression of long term complications in insulin-dependent diabetes mellitus. *N Engl J Med*. 1983;329:977–986.
35. The Diabetic Retinopathy Study Research Group. Preliminary report on effects of photocoagulation therapy. *Am J Ophthalmol*. 1976;81:383–396.
36. The Diabetic Retinopathy Study Research Group. Photocoagulation treatment of proliferative diabetic retinopathy: the second report of Diabetic Retinopathy Study findings. *Ophthalmology*. 1978;85:82–105.
37. The Early Treatment Diabetic Retinopathy Study Group. Photocoagulation for diabetic macular edema. Early Treatment Diabetic Retinopathy Study report number 1. *Arch Ophthalmol*. 1985;103:1796–1806.
38. The Early Treatment Diabetic Retinopathy Study Group. Treatment techniques and clinical guidelines for photocoagulation of diabetic macular edema: Early Treatment Diabetic Retinopathy Study report number 2. *Ophthalmology*. 1987;94:761–774.
39. Patz A, Eastham A, Higgenbotham DH, Kleh T. Oxygen studies in retrolental fibroplasia: production of the microscopic changes of retrolental fibroplasia in experimental animals. *Am J Ophthalmol*. 1953;36:1511–1522.
40. Smith LEH, Wesolowski E, McLellan A, et al. Oxygen-induced retinopathy in the mouse. *Invest Ophthalmol Vis Sci*. 1994;35:101–111.
41. Pierce EA, Avery RL, Foley ED, Aiello LP, Smith LEH. Vascular endothelial growth factor/vascular permeability factor expression in a mouse model of retinal neovascularization. *Proc Natl Acad Sci USA*. 1995;92:905–909.
42. Ozaki H, Yu A, Della N, et al. Hypoxia inducible factor-1a is increased in ischemic retina: temporal and spatial correlation with VEGF expression. *Invest Ophthalmol Vis Sci*. 1999;40:182–189.
43. Kelly BD, Hackett SF, Hirota K, et al. Cell type-specific regulation of angiogenic growth factor gene expression and induction of angiogenesis in nonischemic tissue by a constitutively active form of hypoxia-inducible factor 1. *Circ Res*. 2003;93:1074–1081.
44. Zhang H, Qian DZ, Tan YS, et al. Digoxin and other cardiac glycosides inhibit HIF-1alpha synthesis and block tumor growth. *Proc Natl Acad Sci USA*. 2008;105:19579–19586.
45. Lee K, Qian DZ, Rey S, Wei H, Liu JO, Semenza GL. Anthracycline chemotherapy inhibits HIF-1 transcriptional activity and tumor induced mobilization of circulating angiogenic cells. *Proc Natl Acad Sci USA*. 2009;106:2353–2358.
46. Lee K, Zhang H, Qian DZ, Rey S, Liu JO, Semenza GL. Acriflavine inhibits HIF-1 dimerization, tumor growth, and vascularization. *Proc Natl Acad Sci USA*. 2009;106:17910–17915.
47. Yoshida T, Zhang H, Iwase T, Shen J, Semenza G, Campochiaro PA. Digoxin inhibits retinal ischemia-induced HIF-1alpha expression and ocular neovascularization. *FASEB J*. 2010;24:1759–1767.
48. Iwase T, Fu J, Yoshida T, et al. Sustained delivery of a HIF-1 antagonist for ocular neovascularization. *J Control Release*. 2013;172:625–633.
49. Zeng M, Shen J, Liu Y, et al. The HIF-1 antagonist acriflavine: visualization in retina and suppression of ocular neovascularization. *J Mol Med (Berl)*. 2017;95:417–429.
50. Dumont DJ, Gradwohl G, Fong G-H, et al. Dominant-negative and targeted null mutations in the endothelial receptor tyrosine kinase, tek, reveal a critical role in vasculogenesis of the embryo. *Genes Dev*. 1994;8:1897–1909.
51. Sato TN, Tozawa Y, Deutsch U, et al. Distinct roles of the receptor tyrosine kinases Tie-1 and Tie-2 in blood vessel formation. *Nature*. 1995;376:70–74.
52. Davis S, Aldrich TH, Jones P, et al. Isolation of angiopoietin-1, a ligand for the TIE2 receptor, by secretion-trap expression cloning. *Cell*. 1996;87:1161–1169.
53. Suri C, Jones PF, Patan S, et al. Requisite role of Angiopoietin-1, a ligand for the Tie2 receptor, during embryonic angiogenesis. *Cell*. 1996;87:1171–1180.
54. Maisonpierre PC, Suri C, Jones PF, et al. Angiopoietin-2, a natural antagonist for Tie2 that disrupts in vivo angiogenesis. *Science*. 1997;277:55–60.
55. Hackett SF, Ozaki H, Strauss RW, et al. Angiopoietin 2 expression in the retina: upregulation during physiologic and pathologic neovascularization. *J Cell Physiol*. 2000;184:275–284.
56. Oshima Y, Deering T, Oshima S, et al. Angiopoietin-2 enhances retinal vessel sensitivity to vascular endothelial growth factor. *J Cell Physiol*. 2004;199:412–417.
57. Oshima Y, Oshima S, Nambu H, et al. Different effects of angiopoietin 2 in different vascular beds in the eye; new vessels are most sensitive. *FASEB J*. 2005;19:963–965.
58. Shen J, Frye M, Lee BL, et al. Targeting VE-PTP activates TIE2 and stabilizes the ocular vasculature. *J Clin Invest*. 2014;124:4564–4576.
59. Nambu H, Nambu R, Oshima Y, et al. Angiopoietin 1 inhibits ocular neovascularization and breakdown of the blood-retinal barrier. *Gene Ther*. 2004;11:865–873.
60. Nambu H, Umeda N, Kachi S, Oshima Y, Nambu R, Campochiaro PA. Angiopoietin 1 prevents retinal detachment in an aggressive model of proliferative retinopathy,

- but has no effect on established neovascularization. *J Cell Physiol.* 2005;204:227–235.
61. Nguyen QD, Shah SM, Van Anden E, Sung JU, Vitale S, Campochiaro PA. Supplemental inspired oxygen improves diabetic macular edema; a pilot study. *Invest Ophthalmol Vis Sci.* 2003;45:617–624.
 62. Ozaki H, Hayashi H, Vinoses SA, Moromizato Y, Campochiaro PA, Oshima K. Intravitreal sustained release of VEGF causes retinal neovascularization in rabbits and breakdown of the blood-retinal barrier in rabbits and primates. *Exp Eye Res.* 1997;64:505–517.
 63. Campochiaro PA, C99-PKC412-003 Study Group. Reduction of diabetic macular edema by oral administration of the kinase inhibitor PKC412. *Invest Ophthalmol Vis Sci.* 2004;45:922–931.
 64. Nguyen QD, Tatlipinar S, Shah SM, et al. Vascular endothelial growth factor is a critical stimulus for diabetic macular edema. *Am J Ophthalmol.* 2006;142:961–969.
 65. Nguyen QD, Shah SM, Heier JS, et al. Primary End Point (Six Months) Results of the Ranibizumab for Edema of the macula in Diabetes (READ-2) Study. *Ophthalmology.* 2009;116:2175–2181.
 66. Nguyen QD, Shah SM, Khwaja AA, et al. Two-year outcomes of the Ranibizumab for Edema of the macula in Diabetes (READ-2) study. *Ophthalmology.* 2010;117:2146–2151.
 67. The Diabetic Retinopathy Clinical Research Network, Elman MJ, Aiello LM, Beck RW, et al. Randomized trial evaluating ranibizumab plus prompt or deferred laser or triamcinolone plus prompt laser for diabetic macular edema. *Ophthalmology.* 2010;117:1064–1077.
 68. Nguyen QD, Brown DM, Marcus DM, et al. Ranibizumab for Diabetic Macular Edema. Results from 2 phase III randomized trials: RISE and RIDE. *Ophthalmology.* 2012;119:789–801.
 69. Campochiaro PA, Hafiz G, Shah SM, et al. Ranibizumab for macular edema due to retinal vein occlusions; implication of VEGF as a critical stimulator. *Molec Ther.* 2008;16:791–799.
 70. Campochiaro PA, Hafiz G, Channa R, et al. Antagonism of vascular endothelial growth factor for macular edema caused by retinal vein occlusion: two-year outcomes. *Ophthalmology.* 2010;117:2387–2394.
 71. Campochiaro PA, Heier JS, Feiner L, et al. Ranibizumab for macular edema following branch retinal vein occlusion: 6-month primary endpoint results of a phase III study. *Ophthalmology.* 2010;117:1102–1112.
 72. Brown DM, Campochiaro PA, Singh RP, et al. Efficacy and safety of ranibizumab in the treatment of macular edema secondary to central retinal vein occlusion: 6-month results of the phase III CRUISE study. *Ophthalmology.* 2010;117:1124–1133.
 73. Brown DM, Campochiaro PA, Bhisitkul RB, et al. Sustained benefits from ranibizumab for macular edema following branch retinal vein occlusion: 12-month outcomes of a phase III study. *Ophthalmology.* 2011;118:1594–1602.
 74. Campochiaro PA, Brown DM, Awh CC, et al. Sustained benefits from ranibizumab for macular edema following central retinal vein occlusion: 12-month outcomes of a phase III study. *Ophthalmology.* 2011;118:2041–2049.
 75. Sabet-Peyman EJ, Heussen FM, Thorne JE, Casparis H, Patel SJ, Do DV. Progressive macular ischemia following intravitreal bevacizumab. *Ophthalmic Surg Lasers Imaging.* 2009;40:316–318.
 76. Mansour AM, Bynoe LA, Welch JC, et al. Retinal vascular events after intravitreal bevacizumab. *Acta Ophthalmol.* 2010;88:730–735.
 77. Shimura M, Yasuda K. Macular ischemia after intravitreal bevacizumab injection in patients with central retinal vein occlusion and a history of diabetes and vascular disease. *Br J Ophthalmol.* 2010;94:381–383.
 78. Kim NR, Chin HS. Progression of impending central retinal vein occlusion to the ischemic variant following intravitreal bevacizumab. *Korean J Ophthalmol.* 2010;24:179–181.
 79. Campochiaro PA, Bhisitkul RB, Shapiro H, Rubio RG. Vascular endothelial growth factor promotes progressive retinal nonperfusion in patients with retinal vein occlusion. *Ophthalmology.* 2013;120:795–802.
 80. Campochiaro PA, Wykoff CC, Shapiro H, Rubio RG, Ehrlich JS. Neutralization of vascular endothelial growth factor slows progression of retinal nonperfusion in patients with diabetic macular edema. *Ophthalmology.* 2014;121:1783–1789.
 81. Feltgen N, Ogura Y, Boscia F, et al. Impact of baseline retinal nonperfusion and macular retinal capillary nonperfusion on outcomes in the COPERNICUS and GALILEO studies. *Ophthalmol Retina.* 2019;3:553–560.
 82. Liu Y, Shen J, Fortmann SD, Wang J, Vestweber D, Campochiaro PA. Reversible retinal vessel closure from VEGF-induced leukocyte plugging. *JCI Insight.* 2017;2:e95530, doi:95510.91172/jci.insight.95530.
 83. Saint-Geniez M, Raharaj ASR, Walshe TE, et al. Endogenous VEGF is required for visual function: evidence for a survival role on Muller cells and photoreceptors. *PLoS One.* 2008;3:e3554: 3551–3511.
 84. Grunwald JE, Daniel E, Huang J, et al. Risk of geographic atrophy in the comparison of age-related macular degeneration treatments trials. *Ophthalmology.* 2014;121:150–161.
 85. Usui-Ouchi A, Friedlander M. Anti-VEGF therapy: higher potency and long-lasting antagonism are not necessarily better. *J Clin Invest.* 2019;129:3032–3034.
 86. Ueno S, Pease ME, Wersinger DMB, et al. Prolonged blockade of VEGF family members does not cause identifiable damage to retinal neurons or vessels. *J Cell Physiol.* 2008;217:13–22.
 87. Miki A, Ueno S, Wesinger DM, et al. Prolonged blockade of VEGF receptors does not damage retinal photoreceptors or ganglion cells. *J Cell Physiol* 2010;224:262–272.
 88. Faktorovich EG, Steinberg RH, Yasumura D, Matthes MT, LaVail MM. Photoreceptor degeneration in inherited retinal dystrophy delayed by fibroblast growth factor. *Nature.* 1990;347:83–86.
 89. LaVail MW, Yasumura D, Matthes MT, et al. Protection of mouse photoreceptors by survival factors in retinal degenerations. *Invest Ophthalmol Vis Sci.* 1998;39:592–602.
 90. Long D, Kanan Y, Shen J, et al. VEGF/VEGFR2 blockade does not cause retinal atrophy in AMD-relevant models. *JCI Insight.* 2018;3:e120231, doi:120210.121172/jci.insight.120231.
 91. Okabe K, Kobayashi S, Yamada T, et al. Neurons limit angiogenesis by titrating VEGF in retina. *Cell.* 2014;159:584–596.
 92. Campochiaro PA. Low risk to retina from sustained suppression of VEGF. *J Clin Invest.* 2019;129:3029–3031.
 93. Sophie R, Hafiz G, Scott A, et al. Long term outcomes in ranibizumab-treated patients with retinal vein occlusion; the role of progression of retinal nonperfusion. *Am J Ophthalmol.* 2013;156:693–705.
 94. Mir TA, Kherani S, Hafiz G, et al. Changes in retinal nonperfusion associated with suppression of vascular endothelial growth factor in retinal vein occlusion. *Ophthalmology.* 2016;123:625–634.
 95. Campochiaro PA, Marcus DM, Awh CC, et al. The port delivery system with ranibizumab for neovascular age-related

- macular degeneration: results from the randomized phase 2 Ladder clinical trial. *Ophthalmology*. 2019;126:1141–1154.
96. Campochiaro PA, Singh N, Kardatzke D, Blotner S, Patel SS, Barteselli G. Primary analysis results of the phase 3 Archway Trial of the port delivery system with ranibizumab for patients with neovascular AMD. *38th Annual Scientific Meeting of the American Society of Retina Specialists; July 24-26, 2020; Virtual*. 2020.
 97. Tsujinaka H, Fu J, Shen J, et al. Sustained treatment of retinal vascular diseases with self-aggregating sunitinib microparticles. *Nat Commun*. 2020;11:694.
 98. Campochiaro PA, Nguyen QD, Shah SM, et al. Adenoviral vector-delivered pigment epithelium-derived factor for neovascular age-related macular degeneration: results of a phase I clinical trial. *Hum Gene Ther*. 2006;17:167–176.
 99. Campochiaro PA, Lauer AK, Sohn EH, et al. Lentiviral vector gene transfer of endostatin/angiostatin for macular degeneration (GEM) study. *Hum Gene Ther*. 2016;28:99–111.
 100. Rakoczy EP, Lai C-L, Magno AL, et al. Gene therapy with recombinant adeno-associated vectors for neovascular age-related macular degeneration: 1 year follow-up of a phase 1 randomized clinical trial. *Lancet*. 2015;386:2395–2403.
 101. Liu Y, Fortmann SD, Shen J, et al. AAV8-antiVEGF Fab ocular gene transfer for neovascular age-related macular degeneration. *Mol Ther*. 2017;26:542–549.
 102. Ding K, Shen J, Hafiz Z, et al. AAV8-vectored suprachoroidal gene transfer produces widespread ocular transgene expression. *J Clin Invest*. 2019;130:4901–4911.
 103. Campochiaro PA, Khanani A, Singer M, et al. Enhanced benefit in diabetic macular edema from AKB-9778 Tie2 activation combined with vascular endothelial growth factor suppression. *Ophthalmology*. 2016;123:1722–1730.
 104. Sahni J, Patel SS, Dugel PU, et al. Simultaneous inhibition of angiopoietin-2 and vascular endothelial growth factor-A with faricimab in diabetic macular edema: BOULEVARD phase 2 randomized trial. *Ophthalmology*. 2019;126:1155–1170.
 105. Lima e Silva R, Kanan Y, Miranda AC, et al. Tyrosine kinase blocking collagen IV-derived peptide suppresses ocular neovascularization and vascular leakage. *Sci Trans Med*. 2017;9:eai8030, doi:8010.1126/scitranslmed.aai8030.