



Case report

Miliary tuberculosis mimicking systemic lupus erythematosus flare

Fatehi Elzein^{a,*}, Ahmed Elzein^a, Nazik Mohammed^a, Ramiz Alswailem^b^a Infectious Diseases Unit, PSMCM, Riyadh, Saudi Arabia, P.O. Box 7897, Riyadh, 11159, Saudi Arabia^b Rheumatology Division, PSMCM, Riyadh, Saudi Arabia, P.O. Box 7897, Riyadh, 11159, Saudi Arabia

A B S T R A C T

A 26-year-old woman was diagnosed with and treated for systemic lupus erythematosus (SLE) in 2002. She was admitted 11 years later with nephrotic-range proteinuria and lupus nephritis and received two doses of rituximab after failing on steroids and mycophenolate mofetil. Four months later, she presented with fever and joint pain/swelling. Gram stains, joint aspirates, and blood culture all yielded negative results for bacteria. She was discharged after treatment for a possible flare of lupus, but two weeks later, she presented again with a cough and shortness of breath in addition to the flare symptoms. Synovial fluid smears, and cultures yielded positive results for *Mycobacterium tuberculosis*; similarly, sputum polymerase chain reaction test and culture confirmed pulmonary tuberculosis. Tuberculosis is difficult to diagnose in SLE patients; it may present like or precipitate SLE flare. In this patient a presumed SLE flare turned out to be an aggressive miliary, disseminated tuberculosis.

1. Background

The risk of infections, including tuberculosis, is increased in patients with systemic lupus erythematosus. This risk is influenced by the degree of immunosuppression, presence of nephropathy as well as the prevalence of tuberculosis. A review by Sebastiani et al. noted that the relative frequency of tuberculosis in patients with systemic lupus erythematosus differed from 50 out of 100,000 patients (in Turkey) to 2450 out of 100,000 patients (in India) [1]. Many factors increase the risk of developing tuberculosis in patients with systemic lupus erythematosus, including deficiency in immunoglobulins and complement, defective phagocytic function, and decreased cellular immunity. Furthermore, Ribero et al. [2] suggest that molecular mimicry could be a contributory factor; for example, antigenic similarity exists between cell wall glycolipids of *Mycobacterium tuberculosis* (MTB) and DNA. They also note that heat-shock proteins 60 and 65 of MTB might act as super-antigens that trigger an autoimmune response. Additionally, the use of corticosteroids and the increasing use of biological agents, anti-tumour necrosis factor (anti-TNF) therapy, increase this risk. The average daily dose, cumulative dose and pulse steroids therapy are important determinant for increasing risk of tuberculosis. The adjusted odds ratio for the development of tuberculosis was 7.7 (95% CI 2.8,21.4) for doses greater than 15mg/day as compared to 2.8 (95% CI 1.0,7.9) for doses less than 15mg/day. An increase in the cumulative dose of steroids by one gram is postulated to increase the risk by 23% while treatment with pulse steroids therapy is found to be more common among patients who developed tuberculosis in SLE patients [3,4]. In contrast, the association between use of rituximab (a chimeric

human/mouse antibody) and reactivation of tuberculosis has not been widely reported. The adjusted ORs for rituximab, infliximab, and adalimumab were 1.4, 2.4, and 4.7, respectively. Interestingly, rituximab is more commonly associated with nontuberculous mycobacteria (NTM) when compared with the anti-TNF increased risk of tuberculosis. Two patients with inflammatory myopathies acquired severe NTM infections while undergoing treatment with rituximab [5,6]. On the other hand, systemic lupus erythematosus itself is associated with a higher risk of NTM. Reminiscent of human immunodeficiency virus, NTM tends to occur later in the clinical course of systemic lupus erythematosus than MTB infection. Advanced immunosuppression is suggested as a predisposing cause [7].

2. Case presentation

A 26-year-old woman was diagnosed with systemic lupus erythematosus in 2002 and was treated with prednisolone, mycophenolate, and hydroxychloroquine. In September 2013, she was admitted with nephrotic-range proteinuria. Renal biopsy confirmed class IV lupus nephritis. After failure of treatment with mycophenolate mofetil, enalapril, and high doses of steroids, she received two 1000-mg doses of rituximab one month apart. Prior to receiving rituximab, a chest x-ray showed normal findings, but a tuberculin skin test (TST) was not performed. A pre-employment TST performed in 2010 showed negative findings. Following rituximab she was maintained on 10–15 mg prednisolone daily. Four months after the second dose of rituximab, she presented with fever as well as pain and swelling in her right knee and left elbow. Her temperature was 39 °C and erythrocyte sedimentation

* Corresponding author.

E-mail address: fatehielzein@gmail.com (F. Elzein).

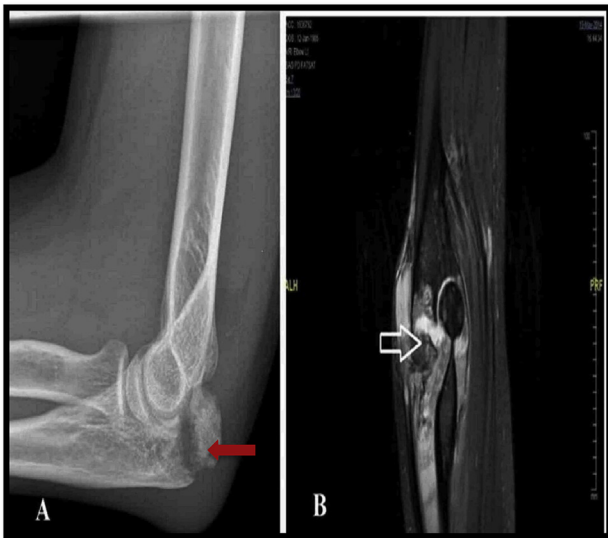

Fig. 1. A: Plain x-ray of the left elbow showed cranial displacement of a proximal fractured fragment of the olecranon process (red arrow) with an intra-articular extension associated with olecranon bursa swelling. Fig. 1B: Magnetic resonance imaging scan (MRI) of left elbow joint showing avulsion fracture involving the olecranon process (White arrow). (For interpretation of the references to colour in this figure legend, the reader is referred to the Web version of this article.)

rate was 117 mm/hr. Gram stains and culture of aspirates from the knee and elbow joints yielded negative results for bacteria, as did a blood culture. A combination of methylprednisolone and intravenous ceftriaxone was given for a possible flare of lupus. Her condition improved, and she was discharged home. Two weeks later, she presented with similar symptoms accompanied by cough and shortness of breath. The patient's temperature was 38.3 °C. Both her right knee and left elbow joints were erythematous and tender; her other joints were normal.

3. Investigations

The anti-nuclear antibody titre was 1:2560 (normal < 1:40); anti-double-stranded DNA level, 110 IU/mL (normal: 0–200); creatinine, 57 µmol/L; serum calcium, 2.63 mmol/L (normal: 2.06–2.44); and vitamin D, 43.6 nmol/L (optimal ≥ 75). A plain x-ray of the left elbow showed cranial displacement of a proximal fractured fragment of the olecranon process with intra-articular extension associated with swelling of the olecranon bursa (Fig. 1A). Magnetic resonance imaging scan (MRI) of left elbow joint showing avulsion fracture involving the olecranon process (White arrow) with possible underlying osteomyelitis of the avulsed fragment in addition to synovitis and reactive bursitis of the left elbow joint (Fig. 1B).

MRI of the right knee joint revealed arthritis with synovial thickening, rice pad in the suprapatellar pouch, and large lateral femoral condyle erosion in addition to severe bone marrow edema involving almost the entire lateral femoral condyle. MRI findings were highly suggestive of tuberculous arthritis (Fig. 2). A computed tomography (CT)-guided biopsy confirmed acute-on-chronic osteomyelitis of the right knee. A synovial fluid smear yielded positive results for acid-fast bacilli, and culture confirmed MTB.

An initial chest radiograph was reported as normal; conversely, a CT scan of the chest showed marked miliary nodular shadowing consistent with miliary tuberculosis (Fig. 3). Sputum smear yielded negative findings for acid-fast bacilli; however, sputum polymerase chain reaction (PCR) test using a GeneXpert system (Cepheid, Sunnyvale, CA, USA) yielded positive results for MTB. The gene mutation for rifampicin resistance was not detected. A fully sensitive MTB was isolated from

both the sputum and synovial fluid culture.

4. Treatment

The patient was treated with an initial phase of isoniazid 300 mg, rifampicin 600 mg, ethambutol 1.2 g, pyrazinamide 1.5 g, and pyridoxine 40 mg, all given once daily for two months; the same doses of isoniazid, rifampicin, and pyridoxine were then continued for another 7 months.

5. Outcome and follow-up

The patient made a remarkable recovery and has had no relapse of tuberculosis for almost 4 years.

6. Discussion

This patient's presentation highlights a number of interesting issues. She had underlying systemic lupus erythematosus nephropathy, was receiving steroid treatment, and had received recent courses of rituximab therapy. The complicating tuberculosis was severe; with miliary dissemination masquerading as a systemic lupus erythematosus flare. Despite having a low vitamin D level, her serum calcium level was high, but regressed on anti-tuberculosis treatment.

She presented with fever, arthritis, and negative synovial fluid culture, which erroneously indicated treatment with pulse steroid therapy for possible active systemic lupus erythematosus. However, tuberculosis can masquerade as a systemic lupus erythematosus flare, with similar laboratory findings as well as shared symptoms including fever, arthritis, and central nervous system manifestations. Moreover, a previous study showed an increased risk of precipitating systemic lupus erythematosus flares among patients with tuberculosis [8]. In some cases, tuberculosis' presentation can mimic an initial presentation of SLE. Justin Li et al., describe a 19 years old patient who fulfilled the American college of Rheumatology (ACR) and systemic lupus international collaborating clinics (SLICC) criteria. Her ANA, anti-RO, anti-LA, and anticardiolipin antibodies were all positive. Furthermore, skin biopsy showed IgM containing granular deposits consistent with connective tissue disease. Bronchoalveolar lavage for a worsening pulmonary infiltrate ultimately recovered MTB on culture. Following treatment with anti-TB medications, she showed resolution of disseminated and military TB changes as well as disappearance of all antibodies [9]. Thus, tuberculosis diagnosis in patients with active systemic lupus erythematosus is difficult; misdiagnosis can result in delay of tuberculosis treatment that can vary from months to years in some cases [10].

Vitamin D deficiency has been related to a heightened risk of tuberculosis in systemic lupus erythematosus patients. Remarkably, anti-vitamin D antibodies are known to be present in patients with systemic lupus erythematosus [11]. Inflammatory and immune response to tuberculosis are modulated by vitamin D. Furthermore, vitamin D also mediates the release of the human cathelicidin antimicrobial peptides. A likely association between vitamin D deficiency and impaired host defence to MTB was reported in the 1980s [12]. Vitamin D deficiency has been detected in 8.5–62.7% of patients with tuberculosis living in Africa [13]. A meta-analysis revealed hypovitaminosis D to be linked with higher risk of active tuberculosis [14]. Additionally, vitamin D receptor polymorphisms and increased susceptibility to MTB infection have been previously reported. Smear or culture conversion time in patients with pulmonary tuberculosis have been reported to be related to vitamin D receptor polymorphisms [15]. Therefore, further studies are required before vitamin D is routinely used in these patients.

Rituximab specifically binds to the CD20 antigen of B cells. It also leads to the depletion of peripheral blood B cells as well as bone marrow and synovial B cells, subsequently reducing the levels of immunoglobulin M and G [16]. Evidence is growing that B cells play a role

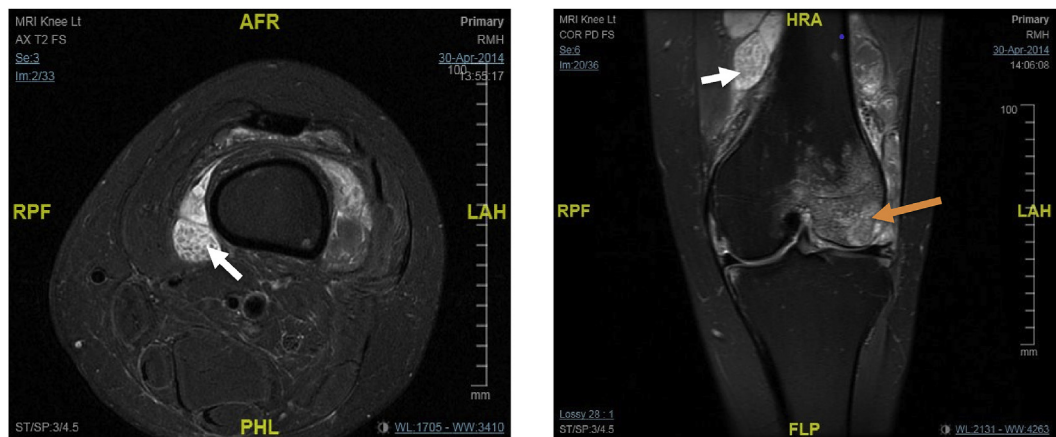


Fig. 2. MRI of the right knee joint revealed arthritis with synovial thickening, rice pad in the suprapatellar pouch (white arrows), and large lateral femoral condyle erosion in addition to severe bone marrow edema involving almost the entire lateral femoral condyle (orange arrow). (For interpretation of the references to colour in this figure legend, the reader is referred to the Web version of this article.)

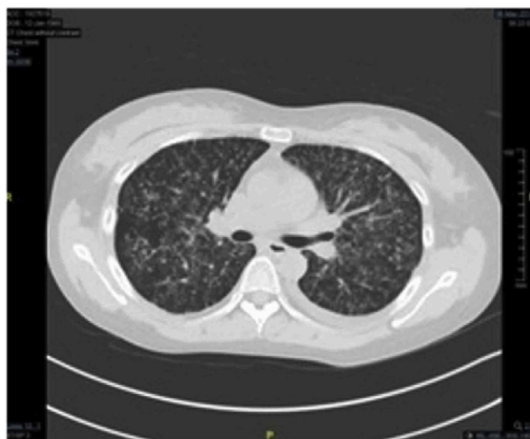

Fig. 3. Computed tomography scan of the chest showing marked miliary nodular shadowing consistent with miliary tuberculosis.

in the defence against Mycobacterial infections. In an animal study, B cell-deficient mice were found to be more vulnerable to MTB infection, which was corrected by infusion of B cells into these mice [17]. Furthermore, studies have shown that B cells are decreased in number and impaired in function in patient with tuberculosis [18]. However, tuberculosis is extremely rare among patients on rituximab, with few case reports present in the literature. The concomitant use of high dose steroids (prednisolone dose > 15 mg/day) while receiving rituximab, was found to be associated with the development of serious infections. Notably, renal impairment and greater total dose of rituximab are linked to an increased susceptibility to infection during rituximab therapy [6].

In conclusion, the patient described in this case report had multiple predispositions to tuberculosis including systemic lupus erythematosus, SLE nephropathy, immunosuppressive therapy, and low Vitamin D levels. Although the concurrent manifestation of miliary tuberculosis and administration of rituximab make it plausible to assume rituximab as an added risk, it is very difficult to dichotomise its contribution among these factors.

7. Learning points/take home messages

- Patients with systemic lupus erythematosus are at increased risk of tuberculosis.
- Tuberculosis can mimic an initial presentation of SLE, a flare or precipitate SLE disease.

- High dose, cumulative dose and steroid pulse therapy are responsible for most cases. Rituximab is not usually associated with reactivation; however a high index of suspicion is needed when such patients present with tuberculosis symptoms.
- Further studies are needed to assess the relationship between vitamin D and tuberculosis in patients with systemic lupus erythematosus.

Appendix A. Supplementary data

Supplementary data related to this article can be found at <https://doi.org/10.1016/j.rmcr.2018.09.005>.

References

- [1] E. Risk, Opportunistic Infections in Systemic Lupus Erythematosus S PECIAL R Eport, (2012) 275–9.
- [2] F.R.E.M. Ribeiro, M. Szyper-Kravitz, E.M. Klumb, G. Lannes, F.R.E.M. Ribeiro, E.M.M. Albuquerque, et al., Can lupus flares be associated with tuberculosis infection? *Clin. Rev. Allergy Immunol.* 38 (2–3) (2010) 163–168.
- [3] L.S. Tam, E.K. Li, S.M. Wong, C.C. Szeto, Risk factors and clinical features for tuberculosis among patients with systemic lupus erythematosus in Hong Kong, *Scand. J. Rheumatol.* 31 (5) (2002 Jan 1) 296–300.
- [4] S.S. Jick, E.S. Lieberman, M.U. Rahman, H.K. Choi, Glucocorticoid use, other associated factors, and the risk of tuberculosis, *Arthritis Care Res. Offic. J. Am. Coll. Rheumatol.* 55 (1) (2006 Feb 15) 19–26.
- [5] J.R. Lutt, M.L. Pisculli, M.E. Weinblatt, A. Deodhar, K.L. Winthrop, Severe non-tuberculous mycobacterial infection in 2 patients receiving rituximab for refractory myositis the journal of Rheumatology is a monthly international serial edited by Earl D. Silverman featuring research articles on clinical subjects from scient. *J. Rheumatol.* 35 (8) (2008) 1683–1686.
- [6] A. Nixon, L. Ogden, A. Woywodt, A. Dhaygude, Infectious complications of rituximab therapy in renal disease, *Clin. Kidney J.* 10 (4) (2017 Jul 6) 455–460.
- [7] M.Y. Mok, S.S. Wong, T.M. Chan, D.Y. Fong, W.S. Wong, C.S. Lau, Non-tuberculous mycobacterial infection in patients with systemic lupus erythematosus, *Rheumatology* 46 (2) (2006 Jul 22) 280–284.
- [8] Y.C. Lin, S.J. Liang, Y.H. Liu, W.H. Hsu, C.M. Shih, F.C. Sung, W. Chen, Tuberculosis as a risk factor for systemic lupus erythematosus: results of a nationwide study in Taiwan, *Rheumatol. Int.* 32 (6) (2012 Jun 1) 1669–1673.
- [9] J.C. Li, W. Fong, L. Wijaya, Y.Y. Leung, Disseminated tuberculosis masquerading as a presentation of systemic lupus erythematosus, *Int. J. Rheum. Dis.* 21 (1) (2018 Jan) 352–355.
- [10] M. Sayarlioglu, M. Inanc, S. Kamali, A. Cefle, O. Karaman, A. Gul, L. Ocal, O. Aral, M. Konice, Tuberculosis in Turkish patients with systemic lupus erythematosus: increased frequency of extrapulmonary localization, *Lupus* 13 (4) (2004 Apr) 274–278.
- [11] J.F. Carvalho, M. Blank, E. Kiss, T. Tarr, H. Amital, Y. Shoenfeld, Anti-vitamin D, vitamin D in SLE: preliminary results, *Annals of the New York Academy of Sciences*, 2007, pp. 550–557.
- [12] L. Hospital, Hypothesis a possible link between vitamin D deficiency and impaired host defence to mycobacterium tuberculosis: the pattern in the United Kingdom, *Group 66* (1985) 301–306.
- [13] D. Kibirige, E. Mutebi, R. Ssekitoleko, W. Wordria, H. Mayanja-Kizza, Vitamin D deficiency among adult patients with tuberculosis: a cross sectional study from a national referral hospital in Uganda, *BMC Res. Notes* 6 (1) (2013) 1 (Available

- from: BMC Research Notes).
- [14] K.E. Nnoaham, A. Clarke, Low serum vitamin D levels and tuberculosis: a systematic review and meta-analysis, *Int. J. Epidemiol.* 37 (1) (2008) 113–119. Available from: <https://academic.oup.com/ije/article-lookup/doi/10.1093/ije/dym247>.
- [15] M.J. Magee, Y.V. Sun, J.C.M. Brust, N.S. Shah, Y. Ning, S. Allana, et al., Polymorphisms in the vitamin D receptor gene are associated with reduced rate of sputum culture conversion in multidrug-resistant tuberculosis patients in South Africa, *PLoS One* 12 (7) (2017) e0180916 Available from: <http://dx.plos.org/10.1371/journal.pone.0180916>.
- [16] M.H. Buch, J.S. Smolen, N. Betteridge, F.C. Breedveld, G. Burmester, T. Dörner, et al., Updated consensus statement on the use of rituximab in patients with rheumatoid arthritis, *Ann. Rheum. Dis.* 70 (6) (2011) 909–920.
- [17] P.J. Maglione, J. Chan, How B cells shape the immune response against *Mycobacterium tuberculosis*, *Eur. J. Immunol.* 39 (2009) 676–686. Available from: <http://www.pubmedcentral.nih.gov/articlerender.fcgi?artid=2760469&tool=pmcentrez&rendertype=abstract>.
- [18] S.A. Joosten, K.E. van Meijgaarden, F. del Nonno, A. Baiocchi, L. Petrone, V. Vanini, et al., Patients with tuberculosis have a dysfunctional circulating B-cell compartment, which normalizes following successful treatment, *PLoS Pathog.* 12 (6) (2016 Jun 15) e1005687.