



Mid- to long-term clinical outcomes of arthroscopic surgery for external snapping hip syndrome

Chun-Ting Chu¹, Huan Hsu², Hao-Che Tang³, Alvin Chao-Yu Chen^{2,4} and Yi-Sheng Chan^{ID 2,4*}

¹Department of General Medicine, Chang Gung Memorial Hospital, No. 5, Fuxing Street, Guishan District, Taoyuan City 333, Taiwan, ²Department of Orthopaedic Surgery, Chang Gung Memorial Hospital, No. 5, Fuxing Street, Guishan District, Taoyuan City 333, Taiwan, ³Department of Orthopaedic Surgery, Chang Gung Memorial Hospital, No. 222, Maijin Road, Anle District, Keelung City 204, Taiwan and ⁴School of Medicine, Chang Gung University, No. 259, Wenhua 1st Road, Guishan District, Taoyuan City 333, Taiwan.

*Correspondence to: Y.-S. Chan. E-mail: yschan512@gmail.com

ABSTRACT

This study evaluated the outcomes of arthroscopic surgery for the treatment of external snapping hip at 2- to 10-year follow-ups. Eighteen patients with refractory external snapping hip treated by arthroscopic surgery were enrolled in this prospective study. All patients underwent unsuccessful conservative treatment for more than 3 months before surgery. We made diamond-shaped defects on the iliotibial band and resected peripheral fibrosis tissues for iliotibial band release with an arthroscopic approach. The visual analog scale (VAS), modified Harris hip score and return to previous level of activity were evaluated as functional outcomes. In addition, residual discomfort or the presentation of complications was also investigated. The average follow up period was 7 years. The modified Harris hip score increased from 70.08 preoperatively to 93.14 postoperatively, and the VAS score decreased from 3.67 preoperatively to 1.17 2 weeks after the operation and declined to 0.33 at the last follow-up. Neither recurrence of snaps nor complications were recorded. Two patients complained of a tight sensation with tenderness after exertion. Our clinical outcomes were compatible with those of previous studies, and no long-term complications were noted, even with a relatively longer follow-up period than what was reported in previous studies. Arthroscopic surgery is a safe and effective treatment that can provide promising long-term clinical outcomes for patients with refractory external snapping hip.

INTRODUCTION

Snapping hip, also called Coax saltans, are described as audible or palpable snaps during the motion of hip joints. This ailment is frequently seen in young adults with high activity demand, such as dancers or CrossFit athletes [1, 2, 31]. It can be divided into three types according to different limping sites: external, internal, and intra-articular. Among them, external snapping hip are the most common [1–3]. External snapping hip is caused by friction between the thickened posterior part of the iliotibial band or anterior part of the gluteus maximus and the great trochanter of the femur, causing great trochanteric bursitis responsible for pain [2, 4–8].

Although asymptomatic snapping of the hip is not uncommon [7], the condition may progress to marked pain and limit the range of motion of the hip joint. Typically, conservative treatment is used first for symptomatic patients, including activity modification, physical therapy, nonsteroidal anti-inflammatory drugs or local injection of steroids [1, 2, 4, 9, 32]. However, surgical intervention should be considered if conservative treatment fails.

In previous studies, surgical treatment has provided promising clinical outcomes and high satisfaction levels [4, 10–21].

The surgical treatment of external snapping hip can be both open and arthroscopic. Various arthroscopic surgical techniques have been introduced, and most of the literature reveals good clinical results [3, 10–13, 15–27]. Although some articles have demonstrated the long-term outcomes of open surgery, no published literature has evaluated the long-term clinical outcomes of arthroscopic surgery. Thus, this study aimed to assess the long-term clinical outcomes of arthroscopic treatment for external snapping hip.

MATERIALS AND METHODS

Patients and preoperative evaluation

Between April 2003 and January 2018, 18 patients with unilateral external snapping hip received arthroscopic diamond-shaped iliotibial band release by a single senior surgeon and this study was performed prospectively. The evaluation included physical examination to reproduce snaps by passive flexion and extension of the hip and localize tender points over the greater trochanter area with palpation. Ober's test was performed to confirm the tightness of the iliotibial band. Anteroposterior radiographs of the pelvis and hip joints with weight bearing position were obtained in all cases to exclude bony lesions or

deformities, and magnetic resonance imaging of the hip joint was used in some cases to exclude intraarticular lesions. All patients received conservative treatment for at least 3 months, and surgical intervention was indicated if the symptoms persisted after unsuccessful conservative treatments. Patients were excluded if they had any of the following features: (i) bony lesions or muscle tears of the hip joint, such as hip dysplasia, femoroacetabular impingement, gluteus or iliotibial band tears, or osteoarthritis or (ii) symptoms associated with internal or intra-articular snapping hips.

Surgical technique

The patients were positioned lateral decubitus on the operating table and given general endotracheal anesthesia. Two portals were marked superior and inferior to the greater trochanter (Fig. 1). The superior trochanter portals were created first, and a 30° 4 mm arthroscope was introduced into the space between the subcutaneous tissue and iliotibial band. The plane above the superficial side of the iliotibial band was further created with a shaver until the tendon could be visualized directly. Then, the radiofrequency probe was introduced, and a 4–5 cm retrograde vertical cut from the level of the distal portal with anterior transverse release was made (Figs 2 and 4). Then, a 2 cm horizontal cut was made from the middle portion of the vertical cut anteriorly and posteriorly, and the flaps were then resected to create a diamond-shaped defect (Figs 3 and 4). If bursitis or fibrosis was observed, bursectomy of the great trochanter bursa was indicated and debridement of inflammatory tissues was performed to release adhesion and decrease the local inflammatory response. After the operation, passive motion of the hip was performed to ensure the appropriate release of muscle and tissue and no residual snaps.

Postoperative management and evaluation

Patients were assessed in the outpatient department at 2 weeks, 1 month, 3 months, 6 months, and 1 year postoperatively and then per annum postoperatively. The outcomes included the

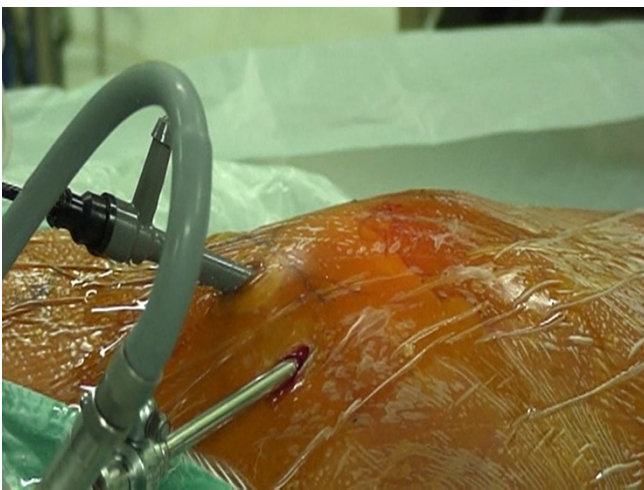


Fig. 1. Two portals were made for scope and radiofrequency probes with the line of femur on the proximal and distal sides of the great trochanter, respectively.

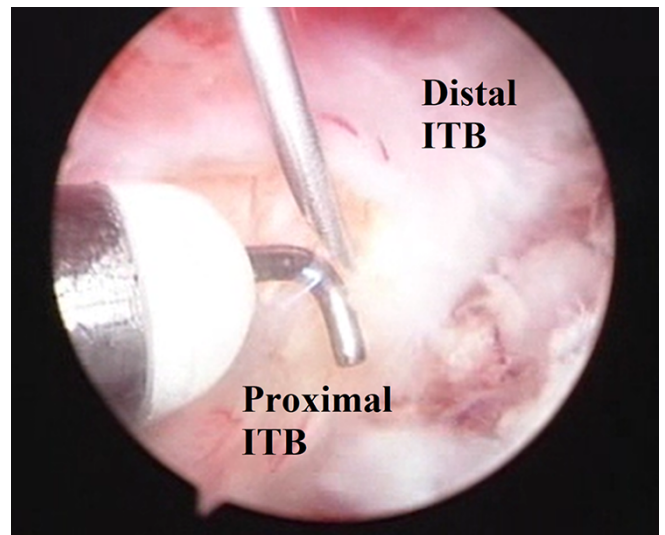


Fig. 2. The arthroscopic image (right hip) shows transverse cutting after vertical cutting with a probe.

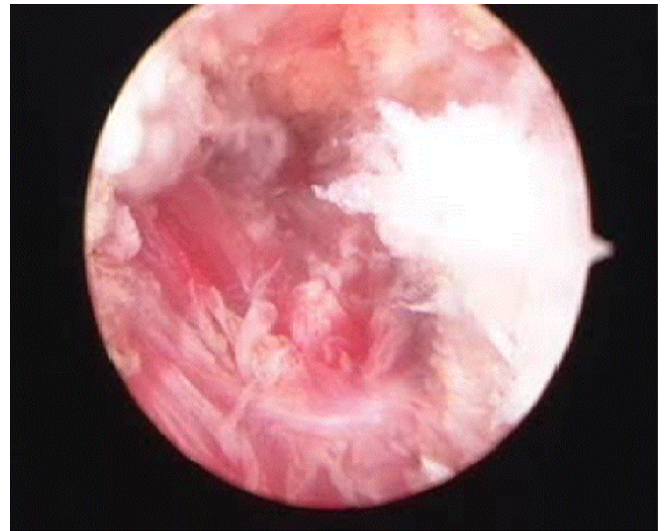


Fig. 3. The arthroscopic image (right hip) shows a triangular defect after vertical release and anteriortransverse iliotibial band with a radiofrequency probe, and the inflamed greater trochanter bursa was removed by shaver.

symptom-free rate, which was defined as no residual snaps or pain, return to preinjury activity level, visual analog scale (VAS) score, and modified Harris hip score (mHHS). VAS were assessed at each follow-up, and the VAS at discharge was used as an early result. We chose the VAS at the 2-week follow-up as postoperative pain and the data at the last follow-up as long-term results. The mHHS was collected by a single doctor before the surgery was performed and in the most recent follow-up of the patients. In addition, the presence of muscle weakness or other complications was also investigated. All patients were evaluated by the senior author (***) .

Statistical analysis was conducted with IBM SPSS Statistics (version 22.0, IBM, New York, United States). The VAS and mHHS were analyzed with paired-sample Student's *t*-test to

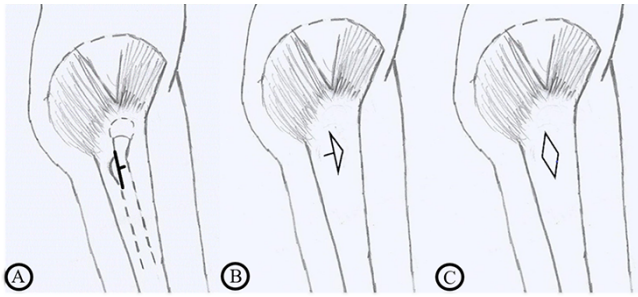


Fig. 4. (A) Vertical and anterior transverse release was performed on the greater trochanter area. (B) Triangular defects were made after resection of the anterior-superior and anterior-inferior flaps, followed by posterior transverse release. (C) Diamond-shaped defects were completed after the posterior-superior and posterior-inferior flaps were removed.

identify statistical significant differences between preoperative and postoperative values. A P -value <0.05 was considered statistically significant.

RESULTS

We treated 18 patients, 10 men and eight women, with an average age of 38.8 years (ranging from 21 to 52 years). The average symptomatic period was 3 years (ranging from three months to 10 years). Among them, nine patients had high activity demand due to exercise or occupation. The average follow-up period of all patients was 7 years (ranging from 2 to 17 years); 14 patients completed at least 5 years of follow-up, two patients completed 4 years of follow-up, one patient completed 3 years of follow-up and one patient completed 2 years of follow-up. The average VAS score decreased from 3.67 (ranging from 0 to 8) preoperatively to 1.17 (ranging from 0 to 3) postoperatively, and the pain score further decreased to 0.34 (ranging from 0 to 3) at the last follow-up. The average mHHS increased from 70.08 (ranging from 59.4 to 88.4) preoperatively to 93.14 (ranging from 80.45 to 99.65) at the last follow-up. All patients improved hip function, and the elevation of the Harris hip score was statistically significant. No recurrence of snaps was noted by our patients. Two patients complained about tightness sensation after conducting sports, but this discomfort resolved with rest. None of the patients considered revision operations or conservative treatment. No complications, such as muscle weakness or limping gait, were recorded in any patient.

DISCUSSION

Although the main treatment for snapping hip is conservative treatment, and surgical intervention is reserved for refractory cases, various techniques have been invented and performed to treat external snapping hip since the surgical procedure was first used in 1929 by Dickison [28]. Although the actual cause of external snapping hip is still undetermined [29], tightness of the iliotibial band or gluteus maximus is widely recognized as the cause [4]. Based on the mechanism causing symptomatic snaps, surgical techniques can be divided into three categories: (i) iliotibial band elongation, (ii) partial excision or release of the iliotibial band, and (iii) partial excision or release of

the gluteus maximus. Some authors may combine different techniques according to the patient's history and clinical symptoms. Although different techniques are performed by different authors, we know that surgical management is an effective and safe treatment with a low recurrence rate and few complications [10].

Although surgical treatment has been used to treat snapping hip for decades, arthroscopic treatment is emerging rapidly and widely. Ilizaliturri *et al.* [12] performed arthroscopic diamond-shaped resection of the GT bursa; the symptoms resolved in 10 patients, but one had painless recurrence snaps. Thomassen *et al.* [21] performed a similar procedure but with star-shaped defects. Polesello *et al.* [15] treated nine hips with arthroscopic gluteus maximus tendon release. Wu *et al.* [18] modified the technique as a complete cut of contracture gluteus maximus and tensor fascia lata bands with a large case number. Zini *et al.* [16] performed arthroscopic transversal complete cutting of the iliotibial band with the release of the gluteus maximus. Yoon *et al.* [17] performed a similar technique but did not release the gluteus maximus, but Park *et al.* [19] chose arthroscopically modified N-plasty to release the iliotibial band. The clinical outcomes of previous studies are summarized in Table I. All studies demonstrated a high symptom relieving ratio of $\sim 90\%$ or more in a short follow-up period, ranging from 1.6 to 2.8 years. Both mHHS and VAS were improved in all studies, which means that surgical intervention can provide fair clinical outcomes and also preserve the function of the hip in the early follow-up after the operation. Although only two patients needed revision surgery for residual symptoms in previous serious cases [15, 21], residual discomfort over the surgical site has been reported by different authors. However, the cause of residual symptoms is poorly understood and needs further study. In our study, we demonstrated desirable and satisfactory results even with longer follow-up periods. The symptom-relieving ratio was similar to that in previous studies and stable even with a longer follow-up period. Combined with previous studies, our conclusion is that the effect of arthroscopic surgery is durable without long-term complications.

To our knowledge, few studies have evaluated the long-term outcomes of surgical intervention for external snapping hip, and all used an open approach. The results of previous studies with a follow-up period of over 60 months are summarized in Table II. Yoon *et al.* [16] demonstrated a lower recurrence rate and no revision with a relatively large number of cases, and the complication of limping gait was first mentioned in the literature. Nam *et al.* [26] obtained excellent results with no recurrence or complications. Similar results can be seen in our study with the same follow-up period but with the arthroscopic approach.

In our studies, two patients complained of tightness with exercise but without snaps, and no muscle weakness was noted in the follow-up period. The same symptom was reported in Zini *et al.* and Polesello *et al.* [15, 16]. According to our observation, this symptom should be considered as easy fatigue of the surgical site due to incision on the muscle, but surgical damage of the muscle is not large enough to cause muscle weakness. This phenomenon could also be seen in Yoon *et al.* [13]. As the only study that performed multiple incisions, it is the only study reporting the complication of limping gait. Thus, the larger the scale of release, the higher the risk of muscle weakness and fatigue. In addition,

Table I. Literature review of arthroscopic surgery for external snapping hips

Study	Year	No. of hips (No. of patients)	Technique	Follow-up period (months)	Symptom free ratio	Results
Ilizaliturri [12]	2006	11 (10)	Diamond-shaped resection on ITB with resection of the GT bursa.	24	91%	1 mild snap
Polesello [15]	2013	9 (8)	GM tendon release	22	78%	1 revision 1 residual snap mHHS: 61-> 78
Zini [16]	2013	15 (15)	Transverse complete cut of ITB with release of GM	33.8	60%	6 mild exercising pain VAS 5.5 -> 0.53 Post OP mHHS 97.8
Yoon [17]	2014	10 (7)	Cross-cutting with flap resection	19	90%	VAS: 6.8 -> 0.2 mHHS 68.2-> 94.8
Shrestha [18]	2017	248 (248)	Complete cut of contractures GM and tensor fascia lata (TFL) bands	24	100%	No recurrence No complication
Park [19]	2017	24 (17)	Modified N-plasty of ITB	24.5	100%	1 wound infection VAS:6.77-> 0.09 mHHS 69.5-> 97.8
Thomassen [21]	2019	11 (11)	Star-shaped resection on ITB	28	90%	1 revision VAS: 8-> 4 mHHS 73.8-> 86.8
Chan	2020	18 (18)	Diamond-shaped excision on ITB ± bursectomy	84	89%	2 residual tightness VAS 3.67 -> 0.33 mHHS 70.46-> 93.14

Table II. Literature review with follow-up of more than 60 months

Study	Year	No. of hips (No. of patients)	Technique	Follow-up period (months)	Symptom free ratio	Results
Féry [30]	1988	35 (23)	Open cruciate incision with sutures flaps	84	30%	30% recurrence 60% residual pain
Yoon [13]	2009	44 (44)	Open multiple fibrous band release	62	88%	5 snaps 10 weakness
Nam [26]	2011	14 (7)	Open Modified Z-plasty	84	100%	no complication no recurrence
Chan	2020	18 (18)	Arthroscopic diamond-shaped resection of ITB with/without GT bursa resection	84	89%	2 tightness

since most of the candidates were athletes, dancers or people with high activity demand, the balance between symptom relief and muscle strength should be considered before surgery. In our institution, we preferred resection to lengthening because we believed resection could minimize the damage to muscles since the length and size of flap can be adjusted according to the tightness of muscle and body size of our patients. We would check the presentation of snaps during the operation and cut the adequate part for symptom relieving. Besides, we could not assess the muscle power when patient was under general anesthesia during operation, so it was hard for us to find out the best muscle length between symptom relieving and preserving of muscle power. Since most patients were diagnosed with ipsilateral snapping hip, limping gait should be concerned if overcorrection was

noted in lengthening. However, more clinical trials are needed to confirm this phenomenon and determine the best strategy for patients.

Arthroscopic surgery can provide similar clinical outcomes with smaller operation scars and less postoperative pain than open surgery [20], and the outcomes are similar even in the long follow-up period. There were no significant differences in recurrence or complication rates between either short-term or long-term results. However, minimally invasive techniques with arthroscopy cause less pain postoperatively due to smaller incisions and less damage to peripheral soft tissue. In addition, arthroscopic surgery also provides better cosmetic outcomes with fewer complications [23]. Although both open and arthroscopic approaches can provide satisfactory results, arthroscopic

surgery should always be considered due to similar outcomes, with advantages in pain control and cosmetic results.

Our study has several limitations. First, this was a retrospective study without a control group; thus, the results cannot be compared to other surgical techniques directly, and recall bias should be considered. Second, the case number of our study was small. Since conservative treatment is the main treatment option for snapping hip, few patients chose surgery in our institution. Studies with larger case numbers and long follow-up periods are needed in the future. However, our study is the first to provide a subjective assessment of arthroscopic surgery with a long follow-up period. Most importantly, this study found that arthroscopic surgery can provide good long-term clinical outcomes with a low recurrence rate and few complications.

CONCLUSION

Arthroscopic surgery can provide promising and stable long-term clinical outcomes for patients disturbed by external snapping hip, and the improvement of hip function and return to preinjury activity levels is sustainable. In addition, the arthroscopic approach is safe and has a low complication rate using minimally invasive procedures.

DATA AVAILABILITY

The data underlying this article will be shared on reasonable request to the corresponding author.

ACKNOWLEDGEMENTS

This study did not receive any financial support from any institution.

FUNDING

No funding was received for this study.

CONFLICT OF INTEREST STATEMENT

None declared.

REFERENCES

- Schaberg JE, Harper MC, Allen WC. The snapping hip syndrome. *Am J Sports Med* 1984; **12**: 361–5.
- Allen WC, Cope R. Coxa saltans: the snapping hip revisited. *J Am Acad Orthop Surg* 1995; **3**: 303–8.
- White RA, Hughes MS, Burd T *et al*. A new operative approach in the correction of external coxa saltans: the snapping hip. *Am J Sports Med* 2004; **32**: 1504–8.
- Yen YM, Lewis CL, Kim YJ. Understanding and treating the snapping hip. *Sports Med Arthrosc Rev* 2015; **23**: 194–9.
- Choi YS, Lee SM, Song BY *et al*. Dynamic sonography of external snapping hip syndrome. *J Ultrasound Med* 2002; **21**: 753–8.
- Kim CH, Lee SK, Kim JH *et al*. External snapping hip: classification based on magnetic resonance imaging features and clinical correlation. *Hip Int* 2020; **1120700020944139**.
- Pelsser V, Cardinal E, Hobden R *et al*. Extraarticular snapping hip: sonographic findings. *AJR Am J Roentgenol* 2001; **176**: 67–73.
- Lee KS, Rosas HG, Phancao JP. Snapping hip: imaging and treatment. *Semin Musculoskelet Radiol* 2013; **17**: 286–94.
- Rompe JD, Segal NA, Cacchio A *et al*. Home training, local corticosteroid injection, or radial shock wave therapy for greater trochanter pain syndrome. *Am J Sports Med* 2009; **37**: 1981–90.
- Pierce TP, Kurowicki J, Issa K *et al*. External snapping hip: a systematic review of outcomes following surgical intervention: external snapping hip systematic review. *Hip Int* 2018; **28**: 468–72.
- Provencher MT, Hofmeister EP, Muldoon MP. The surgical treatment of external coxa saltans (the snapping hip) by Z-plasty of the iliotibial band. *Am J Sports Med* 2004; **32**: 470–6.
- Ilizaliturri VM, Martinez-Escalante FA, Chaidez PA *et al*. Endoscopic iliotibial band release for external snapping hip syndrome. *Arthroscopy* 2006; **22**: 505–10.
- Yoon TR, Park KS, Diwanji SR *et al*. Clinical results of multiple fibrous band release for the external snapping hip. *J Orthop Sci* 2009; **14**: 405–9.
- Lewis CL. Extra-articular snapping hip: a literature review. *Sports Health* 2010; **2**: 186–90.
- Polesello GC, Queiroz MC, Domb BG *et al*. Surgical technique: endoscopic gluteus maximus tendon release for external snapping hip syndrome. *Clin Orthop Relat Res* 2013; **471**: 2471–6.
- Zini R, Munegato D, De Benedetto M *et al*. Endoscopic iliotibial band release in snapping hip. *Hip Int* 2013; **23**: 225–32.
- Yoon JY, Kwak HS, Yoon KS *et al*. Arthroscopic treatment for external snapping hip. *Hip Pelvis* 2014; **26**: 173–7.
- Shrestha A, Wu P, Ge H *et al*. Clinical outcomes of arthroscopic surgery for external snapping hip. *J Orthop Surg Res* 2017; **12**: 81.
- Park JS, Kim WJ, Lee DW *et al*. External snapping hip treated by effective designed N-plasty of the iliotibial band. *Hip Pelvis* 2017; **29**: 187–93.
- Dai Z, Chen Z, Liao Y *et al*. Comparison of arthroscopic versus open surgery on external snapping hip caused by gluteal muscle contraction. *Hip Int* 2018; **28**: 173–7.
- Thomassen PJB, Basso T, Foss OA. Endoscopic treatment of greater trochanteric pain syndrome - a case series of 11 patients. *J Orthop Case Rep* 2019; **9**: 6–10.
- Faraj AA, Moulton A, Sirivastava VM. Snapping iliotibial band. Report of ten cases and review of the literature. *Acta Orthop Belg* 2001; **67**: 19–23.
- Ilizaliturri VM Jr., Camacho-Galindo J. Endoscopic treatment of snapping hips, iliotibial band, and iliopsoas tendon. *Sports Med Arthrosc Rev* 2010; **18**: 120–7.
- Larsen E, Johansen J. Snapping hip. *Acta Orthop Scand* 1986; **57**: 168–70.
- Zoltan DJ, Clancy WG Jr., Keene JS. A new operative approach to snapping hip and refractory trochanteric bursitis in athletes. *Am J Sports Med* 1986; **14**: 201–4.
- Nam KW, Yoo JJ, Koo KH *et al*. A modified Z-plasty technique for severe tightness of the gluteus maximus. *Scand J Med Sci Sports* 2011; **21**: 85–9.
- Khan M, Adamich J, Simunovic N *et al*. Surgical management of internal snapping hip syndrome: a systematic review evaluating open and arthroscopic approaches. *Arthroscopy* 2013; **29**: 942–8.
- Dickinson AM. Case reports by Dr. Arthur M. Dickinson: bilateral snapping hip. *Am J Surg* 1929; **6**: 97–101.
- Byrd JWT. Snapping hip. *Oper Tech Sports Med* 2005; **13**: 46–54.
- Féry A, Sommelet J. The snapping hip. Late results of 24 surgical cases. *Int Orthop* 1988; **12**: 277–82.
- Everhart JS, Poland S, Vajapey SP *et al*. CrossFit-related hip and groin injuries: a case series. *J Hip Preserv Surg* 2020; **7**: 109–15.
- Lall AC, Walsh JP, Maldonado DR *et al*. Teamwork in hip preservation: the ISHA 2019 Annual Scientific Meeting. *J Hip Preserv Surg* 2020; **7**: 2–21.