



Contents lists available at ScienceDirect

International Journal of Surgery Case Reports

journal homepage: www.casereports.com

Reconstruction of short bowel syndrome after internal hernia in a pregnant woman with previous bariatric surgery[☆]



Märta Kristina Borghede^{a,*}, Lars Vinter-Jensen^a, Jens Christian Andersen^b, Peter Brøndum Mortensen^b, Henrik Højgaard Rasmussen^a

^a Centre for Nutrition and Bowel Disease, Department of Gastroenterology, Aalborg University Hospital, Hobrovej, DK-9100 Aalborg, Denmark

^b Department of Surgery, Aalborg University Hospital, Hobrovej, DK-9100 Aalborg, Denmark

ARTICLE INFO

Article history:

Received 8 August 2013

Accepted 13 August 2013

Available online 8 October 2013

Keywords:

Internal hernia

Laparoscopic gastric bypass

Short bowel syndrome

Pregnancy

ABSTRACT

INTRODUCTION: Bariatric surgery is most often performed with the laparoscopic Roux-en-Y gastric bypass. A complication to the laparoscopic Roux-en-Y gastric bypass is internal hernia, which occurs in up to 16% of the patients. Since the laparoscopic Roux-en-Y gastric bypass is performed in women of fertile age, internal hernia may occur during pregnancy.

PRESENTATION OF CASE: A 22-year old woman with a history of laparoscopic Roux-en-Y gastric bypass suffered from massive internal hernia during pregnancy with widespread bowel necrosis. Extensive surgery was performed leaving the patient with an intact duodenum, 15 cm of jejunum, 35 cm of ileum and colon. Parenteral nutrition was initiated and ten months after the internal hernia, intestinal continuity was re-established. Ten weeks later the patient reached parenteral nutrition independence.

DISCUSSION: Internal hernia after laparoscopic Roux-en-Y gastric bypass can be difficult to diagnose, especially during pregnancy and might be severe and life threatening for both mother and child.

CONCLUSION: Obstetricians and abdominal surgeons must be aware of this condition. Surgery should be performed on a wide indication. When bowel necrosis is found it should be resected and in case of extensive bowel resection the patient should be evaluated in centres specialized in intestinal failure.

© 2013 The Authors. Published by Elsevier Ltd on behalf of Surgical Associates Ltd. All rights reserved.

1. Introduction

Bariatric surgery is most often performed with the laparoscopic Roux-en-Y gastric bypass (LRGB). LRGB has favourable effects such as weight loss and correction of metabolic disturbances, but is also associated with serious complications. Internal hernia occurs in up to 16% of the patients.¹ It is a severe complication, which can lead to massive bowel necrosis that may result in short bowel syndrome (SBS) and sometimes death.^{2,3} Pregnant women, who have previously undergone LRGB, represent a diagnostic challenge when presenting with acute abdomen and internal hernia in this setting might be particularly risky.

In this case, we present a 22-year-old woman, who had undergone LRGB and who suffered a massive internal hernia during pregnancy leading to short bowel syndrome.

2. Presentation of case

In January 2012, at 26 weeks of gestation, a 22-year-old woman was admitted to our surgical department due to sudden onset of upper abdominal pain. The patient was otherwise healthy and had at the time she became pregnant lost 50 kg following a LRGB done two years and 11 months earlier.

Following admission, an acute ultrasound showed gall bladder stones, and a MRI scan showed no definite signs of internal hernia but could not demonstrate gallstones. Due to severe pain, open cholecystectomy was performed. A trans-cystic balloon dilation of the papilla of Vater was done as the cholangiogram demonstrated poor drainage caused by small gallstones in the common hepatic bile duct. On the 5th postoperative day she was re-operated due to cholangios with renewed cystic duct ligation and drainage. On the following day, endoscopy was performed because of hematemesis, with the finding of blood in the jejunum, but no specific bleeding site was identified. The clinical condition worsened and she was transferred to the intensive care unit (ICU) with severe septicæmia and acute respiratory distress syndrome (ARDS). On day 13, a laparotomy was performed. An internal hernia through Petersen's space with necrosis of 1 m jejunum starting 10 cm below the pouch-enteric anastomosis was found. A vital premature girl of 1020 g was delivered by caesarean and the necrotic intestine was removed. Second and third look operations were performed the next days with further small bowel resections leaving her with a saliva fistula

[☆] This is an open-access article distributed under the terms of the Creative Commons Attribution-NonCommercial-No Derivative Works License, which permits non-commercial use, distribution, and reproduction in any medium, provided the original author and source are credited.

* Corresponding author at: Department of Gastroenterology, Aalborg University Hospital, Mølleparkvej 4, 9000 Aalborg, Denmark. Tel.: +45 99326241; fax: +45 99326507.

E-mail address: marta.borghede@gmail.com (M.K. Borghede).

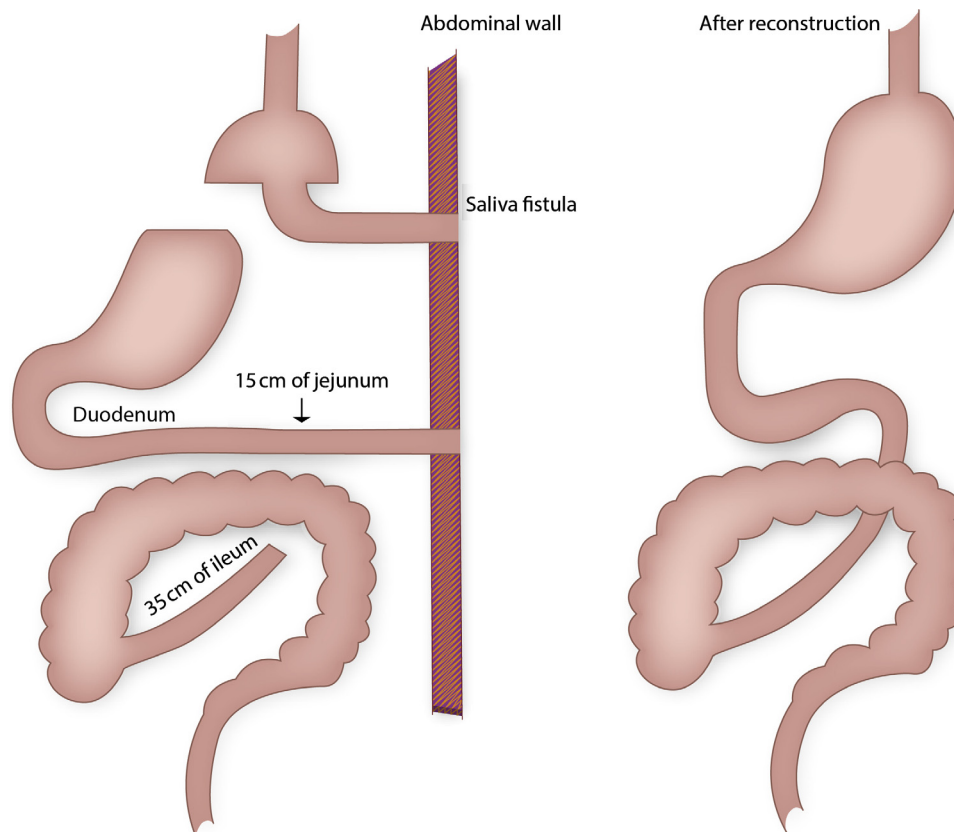


Fig. 1. The intestinal system of a 22-year old woman with previous gastric bypass operation after internal herniation with massive bowel necrosis. The patient ended up with a saliva fistula from the pouch-enteric anastomosis, a jejunostomy 15 cm from the ligament of Treitz, and a blind closed ileum 35 cm from the ileo-coecal valve (left). Ten months later the intestinal continuity was reestablished (right).

10 cm below the pouch-enteric anastomosis, a jejunostomy 15 cm from the ligament of Treitz and a blind closed ileum 35 cm from the ileo-coecal valve (Fig. 1).

After 3 months in the ICU and surgical ward with several other complications, such as infectious complications, pneumothorax, thrombosis of the superior mesenteric vein as well as the iliac veins and a exposed bowel parquet covered with split skin, the patient was transferred to our intestinal failure unit. The patient had a good appetite and enjoyed the meals, but obviously she had no absorption of food due to the very short fistula below the pouch-enteric anastomosis. Through a central venous line (Hickmann catheter) she initially received 2200 kcal and later when she increased her daily activities this was increased according to 2700 kcal given as SMOF Kabiven (Fresenius) added with vitamins and trace elements, and in addition 3 l of isotonic saline to maintain the fluid balance. Also in this phase complications occurred, and the Hickmann catheter eventually had to be removed due to a yeast infection with *Candida albicans*. The nutrition was thereafter delivered through a peripherally inserted central venous catheter (PICCline). After four months of hospitalization the patient was discharged with home parenteral nutrition. In November 2012, ten month after the internal herniation, intestinal continuity was reconstructed, and a defect having a width of up to 12 cm in the anterior abdominal wall was closed with bilateral partial component separation technique ad modum Ramirez.⁴ Six weeks after the operation, the PICCline occluded and was removed. The patient insisted on trying without parenteral nutrition, and 10 weeks later, she was doing well. Her weight had increased 2 kg since the operation, she had 1–2 bowel movements a day and blood values for haemoglobin and albumin had increased as well.

3. Discussion

This patient suffered from massive small bowel internal hernia with extensive bowel resection leading to SBS dependent on parenteral nutrition during her pregnancy. The patient was left with an intact duodenum, 15 cm of jejunum, 35 cm of ileum and her colon. Initially she was treated with 100% parenteral nutrition, but after reconstructive surgery with re-established intestinal continuity the amount of parenteral nutrition was rapidly reduced, and after six weeks she was weaned off parenteral nutrition.

Several cases of internal hernias during pregnancies have been reported and three maternal deaths have been described.⁵ Renault et al.³ and Loar et al.⁶ describe severe internal hernias in pregnant women, involving the entire small intestine, parts of the colon and in Renault et al. even parts of the ventricle. In these cases surgical and medical interventions were considered futile and the patients died. Our patient also suffered a severe internal hernia with necrotic intestine. She underwent extensive bowel resection leading to an acute intestinal failure associated with severe complications (type 2 intestinal failure). After treatment in a specialized intestinal failure unit, she underwent a long and complicated rehabilitation period and was discharged with a short bowel syndrome treated with home parenteral nutrition and fluids (type 3 intestinal failure), and she survived.

To our knowledge, no pregnant woman with LRGB has previously survived an internal herniation with such massive bowel necrosis as in this case, see Table 1. This illustrates the importance of extensive surgery, second and third looks operations. The University of Nebraska Medical Center describes in a series of papers that 5 out of 210 patient with postoperative SBS had previous gastric bypass operation,⁷ and thereafter they scrutinized

Table 1
Review of reported cases of internal hernias in pregnant women with previous gastric bypass. Reports on bowel resection, foetal death and maternal outcome are shown.^{3,6,8,10–15}

Authors	Bowel resection	Foetal death	Maternal outcome
Moore et al. ¹⁴	61 cm	Yes	Death, ventricular fibrillation
Charles et al. ¹⁰	Non viable portions of the Roux-limb	Yes	Survived
Loar et al. ⁶	No, surgery considered futile	No	Death, three days postpartum
Wang et al. ¹⁵	20 cm	No	Survived
Efthimiou et al. ¹¹	100 cm	Yes	Survived
Gazzalle et al. ¹²	150 cm	No	Survived
Hooks et al. ¹³	Resection of jejunal anastomosis	No	Survived
Boland et al. ⁸	Yes, 70 cm small intestine remaining	No	SBS
Renault et al. ³	No, surgery considered futile	No	Death, three days postpartum
Current study	Yes, 50 cm small intestine remaining	No	SBS

SBS = short bowel syndrome; IH = internal hernia.

9 patients with SBS that had bariatric surgery performed.² In a more recent paper, they reviewed 9 cases with massive bowel resection during pregnancy leading to small bowel syndrome.⁸ One of these had previous LRGB. Internal hernia during pregnancy mostly occur in the third trimester and postpartum. It is believed to be caused by the growing uterus, which increases the intra-abdominal pressure, or postpartum as the uterus rapidly decreases in size.³

The surveys of series of patients with previous bariatric surgery demonstrate that up to 16% of the patients develop internal herniation.¹ Most bariatric surgeries have been performed in women of reproductive age, and as LRGB increases fertility, complications during pregnancy are to be expected. It is suggested that the changed anatomy during pregnancy disposes for herniation to occur. During pregnancy, the cause of abdominal pain can be difficult to diagnose, with potentially fatal consequences for both mother and foetus. This should be of particular concern for obstetricians and abdominal surgeons. It is most important that relevant tools such as MRI or CT scans are not postponed. Interpretation of MRI and CT scan can be difficult especially in pregnant women, thus laparoscopy should be performed on a wide indication, when there is clinical suspicion of internal hernia and laparotomy performed if the anatomy is not clear.

In the present paper, we describe a successful reconstruction. The literature provides other successful reconstructions after LRGB complicated with internal obstruction. A case report of a 44-year-old woman, who suffered from volvulus after LRGB, leaving her with an intact duodenum, 25 cm of jejunum and ileum and colon, has been described. Interestingly she eventually managed after reconstruction without parenteral nutrition.⁹ The younger age of our patient leaves her with an even better chance to stay off parenteral nutrition.

4. Conclusion

Since internal hernia is potentially life threatening for mother and foetus, both obstetricians and abdominal surgeons must be aware of this condition and surgery should be performed on a wide indication. When bowel necrosis is found it should be resected and in case of extensive bowel resection the patient should start parenteral nutrition, and an evaluation should be made in centres specialized in intestinal failure.

Authors’ contributions

All authors have contributed to acquisition of data, analysis and interpretation of data, writing, drafting the article and revising it critically for important intellectual content and approved of the final version.

Conflict of interest statement

None.

Role of funding sources

None.

Ethical approval

Written informed consent was obtained from the patient for publication of this case report and case series and accompanying images. A copy of the written consent is available for review by the Editor-in-Chief of this journal on request.

References

- Higa K, Ho T, Tercero F, Yunus T, Boone KB. Laparoscopic Roux-en-Y gastric bypass: 10-year follow-up. *Surg Obes Relat Dis* 2011;**7**(July (4)):516–25.
- McBride CL, Petersen A, Sudan D, Thompson J. Short bowel syndrome following bariatric surgical procedures. *Am J Surg* 2006;**192**(December (6)):828–32.
- Renault K, Gyrttrup HJ, Damgaard K, Hedegaard M, Sorensen JL. Pregnant woman with fatal complication after laparoscopic Roux-en-Y gastric bypass. *Acta Obstet Gynecol Scand* 2012;**91**(July (7)):873–5.
- Ramirez MM, Turrentine MA. Gastrointestinal hemorrhage during pregnancy in a patient with a history of vertical-banded gastroplasty. *Am J Obstet Gynecol* 1995;**173**(November (5)):1630–1.
- Leal-Gonzalez R, Garza-Ramos R, Guajardo-Perez H, Ayala-Aguilera F, Rumbaut R. Internal hernias in pregnant women with history of gastric bypass surgery: case series and review of literature. *Int J Surg Case Rep* 2013;**4**(1):44–7.
- Loar III PV, Sanchez-Ramos L, Kaunitz AM, Kerwin AJ, Diaz J. Maternal death caused by midgut volvulus after bariatric surgery. *Am J Obstet Gynecol* 2005;**193**(November (5)):1748–9.
- Thompson JS, DiBaise JK, Iyer KR, Yeats M, Sudan DL. Postoperative short bowel syndrome. *J Am Coll Surg* 2005;**201**(July (1)):85–9.
- Boland E, Thompson JS, Grant WJ, Botha J, Langnas AN, Mercer DF. Massive small bowel resection during pregnancy causing short bowel syndrome. *Am Surg* 2011;**77**(December (12)):1589–92.
- Genton L, Nardo P, Huber O, Pichard C. Parenteral nutrition independence in a patient left with 25 cm of ileum and jejunum: a case report. *Obes Surg* 2010;**20**(May (5)):666–71.

10. Charles A, Domingo S, Goldfadden A, Fader J, Lampmann R, Mazzeo R. Small bowel ischemia after Roux-en-Y gastric bypass complicated by pregnancy: a case report. *Am Surg* 2005;**71**(March (3)):231–4.
11. Efthimiou E, Stein L, Court O, Christou N. Internal hernia after gastric bypass surgery during middle trimester pregnancy resulting in fetal loss: risk of internal hernia never ends. *Surg Obes Relat Dis* 2009;**5**(May (3)):378–80.
12. Gazzalle A, Braun D, Cavazzola LT, Wendt LR, Navarini D, Fauri MA, et al. Late intestinal obstruction due to an intestinal volvulus in a pregnant patient with a previous Roux-en-Y gastric bypass. *Obes Surg* 2010;**20**(December (12)):1740–2.
13. Hooks III WB, Westbrook AD, Clancy TV, Hope WW. Small bowel obstruction in a postpartum woman after laparoscopic Roux-en-Y gastric bypass. *Surg Obes Relat Dis* 2010;**6**(March (2)):209–10.
14. Moore KA, Ouyang DW, Whang EE. Maternal and fetal deaths after gastric bypass surgery for morbid obesity. *N Engl J Med* 2004;**351**(August (7)):721–2.
15. Wang CB, Hsieh CC, Chen CH, Lin YH, Lee CY, Tseng CJ. Strangulation of upper jejunum in subsequent pregnancy following gastric bypass surgery. *Taiwan J Obstet Gynecol* 2007;**46**(September (3)):267–71.

Open Access

This article is published Open Access at scimedirect.com. It is distributed under the [IJSCR Supplemental terms and conditions](#), which permits unrestricted non commercial use, distribution, and reproduction in any medium, provided the original authors and source are credited.