

Frequency and nature of endoscopic and pathologic errors leading to referral for endoscopic resection to a tertiary center



Authors

Rachel E. Lahr¹, Connor D. McWhinney¹, Oscar W. Cummings², Douglas K. Rex¹

Institutions

- 1 Division of Gastroenterology/Hepatology, Indiana University School of Medicine Indianapolis, Indiana, United States
- 2 Department of Pathology and Laboratory Medicine, Indiana University School of Medicine, Indianapolis, Indiana, United States

submitted 8.6.2022

accepted after revision 11.10.2022

published online 12.10.2022

Bibliography

Endosc Int Open 2022; 10: E1555–E1561

DOI 10.1055/a-1959-6012

ISSN 2364-3722

© 2022. The Author(s).

This is an open access article published by Thieme under the terms of the Creative Commons Attribution-NonDerivative-NonCommercial License, permitting copying and reproduction so long as the original work is given appropriate credit. Contents may not be used for commercial purposes, or adapted, remixed, transformed or built upon. (<https://creativecommons.org/licenses/by-nc-nd/4.0/>)

Georg Thieme Verlag KG, Rüdigerstraße 14,
70469 Stuttgart, Germany

Corresponding author

Douglas K. Rex, MD, 550 N. University Blvd, Suite 4100,
Indianapolis, IN 46202
Phone: +1-317-948-8741
drex@iu.edu

Supplementary material is available under
<https://doi.org/10.1055/a-1959-6012>

ABSTRACT

Background and study aims We anecdotally encounter cases where referring endoscopists made errors in endoscopic interpretation of a colorectal lesion, sometimes combined with pathology errors at the referring centers, resulting in referral to our center for endoscopic resection. In this paper, we describe the frequency and nature of endoscopic and pathology errors leading to consultation for endoscopic resection.

Patients and methods Review of 760 consecutive referrals to our center over a 26-month interval.

Results In total, 28 (3.7%) of all referred patients had ≥ 1 lesion that did not require any resection after investigation. There were 12 cases (1.6% of all referrals) involving errors by both the referring endoscopist and the pathologist at the referring center. Errors commonly involved the ileocecal valve, lipomas, and mucosal prolapse changes. There were 15 additional referrals (2.0% of all referrals) where no neoplastic lesion was identified at our center and either no biopsy was taken at the referring center ($n=9$ patients, 10 lesions), the patient was referred although biopsy showed no neoplasia ($n=6$), or the referring doctor correctly interpreted the lesion (lipoma), but the outside pathologist incorrectly reported adenoma ($n=1$).

Conclusions Endoscopists at tertiary centers should expect referrals to clarify the nature of colorectal lesions as neoplastic or non-neoplastic. Community endoscopists with equivocal endoscopic findings and unexpected or equivocal pathology results can consider pathology review at their center or at an expert center before referral for endoscopic or surgical resection.

Introduction

Anecdotally, normal endoscopic structures in the colorectum such as the ileocecal valve, as well as abnormal but non-neoplastic lesions such as lipomas, mucosal prolapse, and granulation tissue may be incorrectly interpreted as neoplasms requiring resection. In cases of endoscopist uncertainty, these areas may undergo endoscopic biopsy. If biopsies show no neoplasia, the endoscopist may be reassured. However, in cases of contin-

ued endoscopic uncertainty, or if biopsies are read by pathology as neoplastic tissue, there may be an attempt at endoscopic or surgical resection or referral to an expert endoscopist or surgeon for resection. In this report, we describe cases involving endoscopic misinterpretation and, in some cases, incorrect readings by pathologists which lead to referrals for endoscopic or surgical resection.

Patients and methods

Since 2000, we prospectively maintained a database of colorectal lesions ≥ 20 mm that underwent endoscopic resection at our center. Beginning in August 2019, we kept a database for all referred lesions, regardless of size, and regardless of whether endoscopic resection at our center was undertaken. The latter database was used to identify cases in this report. Permission to review the database was granted by the Institutional Review Board at Indiana University on October 5, 2021.

We identified cases referred for endoscopic resection from August 12, 2019 to March 1, 2022 in which errors in endoscopic or pathology interpretation or both led to a referral to our center for endoscopic resection. Cases were included if the referred lesion proved to be non-neoplastic and not clinically warranting resection at our center, based on endoscopic assessments by the expert at our center, in combination with review of outside pathology by expert gastroenterology center and/or biopsies of the referral lesion at our center. In 2020 there was a gap of 3.5 months (mid-March through June) where data were not collected because research assistants were not allowed in the endoscopy units due to the COVID-19 pandemic. Thus, the study period involved 26 months. In some cases, additional biopsies of the area in question were performed at our center, and in some cases, pathologic slides from the referring center were reviewed (before or after the procedure at our center).

All statistics are descriptive.

Results

Exclusions and inclusions

During the 26-month study interval, 760 patients with 897 lesions were referred to the senior author for endoscopic resection of one or more colorectal lesions. Mean age was 64.84 years and there were 401 males (52.8%). For this report we excluded 732 patients (96.3%), primarily because they were referred with a lesion that was identified and resected at our center. A full description of the excluded patients is given in the Supplementary Material. Thus, there were 28 patients (3.7% of all referred patients) with 29 lesions included in the study, because they were referred for resection of at least one lesion that was ultimately determined to be non-neoplastic at our center and to not warrant resection. Two of these patients had two referred lesions, one of which was excluded (removed at our center) and the second was included.

Referrals associated with both endoscopic and pathology misinterpretations

► **Table 1** lists features of 12 cases (1.6% of all referrals) referred for endoscopic consultation that involved errors in both endoscopic assessment and pathology interpretation at the referral center. In each case, the lesion was determined at our center to not be precancerous lesion and to not warrant either endoscopic or surgical resection. Four cases (► **Table 1**, Cases 1–4) involved interpretation of either normal features of the ileocecal valve or a lipoma on the ileocecal valve (ICV). One other case involved a lipoma (► **Table 1**, Case 5), for which biopsy at the

outside center was incorrectly interpreted as hyperplastic polyp. Biopsies at our center showed mucosal prolapse changes on the surface of the lipoma, as did review of the outside pathology slides at our center. Two other cases also involved mucosal prolapse. One was incorrectly identified as a mass by the referring endoscopist (► **Table 1**, Case 6; ► **Fig. 1a**), and incorrectly identified as an adenoma by the referring pathologist (► **Fig. 1b**). The other was described by the referring physician as a 2- to 2.5-cm flat white area seen on retroflexion in the rectum (► **Table 1**, Case 7; ► **Fig. 2**). Biopsy revealed adenoma at the referring center. At our center the endoscopic changes were resolved, and these biopsies were read as “fibrous and reactive epithelial change.” Review of slides from the outside hospital at our center revealed mucosal prolapse.

Two cases involved the referring endoscopist describing vague mucosal abnormalities. One case was described as mildly nodular mucosa in the cecum over 3 to 4 cm (► **Table 1**, Case 8). The referring pathologist identified “adenomatous change” in the biopsy. At our center, the cecum appeared endoscopically normal. Review of the outside biopsies at our center demonstrated normal colonic mucosa (► **Fig. 3**). The other involved “congested mucosa” in the ascending colon (► **Table 1**, Case 9). Biopsies at the outside hospital were read as tubular adenoma. At our center no lesions were seen, and review of the outside pathology showed normal mucosa.

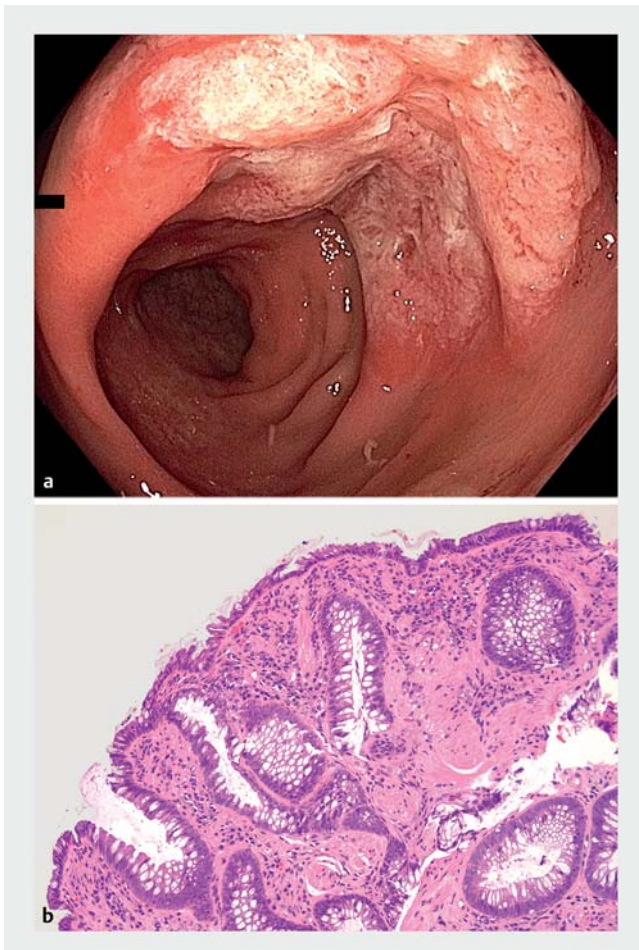
Two cases involved an area of granulation tissue and ulceration. One was (► **Table 1**, Case 10; ► **Fig. 4a**) interpreted as a mass by the referring endoscopist and by the pathologist at the outside center as an adenoma. This case was referred to a colorectal surgeon at our center for right hemicolectomy. The surgeon forwarded the endoscopic photographs to the senior author, who interpreted them as ulceration and granulation tissue and recommended review of the outside pathology. This review showed primarily granulation tissue (► **Fig. 4b**), with an area of reactive atypia (► **Fig. 4c**). A repeat colonoscopy was performed at our center after a period of abstinence from non-steroidal anti-inflammatory (NSAID) use. There was complete healing of the area in the right colon, and no additional biopsies were taken. The patient was instructed to remain off NSAIDs. The second case (► **Table 1**, Case 11) involved a large inflammatory polyp in the transverse colon interpreted as a “mass” by the referring physician. At our center the lesion appeared to be a large inflammatory polyp, which was confirmed by biopsy at our center and by review of the outside pathology.

The final case (► **Table 1**, Case 12) involved many polyps throughout the colon which were biopsied at the referring center and interpreted as hyperplastic polyps. The patient was considered to have Type 2 serrated polyposis syndrome. At our center the lesions appeared to be very prominent lymphoid follicles with clear centers, and lymphoid hyperplasia was confirmed by biopsy at our center and review of outside pathology.

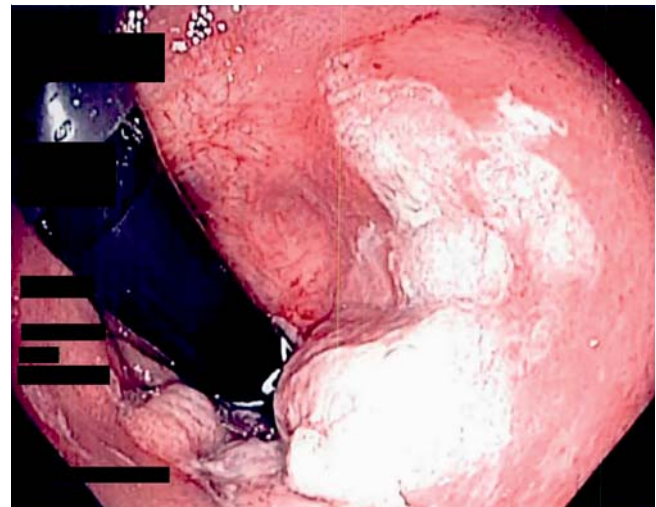
► **Table 1** Twelve cases where errors in interpretation by both the outside endoscopist and pathologist led to referral to our center.

Case number	Endoscopic finding at referral center	Pathology reading at referral center	Endoscopic finding at our center	Pathology finding at our center	Review of outside pathology at our center	Comments
1	Erythematous, irregular nodular, inflamed thickened ICV	Hyperplastic polyp	Normal ICV	Normal	Enteric and colonic mucosa with mild acute inflammation, small bowel fragments	
2	4 cm broad polyp on ICV	Hyperplastic polyp	Lipoma on ICV	Normal	Normal	
3	Fatty ICV polyp versus polyp	Focal features suggestive of focal early tubular adenoma	7-mm cyst on ICV orifice	Cyst: normal mucosa with dilated lacteals	Normal mucosa	
4	Focal thickened prominent mucosa ICV	Hyperplastic polyp	Normal ICV	Normal	Normal	
5	4- to 5-cm pedunculated sigmoid colon mass, partly obstructing	Hyperplastic polyp	Large sigmoid lipoma	Mucosal prolapse	Mucosal prolapse	
6	5-cm mass in rectum	Adenomatous polyp	Multiple rectal ulcers consistent with solitary rectal ulcer syndrome	Mucosal prolapse	Mucosal prolapse	Patient underwent sigmoid resection and rectopexy
7	2- to 2.5-cm white area in rectum on retroflexion	Adenoma	Changes resolved	Fibrosis with reactive epithelial change	Mucosal prolapse	
8	Mildly nodular mucosa in cecum over 3-4 cm might be normal variant cannot exclude flat polyp	Adenomatous change	No lesion	No biopsies taken	Normal mucosa	
9	Congested mucosa ascending colon	Tubular Adenoma	No lesion	No biopsies taken	Normal mucosa	
10	Mass proximal ascending colon one-third to one-half circumference; 4-5 cm; worrisome for cancer	Tubular adenoma	Review of outside photos: ulcer with granulation tissue; Repeat colonoscopy at our center → scar consistent with healed ulcer	No biopsies taken	Granulation tissue; 4-5 glands that are "indeterminate for dysplasia", possibly reactive	Patient advised to stay off NSAIDs
11	Transverse colon mass with adjacent polyps	Tubular adenoma	Review of outside photos: Inflammatory mass and adjacent inflammatory polyps	Inflammatory polyps	Inflammatory polyps	
12	Multiple small polyps	Hyperplastic polyps	Lymphoid hyperplasia	Lymphoid hyperplasia	Lymphoid hyperplasia	

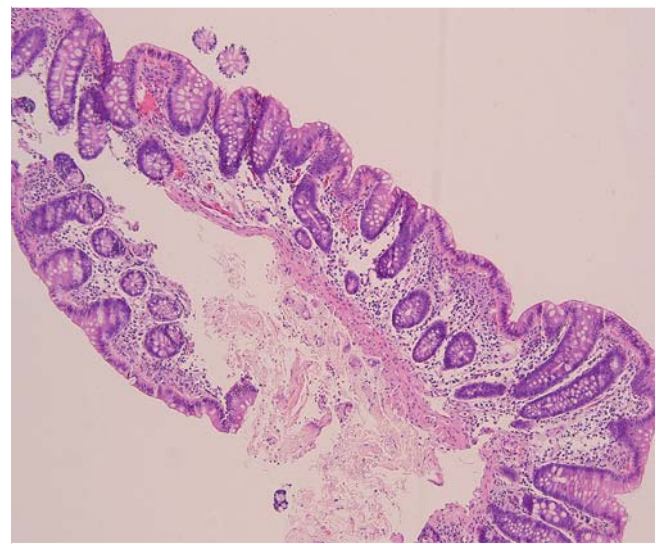
ICV, ileocecal valve.



► **Fig. 1** **a** Endoscopic photo of the rectum in Case 6, described as a mass by the referring physician. **b** Higher magnification view of Case 6 showing some irregularity to the colonic glands due to the prominent fibromuscular hyperplasia in the lamina propria- all features of mucosal prolapse. In other foci there was an erosion with some acute inflammation. No dysplasia is present.



► **Fig. 2** Endoscopic photograph taken by the referring colonoscopist (► [Table 1](#), Case 7).



► **Fig. 3** Outside biopsy of Case 8 showing an intact colonic architecture with no evidence of dysplasia – basically normal colonic mucosa.

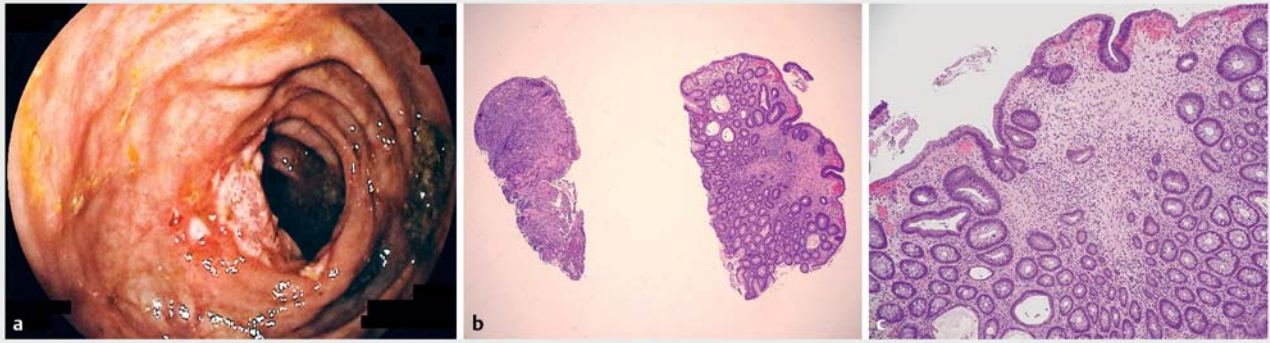
Referrals associated with endoscopic misinterpretations alone

There were 15 additional cases where a polyp was identified endoscopically at the referring center, but biopsy of the lesion at the referring center demonstrated no neoplasia ($n=6$) or no biopsy had been taken ($n=9$).

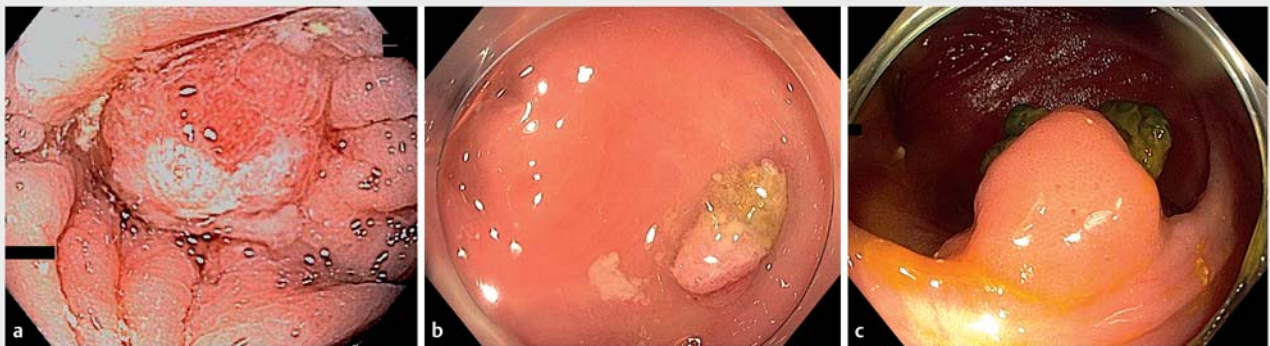Of the six lesions that had undergone biopsy at the referring center, one was a nodule of granulation tissue in a hepatic flexure tic (► [Fig. 5a](#)), confirmed by biopsy at both the referring center and our center. A second was described as residual polyp tissue on an endoscopic mucosal resection (EMR) scar at the referring center, but biopsy was normal. At our center, the scar demonstrated clip artifact but no residual adenoma. A third was described at the referring center as a 10-cm segment in the sigmoid colon with multiple equivocal polyps. Biopsy of the area demonstrated fragments of hyperplastic tissue. The area was marked with tattoos at the proximal and distal ends. Multiple passes through the segment between the tattoos at our center demonstrated no endoscopic abnormality. A fourth

involved a 1.5-cm polyp at an ileocolonic anastomosis, and biopsy at the referring center had demonstrated normal small bowel mucosa. At our center, there was a polyp of normal-appearing small bowel mucosa surrounding a retained suture (► [Fig. 5c](#)). Repeat biopsies confirmed normal small bowel mucosa. The fifth and sixth lesions involved a right colon lipoma and sigmoid mucosal prolapse, both interpreted as polyps by the referring endoscopist.

There were nine cases in which no biopsy was taken at the referring center, and no neoplastic lesion could be confirmed at our center. One of these involved a polyp in a sigmoid diverticulum, confirmed as granulation tissue by biopsy at our center (► [Fig. 5b](#)). A second involved nodular mucosa in the cecum between the appendiceal orifice and ICV. The endoscopic photographs taken at the referring center suggested inflammatory



► **Fig. 4** **a** Endoscopic photograph from the referring endoscopist of Case 10 described as a mass. Recognized at our center as granulation tissue. **b** Two fragments from the colon biopsy, the left fragment showing granulation tissue consistent with an ulcer, the right fragment showing inflammatory changes. **c** Higher magnification of the inflamed fragment showing some surface epithelial crowding, hyperchromasia, and pseudostratification consistent with reactive atypia rather than dysplasia.



► **Fig. 5** Non-neoplastic lesions referred for endoscopic consultation and possible resection. **a** Mound of granulation tissue in the hepatic flexure. **b** Granulation tissue in a sigmoid tic. **c** Mound of small bowel mucosa surrounding an embedded suture (green material).

change. At our center, the area was well demonstrated, and the inflammatory change had largely resolved, and biopsies were negative for neoplasia. A third case involved a prominent ICV found to be normal at our center. A fourth case of a “3–4cm” polyp was confirmed as lipoma at our center. Five other cases involve suspected polyps. The language in these cases suggested uncertainty about the presence of a polyp via terms such as “suspected polyp,” “probable polyp,” “area of mucosal abnormality.” Three of the five reports indicated difficulty with accessing the lesion because of tortuosity or loop formation, and none of the four cases involved either partial snare resection, biopsy, or tattoo. In all five cases, cecal intubation was achieved at our center with a stable and short scope, and the region of abnormality was examined four to six times using exposure devices such the Olympus distal attachment, Endocuff Vision, and in both forward and retroflexed views, and no lesion was identified.

Correct interpretation by the referring endoscopist but error by the outside pathologist

In one case the outside endoscopist diagnosed a lipoma but biopsy was read as adenoma. At our center no adenoma was visible on any surface of the lipoma. Review of the outside pathology was interpreted as normal at our center.

Discussion

In this report, we describe 28 patients referred to a tertiary center for endoscopic or surgical resection as a result of endoscopic interpretations or pathology readings or both at a referring center that indicated or suggested neoplasia, but reevaluation at our center established that no neoplastic lesion was present. These cases constituted 3.7% of referrals for endoscopic resection to our center during this interval.

We consider these cases appropriate referrals, because from the referring endoscopist’s perspective, there may be times where there is uncertainty as to the presence of a discrete lesion, and assistance in sorting the issue from an expert endoscopist is warranted. Further, if biopsies are taken and interpret-

ed incorrectly as neoplasia by the local pathologist, referral to an expert center to sort the situation can be helpful. Endoscopists at expert centers should be aware that these referrals occur. Endoscopists in the community who identify equivocal endoscopic findings and then get biopsy reports of dysplasia that are unexpected or use equivocal language (► **Table 1**) should consider discussion of the findings with their pathologist and reassessment of the pathologic diagnosis, as well as obtaining pathology consultation from an expert pathologist, before referral to another endoscopist or surgeon. In some cases, equivocal mucosal changes could be resolved with the assistance of a more experienced endoscopist. Use of a colonoscope with high-definition, optical magnification, and/or electronic chromoendoscopy could allow better characterization. In general, inability to define mucosal changes as a discrete lesion or polyp versus another mucosal abnormality or variant should be rare. In one case in our series the patient was referred to us from one of our colorectal surgeons who had received a consult for surgical resection. It is possible that many patients undergo operations in the United States for these combined errors of endoscopy or endoscopy and pathology interpretation.

We describe 13 cases where a referral was precipitated in part by an incorrect reading of neoplasia by a pathologist at a referring center. We have previously shown that pathologic interpretation of colorectal polyps in community centers has significant inaccuracies in several regards [1]. In particular, atypical polyps such as mucosal prolapse, inflammatory polyps, and hamartomas, are frequently misinterpreted by community pathologists as adenomas [1]. Endoscopists at referral centers should be aware of this possibility, particularly when endoscopic features are not consistent with reported pathology findings. When there is inconsistency between the pathology findings from the referring center and the endoscopic findings, review of the pathology by the original pathologist and/or a gastrointestinal pathologist at the referral center is often the best course of action, and often leads to resolution of the discrepancy.

In some cases in this series, normal mucosa at the referring center was interpreted as hyperplastic polyp. Because there is large interobserver variation between pathologists in differentiation of hyperplastic polyps from sessile serrated lesions (SSLs) [2, 3], and because some centers have reported to never describe SSLs [4], referral of large lesions described as hyperplastic polyps for resection is clinically warranted, because they could represent large SSLs. However, in the cases in this series, the lesions referred as hyperplastic polyps proved to be neither hyperplastic polyps nor SSLs. This was a relatively common source of the errors encountered in our series (► **Table 1**).

We found that endoscopic locations and lesions that were sources of endoscopic misinterpretation included the ICV, lipomas, mucosal prolapse changes, granulation tissue in diverticula, and clip artifact on EMR scars. We previously reported the frequency of granulation tissue in diverticula [5] and clip artifact at follow-up after clip closure of EMR defects [6]. Our series show that both of these features can cause diagnostic confusion.

Endoscopists at referring centers should not take biopsies when lesions that are endoscopically definite and benign are detected and planned for referral to endoscopic resectionists. Further, tattoos should be prevented from extending under lesions. These steps are intended to avoid unnecessary creation of submucosal fibrosis that could make subsequent endoscopic resection more difficult [7–9]. However, our cases suggest that in the setting of equivocal endoscopic abnormality, biopsy that demonstrates no dysplasia could prevent unnecessary referral. When referral does occur for equivocal lesions, tattoo could help ensure that the endoscopist at the referral center thoroughly examines the region in question.

Conclusions

In conclusion, expert endoscopists at tertiary centers should be aware of referrals for misinterpreted endoscopic findings, sometimes combined with inaccurate pathologic interpretation at referral centers. In our experience, misinterpreted endoscopic findings, with or without misinterpreted histology, accounted for 3.7% of 760 consecutive referrals. General endoscopists should be aware that equivocal or uncertain endoscopic findings may be interpreted as dysplasia or hyperplastic polyp by pathologists. If the pathologic interpretation is unexpected or used equivocal language (► **Table 1**), reassessment by the interpreting pathologist or consultation with an expert pathologist may avert unnecessary referral for resection. Experienced endoscopic assessment of such lesions (to establish that reported pathology from outside centers and the endoscopic appearance are consistent), combined with reinterpretation of the pathology findings when appropriate, can resolve these discrepancies and avoid inappropriate therapy for non-neoplastic lesions.

Competing interests

Douglas K. Rex discloses the following relationships: consultant: Olympus Corporation, Boston Scientific, Aries Pharmaceutical, Braintree Laboratories, Lumendi, Ltd., Norgine, Endokey, GI Supply, Medtronic, Acacia Pharmaceuticals; research Support: EndoAid, Olympus Corporation, Medivators, Erbe USA Inc, Braintree Laboratories; shareholder: Satisfai Health. Remaining authors do not have relationships to disclose.

References

- [1] Rex DK, Alikhan M, Cummings O et al. Accuracy of pathologic interpretation of colorectal polyps by general pathologists in community practice. *Gastrointest Endosc* 1999; 50: 468–474
- [2] Khalid O, Radaideh S, Cummings OW et al. Reinterpretation of histology of proximal colon polyps called hyperplastic in 2001. *World J Gastroenterol* 2009; 15: 3767–3770
- [3] Tinmouth J, Henry P, Hsieh E et al. Sessile serrated polyps at screening colonoscopy: have they been under diagnosed? *Am J Gastroenterol* 2014; 109: 1698–1704
- [4] Payne SR, Church TR, Wandell M et al. Endoscopic detection of proximal serrated lesions and pathologic identification of sessile serrated

adenomas/polyps vary on the basis of center. *Clin Gastroenterol Hepatol* 2014; 12: 1119–1126

- [5] Ghorai S, Ulbright TM, Rex DK. Endoscopic findings of diverticular inflammation in colonoscopy patients without clinical acute diverticulitis: prevalence and endoscopic spectrum. *Am J Gastroenterol* 2003; 98: 802–806
- [6] Sreepati G, Vemulapalli KC, Rex DK. Clip artifact after closure of large colorectal EMR sites: incidence and recognition. *Gastrointest Endosc* 2015; 82: 344–349
- [7] Kaltenbach T, Anderson JC, Burke CA et al. Endoscopic removal of colorectal lesions-recommendations by the US Multi-Society Task Force on Colorectal Cancer. *Gastrointest Endosc* 2020; 91: 486–519
- [8] Ferlitsch M, Moss A, Hassan C et al. Colorectal polypectomy and endoscopic mucosal resection (EMR): European Society of Gastrointestinal Endoscopy (ESGE) Clinical Guideline. *Endoscopy* 2017; 49: 270–297
- [9] Moss A, Bourke MJ, Pathmanathan N. Safety of colonic tattoo with sterile carbon particle suspension: a proposed guideline with illustrative cases. *Gastrointest Endosc* 2011; 74: 214–218