

## The cyamella, a lost sesamoid: Normal variant or posterolateral corner anomaly?

Vineet Khanna, MD, and Catherine Maldjian, MD

Cyamella, an accessory sesamoid ossicle of the popliteus in the region of the proximal myotendinous junction, is an extremely unusual finding, with a paucity of current published literature describing its MR appearance. In this case study, we describe MRI findings in a 44-year-old female presenting with pain after a stretching workout. Bone edema in the cyamella, edema in the myotendinous portion of the popliteus, and pericapsular edema at the posterolateral corner were identified. While commonly seen in certain mammalian species, cyamella is rare in humans. The upright walking posture of humans requires posterolateral corner structures to play a greater role in structural support and weight-bearing. We hypothesize that the cyamella, while intrinsic to certain mammalian species, may interfere with these biomechanical functions in upright walking posture, thereby predisposing to isolated injury of the posterolateral corner in humans.

### Introduction

Embryologically, sesamoids are generally more common during fetal than adult life; with skeletal growth and maturation, they often fuse. Several common sesamoid bones are routinely seen in adults, though, the largest being the patella, in addition to numerous other frequently seen incidental sesamoid bones, such as the distal first metacarpal bone and the distal first metatarsal bone. However, cyamella is an extremely infrequent finding and, given its rare nature, is best characterized as an abnormal finding as opposed to an incidentally noted, physiological variant.

### Case report

A 44-year-old female presented with right knee pain, predominantly at the posterior aspect but also at the medial aspect of her right knee, following a stretching workout.

Subsequently, she had difficulty ambulating due to the knee pain, which was worse when bearing weight. Multiplanar, multisequence MRI evaluation of the right knee was performed, including axial, coronal, and sagittal fat-suppressed T2 sequences and coronal T1 and sagittal proton-density sequences, as shown below (Figs. 1A-C, and 2A-B).

These sequences demonstrated an 8-x-6-mm ovoid ossicle in the proximal popliteus tendon consistent with a cyamella, with associated bone edema compatible with injury to the cyamella, in the setting of myotendinous injury of the popliteus and low-grade posterolateral capsular injury. Additional findings also included edema of Hoffa's fat pad, extensive patellar chondrosis, patella alta, and flattening of the trochlear groove.

The condition was managed conservatively and nonoperatively, including placement of a knee splint, pain relief measures, and recommendations to avoid excessive weight-bearing.

### Discussion

The presence of a cyamella in this patient with isolated posterolateral corner injury may suggest a disruption of the physiological functioning of the popliteus due to an anomalous sesamoid. A comparison of mammalian biomechanics between humans and rabbits offers a reasonable insight into the potential pathophysiology. Though the anatomy of rabbit knees bears some anatomical similarities

---

**Citation:** Khanna V, Maldjian C. The cyamella, a lost sesamoid: Normal variant or posterolateral corner anomaly? *Radiology Case Reports*. (Online) 2014;1:907.

**Copyright:** © 2014 The Authors. This is an open-access article distributed under the terms of the Creative Commons Attribution-NonCommercial-NoDerivs 2.5 License, which permits reproduction and distribution, provided the original work is properly cited. Commercial use and derivative works are not permitted.

The authors are both in the Department of Radiology at the University of Pittsburgh Medical Center, Pittsburgh PA. Contact Dr. Maldjian at [cmaldjian@gmail.com](mailto:cmaldjian@gmail.com).

**Competing Interests:** The authors have declared that no competing interests exist.

**DOI:** 10.2484/rcr.v9i1.907

## The cyamella, a lost sesamoid: Normal variant or posterolateral corner anomaly?

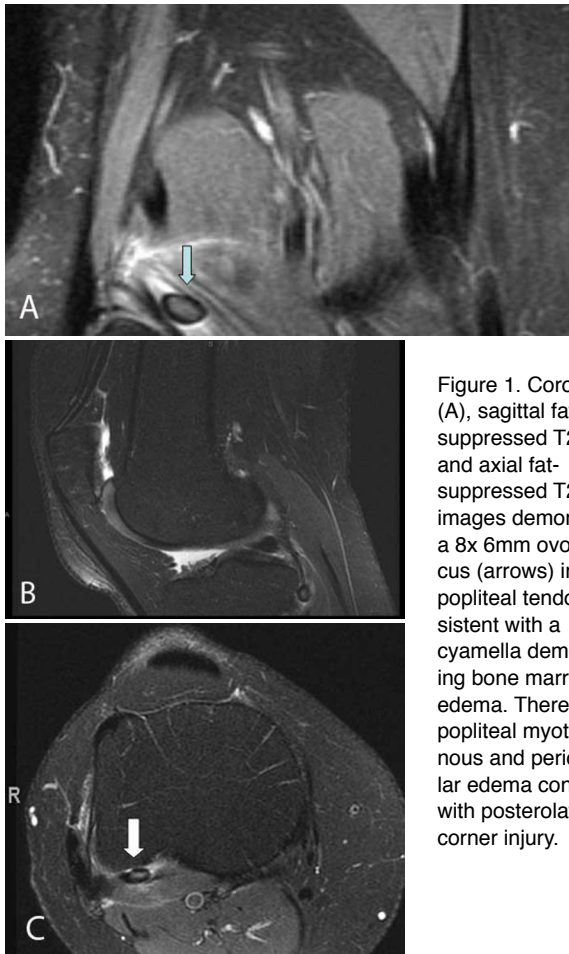


Figure 1. Coronal T1 (A), sagittal fat-suppressed T2 (B), and axial fat-suppressed T2 (C) images demonstrate a 8x6mm ovoid focus (arrows) in the popliteal tendon consistent with a cyamella demonstrating bone marrow edema. There is popliteal myotendinous and pericapsular edema consistent with posterolateral corner injury.

relative to human knees, the physiological biomechanics are notably different. The upright walking posture of humans (as opposed to the flexed posture of rabbits and the physiological presence of a popliteal sesamoid bone in rabbits) are primary differences (1). The thin posterior capsular structures found in the rabbit are in keeping with a flexed knee gait. With an upright posture, the posterolateral corner in humans plays a considerably more important role in structural support of the normal biomechanics, in contrast to the flexed posture of rabbits with its relatively diminished requirement for structural weight-bearing support from the posterolateral corner. Therefore, while the cyamella is a constant finding in the posterolateral corner in rabbits, this is not the case in humans. With increased reliance on the posterolateral corner for structural support in humans, we feel that the cyamella in humans is a pathological entity with the potential to impair the normal biomechanics of the posterolateral structure in its role in weight-bearing in the upright posture.

Evolutionarily, the frequency of a popliteal sesamoid bone is inversely related to the degree of phylogenetic development, and accordingly is less frequently seen in higher primates, including humans (2). Cyamella is commonly seen in certain other mammalian species, with a prevalence of 100% in cats and 84% in dogs. Distal displacement of a

cyamella in dogs has even been proposed as a potential secondary sign of ligamentous injury (3).

Though it is challenging to characterize cyamella definitively, the few published reports of cyamella indicate that its size can vary considerably. The cyamella in this case was 8 mm in greatest axis, definitely smaller than the giant cyamella described by Munk (4).

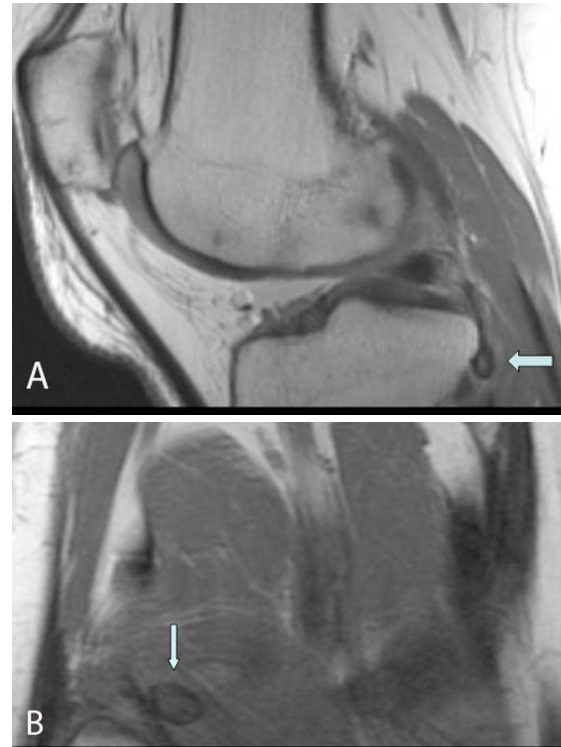


Figure 2. Sagittal proton-density image (A) and coronal T1 image (B) demonstrate a cyamella with marrow edema in the popliteus tendon.

Given the infrequency of cyamella, the characterization and potential exclusion of other potential diagnoses is of particular clinical relevance. Common differential diagnoses include fabella, heterotopic ossification, soft-tissue tumors with associated bone formation, osteocartilaginous loose bodies, free bone fragments in the post-traumatic setting, and detached osteophytes. The location in the popliteus differentiates cyamella from fabella, which is a sesamoid of the lateral gastrocnemius. Clinical history such as trauma, neurological injury, or burns (in the setting of heterotopic ossification) can be of particular value in diagnosis. Bone-marrow signal or the presence of soft tissue can also help differentiate this condition from aggressive, malignant processes such as osteosarcoma. A survey of the remainder of the knee joint, in addition to MR signal characteristics, can help evaluate the likelihood of other etiologies such as osteocartilaginous loose bodies, osteochondromatosis, or the presence of osteophytosis (if there is a concern for a detached osteophyte) (5). With this range of

## The cyamella, a lost sesamoid: Normal variant or posterolateral corner anomaly?

potential differentiating features, multiple modalities including CT, MR, and radiography can all play overlapping, as well as complementary, roles in establishing the rare diagnosis of cyamella.

Consensus treatment algorithms regarding potential operative therapy versus more conservative management are essentially nonexistent for such a rare diagnosis. Potential therapies and goals of treatment are likely to be decided on a case-by-case basis in the context of symptomatology and imaging appearance (2).

### References

1. Crum JA, LaPrade, R, Wentorf, F. A. The anatomy of the posterolateral aspect of the rabbit knee. *Orthop Res.* 2003 Jul 21; (4) 723-9. [PubMed]
2. Benthien, JP, Brunner, A. A symptomatic sesamoid bone in the popliteus muscle (cyamella). *Musculoskeletal Surg.* 2010 Dec;94:141-4. [PubMed]
3. Mc Carthy PH, Wood AK. Anatomical and radiological observations of the sesamoid bone of the popliteus muscle in the adult dog and cat. *Anat Histol Embryol.* 1989 March;18(1):8-65. [PubMed]
4. Munk P, Althathlol A, Rashid F, Malfair D. MR features of a giant cyamella in a patient with osteoarthritis: presentation, diagnosis and discussion. *Skeletal Radiol.* 2009 Jan;38(1):69, 91-2. [PubMed]
5. Akansel G, Inan N, Sarisoy HT, Anik Y, Akansel S. Popliteus muscle sesamoid bone (cyamella): appearance on radiographs, CT, and MRI. *Surg Radiol. Anat.* 2006 Dec;28(6): 642-5. [PubMed]