

Reactive oxygen species modulator 1 (Romo1) as a novel diagnostic marker for lung cancer-related malignant effusion

Seung Hyeun Lee, MD, PhD^a, Myung Jae Park, MD, PhD^a, Sue In Choi, MD^b, Eun Joo Lee, MD, PhD^b, Sang Yeub Lee, MD, PhD^b, Kwang Ho In, MD, PhD^{b,*}

Abstract

Reactive oxygen species modulator 1 (Romo1) is a novel protein that plays an important role in intracellular reactive oxygen species generation. Recently, Romo1 has been suggested to have diagnostic and prognostic potential in lung cancer. However, there is no data on the diagnostic value of Romo1 level in malignant pleural effusion. We evaluated the clinical usefulness of Romo1 in pleural fluid for the diagnosis of malignant effusion in lung cancer patients. Pleural fluid Romo1 level was measured using enzyme-linked immunosorbent assay and compared between lung cancer-associated malignant effusion (n=53; 29 adenocarcinomas and 24 squamous cell carcinomas) and benign pleural effusions (n=91; 31 tuberculous pleurisy, 30 parapneumonic effusion, and 30 transudate). The discriminative power of Romo1 for lung cancer-associated malignant effusion was determined using receiver operating characteristic (ROC) curve analysis and compared with those of other tumor markers. Median Romo1 level in lung cancer-associated malignant effusion was 99.3ng/mL, which was significantly higher than that in benign pleural effusions ($P < 0.001$). The optimal cutoff value of Romo1 to discriminate lung cancer-associated malignant effusion from benign effusions was 67.0 ng/mL with a sensitivity of 73.8% and a specificity of 84.1%. The area under the curve was 0.837 (95% confidence interval [CI]: 0.750–0.886), which was significantly better than that of cytokeratin 19 fragments ($P < 0.001$). Pleural fluid Romo1 could discriminate lung cancer from benign diseases with considerable sensitivity and specificity. Our findings suggest a diagnostic potential of Romo1 for lung cancer-associated malignant effusion.

Abbreviations: AUC = area under the curve, CEA = carcinoembryonic antigen, CYFRA 21-1 = cytokeratin 19 fragments, PPE = parapneumonic effusion, ROS = reactive oxygen species, Romo1 = reactive oxygen species modulator 1, TB = tuberculous.

Keywords: biomarkers, lung cancer, pleural effusion, reactive oxygen species (ROS)

1. Introduction

Pleural effusion in lung cancer is a common clinical presentation. Approximately 20% of lung cancer patients exhibit pleural effusions at the time of diagnosis and 30% to 40% patients develop pleural effusions at some time during the course of cancer.^[1,2] Malignant effusion in lung cancer not only impairs patients' quality of life, but also implies poor prognosis. It confers an M1a descriptor in TNM staging system with a median survival of about 5.5 months.^[3] Thus, diagnosis of malignant effusion in

lung cancer is important for early initiation of treatment and management of symptoms.

Although the diagnosis of malignant pleural effusion is critical, making correct diagnosis is still challenging. Cytological examination is the traditional and standard method for its diagnosis. However, its sensitivity varies from 30% to 60%.^[4,5] Furthermore, the benefit of consecutive blind pleural biopsies is reported to be limited.^[6] Although thoracoscopic pleural biopsy is now widely used in practice, this procedure may not be available at all facilities.^[7] With the development of molecular biology in cancer, tumor markers have been investigated as diagnostic tool for pleural effusion. Many studies have evaluated markers such as carcinoembryonic antigen (CEA) and cytokeratin 19 fragments (CYFRA 21-1) for the diagnosis of malignant pleural effusion. However, despite of extensive researches the diagnostic accuracy of those markers is not yet clinically applicable.^[8–10]

Reactive oxygen species modulator 1 (Romo1) is a novel protein that regulates intracellular reactive oxygen species (ROS) production. The expression level of Romo1 is increased in a wide variety of cancer cell lines including lung cancer cells.^[11] Romo1-induced ROS production is essential for the proliferation of normal cells and cancer cells.^[12] In addition, it has been suggested that Romo1-induced ROS generation is associated with chemoresistance in human lung cancer cells.^[13] Interestingly, the expression of Romo1 is associated with the invasiveness and poor survival of hepatocellular carcinoma patients.^[14] Recently, we have reported that serum Romo1 is significantly increased in lung

Editor: Jianfeng Li.

The authors report no conflicts of interest.

^a Division of Pulmonary and Critical Care Medicine, Department of Internal Medicine, Kyung Hee University School of Medicine, ^b Division of Respiratory and Critical Care Medicine, Department of Internal Medicine, College of Medicine, Korea University, Seoul, Republic of Korea.

* Correspondence: Kwang Ho In, Division of Respiratory and Critical Care Medicine, Department of Internal Medicine, College of Medicine, Korea University, 73, Incheon-ro, Seongbuk-gu, Seoul 02841, Republic of Korea (e-mail: khin@kumc.or.kr).

Copyright © 2017 the Author(s). Published by Wolters Kluwer Health, Inc. This is an open access article distributed under the Creative Commons Attribution-NoDerivatives License 4.0, which allows for redistribution, commercial and non-commercial, as long as it is passed along unchanged and in whole, with credit to the author.

Medicine (2017) 96:4(e5975)

Received: 13 September 2016 / Received in final form: 30 December 2016 /

Accepted: 3 January 2017

<http://dx.doi.org/10.1097/MD.0000000000005975>

cancer patients compared with that in cancer-free population.^[15] In addition, high expression of Romo1 protein was associated with early recurrence and poor survival of lung cancer patients who received surgical treatment.^[16] These studies indicate the potential of Romo1 as a diagnostic and prognostic marker in lung cancer. However, the clinical significance of Romo1 in pleural fluid has not been explored.

We hypothesized that Romo1 level was increased in lung cancer-related malignant effusion. Therefore, we evaluated the clinical usefulness of Romo1 in pleural fluid as a potential diagnostic marker for lung cancer.

2. Materials and methods

2.1. Study subjects and specimens

We prospectively enrolled patients with pleural effusion who were admitted to the Division of Respiratory and Critical Care Medicine at Korea University Anam Hospital or Kyung Hee University Hospital from May 2013 to April 2015. On the day of admission, pleural effusion was collected from subjects and centrifuged at 3000rpm for 10min at 4°C. Supernatant was frozen and stored at -80°C until analysis. Concentrations of Romo1, CEA, and CYFRA 21-1 in pleural effusions were measured. Romo1 level was determined using human Romo1 immunoassay kit (EIAab Science, Wuhan, China). CEA and CYFRA 21-1 levels were measured using electrochemiluminescent immunoassay kit (Roche Diagnostics, Beijing, China) according to the manufacturer's instructions with slight modifications. All samples were blinded to technologists who run the assays. All levels were determined in duplicates. This study was performed after obtaining written informed consent from all patients. The study protocol was approved by the ethics committees of both institutions.

2.2. Diagnostic criteria

The determination of etiology of pleural effusions for each patient was based on clinical presentation, diagnostic test results, and response to treatment. Exudate was defined according to Light's criteria as pleural fluid/serum protein level >0.5, pleural fluid/serum lactate dehydrogenase (LDH) level >0.6, and pleural fluid LDH level >2/3 of the upper limit for serum LDH. Malignant effusion was diagnosed if malignant cells were found on cytological examination or in pleural biopsy specimen. According to the purpose of this study, only lung cancer-associated malignant effusions were enrolled. Parapneumonic effusion (PPE) was identified based on the presence of pulmonary

infection in which the patient had newly acquired fever, purulent sputum, and pneumonic infiltration on chest radiography with response to antibiotic treatment. Tuberculous (TB) pleurisy was diagnosed in cases of lymphocyte dominancy and a high adenosine deaminase level (>40 IU/L) in the pleural fluid with pathological confirmation of caseating granuloma in a pleural biopsy specimen or a positive TB culture for the sputum or pleural fluid.

2.3. Statistical analyses

Data were presented as median and interquartile range. Kruskal–Wallis test or Mann–Whitney *U* test for nonparametric variables was used to compare differences among groups. All tests were 2-tailed. *P* values were corrected for the number of comparisons using Bonferroni method. Receiver operating characteristic (ROC) curves were analyzed to determine the optimal cutoff value and compare the diagnostic accuracies of markers. The cutoff value for each marker was selected based on the best diagnostic efficacy having achieved equilibrium between sensitivity and specificity. For the combinations of markers, the test was considered positive if any of the markers exceeded its cutoff value. A difference was considered as statistically significant if *P* value was less than 0.05. Statistical analysis was carried out using SPSS version 18.0 for Windows (SPSS, Chicago, IL) and MedCalc software (MedCalc, Mariakerke, Belgium).

3. Results

3.1. Patients' characteristics

The clinical characteristics of each group are summarized in Table 1. A total of 144 patients were enrolled, including 53 patients in lung cancer-associated malignant effusion group and 91 in benign effusion group. In lung cancer patients, there were 29 adenocarcinoma and 24 squamous carcinoma. In benign pleural effusions, there were 31 TB pleurisy, 30 PPE, and 30 transudate. All patients were Korean, including 78 (54%) men. The age between malignant and benign pleural effusions was not significantly different (*P*>0.05). However, patients with TB pleurisy were significantly (*P*=0.001) younger compared with other groups.

3.2. Concentrations of Romo1, CEA, and CYFRA 21-1 in each group

Median concentrations of Romo1 in patients with lung cancer, TB pleurisy, PPE, and transudate were 99.3, 45.5, 46.4, and 34.1 ng/mL, respectively (Table 1). Romo1 level in lung cancer group

Table 1

Clinical characteristics and levels of markers in pleural fluid.

Characteristics	Lung cancer-associated malignant effusion (n=53)	Benign pleural effusion (n=91)			<i>P</i>
		Tuberculous pleurisy (n=31)	Parapneumonic effusion (n=30)	Transudate (n=30)	
Age, y	65 (46–74)	43 (27–69)	64 (49–73)	62 (43–70)	0.001
Male sex	29 (54.7)	14 (45.1)	17 (56.7)	18 (60.0)	0.587
Tumor histology					
Adenocarcinoma	29 (54.7)				
Squamous cell carcinoma	24 (45.3)				
Romo1, ng/mL	99.3 (50.9–169.6)	45.5 (25.2–60.6)	46.4 (29.5–66.7)	34.1 (22.8–58.1)	<0.001
CEA, ng/mL	17.3 (4.7–174.6)	1.3 (1.0–2.5)	1.4 (0.5–2.6)	1.3 (0.8–3.9)	<0.001
CYFRA 21-1, ng/mL	150.5 (27.2–507.3)	28.5 (7.6–120.5)	21.8 (10.2–132.5)	22.5 (8.7–101.3)	<0.001

Data are presented as median (interquartile range) or number (%); interquartile range, 25th to 75th percentile; *P* value, Kruskal–Wallis test; CEA=carcinoembryonic antigen, CYFRA 21-1=cytokeratin 19 fragments, Romo1=reactive oxygen species modulator 1.

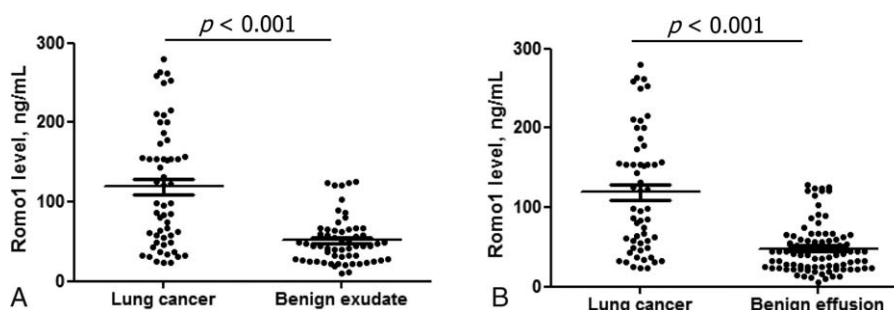


Figure 1. Comparison of pleural fluid Romo1 levels. Pleural fluid Romo1 level was significantly increased in lung cancer patients compared with that in benign exudate (A) or benign pleural effusions (B) (all $P < 0.001$). Bars denote median and interquartile range. Romo1 = reactive oxygen species modulator 1.

was significantly higher than that in each control group (all $P < 0.001$). When TB pleurisy and PPE were considered as the “benign exudate” group, Romo1 level in lung cancer group was significantly higher ($P < 0.001$, Fig. 1A). Romo1 level in lung cancer patients was significantly higher than that in benign pleural effusions ($P < 0.001$, Fig. 1B). Romo1 level was not different among different tumor histologies. Median CEA and CYFRA 21-1 levels in lung cancer groups were 17.3 and 150.5 ng/mL, respectively, which were significantly higher than that in benign pleural effusions ($P < 0.001$, Table 1).

3.3. Diagnostic value of Romo1 for lung cancer-associated malignant effusion

ROC curve analysis was performed to determine the diagnostic performance and optimal cutoff value of pleural fluid Romo1 for lung cancer. Using TB pleurisy as a reference, the optimal discrimination of lung cancer was determined at a cutoff of 67.0 ng/mL with a sensitivity of 68.3% and a specificity of 83.1%; the area under the curve (AUC) was 0.811 (95% confidence interval [CI]: 0.721–0.892, $P < 0.001$) (Fig. 2A). Using benign exudate as a reference, the sensitivity was 67.3% and the specificity was 82.5% with the AUC of 0.803 (95% CI: 0.715–0.865, $P < 0.001$) (Fig. 2B). Using benign pleural effusion as a reference, the sensitivity was 73.8% and the specificity was 84.1% with the AUC of 0.837 (95% CI: 0.750–0.886, $P < 0.001$) (Fig. 2C).

3.4. Comparison of diagnostic performance among markers

The sensitivity, specificity, positive predictive value, and negative predictive values of each single marker and the combinations of markers to discriminate lung cancer-related malignant effusion from benign pleural effusions are summarized in Table 2. The optimal cutoff values of CEA and CYFRA 21-1 were 4.5 and 140.0 ng/mL, respectively. The AUC for CEA was 0.884 (95% CI: 0.811–0.952, $P < 0.001$) with a sensitivity of 76.5% and a specificity of 88.5%. The AUC for CYFRA 21-1 was 0.714 (95% CI: 0.632–0.786, $P < 0.001$) with a sensitivity of 42.9% and a specificity of 95.4%. In a pairwise comparison, CEA showed significantly better diagnostic performance than either Romo1 or CYFRA 21-1 (all $P = 0.001$) and Romo1 was significantly better diagnostic indicator than was CYFRA 21-1 ($P = 0.01$) (Fig. 3). In combinations, CEA+Romo1 showed best diagnostic performance than other combinations (all $P = 0.01$). In addition, CEA+Romo1 showed significantly better diagnostic performance than CEA alone ($P = 0.01$).

4. Discussion

In the present study, pleural fluid Romo1 level was significantly increased in lung cancer patients compared with that in benign causes of pleural effusion. Pleural fluid Romo1 could discriminate lung cancer from benign pleural effusion with considerable

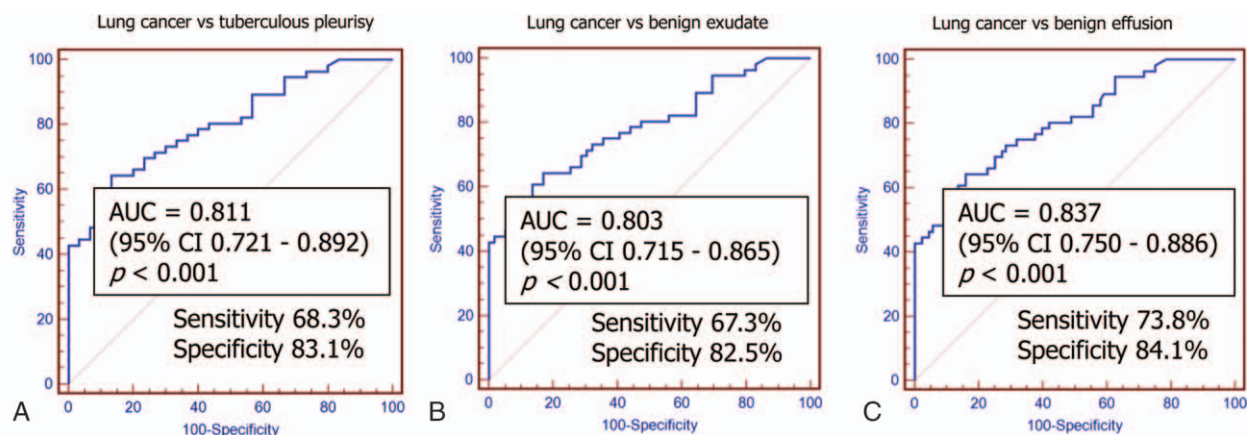


Figure 2. Receiver operating characteristic (ROC) curve analyses of pleural fluid Romo1 levels with tuberculous pleurisy (A), benign exudate (B), and benign effusions (C) as references. The area under the curves (AUCs) ranged from 0.803 to 0.837 with considerable sensitivity and specificity (all $P < 0.001$). Based on AUC value, the best diagnostic performance of pleural fluid Romo1 was noted when the reference was benign effusions. CI = confidence interval, Romo1 = reactive oxygen species modulator 1.

Table 2**Comparison of diagnostic performance for lung cancer-associated malignant effusion among markers.**

Markers	Cutoff (ng/mL)	Sensitivity (%)	Specificity (%)	PPV (%)	NPV (%)
Single					
Romo1	67.0	73.8	84.1	73.0	78.9
CEA	4.5	76.5	88.5	82.5	82.3
CYFRA 21-1	140.0	42.9	95.4	85.7	72.4
Combination*					
Romo1 + CEA		84.8	89.8	83.6	85.9
Romo1 + CYFRA 21-1		78.4	79.5	71.4	83.4
CEA + CYFRA 21-1		79.3	82.0	79.7	83.2
Romo1 + CEA + CYFRA 21-1		86.1	78.2	75.0	87.4

CEA = carcinoembryonic antigen, CYFRA 21-1 = cytokeratin 19 fragments, NPV = negative predictive value, PPV = positive predictive value, Romo1 = reactive oxygen species modulator 1.

* Positive if any of the markers exceeded its cutoff value.

sensitivity and specificity. The diagnostic performance of Romo1 was better than CYFRA 21-1. To the best of our knowledge, this is the first study to show increased Romo1 expression in pleural effusion of lung cancer patients. In addition, we determined the usefulness of pleural fluid Romo1 as a potential diagnostic marker for lung cancer-associated malignant effusion.

Although pleural effusions in lung cancer patients are malignant in most cases, benign effusions can be developed at diagnosis or during clinical course. A recent large retrospective study of Porcel et al^[2] has demonstrated that benign causes of pleural effusions including obstructive pneumonia or heart failure are consisted of as much as 20% of all effusions occurred in patients with lung cancer. When a patient with lung cancer has pleural effusion, differentiation on whether the effusion is malignant or benign is critical as the former not only indicates advanced disease that requires palliative treatment instead of curative resection, but also is often associated with poor prognosis.^[2,17] Although cytological examination is simple and widely used method to diagnose malignant effusion, repeated thoracentesis or more invasive procedures including needle pleural biopsy or thoracostomy are often required due to its low

sensitivity. To avoid such invasive procedures, surrogate markers have long been investigated. However, most markers have failed to show their clinical utility.^[8–10] Thus, it is clinically meaningful to search novel sensitive markers for malignant effusion. Based on our previous finding showing that serum Romo1 level in lung cancer is significantly increased compared with that in benign diseases, we hypothesized that Romo1 levels were also increased in lung cancer-related malignant effusion compared with that in benign effusions. In the present study, we verified our hypothesis, indicating that pleural fluid Romo1 can be used not only to differentiate lung cancer patients from ones with benign diseases but also to determine whether the accompanying effusion is malignant effusion. This could be one of the advantages of checking pleural fluid Romo1 level in lung cancer patients with pleural effusion in clinical practice.

Romo1 is a novel protein firstly discovered in 2006 from head and neck cancer tissue which got resistance to chemotherapy.^[11] It is a membrane protein which is located in mitochondria where it controls mitochondrial ROS production.^[11] Inhibition of Romo1 with small inhibitory RNA has resulted in growth inhibition of both normal and cancer cells, suggesting that Romo1-derived ROS production is essential for cell proliferation.^[12] Recently, we have reported that serum Romo1 is significantly increased in lung cancer patients and can differentiate lung cancer patients from cancer-free population.^[15] In the present study, Romo1 was detectable in pleural effusion and its level was increased in lung cancer-associated effusion compared with that in benign pleural effusions. The exact mechanism by which Romo1 levels are increased in pleural effusion in lung cancer patients remains unclear. Malignant effusion indicates anatomical expansion of tumor or metastasis of the tumor cells into pleural membranes. Based on published data, Romo1 is a protein that exists in the mitochondrial outer membrane and does not appear to be a secretory protein.^[11] Thus, passive release of this protein from the cytoplasm into the pleural space by apoptosis or necrosis of cancer cells can result in high level of Romo1 in cell-free supernatant of lung cancer-related malignant pleural effusion. Decreased lymphatic drainage caused by the obstruction of lymphatics by malignant cells could be another possible mechanism, as suggested previously.^[18]

Our data showed that Romo1 level in pleural effusion was not different according to tumor histology, which is consistent with previous reports where Romo1 level was measured in serum and tissues.^[15] Although the exact role of Romo1 in the development of tumor is not fully understood, Romo1-induced ROS production might be a common phenomenon in lung cancers regardless of tumor histology as demonstrated in a previous study

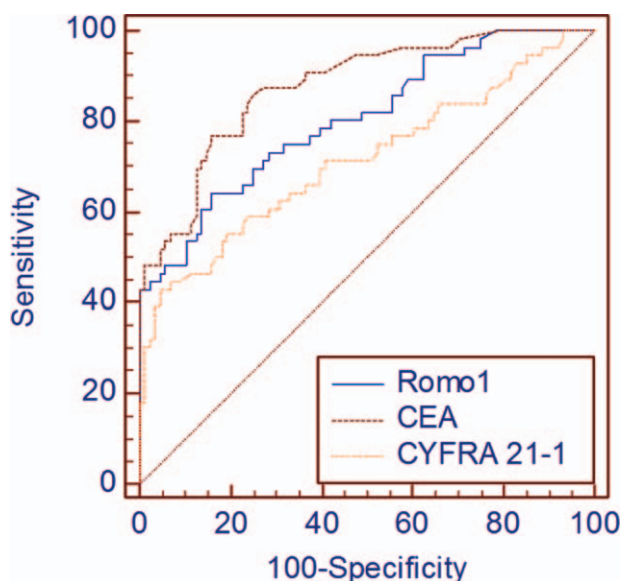


Figure 3. Comparison of diagnostic performance among Romo1, CEA, and CYFRA 21-1. Their area under the curve values were 0.837, 0.884, and 0.714, respectively. CEA = carcinoembryonic antigen, CYFRA 21-1 = cytokeratin 19 fragments, Romo1 = reactive oxygen species modulator 1.

using lung cancer cell lines.^[11] Moreover, the overexpression of Romo1 in a variety of cancer cells may suggest the potential diagnostic usefulness of Romo1 in other malignancies other than lung cancer.

Although many studies have investigated the diagnostic utilities of markers for malignant effusion, their diagnostic values have not been established. CEA is a glycoprotein component of glycocalyx of the endothermic epithelium and is present at a high degree in a wide variety of tumors.^[18] CYFRA 21-1 is the soluble fragments of cytokeratin 19 and is expressed in all histology types of lung cancer, especially squamous cell carcinoma.^[19] For the diagnosis of malignant effusion, CEA has been reported to have a sensitivity from 29% to 82% and a specificity ranging from 77% to 93% with various cutoff values.^[8,9] For CYFRA 21-1, its sensitivity varies from 22% to 91% with specificity from 80% to 97%.^[19,20] Some studies have suggested that CEA is better than CYFRA 21-1 for the diagnosis of lung cancer-related malignant effusion.^[8,18] However, a meta-analysis has revealed that there is no significant difference in performance between these 2 markers.^[10] In this study, CEA was the best single marker among the 3 markers while Romo1 was superior to CYFRA 21-1. In addition, concurrent use of CEA and Romo1 showed better diagnostic performance than did CEA alone, while the combination of CEA and CYFRA 21-1 did not. Moreover, the combination of CEA and Romo1 showed the best performance among 4 combinations. These results suggested that Romo1 may be useful not only on its own but also in combination with other markers.

This study has several limitations. First, the sample size was relatively small and large-scale studies are warranted to confirm our findings. Second, we did not collect paired serum samples. Simultaneous measurement of serum and pleural fluid Romo1 levels could enable us to find the association between Romo1 levels in the 2 types of body fluid, and would provide more information about which is more sensitive or reliable marker in determining pleural fluid etiology. However, based on a previous study showing that serum Romo1 expression was correlated with tissue Romo1 expression,^[15] we could cautiously estimate that Romo1 level in pleural effusion could be related to that in serum. Third, we did not include malignant effusion of other types of tumor. It is because the purpose of this study was to elucidate the clinical significance of pleural fluid Romo1 in lung cancer, and we thought that our data provide fundamentals for the future studies investigating the potential usefulness of this protein in other malignancies. Fourth, although we demonstrated the diagnostic value of Romo1, we did not evaluate its possible association with prognosis simultaneously. However, we have recently demonstrated that tissue Romo1 expression was related to both poor response and prognosis in lung cancer patients who received platinum-based chemotherapy.^[21]

In conclusion, our data showed that Romo1 was overexpressed in malignant effusion of lung cancer patients compared with that in benign pleural effusions. Although, further large-scale studies are required to verify those results, the present findings suggested that pleural fluid Romo1 could be a potential diagnostic marker for lung cancer-associated malignant effusion. In addition, our results provided a basis for future investigations

for the clinical implication of this protein in other body fluids from various malignancies.

References

- [1] Morgensztern D, Waqar S, Subramanian J, et al. Prognostic impact of malignant pleural effusion at presentation in patients with metastatic non-small-cell lung cancer. *J Thorac Oncol* 2012;7:1485–9.
- [2] Porcel JM, Gasol A, Bielsa S, et al. Clinical features and survival of lung cancer patients with pleural effusions. *Respirology* 2015;20:654–9.
- [3] William WJr, Lin HY, Lee JJ, et al. Revisiting stage IIIB and IV non-small cell lung cancer: analysis of the surveillance, epidemiology, and end results data. *Chest* 2009;136:701–9.
- [4] Hirsch A, Ruffie P, Nebut M, et al. Pleural effusion: laboratory tests in 300 cases. *Thorax* 1979;34:106–12.
- [5] Sriram KB, Relan V, Clarke BE, et al. Diagnostic molecular biomarkers for malignant pleural effusions. *Future Oncol* 2011;7:737–52.
- [6] Heffner JE. Diagnosis and management of malignant pleural effusions. *Respirology* 2008;13:5–20.
- [7] Agalioti T, Giannou AD, Stathopoulos GT. Pleural involvement in lung cancer. *J Thorac Dis* 2015;7:1021–30.
- [8] Lee JH, Chang JH. Diagnostic utility of serum and pleural fluid carcinoembryonic antigen, neuron-specific enolase, and cytokeratin 19 fragments in patients with effusions from primary lung cancer. *Chest* 2005;128:2298–303.
- [9] Porcel JM, Vives M, Esquerda A, et al. Use of a panel of tumor markers (carcinoembryonic antigen, cancer antigen 125, carbohydrate antigen 15-3, and cytokeratin 19 fragments) in pleural fluid for the differential diagnosis of benign and malignant effusions. *Chest* 2004;126:1757–63.
- [10] Gu P, Huang G, Chen Y, et al. Diagnostic utility of pleural fluid carcinoembryonic antigen and CYFRA 21-1 in patients with pleural effusion: a systematic review and meta-analysis. *J Clin Lab Anal* 2007;21:398–405.
- [11] Chung YM, Kim JS, Yoo YD. A novel protein, Romo1, induces ROS production in the mitochondria. *Biochem Biophys Res Commun* 2006;347:649–55.
- [12] Na AR, Chung YM, Lee SB, et al. A critical role for Romo1-derived ROS in cell proliferation. *Biochem Biophys Res Commun* 2008;369:672–8.
- [13] Hwang IT, Chung YM, Kim JJ, et al. Drug resistance to 5-FU linked to reactive oxygen species modulator 1. *Biochem Biophys Res Commun* 2007;359:304–10.
- [14] Chung JS, Park S, Park SH, et al. Overexpression of Romo1 promotes production of reactive oxygen species and invasiveness of hepatic tumor cells. *Gastroenterology* 2012;143:1084.e7–94.e7.
- [15] Lee SH, Lee JS, Lee EJ, et al. Serum reactive oxygen species modulator 1 (Romo1) as a potential diagnostic biomarker for non-small cell lung cancer. *Lung Cancer* 2014;85:175–81.
- [16] Lee SH, Min JW, Lee JS, et al. Reactive oxygen species modulator 1 (Romo1) overexpression is an independent predictor of poor survival in NSCLC patients who undergo surgical resection. *Lung Cancer* 2015; 87:45–52.
- [17] Sugiura S, Ando Y, Minami H, et al. Prognostic value of pleural effusion in patients with non-small cell lung cancer. *Clin Cancer Res* 1997;3:47–50.
- [18] Ferrer J, Villarino MA, Encabo G, et al. Diagnostic utility of CYFRA 21-1, carcinoembryonic antigen, CA 125, neuron specific enolase, and squamous cell antigen level determinations in the serum and pleural fluid of patients with pleural effusions. *Cancer* 1999;86:1488–95.
- [19] Lai RS, Chen CC, Lee PC, et al. Evaluation of cytokeratin 19 fragment (CYFRA 21-1) as a tumor marker in malignant pleural effusion. *Jpn J Clin Oncol* 1999;29:421–4.
- [20] Alatas F, Alatas O, Metintas M, et al. Diagnostic value of CEA, CA 15-3, CA 19-9, CYFRA 21-1, NSE and TSA assay in pleural effusions. *Lung Cancer* 2001;31:9–16.
- [21] Lee SH, Choi SI, Lee JS, et al. Reactive oxygen species modulator 1 (Romo1) predicts poor outcomes in advanced non-small cell lung cancer patients treated with platinum-based chemotherapy. *Cancer Res Treat* 2017;49:141–9.