

Imaging Findings in Two Cases of Fluoroquinolone-Induced Achilles Tendinopathy

Gregory M. Sterne, Michael L. Richardson, Bill H. Warren

Tendonitis and tendon rupture are rare but recognized complications of fluoroquinolone therapy. Most reports of this problem have appeared in the rheumatology and pharmacology literature, and this topic has received little attention in the radiologic literature. We report two cases of fluoroquinolone-induced tendinopathy and describe their magnetic resonance (MR) and sonographic findings. Although Achilles tendinopathy is generally the result of repetitive injury, it is useful to keep other causes in mind. MR or sonographic findings of Achilles tendinopathy in a patient without history of antecedent trauma should prompt the radiologist to consider fluoroquinolone treatment as a possible causative agent.

Case Report 1

Patient A is a 56 year old active and otherwise healthy female who presented to her primary care provider with a five day history of worsening fever, sore throat, cough, and rhinorrhea. Medications included atenolol, hydrochlorothiazide, potassium, ranitidine, hormone replacement, and vitamins. The patient had no known drug allergies. The patient was prescribed a 10 day course of 500 mg of oral levofloxacin per day and a beta-agonist inhaler.

On the last day of her 10 day antibiotic course, the patient presented to her physician describing a fairly abrupt onset of bilateral Achilles tendon pain, which increased with plantar flexion and direct palpation. There was no history of trauma or recent increase in activity. Strength and range of motion about the ankle were normal. A diagnosis of bilateral Achilles tendonitis was made and the patient prescribed a 10 day course of the anti-inflammatory agent Naprosyn. The patient was slow to improve, prompt-

ing magnetic resonance imaging (MRI) of both lower extremities.

T1-weighted MRI (Figure 1) obtained 18 days after onset of symptoms demonstrated small foci of increased signal in the medial-posterior margins of both tendons (R > L), suggestive of small partial width tears.

Short tau inversion recovery (STIR) images (Figure 2) demonstrated moderate fusiform dilatation of both Achilles tendons, most pronounced 6 cm above their calcaneal insertions. In addition, there was mild diffusely increased signal within the retrocalcaneal soft tissues, consistent with edema.

Minimal magnetic susceptibility artifact (not visible on the images above) was noted adjacent to sites of tendon injury, likely representing small foci of associated hemorrhage. Other visualized tendons were within normal limits. No bony abnormality was identified, and vascular structures were normal in appearance.

Based on clinical history, physical exam, and MRI findings, a diagnosis of fluoroquinolone-induced tendinopathy was made. Continuing on Naprosyn, the patient's symptoms gradually abated, reaching near complete resolution by eleven months. No further imaging was obtained.

Case Report 2

Patient B is a 38 year old female who presented to the emergency room with a three week history of weight loss, increased sputum production, and shortness of breath. At the time of presentation, the patient was ten years status post bilateral lung transplant for cystic fibrosis and suffered from recurrent pulmonary infections. Her medication list was long and included immunosuppressants SK506, Azathioprine, and low dose prednisone (5mg qd). She had

Citation: Sterne GM, Richardson ML, Warren BH. Imaging findings in two cases of fluoroquinolone-induced achilles tendinopathy. *Radiology Case Reports*. [Online] 2006;1:32.

Copyright: © Gregory M. Sterne. This is an open-access article distributed under the terms of the Creative Commons Attribution-NonCommercial-NoDerivs 2.5 License, which permits reproduction and distribution, provided the original work is properly cited. Commercial use and derivative works are not permitted.

Abbreviations: MR, magnetic resonance, MRI, magnetic resonance imaging, STIR, short tau inversion recovery

Gregory M. Sterne, Michael L. Richardson (E-mail: mrich@u.washington.edu), and Bill H. Warren are from the University of Washington, Department of Radiology, Seattle, WA, United States of America.

DOI: 10.2484/rcr.v1i3.32

Imaging Findings in Two Cases of Fluoroquinolone-Induced Achilles Tendinopathy

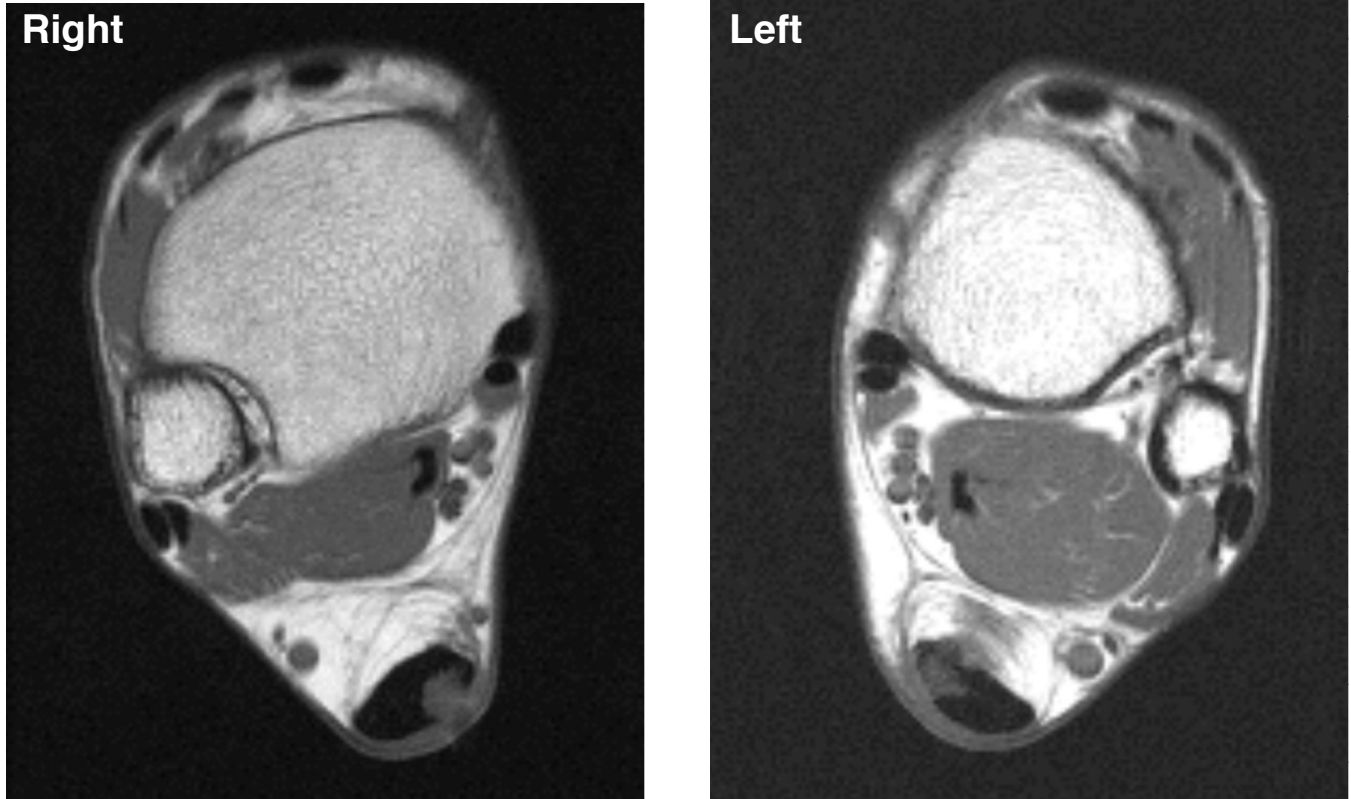


Figure 1. T1-weighted MRI obtained 18 days after onset of symptoms demonstrates small foci of increased signal in the medial-posterior margins of both tendons (R > L), suggestive of small partial width tears.

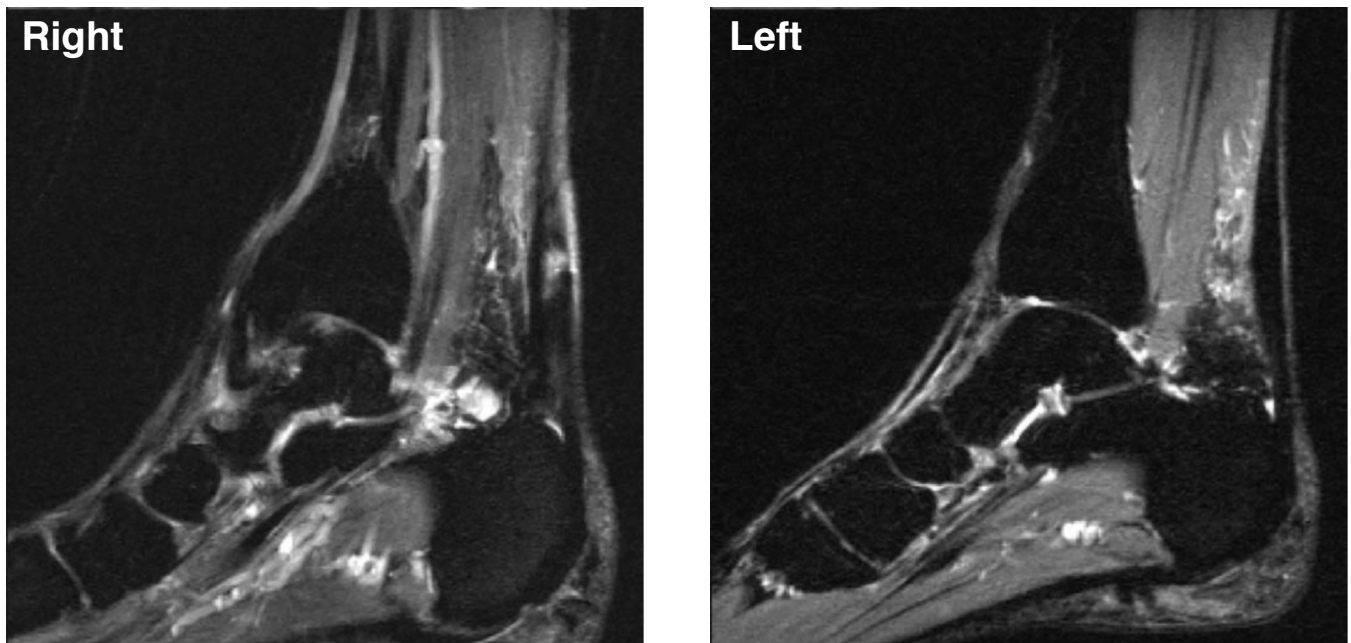


Figure 2. Short tau inversion recovery (STIR) images obtained 18 days after onset of symptoms demonstrates moderate fusiform dilatation of both Achilles tendons, most pronounced 6 cm above their calcaneal insertions. A focal area of increased signal is noted in the right Achilles tendon.

Imaging Findings in Two Cases of Fluoroquinolone-Induced Achilles Tendinopathy

no known drug allergies. Chest x-ray showed no focal infiltrates. She was diagnosed with bronchitis and treated with albuterol nebulizers and a fourteen day course of levofloxacin. Approximately two weeks after her final dose, she reported the onset of bilateral posterior ankle pain which inhibited her ambulation.

Ultrasound performed six weeks after onset of symptoms (Figure 3) demonstrated diffuse thickening of the Achilles tendons bilaterally, without evidence of rupture. Measurements were 8.1 mm (AP) x 12.3 mm (transverse) left, and 8.8 mm (AP) x 16.8 mm (transverse) right, with normal approximately 5.6 +/- 1mm AP and 9.0 +/- 1mm transverse. In addition, focal thickening was noted slightly proximal to both calcaneal insertions (Figure 4).

Symptoms gradually improved over the next several months, although the patient's overall medical state declined. She expired from sepsis approximately one year after the ultrasound exam shown below. No further imaging was obtained.

Discussion

Levofloxacin is a broad spectrum antibiotic and a member of the synthetic fluoroquinolone family, which includes ciprofloxacin, pefloxacin, norfloxacin and many others (1). These antibiotics are designed to inhibit DNA gyrase and topoisomerase IV in bacteria (2). DNA gyrase is a necessary enzyme for the replication, transcription, and repair of bacterial DNA, while topoisomerase IV is thought to play a role in partitioning chromosomal DNA during bacterial cell division.

The fluoroquinolones are frequently prescribed for a variety of infections -- most commonly of the urinary and respiratory tract. A recent study of fluoroquinolone usage in U.S. hospitals found a mean rate of 150 daily doses /

1000 patient days in hospital (3). Side effects of these antibiotics are considered infrequent, and include GI irritation, skin rash, central and peripheral neurologic disorders, and elevation of serum transaminases. Rarely, a patient's course may be complicated by tendinopathy, gait disturbance, or hematologic abnormalities.

Fluoroquinolone-induced tendinopathy was first reported in 1983 by Bailey et al. (4). By 1994, 25 fluoroquinolone-associated tendon ruptures had been reported to the FDA, with 22 occurring outside the U.S. (5). In 2003, Khaliq et al reviewed 98 case reports of fluoroquinolone-associated tendinopathy. Although pefloxacin and ciprofloxacin are most frequently implicated, tendon injury has been reported with most fluoroquinolones (6). The incidence of fluoroquinolone-induced tendon injury in an otherwise healthy population is not well established, but reports suggest that it is low, ranging from 0.14 % to 0.4 % (6). The relative risk for a patient developing Achilles tendinitis following fluoroquinolone therapy is about 3.7 times the risk of a patient not using fluoroquinolones (7).

The risk of spontaneous tendon rupture in patients taking fluoroquinolones appears to be increased by steroid therapy, hypercholesterolemia, gout, rheumatoid arthritis, advanced age, renal dysfunction, long-term dialysis, and solid organ transplantation (6, 8-10). Of note, two of these risk factors -- chronic steroid use and solid organ transplant -- were present in our patient B.

The Achilles tendon is most commonly affected, with involvement of quadriceps, peroneus brevis, extensor pollicis longus, long head of biceps, rotator cuff tendons and other tendons also reported (6, 11). Some authors have suggested an increased prevalence in males (6, 12). Fluoroquinolone tendinopathy often has an abrupt and spontaneous onset, is frequently bilateral, and is accompanied by

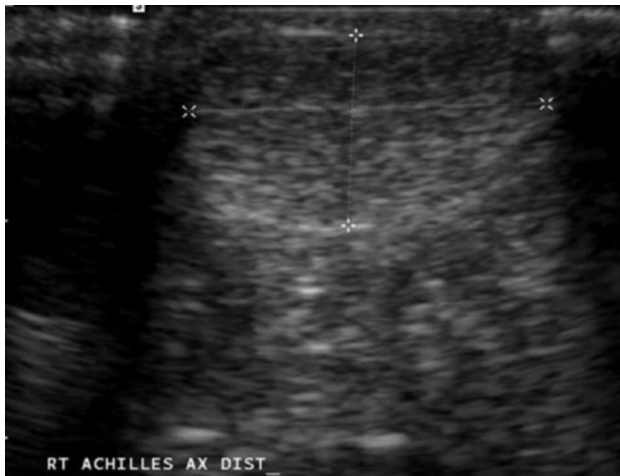

Figure 3. Transverse sonographic image of the right distal Achilles tendon, showing diffuse thickening (cursors).

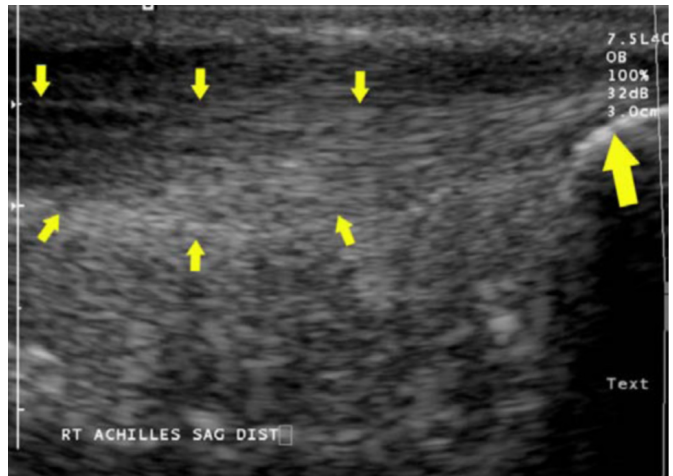


Figure 4. Sagittal sonographic view of right distal Achilles tendon, showing focal thickening (small arrows) slightly proximal to the calcaneal insertion (large arrow).

Imaging Findings in Two Cases of Fluoroquinolone-Induced Achilles Tendinopathy

tendon swelling (12). The latency period between the start of treatment and the appearance of the first symptoms ranges from as little as two hours to 510 days, with a median of 6 days (6, 12, 13).

The relationship between fluoroquinolone dose and the prevalence of tendinopathy remains unclear. Most cases arise despite adherence to recommended dosages. One study noted Achilles tendon rupture occurring at a lower total dosage than tendonitis, suggesting an idiosyncratic response to the drug in some patients (8).

When fluoroquinolone tendinopathy is diagnosed promptly, slow, gradual healing usually follows drug discontinuation (9). Recovery times of three weeks to two months have been reported following rest and immobilization, with a small percentage requiring surgery (6, 9).

Diagnosis of tendinopathy is largely clinical, following onset of pain in the affected tendon. However, MRI and sonography can provide improved localization and characterization of a lesion. While sonography is less expensive and more widely available, MRI provides more easily reproducible imaging. Areas of mucoid degeneration, as were seen in our patient A, appear as transverse or longitudinal foci of high signal intensity on T1- and T2-weighted MR images (13, 14). MRI may be useful in distinguishing between tendinitis and partial tendon rupture (15). MRI may also demonstrate additional findings, such as a thickened paratenon, peritendinous fluid, or edema of peritendinous fat (13). However, these findings are nonspecific, and can appear in tendinopathies of other etiologies. Sonography may demonstrate tendon thickening (similar to that in our patient B) and hypoechoic areas within the tendon (13). Color Doppler sonography may be useful in distinguishing hematoma from acutely torn tendon ends.

In the few cases of fluoroquinolone-related tendinopathy where tissue pathology has been obtained, non-specific findings of necrosis, neovascularity, interstitial edema and cystic change have been reported (6). The pathophysiology of fluoroquinolone-related tendinopathy is not well understood. Many researchers believe the mechanism of fluoroquinolone-related tendon injury to be ischemic in nature, aggravated by local mechanical stresses (6). It has also been suggested that fluoroquinolones alter not only proteoglycan synthesis, but also cellular function, perhaps at the mitochondrial level (16, 17).

Conclusion

Although Achilles tendinopathy is generally the result of repetitive injury, it is useful to keep other causes in mind. MR or sonographic findings of Achilles tendinopathy in a patient without history of antecedent trauma should prompt the radiologist to consider fluoroquinolone treatment as a possible causative agent.

References

1. van der Linden PD, Nab HW, Simonian S, Stricker BH, Leufkens HG, Herings RM. Fluoroquinolone use and

the change in incidence of tendon ruptures in the Netherlands. *Pharm World Sci* 2001; 23:89-92. [[PubMed](#)]

2. Drlica K. Mechanism of fluoroquinolone action. *Curr Opin Microbiol* 1999; 2:504-508. [[PubMed](#)]
3. MacDougall C, Harpe SE, Powell JP, Johnson CK, Edmond MB, Polk RE. *Pseudomonas aeruginosa*, staphylococcus aureus, and fluoroquinolone use. *Emerg Infect Dis* 2005; 11:1197-1204. [[PubMed](#)]
4. Bailey RR, Kirk JA, Peddie BA. Norfloxacin-induced rheumatic disease. *N Z Med J* 1983; 96:590. [[PubMed](#)]
5. Lewis JR, Gums JG, Dickensheets DL. Levofloxacin-induced bilateral Achilles tendonitis. *Ann Pharmacother* 1999; 33:792-795. [[PubMed](#)]
6. Khaliq Y, Zhanel GG. Fluoroquinolone-associated tendinopathy: a critical review of the literature. *Clin Infect Dis* 2003; 36:1404-1410. [[PubMed](#)]
7. van der Linden PD, van de Lei J, Nab HW, Knol A, Stricker BH. Achilles tendinitis associated with fluoroquinolones. *Br J Clin Pharmacol* 1999; 48:433-437. [[PubMed](#)]
8. Chhajed PN, Plit ML, Hopkins PM, Malouf MA, Glanville AR. Achilles tendon disease in lung transplant recipients: association with ciprofloxacin. *Eur Respir J* 2002; 19:469-471. [[PubMed](#)]
9. Zabraniecki L, Negrier I, Vergne P, et al. Fluoroquinolone induced tendinopathy: report of 6 cases. *J Rheumatol* 1996; 23:516-520. [[PubMed](#)]
10. van der Linden PD, Sturkenboom MC, Herings RM, Leufkens HG, Stricker BH. Fluoroquinolones and risk of Achilles tendon disorders: case-control study. *Bmj* 2002; 324:1306-1307. [[PubMed](#)]
11. Casparian JM, Luchi M, Moffat RE, Hinthorn D. Quinolones and tendon ruptures. *South Med J* 2000; 93:488-491. [[PubMed](#)]
12. van der Linden PD, van Puijenbroek EP, Feenstra J, et al. Tendon disorders attributed to fluoroquinolones: a study on 42 spontaneous reports in the period 1988 to 1998. *Arthritis Rheum* 2001; 45:235-239. [[PubMed](#)]
13. Yu C, Giuffre B. Achilles tendinopathy after treatment with fluoroquinolone. *Australas Radiol* 2005; 49:407-410. [[PubMed](#)]
14. Gillet P, Blum A, Hestin D, et al. Magnetic resonance imaging may be an asset to diagnose and classify fluoroquinolone-associated Achilles tendinitis. *Fundam Clin Pharmacol* 1995; 9:52-56. [[PubMed](#)]

Imaging Findings in Two Cases of Fluoroquinolone-Induced Achilles Tendinopathy

15. McGarvey WC, Singh D, Trevino SG. Partial Achilles tendon ruptures associated with fluoroquinolone antibiotics: a case report and literature review. *Foot Ankle Int* 1996; 17:496-498. [[PubMed](#)]
16. Bernard-Beaubois K, Hecquet C, Hayem G, Rat P, Adolphe M. In vitro study of cytotoxicity of quinolones on rabbit tenocytes. *Cell Biol Toxicol* 1998; 14:283-292. [[PubMed](#)]
17. Simonin MA, Gegout-Pottie P, Minn A, Gillet P, Netter P, Terlain B. Pefloxacin-induced achilles tendon toxicity in rodents: biochemical changes in proteoglycan synthesis and oxidative damage to collagen. *Antimicrob Agents Chemother* 2000; 44:867-872. [[PubMed](#)]