

Ceftriaxone-induced Acute Cholecystitis

Fernanda Marta Gomes*, Filipa Costeira, Carolina Leite, Pedro Silva

Department of Radiology, Hospital de Braga, Braga, Portugal

Abstract

Ceftriaxone has been increasingly used in pediatric population, due to its bacteriological and pharmacokinetic features. Association between ceftriaxone and biliary sludge/pseudolithiasis formation has been documented in the literature. More rarely, biliary symptoms and cholecystitis during ceftriaxone therapy have been reported. We present a case of acute cholecystitis related to ceftriaxone administration and its management.

Keywords: Ceftriaxone, cholecystitis, cholecystolithiasis, contraindications, drug-induced

INTRODUCTION

Knowledge of potential adverse drug reactions is vital for an early diagnosis and management, avoiding unnecessary risks for the patient. Growing use and accessibility of imaging media have allowed early recognition and deeper understanding of some drug-induced symptoms and can help identify cases that may require treatment adjustment. Ceftriaxone is a third-generation parenteral cephalosporin with a broad spectrum of activity and excellent pharmacokinetic profile, penetrating in most body fluids. Development of gallbladder sludge and pseudolithiasis is a rarely observed adverse reaction (<0.1%) that, in most reported cases, is transient, disappearing spontaneously after discontinuation of therapy. There are few records in the literature of ceftriaxone-induced cholecystitis and its treatment.

CASE REPORT

A previously healthy 6-year-old girl was admitted to the pediatric assessment unit with a history of sudden onset of fever (maximum of 40°C), prostration, headache, and one episode of vomiting. Laboratory tests showed at admission normal hemoglobin levels (117 g/L, normal range 115–155), leukocytosis white blood cell (WBC) ($19.3 \times 10^9/L$, with 86% neutrophils and 10% lymphocytes, normal range 4.0–13.5), normal platelet count ($256 \times 10^9/L$, normal range 180–400), and a raised C-reactive protein of 129 mg/L (normal range <3). Electrolytes and renal and liver function tests were normal. Urinalysis showed 3–4 WBC per high-power field, no urine protein, and no

red blood cell. A urine sample was sent for culture. Ultrasound was performed and no abnormal abdominopelvic sonographic findings were detected [Figure 1]. Empirical treatment with ceftriaxone (2 g [77 mg/kg/day]) for a suspected bacteremia of an unknown origin was introduced, with no clinical improvement. Approximately 17 h after admission, the patient reported abdominal pain in the upper quadrants, with no signal of peritoneal irritation at physical examination. Due to lack of improvement of patient condition, a computed tomography scan was performed, revealing gallstones, with no signals of gallbladder inflammation [Figure 2]. Repeated laboratory studies were significant for leukocytosis (WBC) ($15.5 \times 10^9/L$), low platelet count (platelet count ($171 \times 10^9/L$), and raised C-reactive protein of 230 mg/L. Due to abdominal pain exacerbation, we repeated an ultrasound that showed cholecystolithiasis and a discrete thickening of the gallbladder wall with a rim of fluid around its neck, consistent with acute inflammation [Figure 3a-c]. Sonographic Murphy sign was positive. Renal ultrasound was normal, with no signs of obstruction or lithiasis. The urine culture revealed the presence of *Enterococcus faecalis*. Cerebrospinal fluid analysis was normal. The diagnosis of acute cholecystitis associated with ceftriaxone treatment was assumed, and the drug was withdrawn due to the reversible nature of this condition if the treatment is discontinued. Appropriate antibiotic treatment for a pyelonephritis was given according to the findings on urine

Address for correspondence: Dr. Fernanda Marta Gomes, Department of Radiology, Hospital de Braga, Braga, Portugal. E-mail: fmgomes2@gmail.com

Received: 06-09-2020 Revised: 03-12-2020 Accepted: 21-12-2020 Available Online: 14-05-2021

Access this article online

Quick Response Code:



Website:
www.jmuonline.org

DOI:
10.4103/JMU.JMU_132_20

This is an open access journal, and articles are distributed under the terms of the Creative Commons Attribution-NonCommercial-ShareAlike 4.0 License, which allows others to remix, tweak, and build upon the work non-commercially, as long as appropriate credit is given and the new creations are licensed under the identical terms.

For reprints contact: WKHLRPMedknow_reprints@wolterskluwer.com

How to cite this article: Gomes FM, Costeira F, Leite C, Silva P. Ceftriaxone-induced acute cholecystitis. J Med Ultrasound 2021;29:288-90.

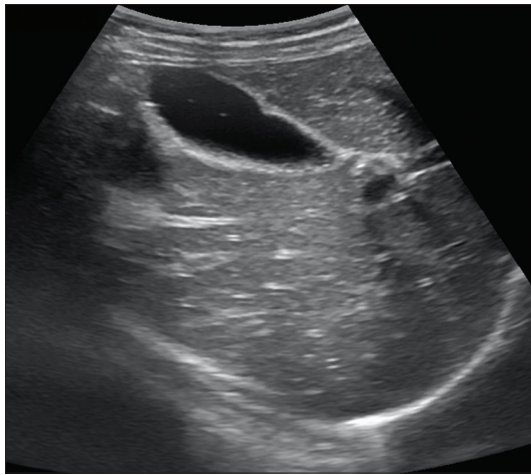


Figure 1: Ultrasonography showing no significant abnormalities, including no evidence of gallbladder sludge or pseudolithiasis

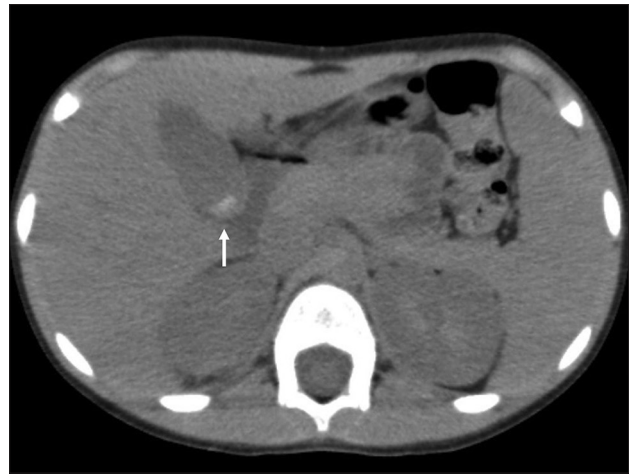

Figure 2: Axial noncontrast-enhanced computed tomography image showing gallstones within the gallbladder (arrow), with no signs of inflammation

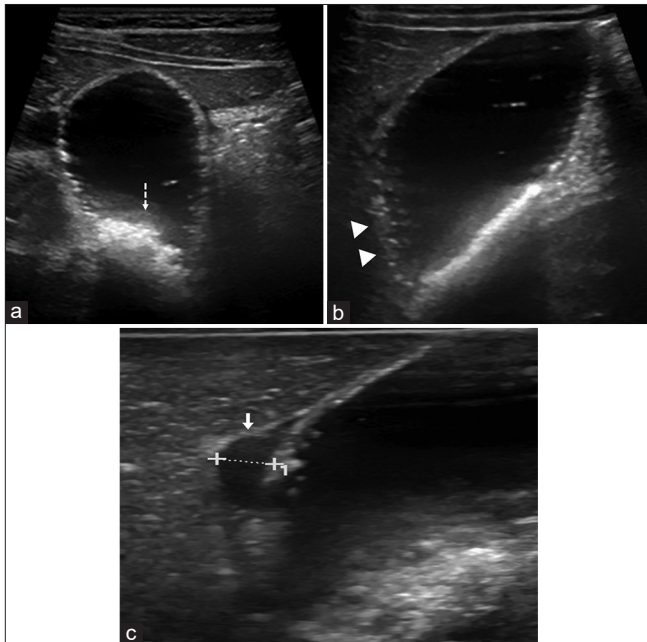


Figure 3: (a) Ultrasound image showing biliary sludge and pseudolithiasis formation (dashed arrow). (b and c) In addition, ultrasound images revealed (b) thickening of the gallbladder wall (arrowheads), (c) pericholecystic fluid (arrow) and probe tenderness, consistent with acute cholecystitis

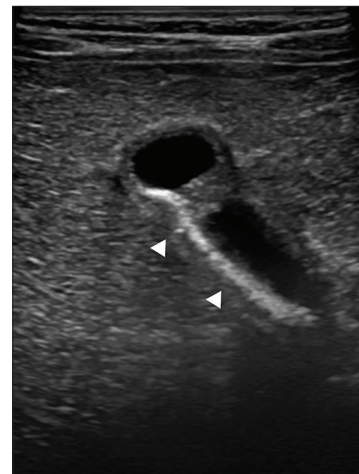

Figure 4: Ultrasound revealed a residual amount of biliary sludge (arrowheads), considerably reduced when compared to previous examination

culture and sensitivity report. A significant clinical improvement was noticed after changing the antibiotic treatment, and the patient's symptoms resolved after 3 days of conservative treatments. One week later, the patient underwent ultrasound reevaluation, which revealed resolution of local inflammatory features and almost complete disappearance of biliary sludge and gallstones [Figure 4].

DISCUSSION

Adverse drug reactions represent a significant problem in medical practice, which can result in prolonged hospitalization

and high morbidity and contribute to a fatal outcome. Ceftriaxone is a third-generation parenteral cephalosporin that is excreted both via kidney (60%) and into bile (40%).^[1] Due to its biliary excretion, ceftriaxone can reach concentrations in bile 20–150 times higher than in serum and, after binding with calcium ions, can form insoluble precipitates, leading to biliary pseudolithiasis. The term pseudolithiasis has been introduced for the first time by Shaad *et al.*, referring to transient and reversible appearance of this condition after discontinuation of therapy.^[2,3] Biliary pseudolithiasis and sludge have been reported in 15%–46% of patients treated with ceftriaxone.^[4] Biliary pseudolithiasis represents a drug-induced complication associated with ceftriaxone use, which may mimic cholelithiasis.

Ceftriaxone use and the onset of biliary pseudolithiasis have been referred in the literature, and it is thought that is dose-dependent and more common in children who, as a result

of weight-dependent dosing, receive proportionately higher doses than adults.^[5,6] In addition, it is influenced by the form of administration (short bolus infusion versus administration in 30 min) and precipitated by the restriction of oral intake and fasting, which cause gallbladder dysfunction and biliary stasis.^[5,7]

This appearance should not be misinterpreted as gallstones, attending that it can result in unnecessary cholecystectomies in pediatric age.^[3] Pseudolithiasis tends to develop, in average, 6 days after the beginning of ceftriaxone. However, a study reported the detection of pseudolithiasis within 2 days after treatment beginning.^[4] Complete resolution of pseudolithiasis is expected after a mean of 15 days (range 2–63 days) after ceftriaxone withdrawal.^[7] The risk of developing ceftriaxone-associated biliary sludge and pseudolithiasis depends on treatment's dose and duration.^[2,8] Studies have shown that, in most cases, pseudolithiasis and biliary sludge are asymptomatic and do not require treatment discontinuation.^[1] Nevertheless, there are reports of symptomatic cases and patients who have undergone cholecystectomy.^[3,7] When clinically apparent, treatment interruption is advised.^[9] Symptomatic pseudolithiasis has been reported more frequently in pediatric patients.^[1,4] Other drugs have been related with gallstone disease, such as furosemide, clofibrate, octreotide, ceftriaxone, cyclosporine, erythromycin, and ampicillin.^[1] Hematologic disorders such as eosinophilia, thrombocytosis, leukopenia, thrombocytopenia, and neutropenia are common side effects of use of ceftriaxone.^[10]

This case report highlights a common drug-induced complication at abdominal imaging, which can mimic real cholelithiasis. Awareness about this possibility might prevent unnecessary procedures, and clinical presentation, markers of cholestasis, and abdominal imaging play a vital role in ceftriaxone-associated biliary pseudocholelithiasis diagnosis. Biliary pseudolithiasis and reversible cholelithiasis are now used to denote the reversibility of this condition upon discontinuation of ceftriaxone.

Declaration of patient consent

The authors certify that they have obtained appropriate patient's guardian consent form. In the form, the guardian has given the consent for the child's images and other clinical information to be reported in the journal. The guardian understands that the child's name and initial will not be published and due efforts will be made to conceal the identity, but anonymity cannot be guaranteed.

Financial support and sponsorship

Nil.

Conflicts of interest

There are no conflicts of interest.

REFERENCES

- Ozturk A, Kaya M, Zeyrek D, Ozturk E, Kat N, Ziylan SZ. Ultrasonographic findings in ceftriaxone: Associated biliary sludge and pseudolithiasis in children. *Acta Radiol* 2005;46:112-6.
- Biner B, Öner N, Çeltik C, Bostancıoğlu M, Tunçbilek N, Güzel A, *et al.* Ceftriaxone-associated biliary pseudolithiasis in children. *J Clin Ultrasound* 2006;34:217-22.
- Blais C, Duperval R. Biliary pseudolithiasis in a child associated with 2 days of ceftriaxone therapy. *Pediatr Radiol* 1994;24:218-9.
- Becker CD, Fischer RA. Acute cholecystitis caused by ceftriaxone stones in an adult. *Case Rep Med* 2009;2009:132452.
- Oggiano AM, Clemente MG, Cuzzolin L. Pharmacological treatment of ceftriaxone-related cholelithiasis in children: Is it worthwhile? *J Pediatr Neonatal Individ Med* 2019;8:e080108.
- Du Y, Wang Y, Xie J, Ruanxin M, Min G, Jing X, *et al.* Ceftriaxone associated biliary pseudolithiasis in a child: A case report and review of the literature. *Int J Clin Exp Med* 2018;11:7502-9.
- Schaad UB, Wedgwood-Krucko J, Tschaepeler H. Reversible ceftriaxone-associated biliary pseudolithiasis in children. *Lancet* 1988;2:1411-3.
- Shiffman ML, Keith FB, Moore EW. Pathogenesis of ceftriaxone-associated biliary sludge. *In vitro* studies of calcium-ceftriaxone binding and solubility. *Gastroenterology* 1990;99:1772-8.
- Palanduz A, Yalçın I, Tonguç E, Güler N, Oneş U, Salman N, *et al.* Sonographic assessment of ceftriaxone-associated biliary pseudolithiasis in children. *J Clin Ultrasound* 2000;28:166-8.
- Jansen JW, Linneman TW, Tan X, Moenster RP. Comparison of adverse drug reactions between patients treated with ceftaroline or ceftriaxone: A single-center, matched cohort study. *Open Forum Infect Dis* 2019;6:ofz279.