

## Black Seed (*Nigella Sativa*) and its Constituent Thymoquinone as an Antidote or a Protective Agent Against Natural or Chemical Toxicities

Alireza Tavakkoli<sup>a</sup>, Ali Ahmadi<sup>a</sup>, Bibi Marjan Razavi<sup>b</sup> and Hossein Hosseinzadeh<sup>c\*</sup>

<sup>a</sup>Department of Pharmacodynamics and Toxicology, School of Pharmacy, Mashhad University of Medical Sciences, Mashhad, Iran. <sup>b</sup>Targeted Drug Delivery Research Center, Department of Pharmacodynamics and Toxicology, School of Pharmacy, Mashhad University of Medical Sciences, Mashhad, Iran. <sup>c</sup>Pharmaceutical Research Center, Department of Pharmacodynamics and Toxicology, School of Pharmacy, Mashhad University of Medical Sciences, Mashhad, Iran.

---

### Abstract

*Nigella sativa* (*N. sativa*), which belongs to the botanical family of Ranunculaceae, is a widely used medicinal plant all over the world. *N. sativa* seeds and oil have been used in the treatment of different diseases. Various studies on *N. sativa* have been carried out and a broad spectrum of its pharmacological actions have been established which include antioxidant, antidiabetic, anticancer, antitussive, immunomodulator, analgesic, antimicrobial, anti-inflammatory, spasmolytic, and bronchodilator. This is also indicated that the majority of the therapeutic effects of *N. sativa* are due to the presence of thymoquinone (TQ) that is the main bioactive constituent of the essential oil. According to several lines of evidence, the protective effects of this plant and its main constituent in different tissues including brain, heart, liver, kidney, and lung have been proved against some toxic agents either natural or chemical toxins in animal studies. In this review article, several *in-vitro* and animal studies in scientific databases which investigate the antidotal and protective effects of *N. sativa* and its main constituents against natural and chemical induced toxicities are introduced. Because human reports are rare, further studies are required to determine the efficacy of this plant as an antidote or protective agent in human intoxication.

**Keywords:** *Nigella sativa*; Thymoquinone; Antidote; Protective; Natural toxin; Chemical toxin.

---

### Introduction

*Nigella sativa*, which belongs to the botanical family of Ranunculaceae, commonly known as black seed. It grows in Eastern Europe, the Middle East, and Western Asia (1). *N. sativa* seeds and oil have been extensively used in treatment of different diseases throughout the world. *N. sativa* is included in the list of natural

drugs in different medicines including Tibb-e-Nabavi (The medicine of Prophet Mohammad), Unani Tebb, and Indian traditional medicine (2). In traditional remedy, *N. sativa* seeds are commonly used as a spice and carminative (1). In addition, several properties such as liver tonics, diuretics, digestive, anti-diarrheal, appetite stimulant, analgesics, and anti-bacterial have been attributed to this plant (1-3). *N. sativa* has been investigated for its biological effects and therapeutic potential and shown to have broad spectrum of activities including antidiabetic (4,5),

---

\* Corresponding author:

E-mail: hosseinzadehh@mums.ac.ir

anticancer (6), immunomodulator (7), analgesic (8), antimicrobial (9), anti-inflammatory (8), spasmolytic (10), bronchodilator (11), hepatoprotective (12, 13), renal protective (14-16), gastro-protective (17), and antioxidant (18) properties. *N. sativa* seed contains more than 30% fixed oil and 0.4 to 0.45% volatile oil (19). Thymoquinone (TQ) is an abundant component of black seed oil extract (20). TQ has a strong antioxidant potential due to its free radicals scavenging activity (18). There are many reports on its biological activities including analgesic, anti-inflammatory (8, 21), anti-tussive (22), anti-hypertensive (23), anti-diabetic (24), anti-bacterial (25), and anticancer (26). In addition, the protective effects of *N. sativa* and its main constituents in different tissues including brain (27-29), heart (30), liver (12), kidney (14), lung (31, 32), etc have been established against some toxic agents. In this review article, several *in-vitro* and animal studies in scientific databases which investigate the antidotal and protective effects of *N. sativa* and its main constituents against natural and chemical induced toxicities are introduced (Table 1, Figure 1). Because human reports are rare, further studies are required to determine the efficacy of this plant as an antidote or protective agent in human intoxication.

#### *Natural toxins*

According to documents, *N. sativa* and its main component (TQ) exhibit antidotal effects against some natural toxins including mycotoxins (33, 34), D-galactosamine (35), and lipopolysaccharides (LPS) (36). These effects might be due to their antioxidant (33), improvement in antioxidant defense system (37), improvement in disturbed biochemical injury markers (35), and antiapoptotic (38) effects.

#### *Mycotoxins*

##### *Aflatoxin B1 (AFB1)*

AFB1 is an aflatoxin produced by *Aspergillus flavus* and *A. parasiticus* (39). TQ showed a protective effect against AFB1-induced hepatotoxicity in mice by reduction of hepatic injury markers including AST (aspartate aminotransferase), ALT (alanine aminotransferase), and ALP (alkaline

phosphatase) and also via preventing necrosis and degradation of hepatic tissue. Malonaldehyde (MDA), which is an indicator of lipid peroxidation was markedly increased in AFB1-toxicated mice in liver, whereas TQ pretreatment significantly prevented MDA production. Histopathological effects such as inflammation, necrosis, disruption of hepatocytes, hyperplasia of kupffer cells, infiltration of mononuclear cells and increased diameter of hepatocytes were observed as signs of toxicity. TQ reduced the number of inflammatory cells and ameliorated the histopathological changes (33). Another study revealed that aflatoxin-contaminated diet induced haematological and biochemical changes in rats. *N. sativa* and *Syzygium aromaticum* oil significantly restored these changes. The protective effect of *N. sativa* oil was more than *Syzygium aromaticum* oil (34).

##### *Verrucaridin J*

Verrucaridin J is one of the most important trichothecene which is produced by several genus of fungi. Verrucaridin J can contaminate foods of both humans and animals (40). Male rats treated with a sublethal dose of verrucaridin J showed an increase in blood and liver tissue levels of thiobarbituric acid reactive substances (TBARs), superoxide dismutase (SOD) and 5-nucleotidase.

These effects were decreased largely by *N. sativa*. Similarly, the decrease in levels of glucose and zinc in blood as well as reduced GSH and glucose-6-phosphate dehydrogenase in liver tissue by verrucaridin J was improved by *N. sativa* (37).

##### *D-galactosamine*

D-galactosamine is an amino sugar which can lead to hepatic damage and necrosis just after a single dose administration. Lipopolysaccharide (LPS) sensitizes liver against multiple toxins including galactosamine (41). A synergistic action of LPS and galactosamine can induce fulminant hepatitis. TQ maintained AST, ALT, and ALP levels near to normal in D-galactosamine/LPS-intoxicated rats.

Furthermore, TQ improved degeneration of liver architecture, infiltration, and inflammation in hepatic tissues (35).

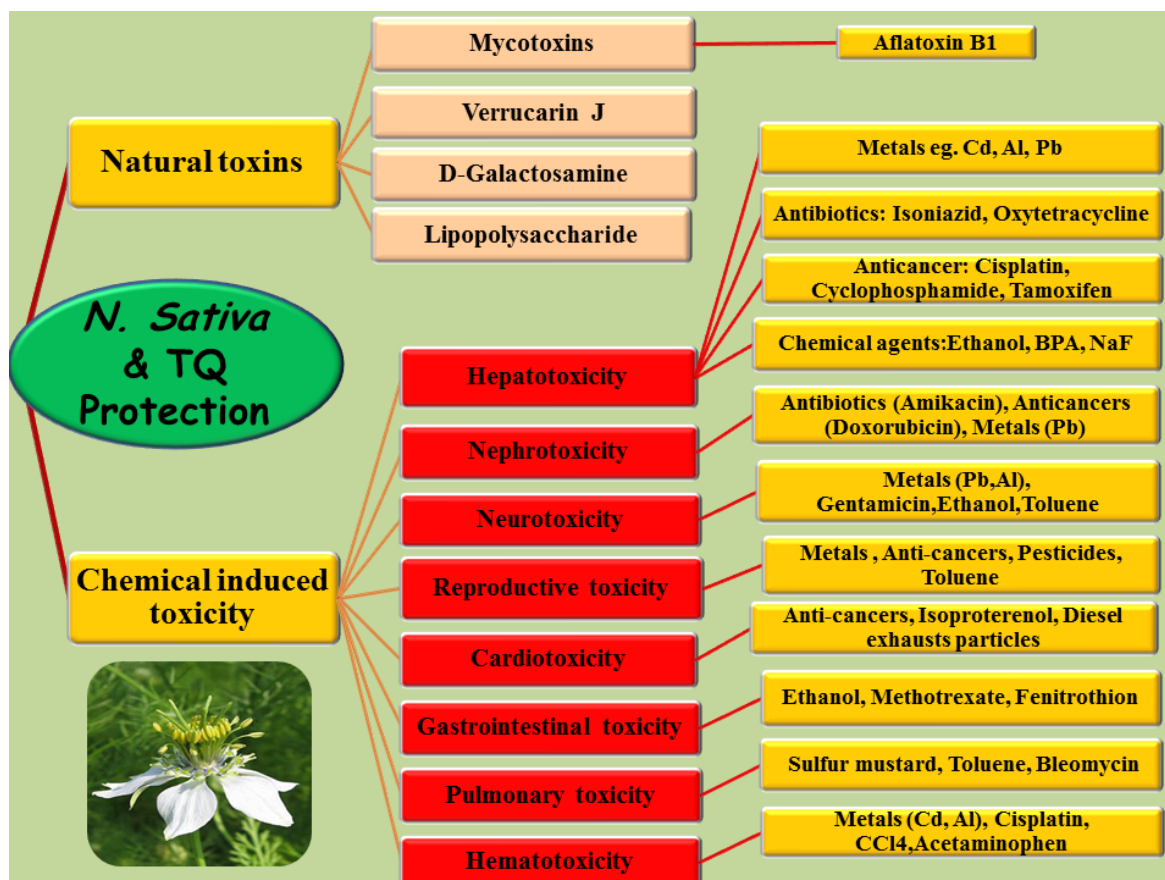


Figure 1. Schematic description of *N. sativa* and TQ against toxicities induced by natural toxins and chemicals in different tissues.

#### *Lipopolysaccharide (LPS)*

Lipopolysaccharide (LPS; endotoxin) is a component of gram-negative bacteria which exhibits a potent inflammatory response in mammals (42). Antioxidant and antiapoptotic effects of *N. sativa* against endotoxemia in rats were manifested by normalization of reduced liver GSH and reversing the increase in the level of MDA and the activity of caspase-3 enzyme in the liver. It also reduced the activities of serum tumor necrosis factor-alpha (TNF- $\alpha$ ) and bilirubin levels as well as activities of ALP, gamma-glutamyl transferase ( $\gamma$ -GT), and ALT (38).

#### *Chemical induced toxicity*

*Protective effects of black seed against chemical induced hepatotoxicity*

#### *Metals*

#### *Cadmium (Cd)*

Cadmium ( $Cd^{2+}$ ) is a toxic heavy metal and its major target is liver (42). Exposed mice to  $CdCl_2$  showed a significant elevation in SOD activity and a marked decline in catalase (CAT) activity which were both prevented by pretreatment with TQ. The levels of protein carbonyl, which is an oxidant marker, increased remarkably in case of  $CdCl_2$  pretreatment but declined considerably if it was combined with TQ (43).

#### *Aluminum (Al)*

Aluminum (Al) is the third most abundant element in nature (44). Aluminum salts are widely used in drinking water for purification purposes which allows its easy access into the body via gastrointestinal tract and lung tissue (45, 46). Oxidative stress was observed in rats exposed to Al, manifested by an increase in

**Table 1.** Protective effects of *N. sativa* or thymoquinone against drugs induced toxicities in different tissues.

Chemical induced toxicity		Toxicity	Study design, dose and type of <i>Nigella sativa</i> preparation	Protective mechanisms and references
Drug family	Drug name			
Antibiotic-aminoglycoside	Gentamicin	Nephrotoxicity	In vivo, rat NSO: (0.2ml/kg and 0.4 ml/kg)	Inhibiting free-radical formation, restoration of the antioxidant systems (108).
		Ototoxicity	In vivo, rat TQ: (50 mg/L in drinking water) for 8 consecutive days.	Decreasing oxidative stress and preserving the activity of the anti-oxidant enzymes, ability to prevent the energy decline in kidney tissues (107).
Antibiotic-aminoglycoside	Amikacin	Nephrotoxicity	In vivo, rat TQ: (20 mg/kg, i.p.)	(130)
Glycopeptide antibiotic	Vancomycin	Nephrotoxicity	In vivo, rat NSO: (2×0.5 ml)	(105)
Antibacterial ((antimycobacterial	Isoniazid	Nephrotoxicity	In vivo, rat TQ: (10 mg/kg, i.p. continued at 24 h intervals for 8 days)	TQ can interact with ROS as a general radical scavenger (111).
		Hepatotoxicity	In vivo, rat N. sativa seeds powder: (1 g/kg/day, orally)	Antioxidant, anti-inflammatory (possibly through prevention of hydrazine function, one of INH metabolites), and anti-angiogenesis properties (54).
Antiretroviral drugs	Lamivudine, Zidovudine Efavirenz	Hepatotoxicity	In vivo, rat Aqueous extract of <i>N. sativa</i> seed (100, 200, 400 and 800 mg/kg, orally for 28 consecutive days)	(104)
		Nephrotoxicity	In vivo, rat TQ: (10 mg/kg orally)	Protection against lipid peroxidation and NO production (126).
NSAID	Acetaminophen	Nephrotoxicity	In vivo, mouse N. sativa aqueous extract: (300 mg/kg)	(127)
		Hepatotoxicity	In vivo, rat TQ: (2 mg/kg/day) for 5 days	Anti-oxidative and nitrosative stress and improving energy production in mitochondria, substantial increase in lowered ATP and GSH levels (98).
NSAID	Indomethacin	Hepatotoxicity	In vivo, rat Alcoholic extract of <i>N. sativa</i> : (250 or 500 mg/kg, orally, for 7 days)	(100)
		Hepatotoxicity	In vivo, rat Three doses of TQ at a 15mg/kg total dose in an 18-h time interval	Upregulation of antioxidant systems (126)
Anti-cancer Intercalating agent, antiracemicals	Doxorubicin	Hepatotoxicity	In vivo, rat TQ: (10 mg/kg/day, orally, for 4 weeks)	Antioxidant and anti-apoptotic properties (102)
		Nephrotoxicity	In vivo, rat TQ (50 mg/kg/day, orally) for 3 weeks	Attenuating the oxidative stress, reversing the redox imbalance and subsequently ameliorating inflammatory tissue damage, Antioxidant activity through increasing Nrf2 expression and binding activity in renal tissue of DOX-treated rats (112).
Anti-cancer Intercalating agent, antiracemicals	Doxorubicin	Hepatotoxicity	In vivo, rat TQ: (10 mg/kg per day, for 5 days)	(113)
		Cardiotoxicity	In vivo, rat TQ: (2 mg/kg/day) for 5 days	Superoxide scavenging and anti-lipid peroxidation (30)
			In vivo, mouse TQ: (8 mg/kg/day, p.o.) for 5 days	(148)

**Table 1.** Continue.

		Hepatotoxicity	In vivo, rat Orally pre-treated with TQ: (500 mg. kg <sup>-1</sup> . day <sup>-1</sup> ) for one month	Antioxidant properties and radical scavenging, prevention of inflammation through inhibition of inflammatory mediators like NO, TNF- $\alpha$ and IL-1 $\beta$ and suppression of NF- $\kappa$ B (62).
Anticancer alkylating agents platinum compounds	Cisplatin	Nephrotoxicity	In vivo, rat Alcoholic extract of NS (100 mg/kg)  In vivo, rat TQ: (10 mg/kg b.w. in drinking water for 5 days)	(115)  Increasing anion and cation transporters and decreasing efflux transporters MRP2 and MRP4 expression (114).
		Hematotoxicity	In vivo, mouse N. sativa aqua extract: (50 mg/kg, i.p.)	(157)
		Reproductive toxicity	In vivo, rat NSO: (0.5. ml/kg concomitantly with cisplatin)	(138)
		Cardiotoxicity	In vivo, rat TQ (50 mg/L in drinking water) for 5 days	Decrease oxidative and nitrosative stress, preserve the activity of antioxidant enzymes, improve the mitochondrial function and energy production (147)
Anti-cancer Alkylating agent	Cyclophosphamide	Hepatotoxicity	In vivo, rat NSO: (1ml/kg) TQ: (10mg/kg) Both via intragastric injection for 12 days	Antioxidant properties (69)
		Reproductive toxicity	In vivo, mouse Ethanol extraction of N. sativa: (10 mg/kg, i.p.)	(141)
Anticancer estrogen antagonist	Tamoxifen	Hepatotoxicity	In vivo, rat TQ: (50 mg/kg/day-,orally, for 20 consecutive days, starting 10 days before tamoxifen injection	Preventing oxidative stress and lipid peroxidation, enhancing antioxidant enzymes activities and inhibiting hepatic inflammation (76)
		Hepatorenal toxicity	In vivo, rat TQ: (10mg/kg/day by gastric gavage for 10 consecutive days) human (Egyptian Children)	Antioxidant, antinitrosative, anti-inflammatory, and antiapoptotic mechanisms (66)
Anticancer ,Antimetabolite DHFR inhibitor	Methotrexate	Hepatotoxicity	Black seeds: (80 mg/kg/day, orally for one week after each methotrexate dose)	(65)
		Reproductive toxicity	In vivo, mouse TQ: (10 mg/kg/day, i.p. for 4 days)	(137)
		Gastrointestinal toxicity	In vivo, rat NSO: (10 ml/kg)	(155)
Anticancer Alkylating agent	Ifosfamide	Nephrotoxicity	In vivo, mouse TQ: (10 mg/kg per day, orally)	(119)
Antiepileptic	Sodium valproate	Hepatotoxicity	In vivo, rat TQ: (5-5.5mg/kg/day, in drinking water, for 21 days)	Antioxidant properties and cleansing the free radicals (101)
		Nephrotoxicity	In vivo, rat NSO: (2 ml/kg orally)	(123)
Immunosuppressive	Cyclosporine	Cardiotoxicity	In vivo, rat NSO: (21 days, 2 ml/kg, orally)	Protect against oxidative stress and imbalance between the production of reactive oxygen species and endogenous antioxidant defense systems (151)

Table 1. Continue.

Gout drug alkaloid	Colchicine	Reproductive toxicity	In vivo, rat Aqueous suspension of powdered <i>N. sativa</i> seeds: (1000 mg/kg/day)	(146)
Anticancer Glycopeptide antibiotic	Bleomycin	Pulmonary toxicity	In vivo, rat TQ: (5 mg/100mL, orally)	Superoxide scavenging and anti-lipid peroxidation (161)

hepatic MDA levels, a decline in GSH and a fall in glutathione peroxidase (GPx), SOD and CAT activities (47, 48). Administration of *N. sativa* oil alleviated the lipid peroxidation in liver and reduced MDA levels significantly, as well as modulated the disturbed activities of hepatic antioxidant enzymes (49).

#### Lead (Pb)

Lead, which plays a major role in today's industry, is known for its toxic effects on multiple organs including kidney and Liver (50). TQ is proved to alleviate lead acetate toxicity in rats. In terms of biochemical parameters, co-treatment with TQ prevented the serum AST from rising and provided no significant change in serum total protein and albumin, the opposite of what was seen in rats fed only on lead acetate. Periportal necrosis of hepatocytes and inflammatory infiltration were observed in lead acetate-treated rats, whereas TQ maintained the normal structure of liver (51).

#### Antibiotics

##### Isoniazid

Isoniazid (INH) is a first-line medication in prevention and treatment of tuberculosis. One of its main side effects is mild to severe hepatotoxicity (52, 53). INH-induced hepatotoxicity in rats was manifested by sinusoidal dilatation (mainly lobular), hepatocellular necrosis, moderate portal inflammation and degeneration of hepatocytes. These inflammatory signs were not observed in rabbits pretreated with *N. sativa*. In terms of hepatic biomarkers, *N. sativa* also significantly reversed the elevated levels of serum ALT, AST, ALP, and bilirubin caused by INH (54).

##### Oxytetracyclin

Oxytetracyclin is a widely used antibiotic

for treating bacterial infections caused by gram-negative and gram-positive microorganisms (55). Oxytetracyclin, however, can have serious side effects like hepato-renal toxicity in high doses (56, 57). Oral administration of oxytetracyclin in rabbits elevated ALT and AST more than two folds of the normal level. It also increased ALP, lactate dehydrogenase (LDH), cholesterol, and total serum bilirubin. Moreover, renal biomarkers like serum urea, uric acid and creatinine were increased. *N. sativa* oil and ascorbic acid (in combination or individually) modulated the rises in liver and kidney injury markers. In terms of lipid peroxidation and antioxidant capacity in both organs, treatment with oxytetracyclin remarkably increased MDA and reduced the CAT, SOD and glutathione (GSH) activities. Combination of *N. sativa* oil and ascorbic acid restored the antioxidant status and MDA levels back to normal and showed greater therapeutic effect than when each of them was used alone (58).

#### Anti-cancers

##### Cisplatin

Cisplatin is a well-known anticancer drug prescribed mainly to treat solid tumors. It has to be used cautiously due to its toxic effects on liver and kidney (59). The main mechanism of cisplatin hepatotoxicity, which is indicated by a fall in GSH levels and a rise in MDA levels, is through oxidative stress (60). Cisplatin can induce generation of reactive oxygen species (ROS) which in turn could lead to DNA damage and membrane lipid peroxidation (61). Treatment of cisplatin-intoxicated rats with TQ showed a significant improvement in the elevated levels of some hepatic biomarkers and manifested a marked increase in GPx activity. Enhancement in activities of antioxidant enzymes such as

SOD and CAT was observed which led to a great reduction in lipid peroxidation (62).

#### *Methotrexate*

Methotrexate (MTX) is a chemotherapeutic agent which can cause hepatotoxicity as a side effect (63). Administration of *N. sativa* oil in rats intoxicated with MTX manifested less degeneration in hepatic tissues through anti-oxidant activity (64). Another study was conducted with the aim of assessing the antidotal effect of black cumin on children diagnosed with acute lymphoblastic leukemia who were under MTX treatment. It was suggested that black cumin significantly recovered the increased levels of serum bilirubin, serum ALT, AST and ALP but did not have a remarkable effect on serum total protein, serum albumin, and globulin (65). El-Sheikh *et al* reported that using TQ concurrently with MTX reversed up regulation of iNOS (inducible nitric oxide synthase), necrosis factor- $\kappa$ B, cyclooxygenase-2, and caspase 3 in rat liver which respectively demonstrates anti-oxidant, anti-inflammatory, and anti-apoptotic effect of TQ (66).

#### *Cyclophosphamide (CTX)*

Cyclophosphamide (CTX) is an alkylating agent with significant therapeutic importance in a wide range of conditions including cancer (67). However, it could induce overproduction of reactive oxygen species which accounts for its systemic toxicity (68). CTX treatment resulted in a considerable increase in serum ALT and AST in rats. Administration of *N. sativa* oil and TQ after and before CTX induced recovery of both enzyme activities. The same effect was observed in levels of ALP and creatine phosphokinase (CPK) in case of pretreatment with *N. sativa* oil or TQ (69).

#### *Tamoxifen*

Tamoxifen is an antistrogen used in breast cancer therapy and also as a chemopreventive agent in health woman with high risk of developing breast cancer (70, 71). Tamoxifen is a potent hepatocarcinogen with tumor-initiating and tumor-promoting properties due to its excessive oxygen radical production (72-75). Serum liver enzymes, AST, ALT, ALP, LDH,  $\gamma$ GT,

and total bilirubin were significantly elevated in tamoxifen -treated rats. These changes were reduced by administration of TQ. Levels of SOD and GSH were increased and the elevated lipid peroxidation and TNF- $\alpha$  were attenuated upon administration of TQ to tamoxifen -intoxicated rats (76).

#### *Imidacloprid*

Imidacloprid, is a member of the neonicotinoid insecticide class which acts on the nervous system by blocking postsynaptic acetylcholine receptors and is highly effective against a variety of insects (77).

A decline in the levels of serum ALT, AST, ALP, and MDA in rats exposed to imidacloprid was an indication that TQ is a useful agent in reducing the oxidative stress caused by exposure to this insecticide (78).

#### *Carbon Tetrachloride (CCl<sub>4</sub>)*

Carbon tetrachloride (CCl<sub>4</sub>) is a xenobiotic which produces hepatotoxicity in humans as well as in animals (79, 80). A single dose of CCl<sub>4</sub> induced hepatotoxicity, manifested biochemically by significant elevation of serum enzyme activities, such as ALT, AST and LDH in mice. These levels fell sharply after treatment with TQ. TQ raised hepatic catalase activity as well (81). In another study conducted on Wistar rats, administration of CCl<sub>4</sub> caused a rise in lipidperoxidase levels of liver and kidney and reduced GSH in these two organs markedly. Moreover, in terms of histopathological observations, it produced fatty degeneration, distended hepatocytes and distortion of hepatic architecture. Treatment with *N. sativa* (750mg/Kg) had the best effect on restoring the antioxidant capacity back to normal and protected the hepatic lesions caused by CCl<sub>4</sub> (82).

#### *Tert-butyl hydroperoxide (TBHP)*

Tert-butyl hydroperoxide is a hepatotoxic agent which in case of exposure stimulates rapid oxidation of intracellular GSH, and pyridine nucleotides, as well as leakage of cytosolic enzymes (83, 84).

Administration of TQ increased the reduced viability of TBHP-treated rat hepatocytes besides

lessening the leakage of AST and ALT (85).

#### *Ethanol*

Ethanol is a well-known hepatotoxic agent which caused substantial increases in ALT and AST levels after application in rats. It also elevated triglyceride and MDA levels notably. Treatment with *N. sativa* oil provided a significant drop in increased transaminase levels and reduced triglyceride and MDA (86, 87).

#### *Sodium Fluoride (NaF)*

Fluoride anion is an agent which contributes to dental protection and prevents osteoporosis in small doses, but in case of excessive exposure it can interfere with metabolic pathways involving lipids, carbohydrates and proteins (88, 89). The consumption of NaF in rats significantly disrupted the antioxidant functionality of liver by reducing SOD, CAT and GSH levels. The elevated levels of AST, ALT, ALP and LDH as well as a remarkable decrease in serum protein profile were also observed. Administration of TQ with NaF restored the antioxidant activity of liver and reversed the decline in serum protein levels (90).

#### *Bisphenol A (BPA)*

Bisphenol A (BPA) is a compound widely used in plastic and resin industry and is a main component of plastic baby bottles, as well as food and beverage containers (91). BPA has an extended range of adverse effects and can cause oxidative stress in liver (92). Reduction in hepatocytes viability and their mitochondrial function were reported in rats treated with BPA (93). Administration of TQ greatly normalized suppressed enzymatic and non-enzymatic antioxidants such as GSH, GPx, GST, SOD, and CAT. It also reduced elevated levels of hepatic biomarkers and decreased lipid peroxidation (94).

#### *Acetaminophen*

Severe hepatotoxicity caused by acetaminophen overdose is well documented (95). It also leads to a significant increase in serum ALT and total nitrate/nitrite, hepatic lipid peroxides, and depletion of hepatic GSH and ATP (96). Acetaminophen overdose can result

in liver necrosis and be fatal (97). TQ produced a marked normalization of the acetaminophen-induced increase in serum nitrate/nitrite and hepatic ALT. A substantial increase in lowered ATP and GSH levels was manifested (98). It was also found that co-administration of TQ with acetaminophen significantly elevated lowered glutathione peroxides (99). Furthermore *N. sativa* extract caused resumption of liver architecture and lessened tissue necrosis and infiltration (100).

#### *Sodium valproate*

Sodium valproate is a widely used drug in the treatment of epilepsy while it is known for its hepatotoxic effects which is characterized by elevated serum AST and ALT as well as a fall in non-protein sulfhydryls and an increase in lipid peroxidation in hepatic cells. Co-treatment of sodium valproate and TQ ameliorated the raised AST and ALT levels but did not prevent increased lipid peroxidation. Moreover, the co-treatment improved the reduction of hepatic glutathione induced by sodium valproate (101).

#### *Indomethacin*

Indomethacin is a NSAID used in the treatment of inflammatory disorders. In high doses however, it can induce hepatotoxicity and hepatocyte death by activating multiple stress pathways. TQ is proved to have oxidant-scavenging abilities and the potential to decrease apoptotic changes which can serve as a protective mechanism against indomethacin-induced toxicity (102).

#### *Antiretroviral drugs*

HAART (Highly Active Antiretroviral Therapy) is the use of a combination of drugs such as Lamivudine, Zidovudine, and Efavirenz to control retroviral infections which can lead to hepatotoxicity (103). In HAART treated rats, the hepatic biomarker levels such as AST, ALT, ALP, and GGT were significantly increased and albumin concentration dropped sharply. Besides, there were signs of histopathological damage in liver tissues.

Administration of *N. sativa* restored the biochemical and histopathological changes to normal through its antioxidant activity (104).



### *Protective effects of black seed against chemical induced nephro- or uro-toxicity*

#### *Antibiotics*

##### *Amikacin*

Amikacin is an aminoglycoside in severe infections. However, its use is associated with undesirable renal toxicity (105). In renal tissue of amikacin-treated rats, MDA level elevated and GSH content reduced which indicates oxidative stress. In addition, creatinine, urea and uric acid levels increased which indicates renal dysfunction. Histopathological examination showed severe vacuolation of renal tubular cells, massive tubular necrosis, renal cast and mononuclear cell infiltration. In rats received *N. sativa* oil with amikacin, all of mentioned markers significantly declined to normal status (105).

##### *Gentamicin*

Gentamicin is effective against gram negative bacterial infection in human and animals (106). Nephrotoxicity is a main complication of its therapeutic doses. Renal failure occurs in about 10–30% of patients receiving the drug (107). The results of some studies showed that gentamicin caused moderate proximal tubular damage, glomerular and tubular necrosis, interstitial nephritis and desquamation of the tubular epithelial cells in rat's renal cortex (106, 107). It also significantly increased the levels of creatinine and urea, and decreased the levels of total antioxidant status and GSH in kidney cortex. Treatment with *N. sativa* oil enhanced rat's growth, and produced a dose-dependent amelioration of the biochemical and histological indices of gentamicin nephrotoxicity that was statistically significant at doses of 1.0 and 2.0 ml/kg/day for 10 days (106).

In another study, in comparison with gentamicin group, *N. sativa* administration caused significant decreases in MDA level and nitric oxide generation and increases in SOD and GSH-Px activities. So, *N. sativa* ameliorates gentamicin-induced oxidative stress (108). Moreover, the synergistic nephroprotective effects of vitamin C and *N. sativa* oil have been shown. Combination of vitamin C and *N. sativa* oil decreased the levels of nephrotoxicity markers such as serum creatinine, BUN, and

antioxidant activity as compared with gentamicin treated rabbits (109). It is also reported that TQ supplementation completely reversed the decrease in ATP and the ATP: ADP ratio induced by gentamicin. Therefore, TQ prevents the energy decline in kidney tissues and so protected gentamicin-induced renal failure (110).

Sayed-Ahmed and Nagi (2007) reported that TQ supplementation resulted in a complete reversal of the gentamicin-induced increase in BUN, creatinine, thiobarbituric acid reactive substances and total nitrate/nitrite and decrease in GSH, GPx, CAT, and ATP to control values. So, TQ supplementation can prevent the development of gentamicin-induced acute renal failure (107).

##### *Oxytetracycline*

Oxytetracyclin is a widely used antibiotic for treating bacterial infections caused by gram-negative and gram-positive microorganisms (55). Oxytetracyclin, however, can have serious side effects like hepato-renal toxicity in high doses (56, 57). Based on the evidences from animal studies, *N. sativa* oil co-administration could alleviate oxytetracycline -induced increase in serum biochemical renal injury markers and lipid peroxidation. Moreover, *N. sativa* oil could improve decrease in tissue antioxidant biomarkers (58).

##### *Vancomycin*

Vancomycin is a kind of glycopeptide antibiotic with antibacterial effect against aerobic and anaerobic gram-positive bacteria. It was reported that levels of serum blood urea nitrogen (BUN), creatinine (Cr) and kidney tissue MDA were increased in the rats treated by vancomycin whereas TQ administration significantly lowered them (111).

#### *Anti-cancers*

##### *Doxorubicin*

Doxorubicin is an antitumor drug that like other chemotherapy drugs has many side effects, the most dominant of which is severe nephrotoxicity. In the renal tissue of doxorubicin -treated rats the activities of SOD and GST were significantly decreased and lipid peroxidation increased. In addition, doxorubicin

caused significant changes in renal levels of inflammatory mediators: increase in TNF- $\alpha$  and IL-6 levels and marked decrease in IL-10 levels. Remarkably TQ restores all mentioned markers toward normal values (112).

Badary *et al* (2000) reported that treatment with TQ significantly suppressed doxorubicin-induced proteinuria and lowered the levels of triglycerides, total cholesterol, and lipid peroxides in the rat kidneys (113).

#### *Cisplatin*

Cisplatin, is a chemotherapeutic drug which is widely used for treatment of several kinds of human disease. Administration of cisplatin is a common cause of acute renal failure, which is a life-threatening illness that continues to have a high mortality. Cisplatin-induced renal injury is associated with an elevation in protein levels of the efflux transporters MRP2 and MRP4 while expression of organic anion and cation transporters (OATs and OCTs) was reduced. Co-administration of TQ with cisplatin reversed down-regulation of OAT1, OAT3, OCT1, and OCT2 as well as up-regulation of MRP2 and MRP4. It was also proved that TQ can alleviate cisplatin-stimulated oxidative stress makers, lipid peroxidation status, and other nephrotoxicity markers (114). TQ treatment also significantly decreased cisplatin-induced elevated serum urea and creatinine levels (115). However, Hadjzadeh *et al* reported that use of *N. sativa* seeds had little effects on biochemical parameters but relatively recovered histopathologic properties of the kidneys (116). One study was performed in order to show the renal toxicity of cisplatin and the way ARF (acute renal failure) was caused by this anticancer drug and eventually to measure the ameliorative effect of TQ on this toxicity. Cisplatin can aggravate the pulmonary dysfunction produced by diesel exhaust particles (DEP). Cisplatin alone, induced significant rises in urea and neutrophil gelatinase-associated lipocalin (NGAL) and remarkably reduced creatinine clearance. DEP alone did not manifest a marked effect on renal parameters and did not significantly change the aforementioned actions of cisplatin. TQ proved to be useful in restoring the normal levels of the indices especially urea. Tubular necrosis and dilation were observed in

cisplatin-treated rats and the conditions were exacerbated in case of co-treatment with DEP. The damage was lessened by treatment with TQ (117).

#### *Ifosfamide*

Ifosfamide is a synthetic structural isomer of cyclophosphamide that has been approved for concurrent use with other drugs in the treatment of metastatic germ-cell testicular cancer and some sarcomas. Nephrotoxicity is a well-known complication of ifosfamide therapy. Renal fanconi syndrome is one of renal toxicities of ifosfamide and is characterized by a generalized disorder in proximal tubule transport (118). It was proved that TQ provides protection against ifosfamide-induced fanconi syndrome in rats as well as improving its anti-tumor effect in mice (119).

#### *Methotrexate (MTX)*

MTX is one of the most widely used anticancer drugs. One of the most prominent toxicities caused by MTX chemotherapy is nephrotoxicity (66). It is revealed that co-administration of TQ with methotrexate could reverse MTX-induced oxidative and nitrosative stress, as well as inflammatory and apoptotic signs in rats kidneys. TQ also ameliorated kidney dysfunction and histological damages caused by MTX (66).

#### *Bromobenzene*

Bromobenzene is a solvent in the chemical industry and chemical intermediates. Bromobenzene metabolites are highly hepatotoxic while secondary metabolites are highly nephrotoxic which are conjugated to bromoquinones that can accumulate in the kidney and are nephrotoxic. The observed low level of serum protein and elevated levels of BUN and creatinine in bromobenzene-treated rats indicate renal dysfunction. Administration of *N.sativa* oil returned BUN and creatinine levels to normal level and significantly increased the reduced serum protein level (120).

#### *Nitilotriacetate Fe*

Nitilotriacetic acid is a constituent of various domestic and hospital detergents and is a common

water contaminant (121). The iron complex of nitrilotriacetic acid (Fe-NTA) is nephrotoxic. A study by Khan and Sultana (2005) demonstrated *N. sativa* could suppress hyperproliferative response and reduce tumor promotion in kidney tissue of rats (122).

#### *Cyclosporine A*

Nephrotoxicity is the main secondary effect of cyclosporine A treatment which is used for the prevention of allograft rejection in solid organ transplantation. Uz *et al* (2008) reported that co-administration of *N. sativa* oil with cyclosporine A ameliorate deterioration in the renal function and morphology was caused by cyclosporine A. It also attenuated the oxidative stress induced by cyclosporine A (123).

#### *Metals*

##### *Lead (Pb)*

Lead caused significant elevations in AST, urea, creatinine, total cholesterol, and triglycerides in serum as well as significant decrease in serum total protein and albumin. Co-administration of *N. sativa* seeds with lead acetate improved the biochemical parameters and reduced the damaged areas in the liver and kidneys (58).

##### *Mercuric chloride*

Mercuric chloride (HgCl<sub>2</sub>) is a potent nephrotoxicant that has been widely used in animal models of acute renal failure. Fouda *et al* (2008) reported that in rats who received a nephrotoxic dose of HgCl<sub>2</sub>, changes in the renal MDA, GSH content, GPx, and CAT activities were observed. This rapid increment of the biomarkers of oxidative stress was associated with marked renal cellular injury. In addition, some signs of histological damage, apoptotic events, and proliferative reactions were seen. The deterioration of antioxidant enzymes and histological damage caused by HgCl<sub>2</sub> were markedly improved by TQ treatment. Apoptosis and proliferative reactions were also reduced, so TQ may be clinically useful in inorganic mercury intoxication (124).

##### *Acetaminophen*

Renal insufficiency occurs in approximately

1-2% of patients with acetaminophen overdose (125). Ayca *et al* (2015) reported that in the TQ-treated group, urea and creatinine levels were lower than the group received acetaminophen whereas MDA and Nitric oxide levels were higher. The results showed that IP administration of TQ caused significant improvement in biochemical, antioxidant, and histopathological changes induced by acetaminophen in rats (126). Another study revealed that co-administration of silymarin and TQ had a better ameliorative effect in case of acetaminophen toxicity and reduced urea and creatinine levels sufficiently more than when each of them was used alone (127).

#### *Protective effects of black seed against chemical induced neurotoxicity*

##### *Metals*

##### *Lead (Pb)*

Treatment with lead causes wide spectrum of histopathological brain damages in rats including degeneration of endothelial lining of brain blood vessels with perivascular cuffing of mononuclear cells consistent to lymphocytes, congestion of choroid plexus blood vessels, ischemic brain infarction, chromatolysis and neuronal degeneration, microglial reaction and neuronophagia, degeneration of hippocampal and cerebellar neurons and axonal demyelination. However, TQ supplement with lead acetate markedly decreased the incidence of those pathological lesions (128).

##### *Aluminum (Al)*

Al is toxic to the central nervous system, Kamal and Kamal (2013) reported that administration of Al in the rat cerebellum caused a significant reduction in the number of Purkinje cells and induced some damages such as cytoplasmic vacuolation, dilatation of Golgi cisternae, and mitochondria with dilated cristae in Purkinje cells. Granule cells showed mitochondria with destroyed cristae. The immune reaction for caspase-3 was intense compared with that of the control group. Co-administration of *N. sativa* oil remarkably protected the neurons against these changes (129).

##### *Gentamicin*

Nephrotoxicity and ototoxicity are the

most common problems during treatment with aminoglycosides such as gentamicin. Auditory brainstem response - thresholds significantly increased in gentamicin received rats. Sagit *et al.* (2014) showed that the mean auditory brainstem response values and numbers of apoptotic cells did not significantly increase in the group receiving gentamicin plus TQ compared to those receiving gentamicin alone. TQ (20 mg/kg) has protective effects on gentamicin-induced ototoxicity (130).

#### *Ethanol*

Exposure to ethanol during early development triggers severe neuronal death by activating multiple stress pathways and causes neurological disorders, such as fetal alcohol effects or fetal alcohol syndrome. Ullah *et al.* (2012) reported that ethanol exposure in rat prenatal cortical neurons induces elevation of cytosolic free calcium  $[Ca^{2+}]$  and decreases normal physiological mitochondrial transmembrane potential ( $\Delta\psi M$ ) which both of them returned to normal status by TQ. Increased  $[Ca^{2+}]$  and decreased  $\Delta\psi M$  significantly reduced the expression of a key anti-apoptotic protein (Bcl-2), increased expression of Bax, and stimulated the release of cytochrome-c from mitochondria. TQ also inhibited the apoptotic cascade by increasing Bcl-2 expression (131).

#### *Toluene*

Toluene is an industrial organic solvent with extensive uses. It is revealed that toluene chronic exposure caused severe degenerative changes in rat's frontal cortex neurons; such as shrunken cytoplasm, severely dilated cisternae of endoplasmic reticulum, markedly swollen mitochondria with degenerated cristae and nuclear membrane breakdown with chromatin disorganization. TQ treatment markedly prevented mentioned degenerative changes, although moderately mitochondrial swollen was still observed in neurons with TQ treatment (132).

#### *Propoxur*

Propoxur is a carbamate insecticide with wide uses especially for household pests. It induces lipid and protein peroxidation and decreases

acetylcholine esterase activity in cerebellum, cortex, and hippocampus. It is also revealed that propoxur significantly reduced the enzymatic antioxidant (SOD, CAT, GSH-Px and GST) activities and non-enzymatic antioxidant (GSH) levels. However, treatment with *N. sativa* oil can ameliorate the propoxur-induced toxicity and oxidative stress in the three brain regions (133).

#### *Protective effects of black seed against chemical induced reproductive toxicity*

##### *Metals*

##### *Cadmium (Cd)*

Sayed *et al.* (2014) reported that Cd long-term exposure caused oxidative stress, spermatological damage, histopathological alterations, and decrease in serum testosterone level in testes, epididymis, and accessory glands in male rats. On the other hand, co-administration of TQ and Cd ameliorated all the damages. Remarkably, no significant difference was observed between Cd-treated and TQ-treated rats in sperm count (134). Another study demonstrated that Cd acute exposure induced oxidative stress indicated by decrease in antioxidants and increase in oxidative enzymes. Cd also elevated the expression of iNOS, TNF- $\alpha$ , COX-2, NF- $\kappa$ B, and caspase-3 in seminiferous tubules cells. TQ treatment alleviated these changes and markedly ameliorated the cadmium-induced damage of testicular tissue and preserved spermatogenesis in most of seminiferous tubules (135).

##### *Lead (Pb)*

A study by Mabrouk and Ben Cheikh (2015) demonstrated that TQ co-treatment could improve lead induced testicular oxidative stress in rats by decrease in the elevated levels of oxidative enzymes and increase in the level of glutathione significantly (136).

##### *Anti-cancers*

##### *Methotrexate*

It was revealed that mice received methotrexate resulting in interstitial space dilatation, edema, vasculitis, abnormalities of Leydig cells, severe disruption of the seminiferous epithelium, and reduced diameter of the seminiferous tubules; however, TQ co-treatment significantly reversed these histopathological changes and

prevented methotrexate-induced increase in the myeloperoxidase activity, but the levels of MDA did not differ among the groups (137).

#### *Cisplatin*

Awadalla (2012) reported that cisplatin negatively affected on MDA level as well as histological structure of the testes and *N. sativa* oil restored these changes to those of control (138).

#### *Cyclophosphamide*

Cyclophosphamide is one of the most harmful alkylating agents. It can cause oxidative stress due to the over-production of ROS. It affects the DNA of replicating cells and rapidly multiplying cells especially in the gonads and pituitary which results in miscoding, cross-linking, and DNA breakage (139). A prophylactic effect of *N. sativa* in the reproductive system of female mice has been shown. In mouse ovarian tissue exposed to *N. sativa* oil before cyclophosphamide exposure significant protection on the fine structure of follicles was observed. Furthermore, the survival rates of normal follicles in group received *N. sativa* oil were higher than cyclophosphamide-treated group (140).

TQ administration significantly alleviated the percentage of defects blastomeres of type c and embryo fragmentation grade IV in cyclophosphamide-treated mice; so, it could be a suitable supplementation for preserving fair-quality embryos and achieving full term pregnancy (139).

Cyclophosphamide treated mice induced reduction of testes weights, epididymides and sperm count with high percentage of acrosome reacted sperm possibly to spontaneous acrosomal reaction caused by free radicals. Co-administration of *N. sativa* ethanol extract and cyclophosphamide elevated sperm count but had no effect on their histology (141).

#### *Pesticides*

##### *Acetamiprid*

Acetamiprid is an odorless neonicotinoid insecticide (142). Acetamiprid caused reproductive toxicity in male rats indicated by a decrease in body weight gain, relative weights of reproductive organs (testis, epididymis and

seminal vesicle), spermatids number, sperm count, sperm motility, and testosterone levels. It also induced histopathological changes including tubular atrophy, disorganization, and degenerative aspect of the seminal epithelium in some seminiferous tubules marked by spermatogenesis perturbation and poor sperm and also presence of sloughing cell debris in their lumens. It is revealed that *N. sativa* oil co-administration modulated these acetamiprid-induced reproductive adverse effects (143).

##### *Chlorpyrifos*

Chlorpyrifos is a pesticide that can induce toxic effects on male rat reproductive system indicated by a decrease in sperm count and production, sexual hormones, body weight, and relative weight of reproductive organs accompanied by increase in dead and abnormal sperms. Chlorpyrifos treatment also causes oxidative stress. Co-administration of *N. sativa* oil and chlorpyrifos ameliorated chlorpyrifos toxic effects (144).

##### *Toluene*

Toluene is a volatile organic compound widely used as an industrial solvent. It can also be found as an air pollutant in homes and buildings. Exposure to high levels of toluene inhalation is known to induce reproductive and developmental toxicity. Kanter (2011) reported that TQ co-administration markedly lowered the reactivity and the number of germ cell apoptosis and improved cell organelles damages in toluene-treated rat's testis. The results showed that chronic toluene exposure decreased spermatogenesis and mean seminiferous tubule diameter. TQ improved histopathological damages induced by toluene in rats (145).

##### *Colchicine*

Colchicine is one of the gout therapy drugs that have a narrow therapeutic index and its toxicity is associated with high mortality rate (146). Colchicine caused histopathological damages in rat testes as well as decrease in spermatogenesis and testosterone plasma level and low positive reaction of PAS. *N. sativa* seeds supplementation significantly improved testicular toxicity manifestations induced by colchicine (146).

*Protective effects of black seed against chemical induced cardiotoxicity*

*Anti-cancers*

*Cyclophosphamide*

Cyclophosphamide is an alkylating agent, which is commonly used in most cancer chemotherapy. High therapeutic doses of cyclophosphamide are associated with lethal cardiotoxicity (147). In rat heart tissues, cyclophosphamide causes a significant increase in TBARS and total nitrate/nitrite and a significant decrease in reduced GSH, GPx, CAT, and ATP levels. Interestingly, TQ supplementation completely reversed all cyclophosphamide-induced biochemical changes to their control values (147).

*Doxorubicin*

Doxorubicin is an anthracycline antibiotic which is used as an antitumor agent. It is well known that anthracyclines can induce cardiotoxicity by releasing ROS (148). According to a study by Al-Shabanah *et al* (1998), doxorubicin -induced cardiotoxicity could lead to cardiomyopathy and heart failure. TQ could protect doxorubicin-induced cardiotoxicity as evidenced by significant reduction in creatine phosphokinase and lactate dehydrogenase in rats. This study revealed that TQ could ameliorate doxorubicin cardiotoxicity without decreasing doxorubicin antitumor activity or its plasma and heart levels (148).

*Isoproterenol*

Isoproterenol induced myocardial injury, is a classical example of excess catecholamines related coronary insufficiency and stress cardiomyopathy. A study revealed that TQ oral administration (dissolved in olive oil) protected the rat's heart from stress cardiomyopathy induced by isoproterenol. Isoproterenol significantly increased plasma LDH, TBARS, and glutathione reductase, whereas there was a dose related decrease in these markers in TQ treated groups. In addition, TQ reversed decrease in plasma SOD, myocardial GSH/GSSG ratio, and histological changes produced by isoproterenol (149).

*Diesel exhausts particles (DEP)*

Adverse cardiovascular events are most strongly associated with exposure to fine particulate matter (diameter < 2.5  $\mu\text{m}$ ). Nemmar *et al* (2011) revealed that TQ pretreatment prevented DEP-induced cardiovascular damages. It is reported that TQ protected DEP-induced decrease of systolic blood pressure, decrease in platelet numbers, leukocytosis, and prothrombotic events. However TQ did not inhibit platelet aggregation *in-vitro* (150).

*Cyclosporine A*

Cyclosporine A is a commonly used immunosuppressive agent in transplant medicine and in the treatment of autoimmune diseases. However, it generates ROS, which causes nephrotoxicity, hepatotoxicity, and cardiotoxicity (151). It is indicated that *N. sativa* oil pre-treatment reduced the subsequent cyclosporine A injury in rat heart, manifested by normalized cardiac histopathology, decrease in lipid peroxidation, improvement in antioxidant enzyme status and cellular protein oxidation (151).

*Methionine*

Homocysteine is a sulfur-containing amino acid which produces during the metabolism of the essential amino acid methionine. Defective metabolism of methionine resulting in hyperhomocysteinemia (HHcy). HHcy is associated with higher risks of coronary, cerebral, and peripheral vascular disease (152). In a study by El-Saleh *et al* (2004), it was showed that methionine-induced hyperhomocysteinemia led to significant increase in the degree of lipid peroxidation and antioxidant enzyme activities (SOD and GPx), decrease in antioxidant status, and elevation in lipid parameters (triglycerides and cholesterol). TQ and black seed oil effectively protected rats against the induction of HHcy due to methionine loading (152).

*Protective effects of black seed against chemical induced gastrointestinal toxicity*

*Ethanol (EtOH)*

The results of a study suggest that TQ could inhibit the development of gastric ulcer caused by ethanol (146, 147). Likewise, TQ protected against the ulcerating effect of alcohol and

mitigated most of the biochemical adverse effects induced by alcohol in gastric mucosa, but to a lesser extent than *N. sativa*. *N. sativa* increased gastric GSH content, GST, and enzymatic activities of gastric SOD (154); however, TQ did not statistically change the high SOD activity (153).

#### *Methotrexate (MTX)*

Labib *et al.* (2009) reported that *N. sativa* oil pretreatment improved MTX-induced diarrhea, food consumption, and body weakness. They also showed that administration of *N. sativa* oil before and after MTX ameliorated gastrointestinal toxicity caused by MTX and maintained mucosal structure (155).

#### *Fenitrothion*

Fenitrothion is one of the organophosphate insecticides. It is demonstrated that fenitrothion oral administration causes some histopathological changes in salivary glands in rats. Remarkably, administration of natural antioxidants like *N. sativa* oil could be of beneficial effect on prevention of cytotoxicity induced by organophosphate. However, green tea showed more effective results than that of *N. sativa* (156).

#### *1, 2-dimethyl-hydrazine (DMH)*

DMH is a potent carcinogen that acts as a DNA methylating agent. It is used to induce colon tumors in experimental animals (157). It is revealed that TQ protects and cures DMH-induced initiation phase of colon cancer. It also exerts a protective role at promotion (157).

#### *Protective effects of black seed against chemical induced pulmonary toxicity*

##### *Diesel exhaust particles (DEP)*

It was revealed that DEP exposure after 18h caused a significant increase in macrophages and polymorphonuclear cell numbers, total protein, and IL-6 concentrations in mice bronchoalveolar lavage (BAL) fluid, while TQ pretreatment significantly prevented these changes and reduced the number of interstitial inflammatory cells. It also prevented DEP-induced enhancement of airway resistance after increasing concentrations of methacholine (150). TQ also can reverse toxic

effects of DEP in combination with cisplatin (117).

#### *Sulfur mustard*

Sulfur mustard is one of the chemical warfare agents (158). Hossein *et al.* (2008) reported that the tracheal responsiveness to methacholine was significantly higher in sulfur mustard-exposed guinea pigs prevented by *N. sativa* extract co-administration (159). Another study demonstrated that effectiveness of *N. sativa* in decrease of tracheal responsiveness to methacholine was equal to that of dexamethasone and these effects were statistically significant compared to that of sulfur mustard -exposed group (160).

#### *Toluene*

Toluene administration induced pulmonary toxicity in rats as indicated by severe inflammatory cell infiltration, alveolar obstruction, significant edema, and alveolar hemorrhage, while TQ co-administration significantly improved these changes. TQ also markedly reduced the number of iNOS-positive and apoptotic cells (145).

#### *Bleomycin*

It was reported that TQ significantly reversed bleomycin-induced depletion of the GSH and elevation in the level of lipid peroxide and the activity of antioxidant enzymes; such as GPx and GST in rat's lung tissue. The possible way of action is superoxide radical scavenging because TQ is as effective as superoxide dismutase against superoxide (161).

#### *Protective effects of black seed against chemical induced hematotoxicity*

##### *Metals*

##### *Cadmium (Cd)*

Cadmium treatment induces hematotoxicity indicated by decrease in red blood cell (RBC) and white blood cell (WBC) counts, packed cell volume (PCV), hemoglobin (Hb) concentration, and neutrophil percentage. Demir *et al.* reported that *N. sativa* extract increased these lowered markers except WBC count (162). In another study, remarkable membrane destruction and hemolytic changes in Cd-treated rat's erythrocytes were observed, while *N. sativa* co-

treatment lessened these damages and decreased the Cd-induced oxidative stress (163).

#### *Aluminium (Al)*

A study by Bouasla *et al.* (2014) demonstrated that Al exhibited some hematological damages such as an increase in WBC counts and a marked decrease in erythrocyte counts and Hb content. Moreover, raise of erythrocyte MDA level was associated with a decrease in GSH content, GPS, SOD, and catalase. However, administration of *N. sativa* oil with AlCl<sub>3</sub> improved all changes of mentioned parameters (49).

#### *Cisplatin*

It was revealed that *N. sativa* seed extract protected rats against cisplatin-induced decrease in hemoglobin levels and leucocyte counts (164).

#### *Carbon tetrachloride (CCl<sub>4</sub>)*

It was reported that CCl<sub>4</sub> causes significant changes in the haematological parameters and morphological characterizes of peripheral blood cells which included both nucleus and cytoplasm in albino mice. Co-treatment of *N. sativa* aqueous suspension with CCl<sub>4</sub> ameliorated these alterations (165).

#### *Acetaminophen*

It was revealed that decrease in RBC numbers and Hb level as well as increase in WBC numbers and TNF- $\alpha$  level were observed in acetaminophen treated mice. Coadministration of *N. sativa* extract with acetaminophen ameliorated hematotoxicity and immunotoxicity was induced by acetaminophen (166).

### **Conclusion**

Recently, several natural plants and their active constituents have been used in various studies with the aim to prevent toxicities in different tissues induced by natural or chemical toxicants. The availability, lower price, and less toxic effects of herbal compounds compared with synthetic make them as simple and excellent choice in the prevention of toxicities. This review article summarized different *in-vitro* and *in-vivo* studies in order to find out the role of *N. sativa* and its active constituent, TQ, in prevention against toxicities induced by natural

or chemical toxins in different tissues.

Based on the results of some important investigations, *N. sativa* and its active constituent, TQ, act as an antidote in different intoxications induced by natural toxins including mycotoxins and endotoxins. Some chemicals induced toxicities which have been prevented by *N. sativa* and its active constituent, TQ, include metals (Al, lead, mercury and cadmium), pesticides (imidacloprid, propoxur, acetamiprid, chlorpyrifos, fenitrothion), solvents and detergents (ethanol, CCl<sub>4</sub>, toluene, nitrilotriacetate) and environmental pollutants (DEP, BPA). Furthermore, *N. sativa* as well as TQ could protect different tissues against some drugs overdose including analgesics, anticancer, immunosuppressive, antibiotics, antiretroviral, and antiseizures. Some mechanisms including antioxidant, anti-inflammatory, free radical scavenging, improvement in the disturbed levels of biochemical markers, modulation of antioxidant defense systems, inhibition of apoptosis and regulatory effects on genes expression, and different signaling pathways are involved in *N. sativa* antidotal effects. According to this review, *N. sativa* has also ability to protect potentially different tissues and organs including liver, kidney, heart, blood, brain, lung, gastrointestinal, and reproductive system against chemical toxins. In conclusion, based on the current review, *N. sativa* has a broad spectrum of protective activities against toxicities induced by either natural or chemical toxicants (Table 1, Figure 1). Since these findings have not yet been established by clinical trials on humans, to verify the antidotal effects of *N. sativa* in human intoxications, human trials should be carried out.

### **References**

- (1) Gilani A, Jabeen Q and Ullah khan M. A review of medicinal uses and pharmacological activities of *Nigella sativa*. *Pakistan J. Biol. sci.* (2004) 7:441-51.
- (2) Rajsekhar S and Kuldeep B. Pharmacognosy and pharmacology of *Nigella sativa*- A review. *Int. Res. J. Pharm.* (2011) 2: 36-9.
- (3) Ziaee T, Moharreri N and Hosseinzadeh H. Review of pharmacological and toxicological effects of *Nigella sativa* and its active constituents. *J. Med. Plants* (2012) 11: 16-42.
- (4) Benhaddou-Andaloussi A, Martineau L and Vuong T. The *in-vivo* antidiabetic activity of *Nigella sativa*



- is mediated through activation of the AMPK pathway and increased muscle Glut4 content. *Evid. Based Complement. Alternat. Med.* (2011) 2011: 538671.
- (5) Razavi BM and Hosseinzadeh H. A review of the effects of *Nigella sativa* L. and its constituent, thymoquinone, in metabolic syndrome. *J. Endocrinol. Invest.* (2014) 37: 1031-1040.
  - (6) Barron J, Benghuzzi H and Tucci M. Effects of thymoquinone and selenium on the proliferation of MG 63 cells in tissue culture. *Biomed. Sci. Instrum.* (2008) 44: 434-40.
  - (7) Swamy S and Tan B. Cytotoxic and immunopotentiating effects of ethanolic extract of *Nigella sativa* seeds. *J. Ethnopharmacol.* (2000) 70: 1-7.
  - (8) Hajhashemi V, Ghannadi A and Jafarabadi H. Black cumin seed essential oil, as a potent analgesic and antiinflammatory drug. *Phytother. Res.* (2004) 18: 195-9.
  - (9) Hosseinzadeh H, Fazly Bazzaz BS and Haghi MM. Antibacterial activity of total extracts and essential oil of *Nigella sativa* L. seeds in mice. *Pharmacologyonline* (2007) 2: 429-35.
  - (10) Keyhanmanesh R, Bagban H, Nazemiyeh H, Mirzaei Babil F, Alipour M and Ahmady M. The relaxant effects of different methanolic fractions of *Nigella sativa* on Guinea pig tracheal chains. *Iran. J. Basic Med. Sci.* (2013) 16: 123-8.
  - (11) Boskabady M, Shirmohammadi B, Jandaghi P and Kiani S. Possible mechanism(s) for relaxant effect of aqueous and macerate extracts from *Nigella sativa* on tracheal chains of guinea pig. *BMC Pharmacol.* (2004) 4: 3.
  - (12) Nagi MN, Alam K, Badary OA, Al-Shabanah OA, Al-Sawaf HA and Al-Bekairi AM. Thymoquinone protects against carbon tetrachloride hepatotoxicity in mice via an antioxidant mechanism. *Biochem. Mol. Biol. Int.* (1999) 47: 153-9.
  - (13) Mollazadeh H and Hosseinzadeh H. The protective effect of *Nigella sativa* against liver injury: A review. *Iran. J. Basic Med. Sci.* (2014) 17: 958-966.
  - (14) Hosseinzadeh H and Montahaei R. Protective effect of *Nigella sativa* L. extracts and thymoquinone, its active constituent, on renal ischemia reperfusion induced oxidative damage in rats. *Pharmacologyonline* (2007) 1: 176-89.
  - (15) Aziz Dollah M, Parhizkar S and Izwan M. Effect of *Nigella sativa* on the kidney function in rats. *Avicenna J. Phytomed.* (2013) 3: 152-8.
  - (16) Havakhah H, Sadeghnia HR, Hajzadeh MAR, Roshan NM, Shafiee S and Hosseinzadeh H. Effect of *Nigella sativa* on ischemia-reperfusion induced rat kidney damage. *Iran. J. Basic Med. Sci.* (2014) 17: 986-992.
  - (17) Kanter M, Demir H, Karakaya C and Ozbek H. Gastroprotective activity of *Nigella sativa* L oil and its constituent, thymoquinone against acute alcohol-induced gastric mucosal injury in rats. *World J. Gastroenterol.* (2005) 11: 6662-6.
  - (18) Hosseinzadeh H, Parvardeh S, Asl MN, Sadeghnia HR and Ziaee T. Effect of thymoquinone and *Nigella sativa* seeds oil on lipid peroxidation level during global cerebral ischemia-reperfusion injury in rat hippocampus. *Phytomedicine* (2007) 14: 621-7.
  - (19) Nergiz C and Otles S. Chemical composition of *Nigella sativa* L. seeds. *Food Chem.* (1993) 48: 259-61.
  - (20) Ghosheh OA, Houdi AA and Crooks PA. High performance liquid chromatographic analysis of the pharmacologically active quinones and related compounds in the oil of the black seed (*Nigella sativa* L.). *J. Pharm. Biomed. Anal.* (1999) 19: 757-62.
  - (21) Amin B, Taheri MMH and Hosseinzadeh H. Effects of intraperitoneal thymoquinone on chronic neuropathic pain in rats. *Planta Medica* (2014) 80: 1269-1277.
  - (22) Hosseinzadeh H, Eskandari M and Ziaee T. Antitussive effect of thymoquinone, a constituent of *Nigella sativa* seeds, in guinea pigs. *Pharmacologyonline* (2008) 2: 480-484.
  - (23) Leong XF, Rais Mustafa M and Jaarin K. *Nigella sativa* and its protective role in oxidative stress and hypertension. *Evid. Based Complement. Altern. Med.* (2013) 2013:120732.
  - (24) Kanter M, Meral I and Yener Z. Partial regeneration/proliferation of the beta-cells in the islets of Langerhans by *Nigella sativa* L. in streptozotocin-induced diabetic rats. *Tohoku J. Exp. Med.* (2003) 201: 213-9.
  - (25) Rakhshandeh H, Vahdati-Mashhadian NandKhajekaramadini M. In-vitro and in-vivo study of the antibacterial effects of *Nigella sativa* methanol extract in dairy cow mastitis. *Avicenna J. Phytomed.* (2011) 1: 29-35.
  - (26) Koka P, Mondal D, Schultz M, Abdel-Mageed AandAgrawal K. Studies on molecular mechanisms of growth inhibitory effects of thymoquinone against prostate cancer cells: role of reactive oxygen species. *Exp. Biol. Med.* (2010) 235: 751-60.
  - (27) Hosseinzadeh H, Parvardeh S, Nassiri-Asl M and Mansouri M-T. Intracerebroventricular administration of thymoquinone, the major constituent of *Nigella sativa* seeds, suppresses epileptic seizures in rats. *Med. Sci. Monitor* (2005) 11: BR106-BR10.
  - (28) Parvardeh S, Nassiri-Asl M, Mansouri MT and Hosseinzadeh H. Study on the anticonvulsant activity of thymoquinone, the major constituent of *Nigella sativa* L. seeds, through intracerebroventricular injection. *J. Med. Plants* (2005) 4: 45-52.
  - (29) Mehri S, Shahi M, Razavi BM, Hassani FV and Hosseinzadeh H. Neuroprotective effect of thymoquinone in acrylamide induced neurotoxicity in wistar rats. *Iran. J. Basic Med. Sci.* (2014) 17: 1007-1011.
  - (30) Nagi M and Mansouru M. Protective effect of thymoquinone against doxorubicin induced cardiotoxicity in rats: a possible mechanism of protection. *Pharm. Res.* (2000) 41: 283-9.
  - (31) Boskabady M and Farhadi F. The possible prophylactic effect of *Nigella sativa* seed extract on respiratory symptoms, pulmonary function tests on chemical war victims. *J. Alt. Comple. Med.* (2008) 14: 1137-44.

- (32) Hosseinzadeh H, Taiari S and Nassiri-Asl M. Effect of thymoquinone, a constituent of *Nigella sativa* L., on ischemia-reperfusion in rat skeletal muscle. *Arch Pharmacol.* (2012) 385: 503-508.
- (33) Nili-Ahmadabadi A, Tavakoli F, Hasanzadeh G, Rahimi H and Sabzevari O. Protective effect of pretreatment with thymoquinone against Aflatoxin B(1) induced liver toxicity in mice. *Daru* (2011) 19: 282-7.
- (34) Abdel-Wahhab MA and Aly SE. Antioxidant property of *Nigella sativa* (black cumin) and *Syzygium aromaticum* in rats during aflatoxicosis. *J. Appl. Toxicol.* (2005) 25: 218-23.
- (35) Mohamed saleem Gani A and Ahmed John S. Evaluation of hepatoprotective effect of *Nigella sativa* L. *Int. J. Pharm. Pharm. Sci.* (2013) 5: 428-30.
- (36) Helal GK. Thymoquinone supplementation ameliorates acute endotoxemia-induced liver dysfunction in rats. *Pakistan J. Pharm. Sci.* (2010) 23: 131-7.
- (37) El-Sawi NM and Gashlan HM. Effect of *Nigella sativa* oil and activated charcoal as antioxidant on verrucarin J induced hepatotoxicity in male rats. *J. Appl. Animal Res.* (2010) 37: 285-8.
- (38) Alkharfy KM, Al-Daghri NM, Al-Attas OS and Alokail MS. The protective effect of thymoquinone against sepsis syndrome morbidity and mortality in mice. *Int. Immunopharmacol.* (2011) 11: 250-4.
- (39) Koehler PE, Hanlin RT and Beraha L. Production of aflatoxins B1 and G1 by *Aspergillus flavus* and *Aspergillus parasiticus* isolated from market pecans. *Appl. Microbiol.* (1975) 30: 581-3.
- (40) Questy SY. Efficacy of activated charcoal in the reduction of hepatotoxic effects of verrucarin J in mice. *Eur. J. Biol. Sci.* (2010) 3: 01-5.
- (41) Barton CC, Barton EX, Ganey PE, Kunkel SL and Roth RA. Bacterial lipopolysaccharide enhances aflatoxin B1 hepatotoxicity in rats by a mechanism that depends on tumor necrosis factor alpha. *Hepatology* (2001) 33: 66-73.
- (42) Belyaeva EA, Glazunov VV, Nikitina ER and Korotkov SM. Bivalent metal ions modulate Cd<sup>2+</sup> effects on isolated rat liver mitochondria. *J. Bioenerg. Biomembr.* (2001) 33: 303-18.
- (43) Zafeer MF, Waseem M, Chaudhary S and Parvez S. Cadmium-induced hepatotoxicity and its abrogation by thymoquinone. *J. Biochem. Mol. Toxicol.* (2012) 26: 199-205.
- (44) Verstraeten SV, Aimo L and Oteiza PI. Aluminium and lead: molecular mechanisms of brain toxicity. *Arch. Toxicol.* (2008) 82: 789-802.
- (45) Guo CH, Hsu GS, Chuang CJ and Chen PC. Aluminum accumulation induced testicular oxidative stress and altered selenium metabolism in mice. *Env. Toxicol. Pharmacol.* (2009) 27: 176-81.
- (46) Kumar V, Bal A and Gill KD. Susceptibility of mitochondrial superoxide dismutase to aluminium induced oxidative damage. *Toxicology* (2009) 255: 117-23.
- (47) El-Demerdash FM. Antioxidant effect of vitamin E and selenium on lipid peroxidation, enzyme activities and biochemical parameters in rats exposed to aluminium. *J. Trace Elem. Med. Biol.* (2004) 18: 113-21.
- (48) Turkez H, Yousef MI and Geyikoglu F. Propolis prevents aluminium-induced genetic and hepatic damages in rat liver. *Food Chem. Toxicol.* (2010) 48: 2741-6.
- (49) Bouasla I, Bouasla A, Boumendjel A, Messarah M, Abdennour C and Boulakoud MS. *Nigella sativa* oil reduces aluminium chloride-induced oxidative injury in liver and erythrocytes of rats. *Biol. Trace Elem. Res.* (2014) 162: 252-61.
- (50) Damek-Poprawa M and Sawicka-Kapusta K. Histopathological changes in the liver, kidneys, and testes of bank voles environmentally exposed to heavy metal emissions from the steelworks and zinc smelter in Poland. *Env. Res.* (2004) 96: 72-8.
- (51) Farrag AR, Mahdy KA, Abdel Rahman GH and Osfor MM. Protective effect of *Nigella sativa* seeds against lead-induced hepatorenal damage in male rats. *Pakistan J. Biol. Sci.* (2007) 10: 2809-16.
- (52) Mitchell JR, Long MW, Thorgeirsson UP and Jollow DJ. Acetylation rates and monthly liver function tests during one year of isoniazid preventive therapy. *Chest* (1975) 68: 181-90.
- (53) Tostmann A, Boeree MJ, Aarnoutse RE, de Lange WC, van der Ven AJ and Dekhuijzen R. Antituberculosis drug-induced hepatotoxicity: concise up-to-date review. *J. Gastroenterol. Hepatol.* (2008) 23: 192-202.
- (54) Hassan AS, Ahmed JH and Al-Haroon SS. A study of the effect of *Nigella sativa* (Black seeds) in isoniazid (INH)-induced hepatotoxicity in rabbits. *Indian J. Pharmacol.* (2012) 44: 678-82.
- (55) Nelson ML and Levy SB. The history of the tetracyclines. *Ann. NY Acad. Sci.* (2011) 1241: 17-32.
- (56) Naseer F and Alam M. The protective effect of ascorbic acid on oxytetracycline induced nephrotoxicity and hepatotoxicity. *J. Pak. Med. Assoc.* (1987) 37: 73-5.
- (57) Polec RB, Yeh SD and Shils ME. Protective effect of ascorbic acid, isoascorbic acid and mannitol against tetracycline-induced nephrotoxicity. *J. Pharmacol. Exp. Ther.* (1971) 178: 152-8.
- (58) Abdel-Daim MM and Ghazy EW. Effects of *Nigella sativa* oil and ascorbic acid against oxytetracycline-induced hepato-renal toxicity in rabbits. *Iran. J. Basic Med. Sci.* (2015) 18: 221-7.
- (59) Lebwahl D and Canetta R. Clinical development of platinum complexes in cancer therapy: an historical perspective and an update. *Eur. J. Cancer* (1998) 34: 1522-34.
- (60) Pugh CW and Ratcliffe PJ. Regulation of angiogenesis by hypoxia: role of the HIF system. *Nat. Med.* (2003) 9: 677-84.
- (61) Kumari KK and Setty OH. Protective effect of *Phyllanthus fraternus* against mitochondrial dysfunction induced by co-administration of cisplatin

- and cyclophosphamide. *J. Bioenerg. Biomembr.* (2012) 44: 179-88.
- (62) Al-Malki AL and Sayed AAR. Thymoquinone attenuates cisplatin-induced hepatotoxicity via nuclear factor kappa-  $\beta$ . *BMC Complement. Altern. Med.* (2014) 14.
- (63) King PD and Perry MC. Hepatotoxicity of chemotherapy. *Oncologist* (2001) 6: 162-76.
- (64) Labib R, Hafez H and Badary O. *Nigella sativa* oil ameliorates methotrexate-induced liver toxicity. *Eur. J. Cancer* (2011) 47: S119.
- (65) Hagag AA, AbdElaal AM, Elfaragy MS, Hassan SM and Elzamarany EA. Therapeutic value of black seed oil in methotrexate hepatotoxicity in Egyptian children with acute lymphoblastic leukemia. *Infect. Disord. Drug Targets* (2015) 15: 64-71.
- (66) El-Sheikh AA, Morsy MA, Abdalla AM, Hamouda AH and Alhaider IA. Mechanisms of thymoquinone hepatorenal protection in methotrexate-induced toxicity in rats. *Mediat. Inflamm.* (2015) 2015: 859383.
- (67) Murphy KT, Wardak A, Beckett MA, Lopez CA, Mehta N and Kimchi E. Forphenicidinol enhances the antitumor effects of cyclophosphamide in a model of squamous cell carcinoma. *Cancer Chem. Pharmacol.* (2005) 56: 317-21.
- (68) Mitchell DC, Niu SL and Litman BJ. Enhancement of G protein-coupled signaling by DHA phospholipids. *Lipids* (2003) 38: 437-43.
- (69) Alenzi FQ, El-Bolkiny Yel S and Salem ML. Protective effects of *Nigella sativa* oil and thymoquinone against toxicity induced by the anticancer drug cyclophosphamide. *Br. J. Biomed. Sci.* (2010) 67: 20-8.
- (70) Dunn BK, Wickerham DL and Ford LG. Prevention of hormone-related cancers: breast cancer. *J. Clin. Oncol.* (2005) 23: 357-67.
- (71) Jordan VC. Tamoxifen: a most unlikely pioneering medicine. *Nat. Rev. Drug Disc.* (2003) 2: 205-13.
- (72) Ahotupa M, Hirsimaki P, Parssinen R and Mantyla E. Alterations of drug metabolizing and antioxidant enzyme activities during tamoxifen-induced hepatocarcinogenesis in the rat. *Carcinogenesis* (1994) 15: 863-8.
- (73) Caballero F, Gerez E, Oliveri L, Falcoff N, Batlle A and Vazquez E. On the promoting action of tamoxifen in a model of hepatocarcinogenesis induced by *p*-dimethylaminoazobenzene in CF1 mice. *Int. J. Biochem. Cell. Biol.* (2001) 33: 681-90.
- (74) Dragan YP, Fahey S, Nuwaysir E, Sattler C, Babcock K and Vaughan J. The effect of tamoxifen and two of its non-isomerizable fixed-ring analogs on multistage rat hepatocarcinogenesis. *Carcinogenesis* (1996) 17: 585-94.
- (75) Williams GM, Iatropoulos MJ and Karlsson S. Initiating activity of the anti-estrogen tamoxifen, but not toremifene in rat liver. *Carcinogenesis* (1997) 18: 2247-53.
- (76) Suddek GM. Protective role of thymoquinone against liver damage induced by tamoxifen in female rats. *Canadian J. Physiol. Pharmacol.* (2014) 92: 640-4.
- (77) Tomizawa M and Casida JE. Neonicotinoid insecticide toxicology: mechanisms of selective action. *Annu. Rev. Pharmacol. Toxicol.* (2005) 45: 247-68.
- (78) Mohany M, El-Feki M, Refaat I, Garraud O and Badr G. Thymoquinone ameliorates the immunological and histological changes induced by exposure to imidacloprid insecticide. *J. Toxicol. Sci.* (2012) 37: 1-11.
- (79) Chenery R, George M and Krishna G. The effect of ionophore A23187 and calcium on carbon tetrachloride-induced toxicity in cultured rat hepatocytes. *Toxicol. Appl. Pharm.* (1981) 60: 241-52.
- (80) Stacey NandPriestly BG. Lipid peroxidation in isolated rat hepatocytes: relationship to toxicity of CCl<sub>4</sub>, ADP/Fe<sup>3+</sup>, and diethyl maleate. *Toxicol. Appl. Pharmacol.* (1978) 45: 41-8.
- (81) Mansour MA. Protective effects of thymoquinone and desferrioxamine against hepatotoxicity of carbon tetrachloride in mice. *Life Sci.* (2000) 66: 2583-91.
- (82) Jaswal A and Shukla S. Therapeutic efficacy of *Nigella sativa* Linn. seed extract against CCl<sub>4</sub> induced hepatic injury in Wistar rats. *Indian J. Exp. Biol.* (2015) 53: 44-50.
- (83) Bellomo G, Jewell SA, Thor H and Orrenius S. Regulation of intracellular calcium compartmentation: studies with isolated hepatocytes and *t*-butyl hydroperoxide. *Proc. Natl. Acad. Sci. U.S.A.* (1982) 79: 6842-6.
- (84) Rush GF and Alberts D. *tert*-Butyl hydroperoxide metabolism and stimulation of the pentose phosphate pathway in isolated rat hepatocytes. *Toxicol. Appl. Pharmacol.* (1986) 85: 324-31.
- (85) Daba MH and Abdel-Rahman MS. Hepatoprotective activity of thymoquinone in isolated rat hepatocytes. *Toxicol. let.* (1998) 95: 23-9.
- (86) Develi S, Evran B, Betul Kalaz E, Kocak-Toker N and Erata GO. Protective effect of *Nigella sativa* oil against binge ethanol-induced oxidative stress and liver injury in rats. *Chinese J. Nat. Med.* (2014) 12: 495-9.
- (87) Pourbakhsh H, Taghiabadi E, Abnous K, Hariri AT, Hosseini SM and Hosseinzadeh H. Effect of *Nigella sativa* fixed oil on ethanol toxicity in rats. *Iran. J. Basic Med. Sci.* (2014) 17: 1020-31.
- (88) Blaszczyk I, Birkner E and Kasperczyk S. Influence of methionine on toxicity of fluoride in the liver of rats. *Biol. Trace Elem. Res.* (2011) 139: 325-31.
- (89) Nabavi SM, Nabavi SF, Eslami Sand Moghaddam AH. *In-vivo* protective effects of quercetin against sodium fluoride-induced oxidative stress in the hepatic tissue. *Food Chem.* (2012) 132: 931-5.
- (90) Abdel-Wahab WM. Protective effect of thymoquinone on sodium fluoride-induced hepatotoxicity and oxidative stress in rats. *J. Basic Appl. Zool.* (2013) 66: 263-70.
- (91) Rubin BS. Bisphenol A: an endocrine disruptor with widespread exposure and multiple effects. *J. Steroid*

- Biochem. Mol. Biol.* (2011) 127: 27-34.
- (92) Bindhumol V, Chitra KC and Mathur PP. Bisphenol A induces reactive oxygen species generation in the liver of male rats. *Toxicology* (2003) 188: 117-24.
- (93) Nakagawa Y and Tayama S. Metabolism and cytotoxicity of bisphenol A and other bisphenols in isolated rat hepatocytes. *Arch.Toxicol.* (2000) 74: 99-105.
- (94) Abdel-Wahab WM. Thymoquinone attenuates toxicity and oxidative stress induced by bisphenol A in liver of male rats. *Pakistan J. Biol. Sci.* (2014) 17: 1152-60.
- (95) Mitchell JR, Jollow DJ, Potter WZ, Gillette JR and Brodie BB. Acetaminophen-induced hepatic necrosis. IV. Protective role of glutathione. *J. Pharmacol. Exp. Ther.* (1973) 187: 211-7.
- (96) Jaeschke H and Bajt ML. Intracellular signaling mechanisms of acetaminophen-induced liver cell death. *Toxicol. Sci.* (2006) 89: 31-41.
- (97) Najafzadeh H, Rezaei A, Masoodi AM and Mehrzadi S. Comparison of the effect of vanadium and deferoxamine on acetaminophen toxicity in rats. *Indian J. Pharmacol.* (2011) 43: 429-32.
- (98) Nagi MN, Almakki HA, Sayed-Ahmed MM and Al-Bekairi AM. Thymoquinone supplementation reverses acetaminophen-induced oxidative stress, nitric oxide production and energy decline in mice liver. *Food Chem. Toxicol.* (2010) 48: 2361-5.
- (99) Aycan IO, Tufek A, Tokgoz O, Evliyaoglu O, Firat U and Kavak GO. Thymoquinone treatment against acetaminophen-induced hepatotoxicity in rats. *Int. J. Surg.* (2014) 12: 213-8.
- (100) Kushwah DS, Salman MT, Singh P, Verma VK and Ahmad A. Protective effects of ethanolic extract of *Nigella sativa* seed in paracetamol induced acute hepatotoxicity *in-vivo*. *Pakistan J.Biol. Sci.* (2014) 17: 517-22.
- (101) Raza M, Alghasham AA, Alorainy MS and El-Hadiyah TM. Beneficial interaction of thymoquinone and sodium valproate in experimental models of epilepsy: Reduction in hepatotoxicity of valproate. *Sci. Pharm.* (2006) 74: 159-73.
- (102) Abdallah M and Kelany M. Life science journal. *Life Sci.* (2014) 11: 26-33.
- (103) Reisler K. High hepatotoxicity rate seen among HAART patients. *AIDS Alert* (2001) 16: 118-9.
- (104) Mudie K, Seifu D, Challa F, Abebe A, Debella A and Gebregzabher A. Hepatoprotective activity of aqueous seed extract of *Nigella sativa* against highly active antiretroviral therapy induced hepatotoxicity in rats. *PharmacologyOnline* (2014) 3: 11-21.
- (105) Abdelaiz I and Kandeel M. The protective effects of *Nigella sativa* oil and *Allium sativum* extracts on Amikacin-induced nephrotoxicity. *Int. J. Pharmacol.* (2011) 7: 697-703.
- (106) Ali BH. The effect of *Nigella sativa* oil on gentamicin nephrotoxicity in rats. *Am. J. Chin. Med.* (2004) 32: 49-55.
- (107) Sayed-Ahmed MM and Nagi MN. Thymoquinone supplementation prevents the development of gentamicin-induced acute renal toxicity in rats. *Clin. Exp. Pharmacol. Physiol.* (2007) 34: 399-405.
- (108) Yaman I and Balikci E. Protective effects of *nigella sativa* against gentamicin-induced nephrotoxicity in rats. *Exp. Toxicol. Pathol.* (2010) 62: 183-90.
- (109) Saleem U, Ahmad B, Rehman K, Mahmood S, Alam M and Erum A. Nephro-protective effect of vitamin C and *Nigella sativa* oil on gentamicin associated nephrotoxicity in rabbits. *Pak. J. Pharm. Sci.* (2012) 25: 727-30.
- (110) Ragheb A, Attia A, Eldin WS, Elbarbry F, Gazarin S and Shoker A. The protective effect of thymoquinone, an anti-oxidant and anti-inflammatory agent, against renal injury: a review. *Saudi J. Kidney Dis. Transpl.* (2009) 20: 741-52.
- (111) Basarslan F, Yilmaz N, Ates S, Ozgur T, Tutanc M and Motor VK. Protective effects of thymoquinone on vancomycin-induced nephrotoxicity in rats. *Hum. Exp. Toxicol.* (2012) 31: 726-33.
- (112) Elsherbiny N and El-Sherbiny M. Thymoquinone attenuates Doxorubicin-induced nephrotoxicity in rats: Role of Nrf2 and NOX4. *Chem. Biol. Inter.* (2014) 223C: 102-8.
- (113) Badary OA, Abdel-Naim AB, Abdel-Wahab MH and Hamada FM. The influence of thymoquinone on doxorubicin-induced hyperlipidemic nephropathy in rats. *Toxicology* (2000) 143: 219-26.
- (114) Ulu R, Dogukan A, Tuzcu M, Gencoglu H, Ulas M and Ilhan N. Regulation of renal organic anion and cation transporters by thymoquinone in cisplatin induced kidney injury. *Food. Chem. Toxicol.* (2012) 50: 1675-9.
- (115) Ulu R, Dogukan A, Tuzcu M, Gurel A, Muqbil I and Mohammad RM. Modulation of Nrf2/HO-1 by thymoquinone during cisplatin-induced nephrotoxicity. *Turkish Nephrol. Dial. Transpl. J.* (2013) 22: 182-7.
- (116) Hadjzadeh MA, Keshavarzi Z, Tabatabaee Yazdi SA, Ghasem Shirazi M, Rajaei Z and Khajavi Rad A. Effect of alcoholic extract of *Nigella sativa* on cisplatin-induced toxicity in rat. *Iran. J. Kidney Dis.* (2012) 6: 99-104.
- (117) Ali BH, Al Za'abi M, Shalaby A, Manoj P, Waly MI and Yasin J. The effect of thymoquinone treatment on the combined renal and pulmonary toxicity of cisplatin and diesel exhaust particles. *Exp. Biol. Med.* (2015) 240: 1698-707.
- (118) Hall AM, Bass P and Unwin RJ. Drug-induced renal Fanconi syndrome. *Q. J. Med.* (2014) 107: 261-9.
- (119) Badary OA. Thymoquinone attenuates ifosfamide-induced Fanconi syndrome in rats and enhances its antitumor activity in mice. *J. Ethnopharmacol.* (1999) 67: 135-42.
- (120) Hamed MA, El-Rigal NS and Ali SA. Effects of black seed oil on resolution of hepato-renal toxicity induced by bromobenzene in rats. *Eur. Rev. Med. Pharmacol. Sci.* (2013) 17: 569-81.
- (121) Anderson RL, Bishop WE and Campbell RL.

- A review of the environmental and mammalian toxicology of nitrilotriacetic acid. *Crit. Rev. Toxicol.* (1985) 15: 1-102.
- (122) Khan N and Sultana S. Inhibition of two stage renal carcinogenesis, oxidative damage and hyperproliferative response by *Nigella sativa*. *Eur. J. Cancer Prev.* (2005) 14: 159-68.
- (123) Uz E, Bayrak O, Uz E, Kaya A, Bayrak R and Uz B. *Nigella sativa* oil for prevention of chronic cyclosporine nephrotoxicity: an experimental model. *Am. J. Nephrol.* (2008) 28: 517-22.
- (124) Fouda AM, Daba MH, Dahab GM and Sharaf El-Din OA. Thymoquinone ameliorates renal oxidative damage and proliferative response induced by mercuric chloride in rats. *Basic Clin. Pharmacol. Toxicol.* (2008) 103: 109-18.
- (125) Mazer M and Perrone J. Acetaminophen-induced nephrotoxicity: pathophysiology, clinical manifestations, and management. *J. Med. Toxicol.* (2008) 4: 2-6.
- (126) Aycan IO, Tokgoz O, Tufek A, Alabalik U, Evliyaoglu O, Turgut H, Celik F and Guzel A. The use of thymoquinone in nephrotoxicity related to acetaminophen. *Int. J. Surg.* (2015) 13: 33-7.
- (127) Hamza RZ and Al-Harbi MS. Silymarin and *Nigella sativa* extract ameliorate paracetamol induced oxidative stress and renal dysfunction in male mice. *Asian Pac. J. Trop. Dis.* (2015) 1: S169-S74.
- (128) Radad K, Hassanein K, Al-Shraim M, Moldzio R and Rausch WD. Thymoquinone ameliorates lead-induced brain damage in Sprague Dawley rats. *Exp. Toxicol. Pathol.* (2014) 66: 13-7.
- (129) Kamal I and Kamal H. Effects of aluminum on rat cerebellar cortex and the possible protective role of *Nigella sativa*: A light and electron microscopic study. *Egyptian J. Histol.* (2013) 36: 979-90.
- (130) Sagit M, Korkmaz F, Gurgun SG, Kaya M, Akcadag A and Ozcan I. The protective role of thymoquinone in the prevention of gentamicin ototoxicity. *Am. J. Otolaryngol.* (2014) 35: 603-9.
- (131) Ullah I, Ullah N, Naseer MI, Lee HY and Kim MO. Neuroprotection with metformin and thymoquinone against ethanol-induced apoptotic neurodegeneration in prenatal rat cortical neurons. *BMC Neurosci.* (2012) 13: 11.
- (132) Kanter M. Protective effects of thymoquinone on the neuronal injury in frontal cortex after chronic toluene exposure. *J. Mol. Histol.* (2011) 42: 39-46.
- (133) Mohamadin AM, Sheikh B, Abd El-Aal AA, Elberry AA and Al-Abbasi FA. Protective effects of *Nigella sativa* oil on propoxur-induced toxicity and oxidative stress in rat brain regions. *Pest. Biochem. Physiol.* (2010) 98: 128-34.
- (134) Sayed MM, Hassanein KMA and Senosy W. Protective effects of thymoquinone and l-cysteine on cadmium-induced reproductive toxicity in rats. *Toxicol. Reports* (2014) 1: 612-20.
- (135) Fouad AA and Jresat I. Thymoquinone therapy abrogates toxic effect of cadmium on rat testes. *Andrologia* (2015) 47: 417-26.
- (136) Mabrouk A and Ben Cheikh H. Thymoquinone supplementation reverses lead-induced oxidative stress in adult rat testes. *Gen. Physiol. Biophys.* (2015) 34: 65-72.
- (137) Gokce A, Oktar S, Koc A and Yonden Z. Protective effects of thymoquinone against methotrexate-induced testicular injury. *Hum. Exp. Toxicol.* (2011) 30: 897-903.
- (138) Awadalla EA. Ameliorative effect of the crude oil of the *Nigella sativa* on oxidative stress induced in rat testes by cisplatin treatment. *Biomed. Prev. Nut.* (2012) 2: 265-8.
- (139) Becker K and Schoneich J. Expression of genetic damage induced by alkylating agents in germ cells of female mice. *Mutat. Res.* (1982) 92: 447-64.
- (140) Kamarzaman S, Abdul Wahab AY and Abdul Rahman S. Effects of thymoquinone supplementation on cyclophosphamide toxicity of mouse embryo *in-vitro*. *Global Veterinaria* (2014) 12: 80-90.
- (141) Rahman SA, Dawood NFS, Basha SS and Kamarzaman S. Protective effect of black seed *Nigella sativa* L. against cyclophosphamide-induced toxicity on reproductive and acrosomal function in mice. *Mid. East J. Sci. Res.* (2013) 17: 955-64.
- (142) Bhatt SA. Physicochemical optimization of Acetamiprid degradation by *Pantoea* species. *Int. J. Chem. Appl.* (2014) 3: 52-62.
- (143) Rachid M, Ibrahim YM and Aziez C. *Nigella sativa* oil protects against reproductive toxicity of acetamiprid insecticide in male rats. *Toxicol. Lett.* (2013) 221: S218.
- (144) Mosbah R, Yousef MI, Maranghi F and Mantovani A. Protective role of *Nigella sativa* oil against reproductive toxicity, hormonal alterations, and oxidative damage induced by chlorpyrifos in male rats. *Toxicol. Ind. Health* (2014) 32: 1266-77.
- (145) Kanter M. Thymoquinone attenuates lung injury induced by chronic toluene exposure in rats. *Toxicol. Ind. Health* (2011) 27: 387-95.
- (146) Elshama SS, Shehab GMG, El-Kenawy AE, Osman H-EH and Farag MM. Role of *Nigella Sativa* Seeds on modulation testicular toxicity of colchicine repeated use in adult albino rats. *Life Sci.* (2013) 10: 1629-39.
- (147) Nagi MN, Al-Shabanah OA, Hafez MM and Sayed-Ahmed MM. Thymoquinone supplementation attenuates cyclophosphamide-induced cardiotoxicity in rats. *J. Biochem. Mol. Toxicol.* (2011) 25: 135-42.
- (148) Al-Shabanah OA, Badary OA, Nagi MN, al-Gharably NM, al-Rikabi AC and al-Bekairi AM. Thymoquinone protects against doxorubicin-induced cardiotoxicity without compromising its antitumor activity. *J. Exp. Clin. Cancer Res.* (1998) 17: 193-8.
- (149) Randhawa MA, Alghamdi MS and Maulik SK. The effect of thymoquinone, an active component of *Nigella sativa*, on isoproterenol induced myocardial injury. *Pakistan J. Pharm. Sci.* (2013) 26: 1215-9.
- (150) Nemmar A, Al-Salam S, Zia S, Marzouqi F, Al-

- Dhaheeri A and Subramaniyan D. Contrasting actions of diesel exhaust particles on the pulmonary and cardiovascular systems and the effects of thymoquinone. *Br. J. Pharmacol.* (2011) 164: 1871-82.
- (151) Ebru U, Burak U, Yusuf S, Reyhan B, Arif K, Faruk TH, Emin M, Aydin K, Lhan Atilla I, Semsettin S and Kemal E. Cardioprotective effects of *Nigella sativa* oil on cyclosporine A-induced cardiotoxicity in rats. *Basic Clin. Pharmacol. Toxicol.* (2008) 103: 574-80.
- (152) El-Saleh SC, Al-Sagair OA and Al-Khalaf MI. Thymoquinone and *Nigella sativa* oil protection against methionine-induced hyperhomocysteinemia in rats. *Int. J. Cardiol.* (2004) 93: 19-23.
- (153) Arslan SO, Gelir E, Armutcu F, Coskun O, Gurel A and Sayan H. The protective effect of thymoquinone on ethanol-induced acute gastric damage in the rat. *Nut. Res.* (2005) 25: 673-80.
- (154) Kanter M, Demir H, Karakaya C and Ozbek H. Gastroprotective activity of *Nigella sativa* L oil and its constituent, thymoquinone against acute alcohol-induced gastric mucosal injury in rats. *World J. Gastroenterol.* (2005) 11: 6662-6.
- (155) Labib R, Badary O and Hafez H. *Nigella sativa* L. oil ameliorates methotrexate-induced intestinal toxicity through antioxidant activity. *Eur. J. Cancer Suppl.* (2009) 7: 106.
- (156) Korany NS and Ezzat BA. Prophylactic effect of green tea and *Nigella sativa* extracts against fenitrothion-induced toxicity in rat parotid gland. *Arch. Oral. Biol.* (2011) 56: 1339-46.
- (157) Jrah-Harzallah H, Ben-Hadj-Khalifa S, Almawi WY, Maaloul A, Houas Z and Mahjoub T. Effect of thymoquinone on 1,2-dimethyl-hydrazine-induced oxidative stress during initiation and promotion of colon carcinogenesis. *Eur. J. Cancer* (2013) 49: 1127-35.
- (158) Borak J and Sidell F. Agents of chemical warfare: sulfur mustard. *Ann. Emerg. Med.* (1992) 21: 303-8.
- (159) Hossein BM, Nasim V and Sediqa A. The protective effect of *Nigella sativa* on lung injury of sulfur mustard-exposed Guinea pigs. *Exp. Lung. Res.* (2008) 34: 183-94.
- (160) Boskabady MH, Vahedi N, Amery S and Khakzad MR. The effect of *Nigella sativa* alone, and in combination with dexamethasone, on tracheal muscle responsiveness and lung inflammation in sulfur mustard exposed guinea pigs. *J. Ethnopharmacol.* (2011) 137: 1028-34.
- (161) Gado AM and Yassen A. Protective effect of thymoquinone and aminoguanidine against bleomycin induced lung damage: Possible role of nitric oxide synthase. *Int. J. Toxicol.* (2011) 8.
- (162) Demir H, Kanter M, Coskun O, Uz YH, Koc A and Yildiz A. Effect of black cumin (*Nigella sativa*) on heart rate, some hematological values, and pancreatic beta-cell damage in cadmium-treated rats. *Biol. Trace Elem. Res.* (2006) 110: 151-62.
- (163) Kanter M, Coskun O and Gurel A. Effect of black cumin (*Nigella sativa*) on cadmium-induced oxidative stress in the blood of rats. *Biol. Trace Elem. Res.* (2005) 107: 277-87.
- (164) Nair SC, Salomi MJ, Panikkar B and Panikkar KR. Modulatory effects of *Crocus sativus* and *Nigella sativa* extracts on cisplatin-induced toxicity in mice. *J. Ethnopharmacol.* (1991) 31: 75-83.
- (165) Essawy AE, Hamed SS, Abdel-Moneim AM, Abou-Gabal AA and Alzergy AA. Role of black seeds (*Nigella sativa*) in ameliorating carbon tetrachloride induced haematotoxicity in Swiss albino mice. *J. Med. Plants Res.* (2010) 4: 1977-86.
- (166) Al-Harbi MS, Hamza RZ and Al-Sofiani TA. Ameliorative roles of silymarin and *Nigella sativa* on hematological parameters and immunological capacities of male mice affected by paracetamol. *Biosci. Biotechnol. Res. Asia* (2015) 12: 379-85.

---

This article is available online at <http://www.ijpr.ir>