

openheart Aortic valve repair techniques: an early UK experience

Renata Greco,¹ Mirko Muretti ,¹ Xu Yu Jin,¹ Mario Petrou²

To cite: Greco R, Muretti M, Jin XY, *et al.* Aortic valve repair techniques: an early UK experience. *Open Heart* 2019;**6**:e001107. doi:10.1136/openhrt-2019-001107

Received 8 June 2019
Revised 9 October 2019
Accepted 14 October 2019

ABSTRACT

Objectives Retrospective review of early results with aortic valve repair (AVr) techniques.

Methods 61 consecutive patients underwent AVr surgery at our institutions between 2008 and 2018. 14 patients had a bicuspid aortic valve and 16 had a connective tissue disorder. In 48 patients, aortic regurgitation (AR) was secondary to an aortic root and/or ascending aneurysms, while in 13 it was due to primary cusp pathologies. 13 patients underwent isolated cusp repair, 19 sinotubular junction remodelling, 25 valve-sparing root replacement (VSRR) and 4 hemirroot replacement. Cusp repair techniques included: 18 free margin plication, 18 commissural re-suspensions, 3 raphe resections and 1 free-edge reinforcement. Subcommissural annuloplasty was performed in 25 patients (42%) with a dilated annulus (>28 mm).

Results 50 patients (82%) left the operating theatre with no AR, 8 with mild central and 3 with mild eccentric AR. In-hospital survival was 100%. Clinical follow-up was complete at 5.08±2.29 years and all patients were alive. Transthoracic echocardiographic follow-up was complete at 2.35±1.92 years and showed the presence of a moderate AR in 10 patients (18%) and severe AR in 2 patients (4%). One of these required re-do aortic valve replacement 6 years after VSRR. Freedom from re-operation at 8 years was 88.15%±1.51%.

Conclusion Good early results are achievable following AVr with acceptable medium-term outcomes. AVr surgery continues to evolve, and concentrating the experience in specialist centres in the UK is recommended.

INTRODUCTION

Aortic valve repair (AVr) is an evolving area, with only few European centres reporting a large volume experience. Despite the introduction of the functional classification of aortic regurgitation (AR) in 2005¹ and the attempts of the experienced centres to standardise surgical valve repair techniques, very few surgical units, especially in the UK, have adopted this approach as an alternative to standard aortic valve replacement even in patients with pure aortic regurgitation.

The aim of this study was to report our early results with AVr techniques carried out by a single experienced aortic surgeon and to provide insights into contemporary UK practice.

Key questions

What is already known about this subject?

- ▶ Aortic valve repair surgery is in its evolutionary phase with only a few large European centres reporting good long-term results.

What does this study add?

- ▶ A real-world experience in aortic valve repair procedures from a UK centre. We report excellent operative results and freedom from re-operation, but with less than perfect valve repair durability.

How might this impact on clinical practice?

- ▶ We recognise the need for the development of a national aortic valve repair service in the UK to concentrate the experience and improve clinical outcomes.

Materials and methods

We retrospectively reviewed 61 patients who underwent aortic valve conserving surgery under a single experienced aortic surgeon (MP). Twenty-three operations were performed at the Royal Brompton Hospital, London, between April 2008 and October 2011 and 38 at the John Radcliffe Hospital, Oxford, between October 2011 and October 2018.

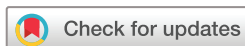Clinical, operative and early outcome data of all patients were collected from the hospital's computerised database (introduced in 2008). All intraoperative details were confirmed by direct review of the surgeon's operative notes and all missing data from direct consultation of the patients' notes.

Statistical analysis

Analysis was conducted with SPSS software, V.16.0 for Windows. Statistical analyses were calculated by measuring the mean±SD for continuous variables, and frequencies were measured for categorical variables. The Kaplan-Meier method was used to plot the freedom from re-operation rate.

Patients

Mean age was 49 years (range 17–85). Fourteen patients had a bicuspid aortic valve and 16 associated syndromic aortic diseases.



© Author(s) (or their employer(s)) 2019. Re-use permitted under CC BY-NC. No commercial re-use. See rights and permissions. Published by BMJ.

¹Department of Cardiothoracic Surgery, John Radcliffe Hospital, Oxford University Hospitals NHS Foundation Trust, Oxford, United Kingdom

²Department of Cardiothoracic Surgery, Royal Brompton and Harefield NHS Foundation Trust, London, UK

Correspondence to
Mr Mario Petrou; M.Petrou@rbht.nhs.uk

Table 1 Preoperative patients' characteristics and echocardiographic data

	Total (61)
Age (years)	48.88±19.26 (range 17–85)
Gender (female)	16 (26.23)
Marfan syndrome	13 (21.31)
Loeys-Diez syndrome	2 (3.28)
Turner syndrome	1 (1.64)
Bicuspid aortic valve	14 (22.95)
Sievers type 0	2
Sievers type Ia	11
Sievers type Ib	1
Urgent	5 (8.20)
Re-do	1 (1.64)
Atrial fibrillation	8 (13.11)
Asymptomatic	40 (65.57)
Primary AR	13 (21.31)
Cusp prolapse	7 (11.48)
Cusp perforation/fenestration	2 (3.28)
Cusp retraction	4 (6.56)
Secondary AR	48 (78.69)
Root±ascending aorta aneurysm	27 (44.26)
Ascending aorta aneurysm	21 (34.43)
Left ventricular function	
Good	54 (88.52)
Moderate	6 (9.84)
Poor	1 (1.64)
AR	
Mild or less	19 (31.15)
Moderate	24 (39.34)
Severe	18 (29.51)
AR jet characteristic	
Central jet	39 (63.93)
Eccentric jet	11 (18.03)
Multiple jets	6 (9.84)

Five patients without preoperative AR.

AR, aortic regurgitation.

In the majority of the patients (79%), the mechanism of AR was aortic root and/or ascending aorta aneurysms (secondary AR), while 13 patients had primary cusp pathologies.

Preoperative patients' characteristics and echocardiographic data are presented in [table 1](#).

Surgical technique

A range of standard repair techniques have been used according to the mechanism of AR as assessed by intraoperative transoesophageal echocardiography (TOE). Thirteen patients underwent isolated aortic cusp repair

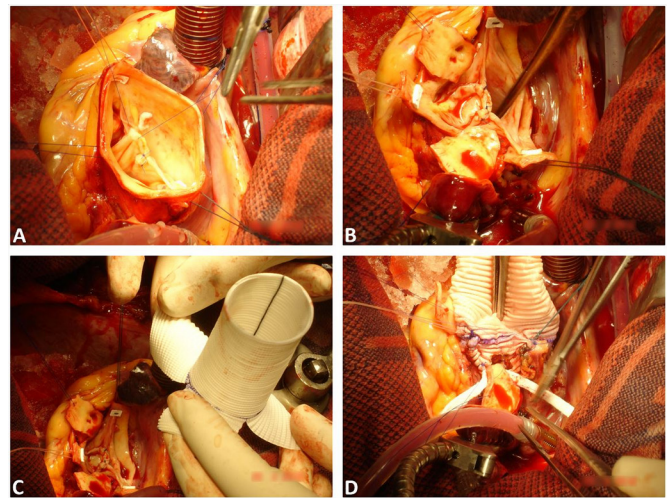


Figure 1 Intraoperative images. Free margin plication and subcommissural annuloplasty in a bicuspid aortic valve (A). Valve-sparing root replacement using remodelling technique with additional cusp repair and subcommissural annuloplasty in a bicuspid aortic valve (B, C, D).

and 19 sinotubular junction (STJ) remodelling with ascending aorta replacement. Twenty-nine had various aortic root procedures.

Twenty-five patients underwent valve-sparing root replacement (VSRR): 24 with the remodelling (Yacoub) and 1 with the reimplantation (David) technique.

Valve cusp repair techniques included: free-edge plication (18 cases), commissural resuspension (18 cases), raphe resection (3 cases) and free-edge reinforcement (1 case). Subcommissural annuloplasty was routinely performed in patients (25 cases, 41%) with dilated annulus (>28mm). Additional free margin plication was required in 5 of the VSRR/STJ remodelling procedures. An example of the applied techniques is displayed in [figure 1](#).

The details of the surgical techniques and intraoperative data are reported in [table 2](#).

RESULTS

Intraoperative outcomes

All patients underwent successful AVr. Mean cardiopulmonary bypass time was 131.39±53.02min and mean cross-clamp time 102.73±44.93. One patient required a second pump run to successfully revise the AVr. Fifty patients (82%) left the operating theatre with no AR, eight patients with mild central and three with mild eccentric AR.

Postoperative outcomes

In-hospital survival was 100%. Two patients suffered a postoperative cerebrovascular accident. No cases required permanent pacemaker. Intensive care and hospital lengths of stay were 2.3±1.7 and 7.6±3.8 days, respectively ([table 3](#)).

Follow-up outcomes

Clinical follow-up was complete at 5.08±2.29 years and all patients were alive. One patient required re-do aortic valve replacement 6 years after a VSRR. This was a patient

Table 2 Surgical techniques and intraoperative data

	Total (61)
Isolated cusp repair	13 (21.3)
Aortic root procedures	29 (47.54)
VSR remodelling	24 (39.34)
VSR reimplantation	1 (1.64)
Hemiroot replacement	4 (6.56)
STJ remodelling	19 (31.15)
Concomitant procedures	13 (21.31)
CABG	3
Hemiarch	3
Mitral valve repair	2
AF ablation	3
Subaortic membrane	1
Reduction aortoplasty	1
CPB time	131.39±53.02
Cross-clamp time	102.73±44.93
DHCA	3 (4.92)
ACP	2 (3.28)
Aortic repair techniques	
Subcommissural annuloplasty	25 (40.98)
Free margin plication	18 (29.51)
Commissural re-suspension	18 (29.51)
Raphe resection	3 (4.92)
Free-edge reinforcement	1 (1.64)
Subcommissural + VSR/STJ remodelling	12 (19.67)
Cusp repair + VSR/STJ remodelling	5 (8.20)

ACP, antegrade cerebral perfusion; AF, atrial fibrillation; CABG, coronary artery bypass graft; CPB, cardio-pulmonary bypass; DHCA, deep hypothermic circulatory arrest; STJ, sinotubular junction; VSR, valve-sparing root.

with Marfan syndrome, referred late to surgery, with a root aneurysm of 55 mm and a dilated left ventricle with poor systolic function.

Table 3 Postoperative outcomes

	Total (61)
Complications (patients)	3 (4.92)
PPM	0
Re-explorations	0
Postoperative MI	1 (1.64)
CVA	2 (3.28)
Upper GI bleeding	1 (1.64)
Ventilatory support (hours)	8.16±5.60
Intensive care LOS (days)	2.29±1.68
Total LOS (days)	7.59±3.78
In-hospital mortality	0

. CVA, cerebrovascular accident; GI, gastrointestinal; LOS, length of stay; MI, myocardial infarction; PPM, permanent pacemaker.

Table 4 Intraoperative transoesophagus and follow-up transthoracic echocardiographic data

	Intraoperative TOE (61)	Follow-up TTE (61)
No/trace AR	50 (81.97)	27 (44.26)
Mild AR	11	22 (40)
Moderate AR	0	10 (18.18)
Severe AR	0	2 (3.64)

AR, aortic regurgitation; TOE, transoesophageal echocardiography; TTE, transthoracic echocardiography.

Freedom from re-operation at 8 years was 88.15%±1.51%, with just three patients observed at 8 years.

Transthoracic echocardiographic follow-up was completed at 2.35±1.92 years and showed the presence of a moderate AR in 10 patients (18%) and severe AR in 2 patients (4%). One of these underwent re-operation and one remains asymptomatic and on clinical follow-up (table 4).

DISCUSSION

AVr is an attractive option to treat patients with pure AR. There are a number of recognised benefits associated with preserving the native aortic valve and avoiding prosthesis-related complications such as thrombosis, endocarditis, bioprosthetic degeneration, mechanical valve dysfunction and haemorrhagic events associated with the life-long anticoagulation treatment. Despite these advantages, however, the long-term benefits of AVr procedures remain to be fully defined. One of the main concerns is related to the durability of the repair, that is, freedom from recurrence of significant AR and the need for a re-operation.²

A recent systematic review compared outcomes of AVr and replacement in patients with aortic regurgitation. In-hospital mortality was 1.3% for the repair and 3.6% for the replacement and 1-year mortality was 3.6% and 8.8%, respectively. Of note however, the re-operation rate at 1 year was higher for AVr (8.8% vs 3.7%).³ Successful long-term outcomes with AVr procedures have been reported by high volume centres and mainly driven by experience with the surgical techniques and the patient selection. Consequently, AVr procedures are currently recommended by the European Society of Cardiology (ESC)/European Association of Cardiothoracic Surgery (EACTS) guidelines in selected patients performed in specialised aortic centres. Valve repair or VSR surgery should be considered in patients with pliable non-calcified tricuspid or bicuspid valves who have a type I (enlargement of the aortic root with normal cusp motion) or type II (cusp prolapse) mechanism of aortic regurgitation. Reimplantation or remodelling with aortic annuloplasty is a Class Ic recommendation

in young patients with aortic root dilation and tricuspid aortic valves, when performed by experienced surgeons.⁴

David *et al*⁵ published the long-term outcomes of 296 consecutive VSRR: survival at 5, 10 and 15 years was 95%, 93% and 76.5%, respectively; freedom from moderate or severe aortic regurgitation at 5, 10 and 15 years was 98%, 93% and 89%, respectively, and just three patients required a re-operation on the aortic valve. Excellent results have also been reported by the most experienced European centres. El Khoury's group reported 85% freedom from re-operation at 10 years after AVr.⁶ Data from the AVIATOR Registry demonstrate a freedom from re-operation at 7 years of 90.5% for aortic root aneurysms, 100% for tubular aortic aneurysm and 97.5% for isolated AR.⁷ A multicentre (four units) German experience with 1015 VSSR procedures showed 90% freedom from aortic valve replacement at 8 years.⁸ A subanalysis performed in 764 patients with echocardiographic follow-up found that one-third of patients left the operating room with some residual AR. Furthermore, 13% of patients without postoperative AR presented with new and significant AR within the first 5 years and that progression of AR was detected in 30% of patients who had left the hospital with mild residual AR. The progression of AR remained stable in 4% of the patients and lead to re-operation in 26%. The main risk factor for new-onset AR was additional cusp repair, while risk factors for mild residual AR were greater aneurysm size and preoperative aortic regurgitation severity.⁹ The Belgian group led by El Khoury also highlight the crucial importance of the TOE in assessing the repair and identified three risk factors for early failure: residual AR, particularly eccentric jet; cusp coaptation below the aortic annulus and a coaptation length <4mm.¹⁰⁶⁷⁸⁹

We presented our UK experience with AVr procedures and our results appear to be in line with the early experience reported from the European aortic centres. We report excellent immediate and early surgical results: no in-hospital mortality, low incidence of complications and short postoperative stay. Over 82% of the patients left the operating theatre with no or trivial AR, 13% with a mild central AR and just three patients with a mild eccentric AR. Despite the good early surgical results, however, echocardiographic follow-up showed a less satisfactory durability of the repair, with 18% of patients having moderate AR and 4% with severe AR. All patients were alive at 5.08±2.29 years clinical follow-up, and the freedom from re-operation at 8 years was 88.15%±1.51%.

One patient required a re-operation 6 years after VSRR. With the benefit of hindsight, we should have been more aggressive in stabilising the aortic annulus of this patient referred late to surgery and consequently had severe annular and left ventricular dilatation. Reports from experienced centres show that suture annuloplasty with polytetrafluoroethylene or ring/band implant is probably associated with better long-term freedom from recurrence of AR when the aortic annulus is severely dilated.^{5 11–13}

As clearly stated in the international guidelines, the choice of the surgical procedure in patients with pure AR should be adapted to patho-anatomical factors (the presence of an aortic root aneurysm and characteristics of the cusps), the experience of the surgical team and the patient's choice (life expectancy and desired anticoagulation status).⁴

No follow-up data are available regarding the current practice in the UK. The most recent available data on VSRR from NICOR (National Institute for Cardiovascular Outcomes Research) reported 103 procedures performed over a period of 3 years across the country (average of 33 cases/year).¹⁴ This suggest that VSRR remains an underperformed procedure in current UK practice. The situation in the USA is similar when we consider that the STS Database recorded that out of 13743 root surgical procedures performed between 2004 and 2010, only 14% were VSRR procedures, only 82 centres performed VSRR procedures, with only 5% of centres performing more than 16 cases/year and only 2 centres 100 VSRRs/year.¹⁵

CONCLUSION

We report our early UK experience with AVr techniques for patients with pure AR due to a variety of mechanisms. We achieved excellent early postoperative clinical and echocardiographic results with acceptable medium-term outcomes (long-term follow-up was limited with missing data). However, AVr techniques continue to evolve and further studies are required to evaluate the long-term benefit to patients with pure AR. These findings underline the need for concentrating the experience in specialist centres in the UK with the aim of providing a national AVr service.

Contributors RG contributed to acquisition and interpretation of data; statistics: drafting the paper and revising it critically; approval of the submitted version. MM contributed to research design, revising it critically; approval of the submitted version. XYJ helped in acquisition and analysis of data; revising it critically; approval of the submitted version. MP helped in research design and interpretation of data; drafting the paper and revising it critically; approval of the submitted version.

Funding The authors have not declared a specific grant for this research from any funding agency in the public, commercial or not-for-profit sectors.

Competing interests None declared.

Patient consent for publication Not required.

Provenance and peer review Not commissioned; externally peer reviewed.

Data availability statement All data relevant to the study are included in the article or uploaded as supplementary information.

Open access This is an open access article distributed in accordance with the Creative Commons Attribution Non Commercial (CC BY-NC 4.0) license, which permits others to distribute, remix, adapt, build upon this work non-commercially, and license their derivative works on different terms, provided the original work is properly cited, appropriate credit is given, any changes made indicated, and the use is non-commercial. See: <http://creativecommons.org/licenses/by-nc/4.0/>.

Correction notice This article has been updated since first published. First author affiliation has been revised, third author's name has been corrected to 'Xu Yu Jin', and reference 3 has been updated.

ORCID iD

Mirko Muretti <http://orcid.org/0000-0002-0483-7372>

REFERENCES

- 1 El Khoury G, Glineur D, Rubay J, *et al.* Functional classification of aortic root/valve abnormalities and their correlation with etiologies and surgical procedures. *Curr Opin Cardiol* 2005;20:115–21.
- 2 Fok M, Shaw M, Sancho E, *et al.* Aortic valve repair: a systematic review and meta-analysis of published literature. *Aorta* 2014;2:10–21.
- 3 Wong CHM, Chan JSK, Sanli D, *et al.* Aortic valve repair or replacement in patients with aortic regurgitation: a systematic review and meta-analysis. *J Card Surg* 2019;34:377–84.
- 4 Baumgartner H, Falk V, Bax JJ, *et al.* 2017 ESC/EACTS guidelines for the management of valvular heart disease. *Eur Heart J* 2017;38:2739–91.
- 5 David TE, Armstrong S, Manlihot C, *et al.* Long-Term results of aortic root repair using the reimplantation technique. *J Thorac Cardiovasc Surg* 2013;145:S22–5.
- 6 Price J, De Kerchove L, Glineur D, *et al.* Risk of valve-related events after aortic valve repair. *Ann Thorac Surg* 2013;95:606–13.
- 7 Lansac E, Di Centa I, Sleilaty G, *et al.* Long-Term results of external aortic ring annuloplasty for aortic valve repair. *Eur J Cardiothorac Surg* 2016;50:350–60.
- 8 Kari FA, Doll K-N, Hemmer W, *et al.* Survival and freedom from aortic valve-related reoperation after valve-sparing aortic root replacement in 1015 patients. *Interact Cardiovasc Thorac Surg* 2016;22:431–8.
- 9 Kari FA, Doll K-N, Hemmer W, *et al.* Residual and progressive aortic regurgitation after Valve-Sparing root replacement: a Propensity-Matched multi-institutional analysis in 764 patients. *Ann Thorac Surg* 2016;101:1500–6.
- 10 le Polain de Waroux JB, Pouleur AC, Robert A, *et al.* Mechanisms of recurrent aortic regurgitation after aortic valve repair: predictive value of intraoperative transesophageal echocardiography. *JACC Cardiovasc Imaging* 2009;2:931–9.
- 11 de Kerchove L, Mastrobuoni S, Boodhwani M, *et al.* The role of annular dimension and annuloplasty in tricuspid aortic valve repair. *Eur J Cardiothorac Surg* 2016;49:428–38.
- 12 Schneider U, Aicher D, Miura Y, *et al.* Suture Annuloplasty in aortic valve repair. *Ann Thorac Surg* 2016;101:783–5.
- 13 Lansac E, Di Centa I, Vojacek J, *et al.* Valve sparing ring replacement: the remodeling technique with external ring annuloplasty. *Ann Cardiothorac Surg* 2013;2:117–23.
- 14 Blue Book Online. Welcome to the blue book online. Available: <http://bluebook.scts.org/> [Accessed 10 Nov 2015].
- 15 Stamou SC, Williams ML, Gunn TM, *et al.* Aortic root surgery in the United States: a report from the Society of thoracic surgeons database. *J Thorac Cardiovasc Surg* 2015;149:116–22.