

# Massive ovarian cystic teratomas diagnosed at a rural Nepal camp

## Abstract

This case report presents the findings of significantly large sized (> 8 cm) symptomatic unilateral cystic teratomas in two perimenopausal patients in remote Nepal.

Ovarian dermoid cysts consist of cystic, solid and fat tissue. Traditionally, cells differentiate along the various germ lines, essentially recapitulating various body tissues. The characteristic sonographic features include a dermoid plug, dermoid mesh, a fat-fluid level and the "tip of the iceberg" sign.

The presence of two or more of these typical features confidently supports an ultrasound-based diagnosis of ovarian dermoid cyst.

The presence of intratumoral hair, teeth, fat, and skin tissue revealed at surgery confirmed the initial ultrasound based diagnosis.

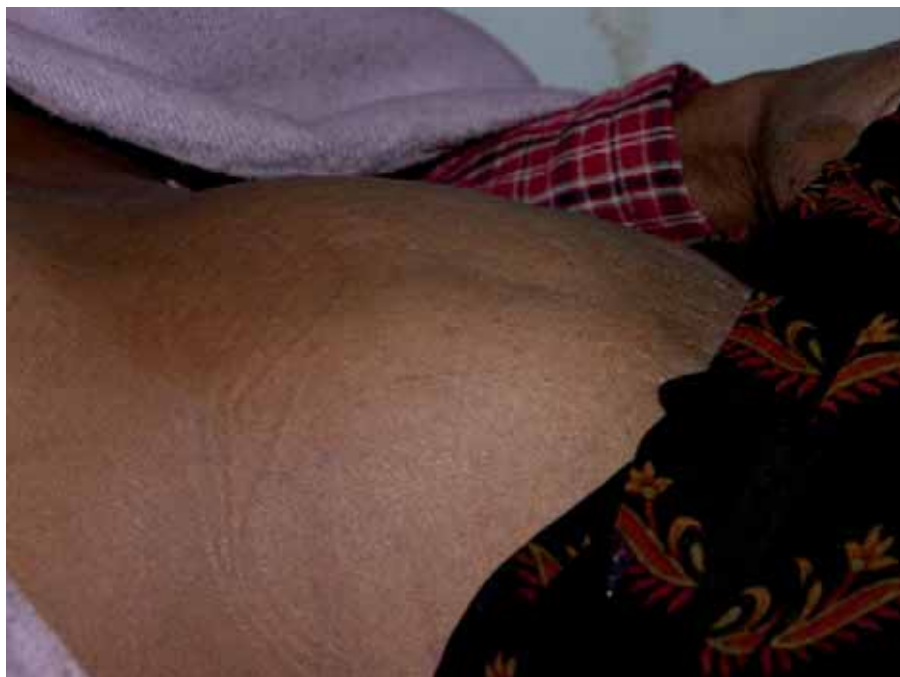**Keywords:** dermoid, mature teratoma, ovarian cyst, pelvic ultrasound.

## Alan Williams

Bapp Sci (medical radiations), DMU (general) (vascular), Diploma in Education (secondary).

Horizon Radiology  
Auckland city 1010  
New Zealand

Correspondence  
to email alan@  
alanwilliamsportfolio.com



**Figure 1:**  
Obvious  
abdominal  
swelling pre  
surgery.

## Introduction

Ovarian teratoma subgroups include mature cystic teratomas (dermoid cysts), immature teratomas and monodermal teratomas.

Teratomas are germ cell tumors composed of a variety of parenchymal cell types representing one or more germ layer: endoderm, ectoderm and mesoderm.

Ectodermal elements tend to predominate, hence mature cystic teratomas are typically benign with malignant transformation occurring in only up to 2% of cases.<sup>1</sup>

Cystic teratomas are often incidental findings, however, in other cases associated symptoms include lower abdominal pain, pelvic mass related

pressure effects and abnormal uterine bleeding.

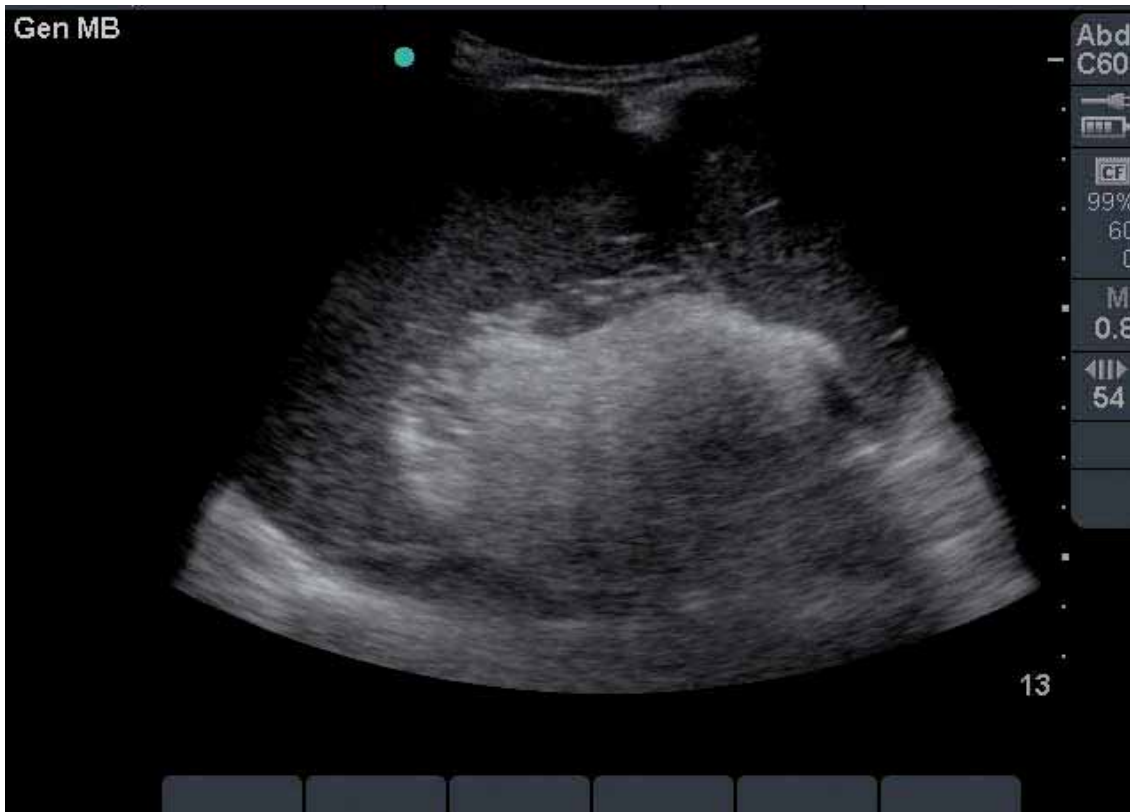The presence of hair, teeth, fat, skin and muscle in these tumors is common, giving rise to the complex cyst formations often described on ultrasound.

## Case reports

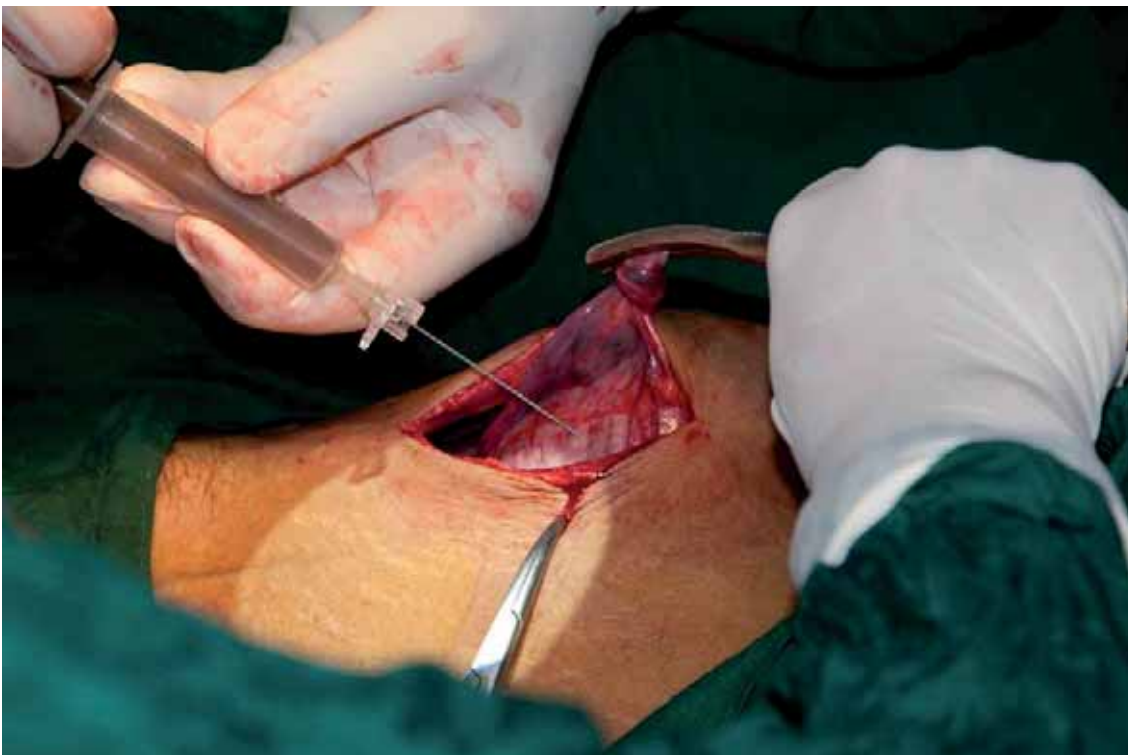Two female patients arrived at the International Nepal Fellowship (INF) camp with abdominal symptoms.

The first patient, aged 45 presented with a clinically palpable right sided large abdominal mass and significant abdomino-pelvic pain.

An abdominal ultrasound using a C5-2MHz curvilinear transducer demonstrated sonographic



**Figure 2:** Sonogram of the cyst in situ.



**Figure 3:** Aspiration and drainage of the cyst before removal at laparotomy.

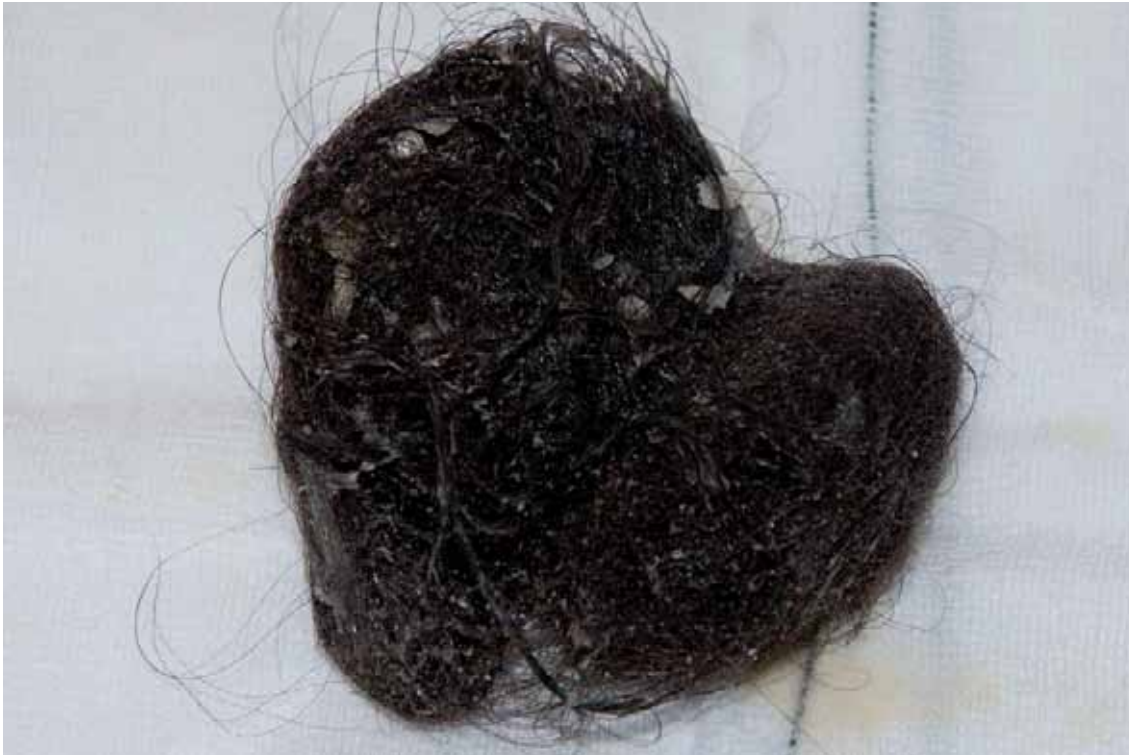features favoring a cystic teratoma. The scan demonstrated a large well defined 13 cm echogenic cyst likely containing sebaceous fluid. A large focal region of diffuse echogenicity with posterior shadowing was noted, presumed to represent a ball of matted hair within the cyst. Peripheral hair clusters were seen as scattered echogenic strands and dots. The contents described on

ultrasound were confirmed at subsequent surgery.

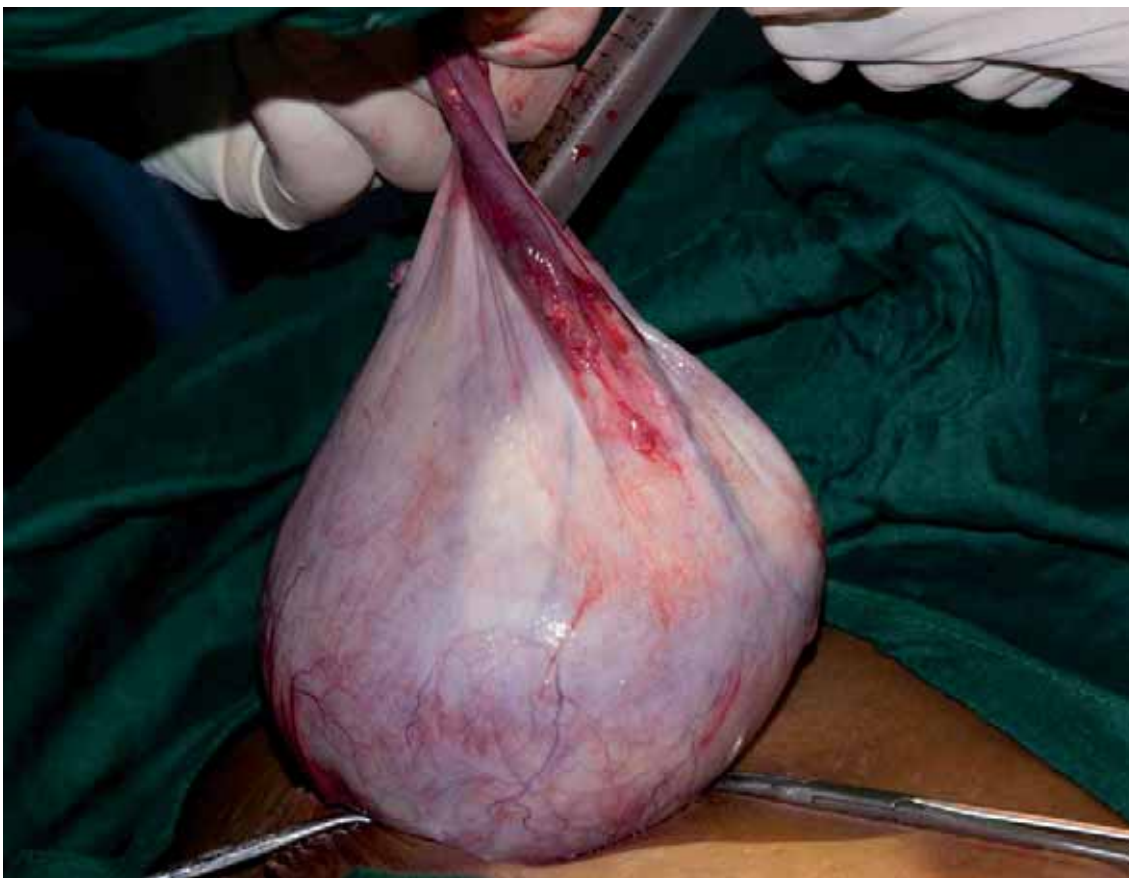Series of images illustrating diagnosis and surgical removal of a 13 cm mature cystic teratoma (patient 1).

Note the focal echogenicity of the “dermoid plug”.

The second patient, also aged 45 year presented with bilateral flank pain and recent onset of vomiting. A painful pelvic mass



**Figure 4:** Matted hair found in the cyst.

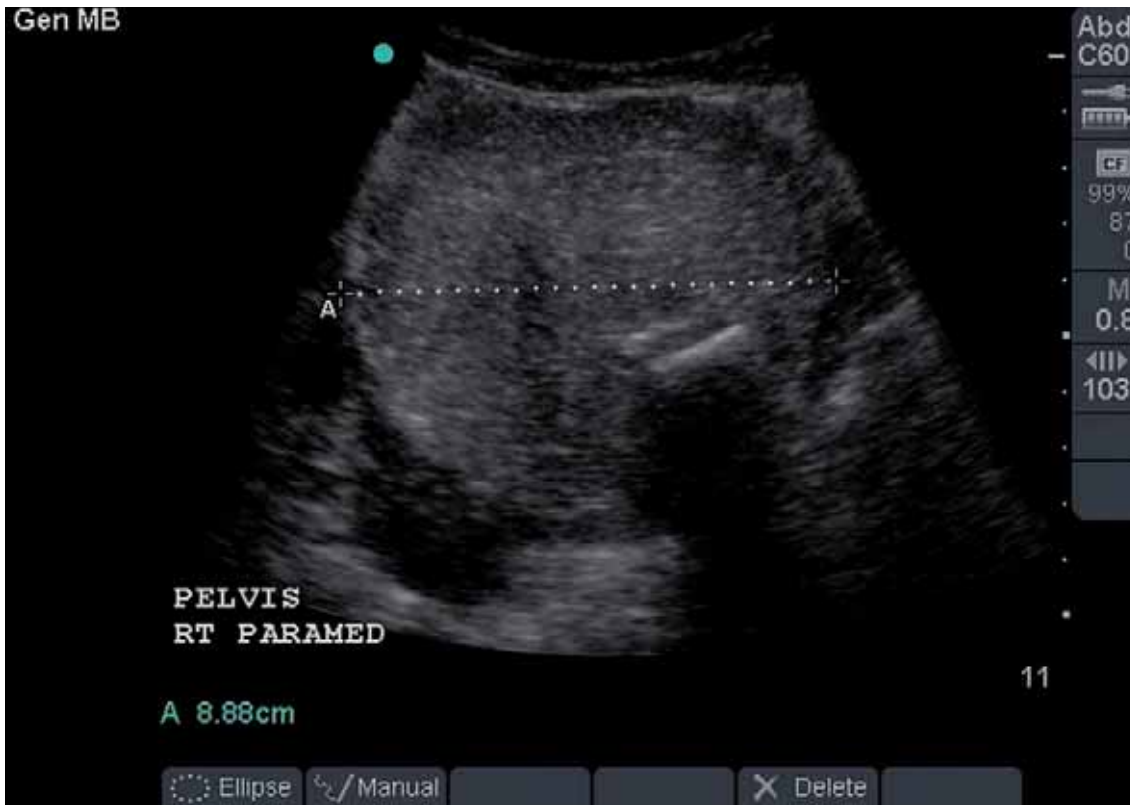

**Figure 5:** Complete removal of the cyst via oophorectomy.

was clinically palpated which prompted further investigation with ultrasound.

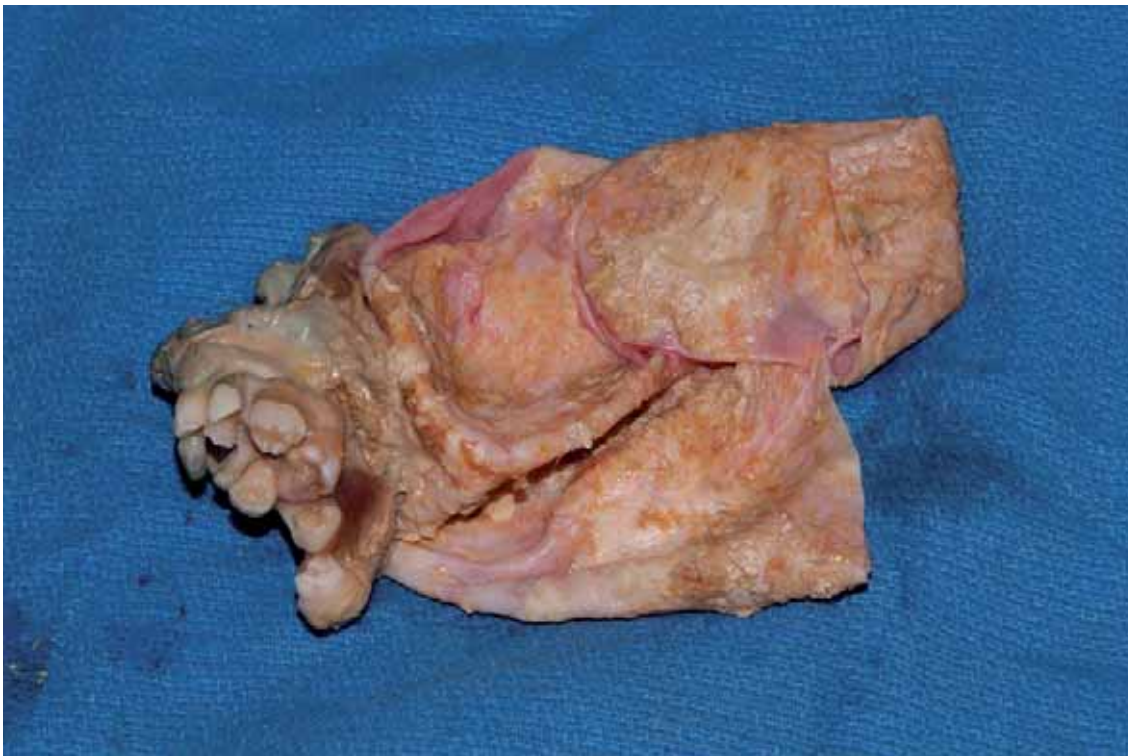
Using the C5-2MHz transducer, a well defined 9 cm complex mass was demonstrated in the pelvis. The internal components of the mass comprised of predominantly hyperechoic sebaceous

fluid. Specific findings in the form of an echodense focal zone with posterior shadowing suggested a calcific nature consistent with bone or teeth. The contents were confirmed to be a cluster of teeth at surgery. The thickened cyst wall contained sebaceous glands and hair strands.



**Figure 6:** Sonogram of a cystic teratoma in situ.

The echogenic focus with posterior cystectomy shadowing was shown to be a cluster of teeth at surgery.



**Figure 7:** Contents of the cystic teratoma displayed post ovarian cystectomy.

## Discussion

Cystic teratomas, or ovarian dermoid cysts as they are commonly known, are the most frequently occurring benign germ cell tumour and make up between 15% to 25% of all ovarian neoplasms.<sup>2</sup>

While diagnosed far more frequently during the active reproductive years, cystic teratomas may occur at any age

including the postmenopausal stage.

Sonographic features that are considered highly specific to teratomas include a predominantly cystic mass (representing the presence of sebaceous fluid) with a focal echogenic mural nodule referred to as a “dermoid plug” which usually contains hair, teeth or fat. This is the most common ultrasound-based feature of a dermoid cyst.<sup>3</sup>

When multiple small hyperechoic lines and dots are visualised within the cyst it can create a 'mesh-like' picture. Such echogenic foci represent small hairs floating in the cystic fluid.<sup>3,4</sup>

In addition, an echodense focus with posterior acoustic shadowing typically represents teeth or bone in association with a Rokitansky protuberance.

The specificity of these sonographic findings is however limited by the overlapping appearance with other ovarian pathologies such as endometriomas and haemorrhagic cysts. Echogenic fluid-filled gas distended bowel, ectopic gestations, pedunculated fibroids, gas forming tubo-ovarian abscess, perforated appendicitis with faecolith are included in the much less common list of false-positive findings.

While conservative or non-surgical management for small incidental tumors is the treatment of choice advocated by some authors,<sup>5</sup> simple cystectomy is considered routine for larger tumors, especially if symptomatic.

The most common complication of a cystic teratoma is ovarian torsion while less common complications include rupture, infection, haemolytic anaemia, chemical peritonitis and malignant transformation.<sup>2</sup>

The slow average rate of growth of these tumours,<sup>6</sup> about 1.8 mm a year plus the chronic symptomatology supports the theory that these tumours probably first appeared in situ during the reproductive years of these two female patients.

These cases were just two examples of many patients who presented with an advanced medical condition typical of a region untouched by surgical service. Established in 1952, INF is Nepal's longest-serving international non-government organisation, with a medical focus is on the poor and disadvantaged, including those in remote areas.

The use of portable ultrasound in a remote setting was proven to be an effective and reliable means of investigating symptoms of abdominal pain and masses. The ultrasound evaluation and confirmation of these masses was performed with a high level of confidence.

This assertion is supported by a study, Patel, *et al.*, in which 252 adnexal masses were evaluated in terms of specific sonographic features such as a shadowing echodensity, regional bright echoes, hyperechoic lines and dots, and fluid-fluid levels.

The study showed that a positive predictive value of almost 100% was established when two or more of these features were used. It was shown in the study that none of the non-cystic teratoma masses had more than two features characteristic of these tumors.<sup>7</sup>

Both patients recovered well and were discharged from the camp on the third post-operative day without complications.

## References

- 1 Hamilton CA. Cystic Teratoma. Available online at: <http://emedicine.medscape.com/article/281850-overview#a0101> [verified January 2012].
- 2 Diagnostic Ultrasound 3rd ed. Missouri: Mosby Inc; 2005.
- 3 Hertzberg BS, Kliewer. Sonography of benign cystic teratoma of the ovary: pitfalls in diagnosis. *AJR* 1996; 167: 1127–33.
- 4 Kite L, Uppal T. Ultrasound of ovarian dermoids – sonographic findings of a dermoid cyst in a 41-year-old woman with an elevated serum hCG. *Australasian Journal of Ultrasound in Medicine* 2011; 14 (3): 19–21.
- 5 Outwater EK, Siegleman ES, Hunt JL. Ovarian teratomas: tumor types and imaging characteristics. *Radiographics RSNA* 2001; 26 (2): 475–90.
- 6 Ultrasonography an Obstetrics and Gynaecology 4th ed. Philadelphia WB Saunders Company 2000
- 7 Patel MD, Feldstein VA, Lipson SD, Chen DC, Filly RA. Cystic teratomas of the ovary: diagnostic value of sonography. *Am J Roentol* 1998; 171: 1061–65.