

Ultrasound elastography as a potential diagnostic aid in oral submucous fibrosis

ABSTRACT

Background: Oral submucous fibrosis (OSMF) is a well-recognized “potentially malignant” disorder. It mostly affects the productive population of young adults and adolescents. The diagnosis of oral submucous fibrosis is primarily clinical and subjective. The only objective diagnostic method for OSMF is tissue biopsy. This study was conducted to find the potential use of ultrasound elastography to objectively quantify the clinical presentation in accordance with severity of the clinical condition in OSMF.

Materials and Methods: The study sample consisted of 27 clinically diagnosed and staged participants with OSMF. Transcutaneous ultrasonography was done by a single operator on GE Logiq E9 machine with a 6–15 MHz linear matrix probe. Color-coded scheme was used to qualitatively grade the eight different zones of oral mucosa with the use of stress–strain elastography. The grades ranged from 0 to 5, where 0 represented artifacts and color range from red to blue corresponded to varying degree of increasing tissue stiffness. Clinical stage 1, 2, and 3 corresponded to mouth opening of >30 mm, 20–30 mm, and <20 mm, respectively. The summative elastography score range as follows: 8–10, 11–14, and 15 represented the respective degree of tissue stiffness from soft, mild stiff to severe stiff.

Results: The results obtained by Pearson’s correlation between the elastographic grading and clinical grading came out to be 0.007, and it was highly significant. The sensitivity and specificity of the diagnostic method were 90.9% and 20%, respectively.

Conclusion: The advantages of ultrasound elastography as a diagnostic tool over the subjective clinical method of diagnosis and staging of OSMF looks promising. Further studies should be conducted with a suitable specific transducer probe and with quantitative diagnostic elastography method.

Keywords: Oral submucous fibrosis, shear-wave elastography, stress-strain elastography, ultrasound elastography

BACKGROUND

Oral submucous fibrosis (OSMF) is a well-recognized “potentially malignant” disorder^[1] and has a prevalence rate of about 0.2%–1.2% in India.^[2–4] OSMF primarily targets most productive age group of young adults and adolescents, thereby putting them in an increased risk of oral cancer.

The diagnosis of OSMF is primarily clinical and involves subjective and objective criteria. The clinical and functional staging suggested by Haider *et al.*^[5] is widely followed, but we still do not have specific and objective diagnostic method other than tissue biopsy to correlate to extent and severity of the disorder. The tissue biopsy in OSMF has inherent


limitation. In diffuse disease, the extent of fibrosis differs in various parts of the oral mucosa, and the tissue sample that we take from a single site may not be the most representative site for biopsy.^[5] Biopsy is an invasive procedure which causes

**SAILESH KUMAR MUKUL, SUBHASH KUMAR¹,
SHWETA PANDEY, EJAZ AHMAD MOKHTAR,
AMIT KUMAR**

Departments of Dentistry and ¹Radiodiagnosis, AIIMS, Patna, Bihar, India

Address for correspondence: Dr. Amit Kumar,
Department of Dentistry, AIIMS, Phulwarisharif, Patna - 801 507,
Bihar, India.
E-mail: docamitkr@yahoo.in

Received: 26-03-2019, **Revised:** 19-05-2019,
Accepted: 11-06-2019, **Published:** 12-11-2019

Access this article online	
Website: www.njms.in	Quick Response Code 
DOI: 10.4103/njms.NJMS_20_19	

This is an open access journal, and articles are distributed under the terms of the Creative Commons Attribution-NonCommercial-ShareAlike 4.0 License, which allows others to remix, tweak, and build upon the work non-commercially, as long as appropriate credit is given and the new creations are licensed under the identical terms.

For reprints contact: reprints@medknow.com

How to cite this article: Mukul SK, Kumar S, Pandey S, Mokhtar EA, Kumar A. Ultrasound elastography as a potential diagnostic aid in oral submucous fibrosis. *Natl J Maxillofac Surg* 2019;10:129-33.

surgical trauma and tissue scarring that further contributes to the severity and progression of OSMF.

Ultrasound elastography is a real-time, widely available, noninvasive, nonionizing, and cost-effective diagnostic method with better patient acceptance. It can be the most valuable tool when mouth opening is very less or absent.

MATERIALS AND METHODS

The study sample consisted of 27 clinically diagnosed and staged participants with OSMF who visited the outpatient clinic for the disorder. Elastography was done by single operator on GE Logiq E9 machine [Figure 1] with a 6–15 MHz linear matrix probe [Figure 2]. No pressure was applied. No water bag was used within the mouth. Coupling agent or gel was applied to the transducer, and the scan was performed from the anterior to the posterior buccal mucosa separately on each side and the upper and lower lip (LL) regions. To obtain the image of buccal mucosa, the transducer was positioned on the cheek extra orally along the line joining the angle of mouth to the tragus of the ear.

Transcutaneous ultrasonography was done as mouth opening was restricted and probe was difficult to place intraorally. In viewing the anterior part of buccal mucosa, the anterior part of the probe was placed at the angle of the mouth. The technical parameters of the scan, such as depth, gain, focus, and time gain compression, were kept constant throughout the study to avoid potential bias in the assessment of eco texture.

The ultrasonographic findings were recorded separately for all the eight zones which were divided for the purpose of examination possible with the linear matrix probe.

The color-coded scheme was used, and images were recorded for the following sites:

1. Right posterior buccal mucosa
2. Right medial buccal mucosa
3. Right anterior buccal mucosa
4. Left posterior buccal mucosa
5. Left medial buccal mucosa
6. Left anterior buccal mucosa
7. LL
8. Upper lip.

Elastography technique

Elastography techniques are classified in various ways:

- i. According to the source:
 - a. Static or quasi-static elastography (strain imaging)
 - b. Dynamic (shear-wave imaging) – transient and continuous.
- ii. According to modality used for tracking – ultrasound and magnetic resonance imaging (MRI), for example, ultrasound – 1D transient elastography, point shear-wave elastography, shear-wave elastography, and magnetic resonance elastography.^[6]

Ultrasonography elastography was displayed over the B-mode image in a color scale that ranged from red, for components with greatest elastic strain (i.e. softest components), to blue for those with no strain (i.e. hardest components).^[7] B-mode ultrasonography for the defined zones was done, and the findings were recorded.

Qualitative elastography in which stress-strain elastography was done that gave a color map of entire areas covered by probe with color grading from red to blue showing soft-to-hard areas. In this way, five grades of color-coded maps were generated.

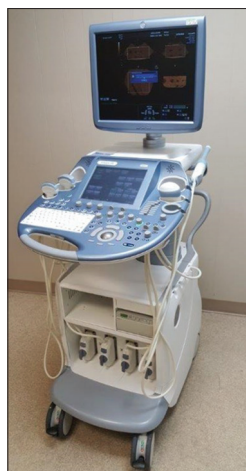

Figure 1: GE Logiq E9 Machine



Figure 2: GE Logiq E9 Machine Probe

Elastography score is a relative elasticity ratio between normal appearing areas and abnormal appearing areas. As shown in Figure 3, the oral mucosal lining (epithelium and connective tissue together) appeared as a single hyperechoic line (white arrow). Just lateral to the mucosa (above the mucosal lining in cross-sectional ultrasound images), the submucosa appeared as a uniformly hypoechoic zone of varying thickness. Just above the submucosa, the muscle layer (comprising predominantly of buccinator) appeared as an echogenic band. Above this zone, the hypoechoic buccal pad of fat, superficial muscles of facial expression, subcutaneous tissue, and skin (black arrow) were seen in that

order. The boundary between the submucosa and the muscle layer was clear and distinct.

Figures 4-9 and Table 1 shows five-point color-coded scheme was used, with 0 point given for incomplete examination (artifacts, mustache, beard, poorly evaluable images, etc.). The same code was used in the excel chart for the analysis.

- Grade 0: Poor visibility due to mustache
- Grade 1: Entire area is evenly shaded red
- Grade 2: Entire area has a mosaic pattern of different colors (green, red, and blue)
- Grade 3: Most of the area is blue (more than half and up to 3/4th area)
- Grade 4: Entire area is blue (more than 3/4th)
- Grade 5: Entire area and adjacent surrounding portions are blue.

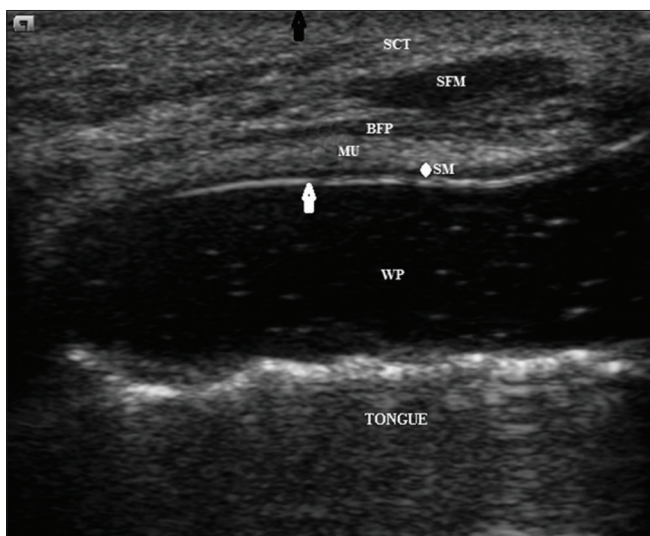


Figure 3: B-mode image for normal mucosa with ultrasound

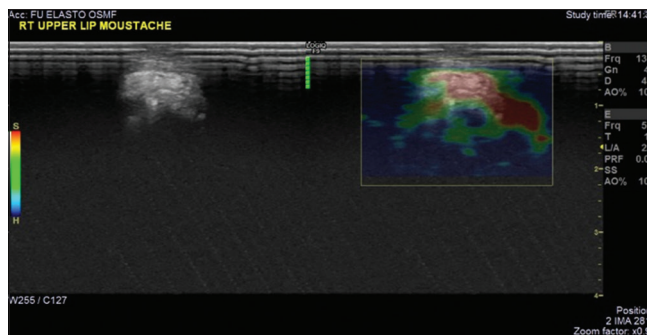


Figure 4: Grade 0 - Poor visibility due to mustache

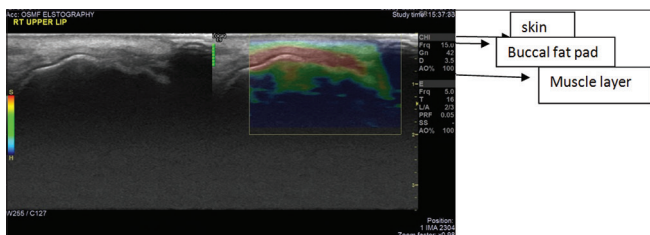


Figure 5: Grade 1 - Entire area is evenly shaded red

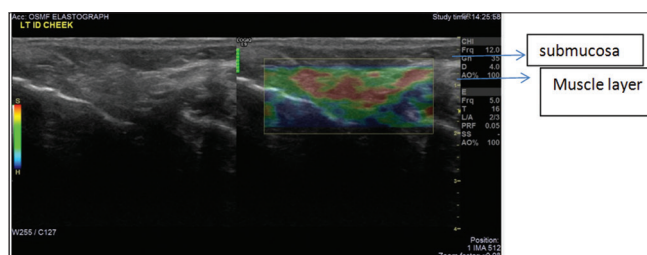


Figure 6: Grade 2 - Entire area has a mosaic pattern of different colors (green, red, and blue)

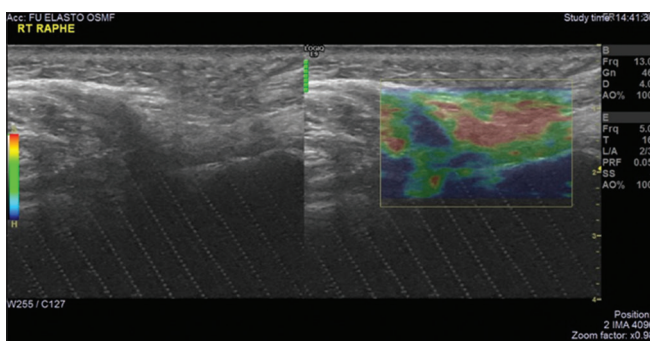


Figure 7: Grade 3 - Most of the area is blue (more than half and up to 3/4th area)

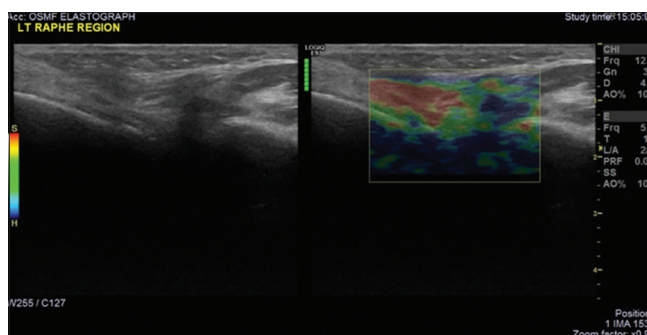


Figure 8: Grade 4 - Entire area is blue (more than 3/4th)

The staging criteria used in the study

The functional staging suggested by Haider *et al.*^[5] was modified to categorize the participants into different stages.

- Stage 1 – mouth opening of >30 mm
- Stage 2 – mouth opening of 20–30 mm
- Stage 3 – mouth opening of <20 mm.

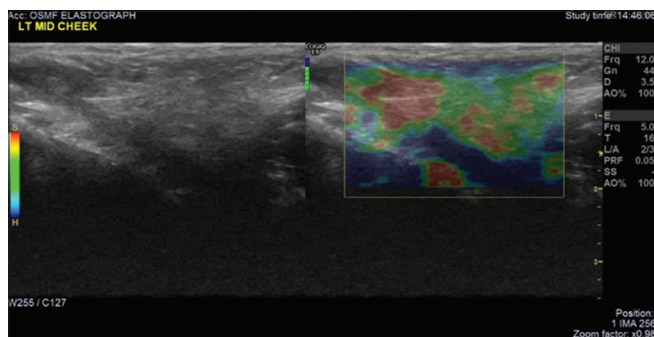


Figure 9: Grade 5 - Entire area and adjacent surrounding portions are blue

Table 1: Five grades with scoring criteria

Grade	Score
Grade 1	Score 1: Entire area is evenly shaded red as is the surrounding tissue
Grade 2	Score 2: Lesion area has mosaic pattern of green, blue, and red (soft)
Grade 3	Score 3: More than half and up to 3/4 th area is blue with peripheral area as green
Grade 4	Score 4: Entire area is blue (stiff)
Grade 5	Score 5: Both entire and its surrounding areas are blue (stiff)

Table 2: Pearson's correlation

	Correlations	
	Elastography	Clinical grading
Elastography		
Pearson's correlation	1	0.509**
Significant (two-tailed)		0.007
n	27	27
Clinical grading		
Pearson's correlation	0.509**	1
Significant (two-tailed)	0.007	
n	27	27

**Correlation is statistically significant at the 0.01 level (two-tailed)

Functional staging was recorded measuring the mouth opening with Vernier caliper from mesioincisal angle of the upper central incisors to the lower central incisors.

For elastography, the total score was calculated by adding grading scores of different zones.

1. Score 8–10 – soft (low-minimum strain area <50%)
2. Score 11–14 – mild stiff (strain area <75%)
3. Score 15 and more - Severe stiff (>75% strain area).

RESULTS

The data collected in our study were analyzed using the Statistical Package for Social Sciences (SPSS) for Windows (SPSS version 16, Chicago, Illinois). Simple mean, standard deviation, and significant correlation between the two groups were used to describe the distribution of data collected. Pearson's test [Table 2] was used to correlate between the clinical grading and elastographic grading.

The results after Pearson's correlation between the elastographic grading and clinical grading came out to be 0.007, and it was highly significant. Table 3 shows that the Ultrasound Elastography has sensitivity of 91% and specificity of 20 % with the Positive and Negative Predictive values of 83.3 % and 33.3 % respectively.

DISCUSSION

Ultrasound elastography is considered a noninvasive, convenient, and precise technique to grade the degree of fibrosis by measuring tissue stiffness. Elastography techniques

Table 3: Result of ultrasound elastography with 91% Sensitivity and 20 % Specificity

	Clinical stage		
	Clinical Stage 1	Clinical Stage 2	Clinical Stage 3
Elastography presentation (negative) (elastography score > 10)	TP 20	FP 4	Positive predictive value TP/(TP + FP): 20/(20+4) 83.3%
Elastography presentation (positive) (elastography score ≤ 10)	FN 2	TN 1	Negative predictive value TN/(FN + TN): 1/(2+1) 33.3%
-	Sensitivity TP/(TP + FN): 20/(20+2) 90.9% 91%	Specificity TN/(FP + TN): 1/(4+1) 20%	

TN: True negative, FN: False negative, TP: True positive, FP: False positive. Gold standard: Clinical mouth opening, TP: Clinical score 2 (mouth opening <30 mm); elastographic score 2 (elastographic scoring >10 mm); TN: Clinical score 1 (mouth opening >30 mm); elastographic score 1 (elastographic scoring <10 mm), FN: Clinically positive (2) (mouth opening <30 mm); elastography negative (1) (elastographic scoring ≤10); FP: Clinically negative (1) (mouth opening >30 mm); elastographically positive (2) (elastographic scoring >10)

may be classified according to the source (static, quasistatic, or dynamic) and duration (transient or continuous) of tissue deformation and the modality used for tracking (ultrasound or MRI). Elastography by the use of clinical ultrasound and MR system has become a promising diagnostic method to noninvasively assess mechanical tissue properties.^[7] The technique of elastography for evaluation of elastic properties of the tissue either quantitatively or qualitatively was prior described by Ophir *et al.* in 1991.^[8] Since its initial application to quantitatively measure the elasticity of compliant tissue; the technological progress has established its diagnostic application in different pathological condition where tissue elasticity is increased or decreased, like in different types of solid tumors and liver cirrhosis, etc.

In liver fibrosis, elastography has been extensively used where parenchymal tissue is replaced by fibrous tissue.^[9] As the similar events take place in OSMF cases, where tissue elasticity decreases following collagen proliferation and fibrosis, the use ultrasound elastography can be a potential diagnostic aid. Bhatia *et al.*^[10,11] has provided various evidences regarding the accuracy of ultrasound elastography for the malignancy of the head-and-neck region.

OSMF is predominant largely in the people of Southeast Asia, South Asian immigrants in other countries and the Indian subcontinent where chewing areca nut with betel quid is a common practice.^[5] OSMF is a diffuse disease in which severity varies from site to site in the very same patient. In this study, manual palpation of the fibrous bands and degree of firmness of mucosa was evaluated along with functional mouth opening range. These findings were correlated with elastographic scoring.

The results in this study were highly significant which stated that elastography can be a useful noninvasive method for diagnosing OSMF. Ultrasound elastography can help in knowing the degree of involvement of the mucosa at different sites very similar to manual palpation and can give measurable records.

Limitations of the study

The major problem in the application of elastography is that there are wide variety of techniques and processing algorithm currently available for producing and displaying elastographic images, and therefore, the findings, as well as the artifact or limitations, are highly dependent on the technique and may be specific to a specific system.

Transducer probe used in the study was not specific for oral region and could not access the oral cavity, and hence only

transbuccal approach was possible. There exists a scope for the design and development of specific probe for oral region and larger study with this method.

CONCLUSION

The advantages of ultrasound elastography as a diagnostic tool over the subjective clinical method of diagnosis and staging of OSMF look promising. This study should be further explored with a suitable specific transducer probe and with quantitative diagnostic elastography method. Shear-wave elastography in OSMF patient can yield valuable information and should be taken up in further studies.

Financial support and sponsorship

Nil.

Conflicts of interest

There are no conflicts of interest.

REFERENCES

1. Warnakulasuriya S, Johnson NW, van der Waal I. Nomenclature and classification of potentially malignant disorders of the oral mucosa. *J Oral Pathol Med* 2007;36:575-80.
2. More CB, Das S, Patel H, Adalja C, Kamatchi V, Venkatesh R. Proposed clinical classification for oral submucous fibrosis. *Oral Oncol* 2012;48:200-2.
3. Katharia SK, Singh SP, Kulshreshtha KV. The effects of placental extract in management of oral submucous fibrosis. *Indian J Pharmacol* 1992;24:181-3.
4. Krithika C, Ramanathan S, Koteeswaran D, Sridhar C, Satheesh Krishna J, Shiva Shankar MP. Ultrasonographic evaluation of oral submucous fibrosis in habitual areca nut chewers. *Dentomaxillofac Radiol* 2013;42:20120319.
5. Haider SM, Merchant AT, Fikree FF, Rahbar MH. Clinical and functional staging of oral submucous fibrosis. *Br J Oral Maxillofac Surg* 2000;38:12-5.
6. Arijji Y, Gotoh A, Hiraiwa Y, Kise Y, Nakayama M, Nishiyama W, *et al.* Sonographic elastography for evaluation of masseter muscle hardness. *Oral Radiol* 2013;29:64-9.
7. Tang A, Cloutier G, Szeverenyi NM, Sirlin CB. Ultrasound elastography and MR elastography for assessing liver fibrosis: Part I, principles and techniques. *AJR Am J Roentgenol* 2015;205:22-32.
8. Ophir J, Céspedes I, Ponnekanti H, Yazdi Y, Li X. Elastography: A quantitative method for imaging the elasticity of biological tissues. *Ultrason Imaging* 1991;13:111-34.
9. Jeong WK, Lim HK, Lee HK, Jo JM, Kim Y. Principles and clinical application of ultrasound elastography for diffuse liver disease. *Ultrasonography* 2014;33:149-60.
10. Bhatia KS, Lee YY, Yuen EH, Ahuja AT. Ultrasound elastography in the head and neck. Part I. Basic principles and practical aspects. *Cancer Imaging* 2013;13:253-9.
11. Bhatia KS, Lee YY, Yuen EH, Ahuja AT. Ultrasound elastography in the head and neck. Part II. Accuracy for malignancy. *Cancer Imaging* 2013;13:260-76.