

## How I Do It

# Separation Surgery for Unresectable Right-sided Colon Cancer as Palliation

Ryosuke Maki, Ken Nakata, Nobuyoshi Ohara, Masaki Tsujie, Junya Fujita and Hiroki Ohzato

*Department of Gastrointestinal Surgery, Sakai City Medical Center, Sakai, Japan*

### Abstract

Patients with acute colorectal obstruction due to malignancy in the right-sided colon are treated with primary resection and anastomosis. However, considering the generally poor status and prognosis, less-invasive, palliative treatment is desirable, particularly for unresectable malignancies. An ileostomy is useful, but the patient must manage the stoma, which worsens the quality of life.

We developed a palliative surgical procedure, termed the “Separation surgery of the right-sided colon,” for treating an obstruction due to unresectable right-sided colon cancer. We identified and divided the ileum and the transverse colon and anastomosed the upper ileum to the lower transverse colon. Then, we created a mucous fistula with the loose ends of the lower ileum and the upper transverse colon.

We performed this procedure in five patients. Stoma pouches were unnecessary. No comorbidities were observed, including anastomotic leakage. The “Separation surgery of the right-sided colon” was useful as palliative surgery.

### Keywords

separation surgery of the right-sided colon, unresectable right-sided colon, palliative surgery

*J Anus Rectum Colon* 2021; 5(2): 207-211

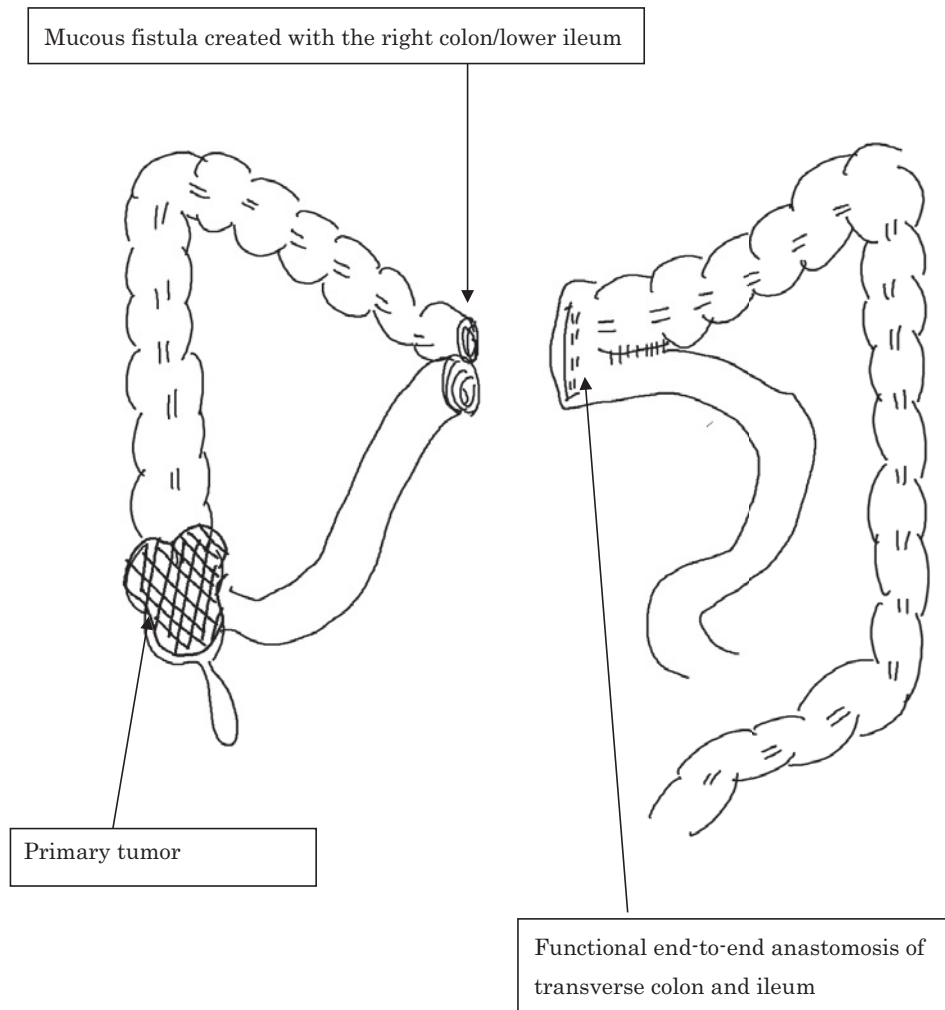
## 1. Introduction

Patients with an acute colorectal obstruction or perforation due to malignancy of the right-sided colon are generally treated with a resection and primary anastomosis[1]. However, given the generally poor status, prognosis, and quality of life of these patients, a less-invasive treatment is desirable as an alternative mode of palliation, particularly for unresectable malignancies.

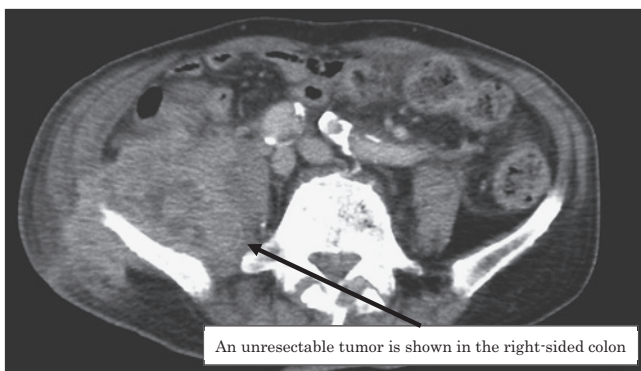
Notably, up to 50% of patients with large bowel obstructions due to malignancy are not candidates for curative resections[2]. As a palliative treatment, the obstructed bowel can be decompressed with an ileostomy, ileo-transverse colon bypass surgery, or endoscopic stent therapy. However, once an unresectable right-sided colon tumor perforates the bowel, ileo-transverse colon bypass surgery cannot prevent the outflow of feces and the subsequent infection. For pa-

tients who are unable or unwilling to undergo a palliative resection, stenting is an alternative that is successful, in the short term, in over 90% of patients[3]. However, endoscopic stent therapy might worsen the situation when a perforation has occurred. An ileostomy might be useful, but the patient must manage the stoma, and the output from a stoma can be substantial, even when an antidiarrheal drug is given. Therefore, an ileostomy worsens the quality of life.

On the basis of these considerations, in the present study, we aimed to develop a palliative surgical procedure, which we called the “Separation surgery of the right-sided colon,” for treating perforations due to unresectable right-sided colon cancer (Figure 1).



**Figure 1.** Configuration of the gastrointestinal tract after separation of the right-sided colon. The ileum (smooth tube) and transverse colon (bulbous tube) are detached from the right colon and anastomosed to form a new connection. A mucous fistula is created to allow the escape of mucous and air from the severed right colon.



**Figure 2.** An unresectable right-sided colon cancer, which infiltrates the retroperitoneum or abdominal organs, is a possible indication for the new procedure.

## 2. Materials and Methods

### 2.1 Procedure for the separation of the right colon

First, we opened the abdomen, located the perforation, and performed abdominal irrigation. We then identified the ileum and transverse colon, divided both, and anastomosed the upper ileum to the lower transverse colon. Next, we sutured the lower ileum to the upper transverse colon. We then created a mucous fistula with the loose ends of the lower ileum and the upper transverse colon. Finally, we placed a drain and closed the abdomen. These surgical procedures can be performed with a laparotomy or endoscopic surgery.

The indications for this new surgical procedure are unresectable right-sided colon cancer, due to locally advanced colon cancer, and cancer with a perforation and/or a retroperitoneal abscess, and/or a slight bleeding from the tumor,

**Table 1.** Characteristics of Patients That Underwent Right Colon Separation.

Patient	Age (y)	Sex	Primary lesion	Perforation	Hemorrhage	Obstruction	T	N	M	Stage
1	69	F	Cecum	+	–	+	T4b	N2b	M0	IIIC
2	66	F	Ascending colon	+	–	+	T4b	N2b	M0	IIIC
3	80	M	Ascending colon	+	–	+	T4b	N0	M1a	IVA
4	62	M	Cecum	+	–	+	T4b	N0	M0	IIIC
5	85	M	Cecum	+	–	+	T4b	N2b	M1b	IVB

but not when general peritonitis is present.

## 2.2 Patients

We performed surgery to separate the right colon in five patients, from October 2012 to May 2018. Patients were identified in the medical database at Sakai City Medical Center. We defined the right-sided colon as the tract from the cecum to the proximal transverse colon. We defined a perforation in the right-sided colon due to cancer as a severe dilatation in the proximal colon near a suspected cancer lesion and free air in the abdomen, observed in computed tomographic scans. Unresectable colon cancer was defined as a tumor that infiltrated or spread to other organs (unresectable due to locally advanced colon cancer), and tumors that could not be treated with a curative resection and negative surgical margins because of the patient's generally poor status and prognosis (Figure 2).

The outcomes included operation time, blood loss, adverse events, acute mortality, specified diet initiation, the length of hospital stay, and survival time (days).

All patients or their relevant persons provided written consent. The Sakai Medical Center Institutional Review Board approved the present study.

## 3. Results

### 3.1 Patient characteristics

Table 1 shows the patients' characteristics. All five patients (three men and two women; mean age, 69 years) underwent a palliative surgical separation of the right-sided colon to treat an obstruction and a perforation due to unresectable right-sided colon cancer. Among these patients, three had cecum colon cancer and two had ascending colon cancer. All patients were classified as T4b; moreover, three patients were staged as IIIC, one was staged as IVA, and one was staged as IVB. The surgeries were performed with four laparotomies and one laparoscopy.

### 3.2 Early outcomes and adverse events

Table 2 shows the early outcomes. The mean operation time was 136.4 min, and no blood loss was detected. No comorbidities were observed, including anastomotic leakage,

and the patients began eating a mean of 3.2 days after surgery. The drainage from the mucous fistula was sufficient, and only one patient (20%) required percutaneous drainage due to an abdominal abscess. The median hospital stay was 17.2 days, and no patients required antidiarrheal drugs. There were no signs that the infection worsened for several days after they started to eat and removed the drainage tube.

### 3.3 Long-term outcomes

Table 2 shows the long-term outcomes of the patients. We administered adjuvant chemotherapy in four patients (80%), and we performed a right hemicolectomy with lymph node dissection in two patients (40%).

One patient (Patient 1) received adjuvant chemotherapy with capecitabine, oxaliplatin, and bevacizumab. The patient exhibited a partial response, and at 3 months after the initial separation surgery, the patient underwent laparoscopic surgery for a right hemicolectomy. We resected 23 regional lymph nodes (seven #201 lymph nodes, five #202 lymph nodes, and 11 #203 lymph nodes). At 3 months after the ileocecal resection, a liver metastasis was found, and laparoscopic surgery was conducted for a partial hepatectomy. This patient was alive with peritoneal metastasis at the 29 month postoperative follow-up.

Another patient (Patient 4) received adjuvant chemotherapy with capecitabine, oxaliplatin, and bevacizumab. The patient exhibited a stable disease response, and at 4 months after the initial separation surgery, the patient underwent a laparotomy for a right hemicolectomy. We resected 11 regional lymph nodes (two #201 lymph nodes, four #202 lymph nodes, and five #203 lymph nodes). At 29 months after the ileocecal resection, a peritoneal metastasis was found, and the patient underwent peritoneal metastasis dissection and small bowel resection. Then, at 54 months after the ileocecal resection, a local recurrence was found, and the patient underwent another peritoneal metastasis dissection, a small bowel resection, and an ileo-transverse bypass. This patient was alive at the 71 month postoperative follow-up.

## 4. Discussion

This procedure was preferred for unresectable right-sided colon cancer, which infiltrated the retroperitoneum or ab-

**Table 2.** Surgical Events and Outcome of Patients That Underwent Right Colon Separation.

Patient	Operation time (min)	Blood loss (ml)	Postoperative stay (days)	Adverse events	Fasting period (days)	Specified diet initiation (days)	Drainage after operation	Adjuvant chemotherapy	Radical surgery	Chemotherapy after radical surgery	Recurrence	Outcome
1	137	0	11	-	6	1	Unnecessary	Capecitabine, oxaliplatin, and bevacizumab	Right hemicolectomy in laparoscopic surgery	free	Liver metastasis ⇒ Partial hepatectomy in laparoscopic surgery	Alive (peritoneal metastasis) at the 29 month postoperative follow-up
2	189	0	14	-	10	2	Unnecessary	Oxaliplatin, 5-fluorouracil, folinic acid, and panitumumab Irinotecan, 5-fluorouracil, folinic acid, and bevacizumab radiation therapy (28 Gy/29 fr)	-	-	-	Died at the 38 month postoperative follow-up
3	115	0	35	-	30	6	Unnecessary	Oxaliplatin, 5-fluorouracil, folinic acid, and bevacizumab Irinotecan, 5-fluorouracil, folinic acid, and bevacizumab	-	-	-	Alive at the 1 month postoperative follow-up (discharged and transferred to another hospital after 1 month)
4	118	0	12	-	14	3	Necessary	Capecitabine, oxaliplatin, and bevacizumab	Right hemicolectomy in open surgery	Capecitabine, oxaliplatin Tegafur/gimeracil/ oteracl and bevacizumab	Peritoneal metastasis ⇒ peritoneal metastasis dissection and small bowel resection Local recurrence ⇒ peritoneal metastasis dissection small bowel resection Ileotransversostomy	Alive at the 71 month postoperative follow-up
5	123	0	14	-	4	4	Unnecessary	-	-	-	-	Died at the 4 month postoperative follow-up

dominal organs, because of patients' severe general status and poor prognosis. Primary resection is highly dangerous for patients because they are at high risk of collateral damage, particularly during this procedure[4]. Primary resection is also indicated for unresectable right-sided colon cancer with a perforation and a retroperitoneal abscess. When a perforation is present, ileo-transverse colon bypass surgery cannot prevent the outflow of feces and subsequent infection.

The procedure is not difficult, and the operation time is relatively short. In addition, based on the low rate of leakage from the anastomosis between the upper ileum and lower transverse colon, the procedure is relatively safe. In the present study, no anastomotic leakage was detected. In this procedure, we could not suture the perforated site to stop the stool flow because the tissue around the edges of the perforated site was too fragile, and thus, it could be easily torn during suturing. However, in cases where stool drainage does not stop spontaneously, the drain must be managed for a long period. Moreover, in cases where drainage continues over the long term, it might be necessary to proceed with the primary resection. Consequently, we recommend suturing the perforated site, whenever possible.

Furthermore, we considered that drainage from the mucus fistula would be useful for avoiding retroperitoneal abscesses and for controlling the infection. Conversely, when general peritonitis occurs, this procedure is preferably avoided because this could result in anastomotic leakage.

A great advantage of this new surgical procedure over an ileostomy was that anal function could be preserved, and the patients did not require antidiarrheal drugs. Importantly, the quality of life was not compromised by the presence of a stoma at the end of life. Conversely, the advantage of an ileostomy is that the procedure is easy to perform and it is associated with a lower rate of postoperative morbidity, regardless of the patient's general condition. When the patient's general condition is poor, an ileostomy is safer than a separation of the right colon.

After creating a mucus fistula and performing an ileocolic anastomosis, the surgical trunk can sometimes become anatomically deformed. In that situation, it becomes difficult to perform a lymph node dissection, which could result in an incomplete dissection. In our two cases, at the time that conversion therapy was performed, it was not difficult to perform a lymph node dissection along the surgical trunk. This could be explained by the lack of adhesion because the first separation surgery did not require any surgical invasion around the surgical trunk, and the main tumor was in the cecum; therefore, lymph node dissections were only required around the ileocolic arteries and veins. However, in cases

where the main tumor is in the ascending colon, it might be difficult to perform lymph node dissection because of the anatomical deformity. Moreover, when patients' prognosis is poor, it is important to forego a lymph node dissection.

Separation surgery remains an option, although the indications are limited. Future studies should include an evaluation of a patient's quality of life at the end of life.

#### Conflicts of Interest

There are no conflicts of interest.

#### Author Contributions

R.M. wrote the manuscript. R.M., K.N., N.O., and M.T. designed the study. J.F. and H.O. proofread the manuscript.

#### Approval by Institutional Review Board (IRB)

The Sakai Medical Center Institutional Review Board approved the present study (approval code 124).

#### References

1. Kye BH, Lee YS, Cho HM, et al. Comparison of long-term outcomes between emergency surgery and bridge to surgery for malignant obstruction in right-sided colon cancer: A multicenter retrospective study. *Ann Surg Oncol*. 2016 Jun; 23(6): 1867-74.
2. Jimenez-Perez J, Casellas J, Garcia-Cano J, et al. Colonic stenting as a bridge to surgery in malignant large-bowel obstruction: A report from two large multinational registries. *Am J Gastroenterol*. 2011 Dec; 106(12): 2174-80.
3. Carne PW, Frye JN, Robertson GM, et al. Stents or open operation for palliation of colorectal cancer: a retrospective, cohort study of perioperative outcome and long-term survival. *Dis Colon Rectum*. 2004 Sep; 47(9): 1455-61.
4. Sawada G, Nakata K, Tsujie M, et al. Laparoscopic colectomy for colon cancer with retroperitoneal abscess treated with initial conservative therapy: A report of three cases with a literature review. *J Clin Case Rep*. 2017; 7: 6.

#### Supplementary Files

**Supplementary Video.** This video shows the method of the "Separation surgery of the right-sided colon," with endoscopic surgery. First, we examined the inside of the abdomen with a laparoscope, located the perforation, and performed abdominal irrigation. We then identified and marked the ileum and transverse colon with a crystal violet in the abdomen. We divided both, and anastomosed the upper ileum to the lower transverse colon. Next, we sutured the lower ileum to the upper transverse colon. We then created a mucous fistula with the loose ends of the lower ileum and the upper transverse colon. Finally, we placed a drain and closed the abdomen.

Please find supplementary file(s);

<http://dx.doi.org/10.23922/jarc.2020-051>

Journal of the Anus, Rectum and Colon is an Open Access journal distributed under the Creative Commons Attribution-NonCommercial-NoDerivatives 4.0 International License. To view the details of this license, please visit (<https://creativecommons.org/licenses/by-nc-nd/4.0/>).