

Augmented Reality Visualization–guided Microscopic Spine Surgery: Transvertebral Anterior Cervical Foraminotomy and Posterior Foraminotomy

Daisuke Umebayashi, MD, PhD
 Yu Yamamoto, MD
 Yasuhiro Nakajima, MD, PhD
 Nobuhisa Fukaya, MD
 Masahito Hara, MD, PhD

From the Department of Neurosurgery, Inazawa Municipal Hospital, Aichi, Japan (Dr. Umebayashi, Dr. Yamamoto, Dr. Nakajima, Dr. Fukaya, and Dr. Hara), and the Department of Neurosurgery, Kyoto Prefectural University of Medicine, Kyoto, Japan (Dr. Umebayashi).

Correspondence to:
 umebayad@gmail.com

The device(s)/drug(s) is approved by the FDA or by the corresponding national agency for this indication.

JAAOS Glob Res Rev 2018;2:e008

DOI: 10.5435/JAAOSGlobal-D-17-00008

Copyright © 2018 The Authors. Published by Wolters Kluwer Health, Inc. on behalf of the American Academy of Orthopaedic Surgeons. This is an open-access article distributed under the terms of the Creative Commons Attribution-Non Commercial-No Derivatives License 4.0 (CCBY-NC-ND), where it is permissible to download and share the work provided it is properly cited. The work cannot be changed in any way or used commercially without permission from the journal.

Abstract

Objective: We describe intraoperative augmented reality (AR) imaging to obtain a microscopic view in spine keyhole surgery.

Background: Minimally invasive keyhole surgery has been developed even for spine surgery, including transvertebral anterior cervical foraminotomy and posterior cervical laminoforaminotomy. These methods are complex and require a skillful technique. Therefore, inexperienced surgeons hesitate to perform keyhole surgeries. The technology used in surgery is rapidly advancing, including intraoperative imaging devices that have enabled AR imaging and facilitated complicated surgeries in many fields. However, data are not currently available on the use of AR imaging in spine surgery. The purpose of this article was to introduce the utility of AR for spine surgery.

Methods: We performed O-arm intraoperative imaging to create an augmented imaging model in navigation systems. Navigation data were linked to a microscope to merge the live view and AR. Augmented reality imaging shows the model plan in the real-world surgical field. We used this novel method in patients who underwent both keyhole surgeries.

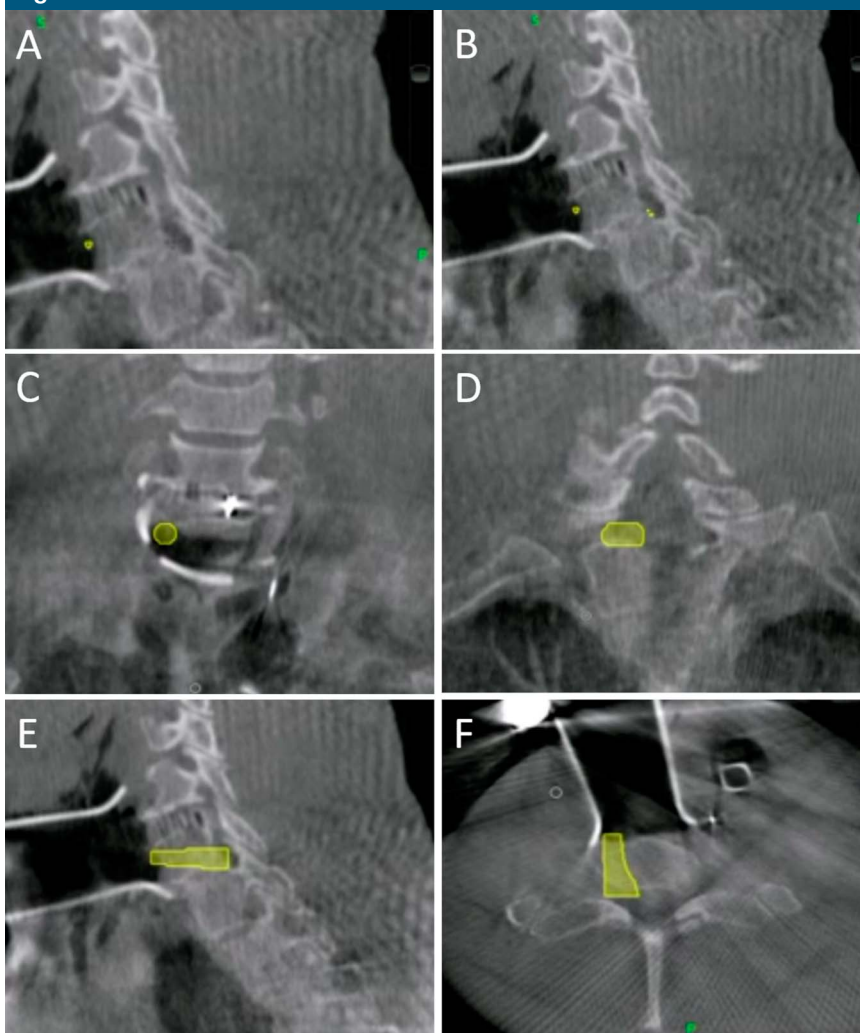
Results: We successfully performed both surgeries using the AR visualization guide.

Conclusions: The AR navigation system facilitates complicated keyhole surgeries in patients who undergo spine surgery.

Study Design: Technical report

Augmented reality (AR) is a novel technology that adds elements via computer-generated sensory data such as graphics, video, and sound in real time.¹ The technology functions by

enhancing people's current perception of reality,² replacing the real world. Advanced AR technology is becoming more popular and has been applied to car navigation systems, smart phones,

Figure 1

The authors made a start window on the ventral surface of the vertebra (A) and an end window behind the vertebra (B) by using the push cursor of the software. The remaining dots were carefully erased, and the authors confirmed the start (C) and the end (D) windows of the tunnel on coronal views. After clicking the interpolated selection cursor, a tunnel model was created (E and F).

and tablet devices. When this technology, especially location-based AR, is applied to the field of medicine, it facilitates complicated surgeries.

Minimally invasive surgery has also been developed and used in spine

surgery, including keyhole surgeries, such as transvertebral anterior cervical foraminotomy (TVACF) and posterior cervical laminoforaminotomy (PCLF). These surgical methods are more complicated than the stan-

dard, more evasive techniques, however. Anterior cervical discectomy and fusion or posterior cervical laminoplasty are the benchmarks for cervical spondylotic myelopathy and to a certain extent contribute to positive clinical outcomes in patients with cervical radiculopathy. However, most patients with unilateral radiculopathy can be treated solely with decompression of the pathologic nerve root around the foramen.

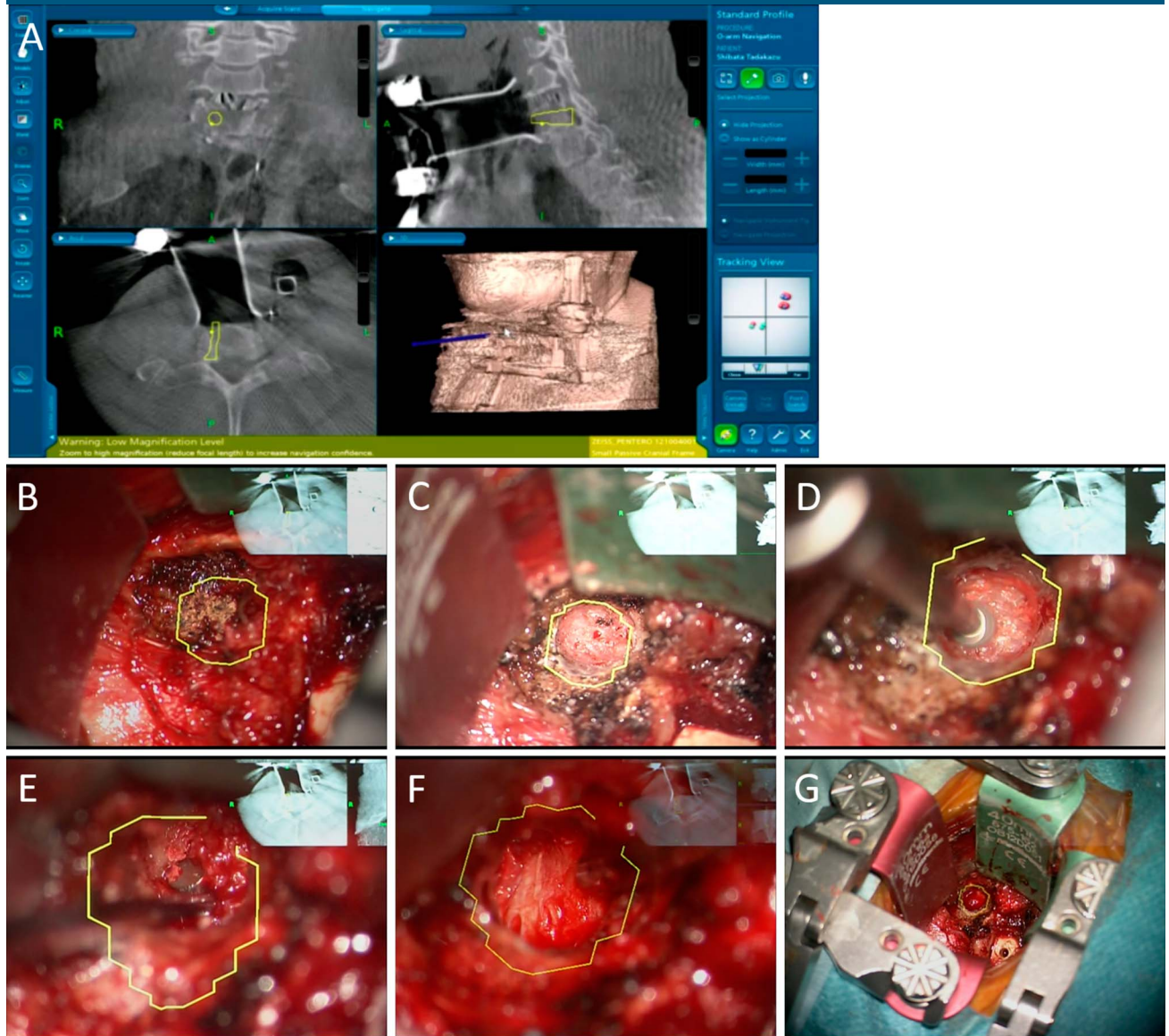
Transvertebral anterior cervical foraminotomy can be beneficial in patients with unilateral cervical radiculopathy because nonfusion and nondisectomy can preserve intervertebral motion. In addition, because most radiculopathies are caused by focal lesions of the intervertebral foramen, they do not require total discectomy and vertebral fusion.³ Especially in patients who have retained physiologic alignment, nonfusion and nondisectomy can preserve intervertebral motion. Theoretically, TVACF can reduce adjacent intervertebral degeneration compared with intervertebral fusion.

Posterior cervical laminoforaminotomy is a good option for patients who undergo posterior laminoplasty with focal severe radiculopathy. It is useful because posterior foraminotomy can be performed simultaneously in the same surgical field. However, these methods are complex and require skillful techniques, especially for controlling the appropriate drilling direction of the keyhole. The lateral and caudal side trajectory of controlling the tunnel is decided based on the findings from the cortical bone and terminal lamina of the drilled tunnel

None of the following authors or any immediate family member has received anything of value from or has stock or stock options held in a commercial company or institution related directly or indirectly to the subject of this article: Dr. Umehayashi, Dr. Yamamoto, Dr. Nakajima, Dr. Fukaya, and Dr. Hara.

Dr. Umehayashi designed research. Dr. Umehayashi, Dr. Yamamoto, Dr. Nakajima, Dr. Fukaya, and Dr. Hara performed research. Dr. Umehayashi analyzed the data and wrote the article.

Figure 2



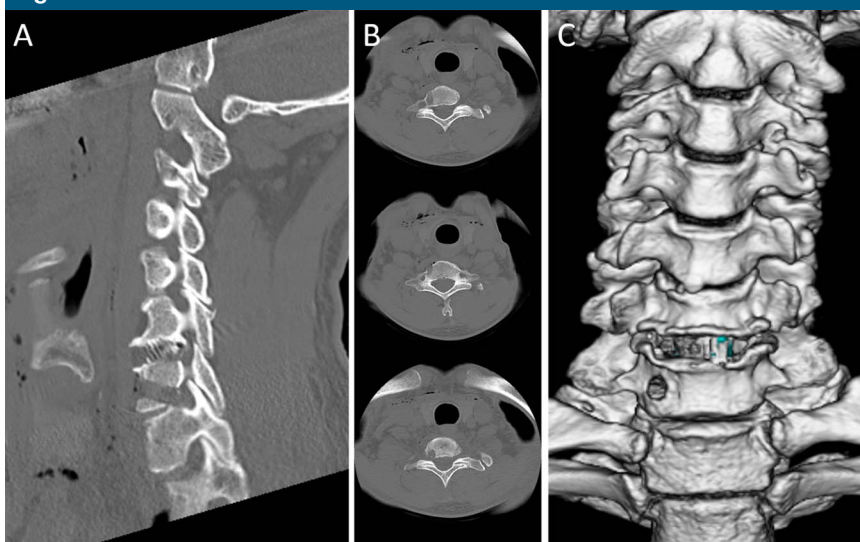
Transvertebral anterior cervical foraminotomy. **A**, Photographs showing navigation display views. **B** through **F**, Photographs showing microscopic views. **G**, Final view of the keyhole tunnel. The yellow outline in panels B through F is the outline of the tunnel model.

wall.³ This is a difficult decision that can cause some surgeons to think twice before performing keyhole surgeries.

O-arm imaging and navigation systems, however, have progressed. The navigation system helps surgeons use the correct direction of the keyhole. Augmented reality imaging is enabled by combined navigation sys-

tems, intraoperative imaging devices, and multifunctional operating microscopes. For example, AR imaging in a microscopic view has been used in brain surgery to create appropriate boundaries of brain tumor resection or vascular components. Augmented reality facilitates such complicated surgeries in many fields. To our knowledge however, no data are

available on AR imaging in patients undergoing spine surgery, especially in complicated procedures such as TVACF or PCLF, although AR could facilitate them. The purpose of this article was to introduce the utility of AR for spine surgery. We think that AR facilitates complicated keyhole surgery even for inexperienced surgeons.

Figure 3

Postoperative sagittal (A) and axial (B) CT demonstrating that the bone defect of the vertebra is very small. C, Postoperative reconstructed three-dimensional CT image. A small tunnel window is seen on the right side of the C7 vertebra.

Methods

We approached the surface of the vertebra or lamina lesion using the respective surgical method. We then determined the appropriate retractor positions and kept them in the same position throughout the surgery. Doing so is important because this navigation technique requires accuracy within <1 mm. O-arm intraoperative imaging (Medtronic) was taken to make an augmented imaging model in the navigation system (StealthStation S7 Surgical Navigation System; Medtronic). At first, each starting and ending point of the expected keyhole tunnel was marked as a dot on the axial views (Figure 1, A and B). While referring to these dots, we made a start window on the ventral surface of the vertebra and an end window behind the vertebra using the software's push cursor on the coronal views (Figure 1, C and D). The remaining dots were then carefully erased, and we confirmed the start and the end windows on axial views; the start and the end windows

were interpolated using the software's interpolated selection cursor (Figure 1, E and F). If the dots remained, the interpolated step would have failed. Navigation data were then transferred and linked to the microscope (Opmi Pentero 900; Zeiss Meditec) to merge the live view and AR microscopic view. We used this novel method in patients who underwent TVACF and posterior foraminotomy.

Results

Transvertebral Anterior Cervical Foraminotomy

A Representative Case

A 63-year-old man presented with pain in the right scapula to the ulnar forearm. Conservative therapy had no effect.

Preoperative Examination

Neurologic examination on admission showed right wrist extensor weakness, dyesthesia in the right ulnar forearm, no pathologic reflex,

and general hyporeflexia in deep tendon reflex. The Spurling sign was positive on the right side. MRI revealed a bilateral C7 root sleeve defect and a right C8 root sleeve defect. We scheduled a C6-7 anterior cervical discectomy and fusion and right C7-T1 TVACF.

Surgery

The C6-7 anterior cervical discectomy and fusion was performed as usual, without any problem. How to make the AR model of TVACF (Figure 2, A; Supplemental Digital Content 1, <http://links.lww.com/JG9/A4>). The AR imaging model was reflected on the microscopic view (Figure 2, B; Supplemental Digital Content 1, <http://links.lww.com/JG9/A4>). The yellow circle is the outline of the tunnel. The surgeon drilled the vertebral bone just along this outline (Figure 2, C and D), reached a herniated disc, and removed it (Figure 2, E and F). The final view of the keyhole tunnel is compatible with the AR model (Figure 2, G).

Postoperative Course

The postoperative course was uneventful, and no neurologic deficit was observed. The patient's pain in the right arm diminished after surgery. Postoperative CT nearly corresponded to the intraoperative AR model (Figure 3). There has been no recurrence for the past 20 months.

Posterior Cervical Laminoforaminotomy

A Representative Case

A 76-year-old man presented with dyesthesia in the second and third fingers of his left hand. The patient felt elaborate motor deficit bilaterally. Conservative therapy had no effect.

Preoperative Examination

Neurologic examination on admission showed weakness in the left

deltoid, biceps, and wrist extensor; no pathologic reflex; and hypoflexia in the left biceps and brachioradialis tendon reflexes. The Spurling sign was positive on the left side. MRI revealed developmental spinal canal stenosis at C3-6 and a left C6 root sleeve defect. We scheduled C3-6 laminoplasty and a left C5-6 PCLF.

Surgery

How to make the AR model of PCLF is shown in Figure 4, A. (Supplemental Digital Content 2, <http://links.lww.com/JG9/A5>). The AR imaging model was reflected on the microscopic view (Figure 4, B; Supplemental Digital Content 2, <http://links.lww.com/JG9/A5>). The yellow outline is the outline of the tunnel. The surgeon drilled the vertebral bone just along this outline (Figure 4, C and D), reached a herniated disc, and removed it (Figure 4, E). The final view of the keyhole tunnel is compatible with the AR model. After that, C3-6 double door laminoplasty was performed as usual, without any problem.

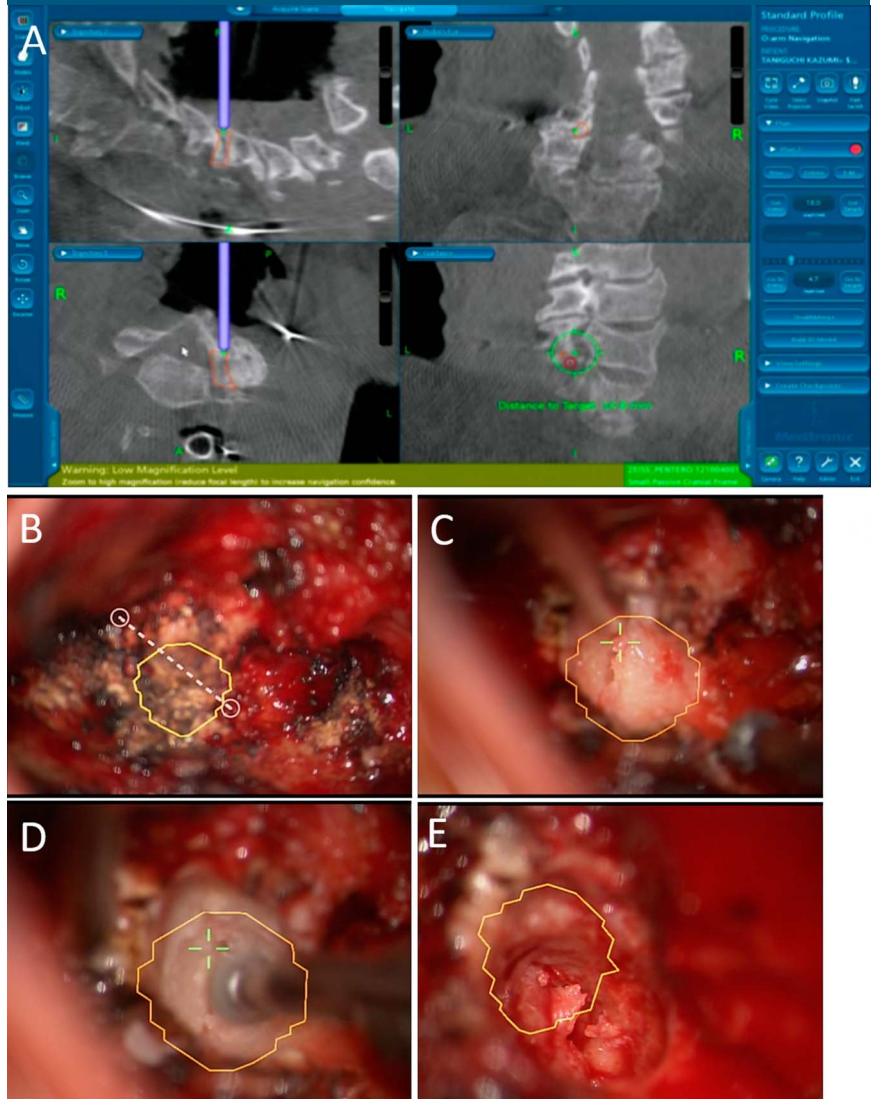
Postoperative Course

The postoperative course was uneventful, and no neurologic deficit was observed. His pain in the left arm reduced after surgery. Postoperative CT nearly corresponded to the intraoperative AR model (Figure 5). There has been no recurrence for the past 20 months.

Discussion

Successful surgery is possible with guided AR visualization combined with O-arm imaging and navigation systems. This technique facilitates complicated keyhole surgeries in the spine. Augmented reality navigation eliminates surgeons' hesitation associated with the orientation of the surgical field. In addition, it allows inexperienced surgeons to safely

Figure 4

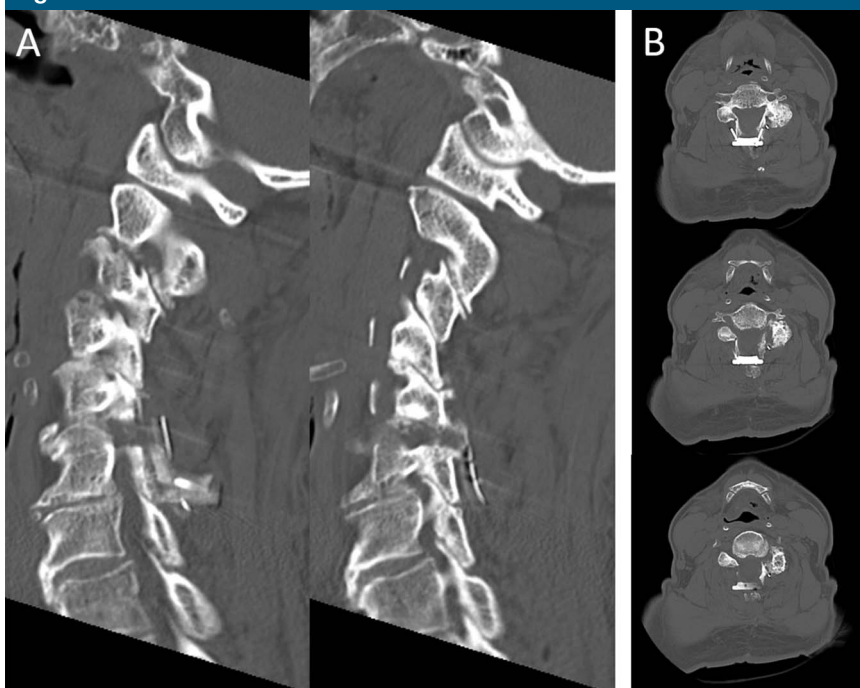


Posterior cervical laminoforaminotomy. **A**, Photographs showing navigation display views. **B** through **E**, Photographs showing microscopic views. The yellow circle is the outline of the tunnel model.

perform complicated surgeries. As a result, keyhole spine surgery may become more widely used among spine surgeons.

It enables surgeons to navigate the electric drill using a sure-track indicated on the navigation map. It is also useful when deciding the accurate direction of surgery. However, navigation without the real-time microscopic view results in deviating a little from accurate surgical planning in very fine surgical fields, such as key-

hole surgeries. A 1-mm error can lead to unsuccessful keyhole surgeries because TVACF and PCLF are performed in the 6-mm tunnel. Furthermore, although standard navigation shows a point only on the navigation display, AR imaging shows the model plan in the real-world surgical field.^{4,5} Although some researchers have reported surgery using image injection into the microscope,⁶⁻⁹ no data are available for spine surgery.

Figure 5

Postoperative sagittal (A) and axial (B) CT images demonstrating that the bone defect of the lamina is very small. A small tunnel window is connected to the left foramen at C5-6.

Augmented reality imaging in a microscopic view has also been used for brain surgery. However, brain shift occurs because of a loss of cerebrospinal fluid following an error in navigation after dural incision. However, keyhole spine surgeries have no association with the brain shift. Therefore, keyhole spine surgeries are preferable to the AR navigation system.

Two groups have reported on the application of AR imaging in spinal surgery.^{10,11} However, almost all reports used special devices that are not usually used in surgeries. One of the strengths of our AR method is that we used only devices that are

already used in brain surgery. As a result, our method is more economical and practical for many surgeons in the Department of Neurosurgery. Although keyhole spine surgery is difficult and complicated, AR technology overcomes these problems.

Acknowledgments

The authors thank K. Hirata for navigation system technical assistance. They also thank Y. Tsuzuki and M. Koshizuka for their radiographic technical assistance and K. Ando and S. Oyama for the set-up

and arrangement of the operating room.

References

1. Shuhaiber JH: Augmented reality in surgery. *Arch Surg* 2004;139:170-174.
2. Graham M, Zook M, Boulton A: Augmented reality in urban places: Contested content and the duplicity of code. *Trans Inst Br Geogr* 2012;38:464-479.
3. Umebayashi D, Hara M, Nakajima Y, et al: Transvertebral anterior cervical foraminotomy: Midterm outcomes of clinical and radiological assessments including the finite element method. *Eur Spine J* 2013;22:2884-2890.
4. Cabrilo I, Bijlenga P, Schaller K: Augmented reality in the surgery of cerebral aneurysms: A technical report. *Neurosurgery* 2014;10(suppl 2):252-260; discussion 260-261.
5. Cabrilo I, Bijlenga P, Schaller K: Augmented reality in the surgery of cerebral arteriovenous malformations: Technique assessment and considerations. *Acta Neurochir (Wien)* 2014;156:1769-1774.
6. Edwards PJ, Hawkes DJ, Hill DL, et al: Augmentation of reality using an operating microscope for otolaryngology and neurosurgical guidance. *J Image Guid Surg* 1995;1:172-178.
7. Edwards PJ, King AP, Hawkes DJ, et al: Stereo augmented reality in the surgical microscope. *Stud Health Technol Inform* 1999;62:102-108.
8. King AP, Edwards PJ, Maurer CR Jr, et al: A system for microscope-assisted guided interventions. *Stereotact Funct Neurosurg* 1999;72:107-111.
9. Nijmeh AD, Goodger NM, Hawkes D, et al: Image-guided navigation in oral and maxillofacial surgery. *Br J Oral Maxillofac Surg* 2005;43:294-302.
10. Abe Y, Sato S, Kato K, et al: A novel 3D guidance system using augmented reality for percutaneous vertebroplasty: Technical note. *J Neurosurg Spine* 2013;19:492-501.
11. Kockro RA, Tsai YT, Ng I, et al: Dex-ray: Augmented reality neurosurgical navigation with a handheld video probe. *Neurosurgery* 2009;65:795-807.