JACC: CASE REPORTS VOL. 29, 2024

IMAGING VIGNETTE

CLINICAL VIGNETTE

Polymicrobial Purulent Pericarditis From a Pancreatico-Pericardial Fistula

Christopher Richardson, DO,[a] Mark Cromer, MD,[b] Luis Tatem, MD,[a] Raymond Wade, MD,[a] Derek Russell, MD[a]

ABSTRACT

A 54-year-old male with chronic pancreatitis presented with dyspnea. Computed tomography scans demonstrated a subdiaphragmatic fluid collection with pericardial fistulization. Pericardial fluid cultures were polymicrobial in nature. Purulent pericarditis is rare but carries a high mortality rate. We present the first documented case of pancreatico-pericardial fistulization causing purulent pericarditis. (J Am Coll Cardiol Case Rep 2024;29:102288) © 2024 The Authors. Published by Elsevier on behalf of the American College of Cardiology Foundation. This is an open access article under the CC BY-NC-ND license (http://creativecommons.org/licenses/by-nc-nd/4.0/).

A 54-year-old male with decompensated alcoholic cirrhosis and chronic pancreatitis complicated by pseudocyst status post recent cystogastrostomy with stent placement presented to the emergency department with 4 days of dyspnea. He was febrile, tachycardic, and tachypneic, but normotensive and normoxemic. Physical examination was notable for cachexia and toxic appearance with diminished heart and lung sounds and epigastric tenderness. Chest x-ray revealed large bilateral pleural effusions and enlarged mediastinal silhouette. Echocardiogram revealed a moderate-to-large pericardial effusion without evidence of tamponade. Computed tomography (CT) of the chest and abdomen showed a subdiaphragmatic fluid collection near the previously decompressed pseudocyst with fistulization to the adjacent pericardium (**Figure 1**). Pericardiocentesis was performed with 350 mL of purulent exudate. The pericardial effusion re-accumulated in 3 days requiring pericardial window with pericardial drain placement. Pericardial fluid and tissue cultures grew *Acinetobacter baumannii*, *Enterococcus faecalis*, *Enterobacter cloacae*, *Achromobacter xylosoxidans*, and yeast. Given the patient's frailty and comorbidities, he was not a candidate for surgical fistulectomy, so a subdiaphragmatic drain was placed percutaneously under CT guidance. Both drainage tubes were removed 10 days post-placement, and the pericardial effusion did not reaccumulate. With assistance from infectious disease specialists and culture sensitivities, the patient initiated ampicillin/sulbactam, ciprofloxacin, and fluconazole for 6 weeks of antibiotic therapy. The patient improved and was discharged home with plans for repeat CT imaging and follow-up with gastroenterology and cardiothoracic surgery.

Purulent pericarditis (PP) is rare, comprising <1% of all infective pericarditis cases.[1] PP occurs most commonly secondary to trauma, thoracic surgery, or hematogenous spread.[1] In treated patients, the associated mortality has been reported as high as 40%.[2] Common organisms are staphylococcus, streptococcus, haemophilus, and mycobacterium.[1] Polymicrobial infections are uncommon.[1,2] Treatment consists of pericardial drainage and antibiotics.[1,2] Those with PP are at high risk for developing cardiac tamponade, occurring at initial

From the [a]Division of Pulmonary, Allergy, & Critical Care Medicine, School of Medicine, The University of Alabama at Birmingham, Birmingham, Alabama, USA; and the [b]Division of Internal Medicine, School of Medicine, The University of Alabama at Birmingham, Birmingham, Alabama, USA.
The authors attest they are in compliance with human studies committees and animal welfare regulations of the authors' institutions and Food and Drug Administration guidelines, including patient consent where appropriate. For more information, visit the Author Center.

Manuscript received November 5, 2023; revised manuscript received January 5, 2024, accepted February 15, 2024.

ISSN 2666-0849 https://doi.org/10.1016/j.jaccas.2024.102288

ABBREVIATIONS AND ACRONYMS

CT = computed tomography

PP = purulent pericarditis

presentation 42% to 77% of the time.[2,3] Delayed treatment may lead to irreversible pericardial fibrosis causing constrictive pericarditis, typically occurring after 14 days.[1,2]

Those with PP frequently experience effusion re-accumulation.[2] There is an absence of randomized controlled trials evaluating the most effective strategy for pericardial drainage in PP. Retrospective data indicate that both surgical pericardial window and pericardiocentesis are safe, but a surgical approach is more likely to achieve complete pericardial drainage reducing the need for repeat procedures.[2] Intrapericardial fibrinolysis may be an option for poor surgical candidates.[2]

The organisms isolated from this patient's pericardial fluid are consistent with gastrointestinal flora often cultured in intra-abdominal abscesses, making this patient's polymicrobial pericarditis only plausible with a direct pericardial connection to the abdominal cavity. Cases of pancreatico-pericardial fistulas are rarely reported in the literature and develop in the setting of acute or chronic pancreatitis.[3] Fistula formation occurs from leakage of pancreatic secretions causing spontaneous erosion into adjacent structures.[3]

To our knowledge, this is the first documented case of PP from an infected pancreatic pseudocyst with fistulization to the pericardium. This case highlights the importance of early recognition and treatment of infectious pericardial effusions and describes a setting in which pancreatic-pericardial fistula may occur.

FUNDING SUPPORT AND AUTHOR DISCLOSURES

The authors have reported that they have no relationships relevant to the contents of this paper to disclose.

ADDRESS FOR CORRESPONDENCE: Dr Christopher C. Richardson, Division of Pulmonary, Allergy, & Critical Care Medicine, School of Medicine, The University of Alabama at Birmingham, 1900 University Blvd, Tinsley Harrison Tower, Suite 422, Birmingham, Alabama 35294, USA. E-mail: Christopher.charles.richardson@gmail.com.

FIGURE 1 Computed Tomography of Chest and Abdomen Demonstrating Pancreatico-Pericardial Fistula

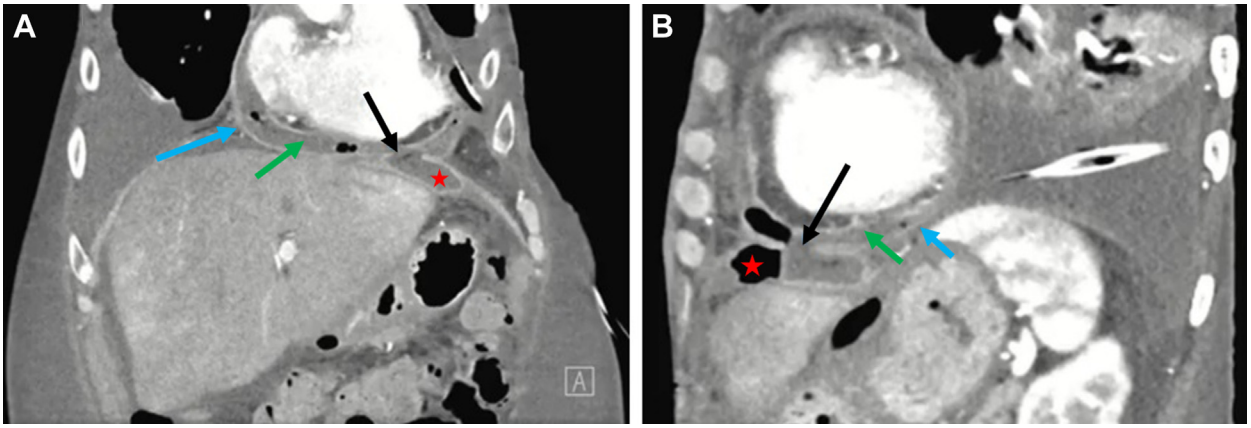

(A) Coronal and (B) sagittal computed tomography chest and abdomen images show a patent fistula tract (black arrow) with a 4.8 × 5.7 × 1.2 cm gas- and fluid-filled, subdiaphragmatic pancreatic pseudocyst (red star) and adjacent pericardium. Multiloculated complex pericardial effusion predominates inferiorly, measuring 1.4 cm at greatest thickness (green arrow). There is circumferential thickened inflamed pericardium (blue arrow).

REFERENCES

1. Adler Y, Charron P, Imazio M, et al. 2015 ESC guidelines for the diagnosis and management of pericardial diseases: the task force for the diagnosis and management of pericardial diseases of the European Society of Cardiology (ESC) endorsed by: the European Association for Cardio-Thoracic Surgery (EACTS). *Eur Heart J*. 2015;36(42):2921-2964. https://doi.org/10.1093/eurheartj/ehv318

2. Pankuweit S, Ristić AD, Seferović PM, Maisch B. Bacterial pericarditis: diagnosis and management. *Am J Cardiovasc Drugs*. 2005;5(2):103-112. https://doi.org/10.2165/00129784-200505020-00004

3. Khan MS, Shahbaz N, Zia HA, Hamza M, Iqbal H, Awab A. Pancreaticopericardial fistula: a case report and literature review. *Case Rep Crit Care*. 2016;2016:7169341. https://doi.org/10.1155/2016/7169341

KEY WORDS computed tomography, imaging, pancreatic pseudocyst, pancreatitis, pericardial effusion, pericarditis, tamponade, thoracic