

Updates on the use of ureteral stents: focus on the Resonance[®] stent

Manoj V Rao
Anthony J Polcari
Thomas MT Turk

Department of Urology,
Loyola University Medical Center,
Maywood, IL, USA

Abstract: The Resonance[®] metallic ureteral stent is one of the latest additions to the urologist's armamentarium in managing ureteral obstruction. One advantage of this stent over traditional polymer-based stents is resistance to encrustation with stone material, which allows longer dwell times and less frequent exchange procedures. Although exchanging a metallic stent is slightly more complicated than exchanging a polymer stent, the fluoroscopic techniques required are familiar to most urologists. The Resonance stent is also more resistant to compression by external forces, potentially allowing greater applicability in patients with metastatic cancer. Furthermore, the use of this stent in patients with benign ureteral obstruction is shown to be associated with significant cost reduction. Clinical studies on the use of this stent are accumulating and the results are mixed, although Level 1 evidence is lacking. In this article we present a comprehensive review of the available literature on the Resonance metallic ureteral stent.

Keywords: resonance, metallic, ureteral, stent, obstruction

Development and use of ureteral stents

Ureteral obstruction is a common urologic problem. It can be caused by both benign and malignant conditions, resulting in either extrinsic or intrinsic forces which block the flow of urine from the kidney to the bladder. First described by Zimskind et al in 1967, ureteral stents serve as a means of bypassing a narrowed portion of ureter, allowing effective urine drainage.¹ Until the development of ureteral stents, there were few options available for managing ureteral obstruction in a minimally invasive manner.

Ureteral stents now have a broad range of clinical uses. Stents may be employed on a short-term basis, such as in patients with obstructing stones or to maintain drainage and allow healing of the ureter following a surgical procedure. In other cases, they serve as a long-term solution. In patients with benign lesions such as strictures, the most desirable option is surgical reconstruction to allow effective urine drainage without the need for an indwelling prosthetic device. However, not all patients are candidates for these potentially difficult surgeries and some prefer a less invasive approach. These patients may be managed with ureteral stents. In addition, patients with metastatic cancers of the retroperitoneum and pelvis that cause ureteral obstruction are also commonly managed with ureteral stents on a chronic basis. In this situation they prevent kidney damage caused by longstanding obstruction, maximize renal function so that chemotherapy may be administered, and minimize pain and infectious complications.

Although ureteral stents have revolutionized urologic practice, they are not without limitation. Most stents in use today are composed of synthetic polymers and quickly

Correspondence: Thomas MT Turk
Department of Urology, Loyola
University Medical Center, Building 54,
Room 200 Maywood, IL 60153, USA
Tel +1 708 216 8152
Fax +1 708 216 1699
Email tturk@lumc.edu

become encrusted with stone material, requiring exchange under anesthesia every 3–4 months.² Stent-related urinary symptoms, including urinary frequency, urgency, dysuria, hematuria, and pain, may affect up to 80% of patients.³ Although most of the time these symptoms are minor and readily controllable, occasionally they are severe enough to require discontinuation of the stent. As with many foreign materials inserted into the body, ureteral stents may become coated in biofilm and colonized with bacteria.⁴ Finally, traditional polymer-based stents fail to relieve obstruction from malignant disease of the retroperitoneum in up to 50% of cases.^{5,6} In this case, a nephrostomy tube is typically placed to drain the renal pelvis. Although these tubes provide adequate drainage in the vast majority, they require an external urine collection bag, so many patients prefer an indwelling ureteral stent.

Design of the Resonance metallic ureteral stent

The Resonance[®] stent was initially developed by Cook Urological as a management option for malignant ureteral obstruction. The stent is composed of a tightly coiled wire made of nickel-cobalt-chromium-molybdenum alloy. Although it has proximal and distal curls and a patent lumen similar to traditional “double-J” stents, its ends are occluded (Figure 1). Although many indwelling metallic devices preclude patients from having magnetic resonance imaging (MRI) studies, the Resonance stent is MRI-compatible.

The occluded ends of the Resonance stent make its placement and exchange slightly more challenging than a traditional stent. Rather than using a cystoscope to place a wire up to the renal pelvis and advancing the stent over the wire, the Resonance stent is inserted through an 8 French outer sheath advanced into the renal pelvis. Thus, a slightly larger diameter instrument must be passed through the narrowed ureter, which in rare instances requires balloon dilation of the ureter.^{7–9} In addition, when the metallic stent is exchanged, a wire must be advanced up the ureter alongside the stent rather than through it. When the ureteral orifice is obliterated by a tumor, this may be difficult.

A study by Christman et al found the Resonance metallic stent could maintain 50% diameter with over 31 lb of compression force placed on its proximal, mid, and distal portions (32.89 ± 0.34 , 31.79 ± 0.16 , and 31.4 ± 0.33 lb, respectively).¹⁰ The force required to compress the Resonance stent was significantly greater than that for the Silhouette[®], Sof-Curl[®], Percuflex[®], and Polaris Ultra[®] stents. The reason for this increased tensile strength has been attributed to the design of the wire coil, ie, extrinsic force applied to the

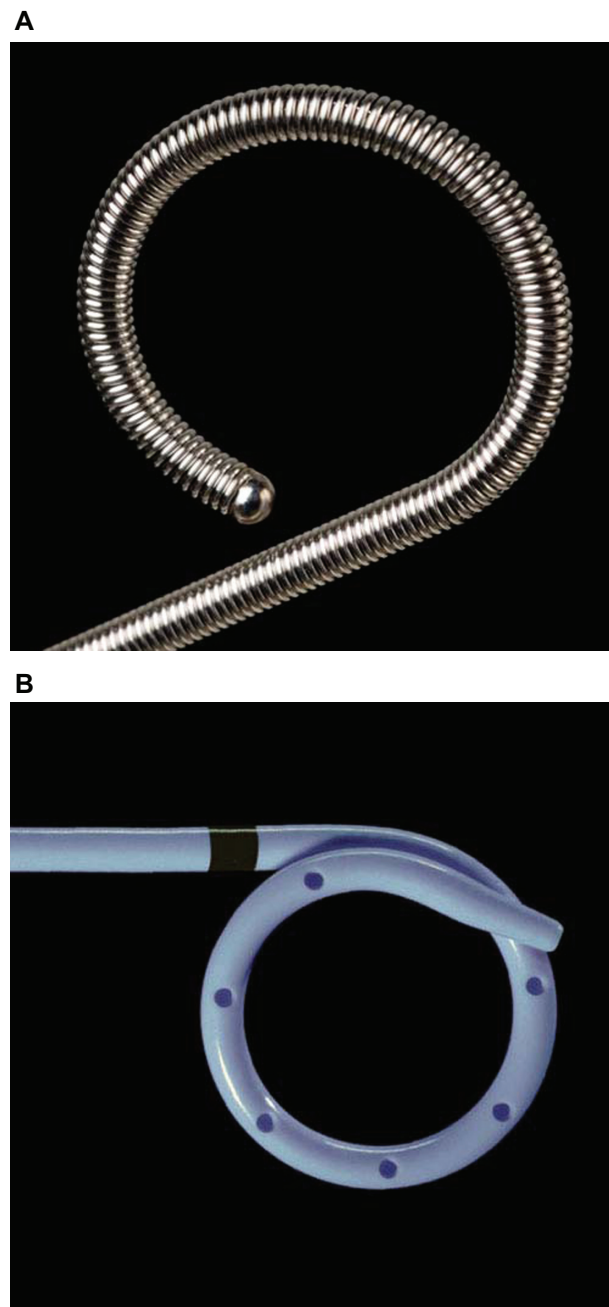


Figure 1 **A)** The Resonance[®] metallic ureteral stent **B)** The Cook Endo-Sof[™], a traditional polymer stent. Permission for use granted by Cook Medical Incorporated, Bloomington, Indiana.

Resonance stent leads to flexion to one side of the coil rather than compression and buckling.

Blaschko et al performed a study comparing flow dynamics between the Resonance and a standard 6 French stent. First they used a model in which there was no compression, and found that the traditional stent actually had better intra- and extraluminal flow rates. However, when obstruction was simulated by tying a 0-silk suture around the ureter, the traditional stent could be occluded, whereas

the Resonance stent maintained patency. The flow through the metallic stent in this model was 5.15 mL/min compared with 0.64 mL/min in the traditional stent.¹¹ This was the first mechanical model to demonstrate superior resistance to external compression. These findings were supported by Pedro et al who also showed that the Resonance is more resistant to extrinsic compression than stents which are not coil-reinforced.¹²

Efficacy studies

Malignant obstruction

As mentioned previously, extrinsic ureteral obstruction from malignant masses of the retroperitoneum and pelvis are one of the primary uses for the Resonance stent. Failure rates of nearly 50%^{5,6} are seen with traditional stents, and risk factors for failure include underlying renal insufficiency, the administration of chemotherapy or radiotherapy, and evidence of bladder involvement with malignant process.^{13,14} However, studies done on metallic stents in the setting of malignant extrinsic compression have shown promise.

Wah et al reported an 80% success rate among 15 patients with malignant disease. In this series, the authors utilized ante-grade nephrostogram studies via existing nephrostomy tubes to diagnose the three failures. They attributed the failure of the Resonance stent to a bulky metastatic tumor burden in the pelvis which caused elevated intravesical pressures and thus poor upper tract drainage.⁷ We previously reported a success rate of 80% in 10 patients with extrinsic upper tract compression secondary to malignancy. Two patients had stents changed after at least one year of use, two died of malignancy prior to the expected 12-month dwell time, and four others maintained adequate drainage at a mean follow-up of six months.¹⁵

Liatkos et al reported on a large series of patients in which the Resonance stent was used for a variety of obstructive etiologies. In the subgroup of 25 patients with malignant obstruction, there was a 100% stricture patency rate at a mean of 11 months follow-up.⁸ A recent case series by Brown et al of five patients with malignant extrinsic compression treated with the Resonance stent was less favorable. All of the patients in this series had failed management with a variety of other stent types prior to placement of the Resonance stent. Four of five patients (80%) developed renal obstruction following metallic stent placement and required nephrostomy drainage despite the fact that most of the patients died of their malignancy within several months.¹⁶

Finally, a multi-institutional experience of 40 patients (59 renal units) was recently published by Modi et al. Forty-four renal units were stented due to active malignancy, and

39 of these had failed previous plastic stents. Patients were followed with periodic imaging studies and creatinine levels. Hydronephrosis was stable or improved in 87% and worsened in 13% of renal units. Serum creatinine values were improved or stable in 65%. At last follow-up, five patients were kept from nephrostomy tubes because of the metallic stent, and 37% of the metallic stents placed because of plastic stent failure in the setting of malignancy also failed. The authors concluded that while the metallic stent can keep some patients from nephrostomy tubes, close follow-up to monitor signs of obstruction and patient symptoms is warranted. These authors recommended upper tract imaging at four weeks after placement and regular intervals thereafter.⁹

Thus, the experience to date with the metallic ureteral stent for malignant obstruction has been mixed and is summarized in Table. While some series report excellent success rates, others have been less favorable. Taken as a whole, it is clear that a number of patients with retroperitoneal malignancies can benefit from the Resonance stent. However, failures do occur, and it is unclear whether these are due to external compression, obstruction of the inner stent lumen, or elevated bladder pressures from bulky pelvic disease. Thus, patients with metastatic cancer in whom the Resonance is placed should be followed closely with periodic laboratory and imaging studies.

Benign obstruction

Benign causes of upper urinary tract obstruction are quite numerous, and include iatrogenic strictures, stone disease, retroperitoneal fibrosis, ureteropelvic junction obstruction, and endometriosis. When patients with benign lesions are managed with traditional indwelling stents, stent failure is generally less common than with malignant lesions. Several groups have reviewed their experience with the Resonance stent for benign obstruction.

In a series reviewing the utility of Resonance metallic stents for benign disease, we reported a success rate

Table Reported success rates of the Resonance® metallic ureteral stent

	Benign disease	Malignant disease
Wah et al ⁷		80% (12/15)
Polcari et al ²⁰	93% (13/14)	80% (8/10)
Liatsikos et al ⁸	56% (10/18)*	100% (25/25)
Brown et al ¹⁶		20% (1/5)
Nagele et al ²¹	75% (3/4)	54% (6/13)
Modi et al ⁹	100% (2/2)	62% (24/39)
Garg et al ¹⁸	10% (1/10)	

Notes: *Includes failures in 6/7 patients with ureteroenteric anastomotic strictures and severe iatrogenic strictures; *study includes only patients with ureteroenteric anastomotic strictures.

of 93% among 14 patients who were previously managed with polymer-based stents.¹⁵ The cause of obstruction were ureteropelvic junction obstruction in seven, benign stricture in three, idiopathic retroperitoneal fibrosis in two, ureteral tortuosity in one, and endometriosis in another. Two of the patients with ureteropelvic junction obstruction and the one patient with endometriosis required bilateral stent drainage. The one failure occurred in a tortuous ureter which was previously managed with two ipsilateral polymer stents. There was no gross encrustation or hyperplastic urothelial reaction of the stent noted at interval stent exchange in any patient. The metallic stent was discontinued prematurely for symptoms in three patients, with two being secondary to irritative lower urinary tract symptoms and the other due to recurrent gross hematuria. Of the two patients with voiding symptoms, one resolved with polymer stent placement and the other eventually required nephrostomy tube placement for refractory symptoms following polymer stent exchange. The patient with recurrent gross hematuria experienced resolution of this issue following polymer stent placement.

Liatsikos et al also evaluated the efficacy of the Resonance metallic stent in the setting of benign disease. In their series of 18 patients with obstruction from benign causes, only 44% of patients maintained patency after a mean of seven months. Failure was defined as worsening dilation of the pelvicalyceal system on imaging studies, or in cases where bilateral metallic stents were placed as a rising serum creatinine level. When the Resonance stent failed, it tended to occur within a few weeks. Of note, seven of eight failures occurred in patients with ureteroenteric or severe iatrogenic strictures. The authors noted a hyperplastic reaction which actually grew through the coils of the stent in these cases. At the time of replacement, 12 of 54 stents displayed evidence of gross calcification, but this did not complicate removal in any case.⁸

Ureteroenteric anastomotic strictures are more difficult to manage. They occur at the site where the ureter is implanted into a segment of bowel, and are thought to be caused by ischemia of the ureter.¹⁷ Garg et al reviewed their experience with the management of ureteroenteric anastomotic strictures using the Resonance stent in 10 patients. They noted distal migration of the stent in nine of 10 (90%) patients, prompting the authors to replace the metallic stent with traditional polymer stents. The authors hypothesized that the increased weight of the metallic stent along with the antegrade intestinal motility were the factors behind the distal migration and Resonance stent failure.¹⁸ Interestingly, proximal or distal migration of the stent has not been a significant issue among patients in other series with intact urinary tracts.

In general, the results for benign strictures have been favorable, with the notable exceptions being ureteroenteric or severe iatrogenic strictures (see Table).

Tolerability and resistance to encrustation

One of the main drawbacks of using ureteral stents in any clinical situation is the high incidence of stent-related side effects. In one study comparing the symptoms associated with soft and firm polymer ureteral stents using a validated questionnaire, overall 90% of patients reported urinary symptoms causing bother. Overall 70% of patients reported hematuria, 70% experienced dysuria, and almost 90% reported pain that interfered with daily life. There was no significant difference in the impact on quality of life between the soft and firm stents. Thirteen percent of patients across both groups required early stent removal.¹⁹

Although there have not been any studies comparing stent symptoms between the Resonance stent and polymer stents, several series have reported on the general tolerability of the Resonance stent. In our series of 25 patients who had a minimum of 12 months of follow-up, four (16%) patients required premature stent removal, two for severe lower urinary tract symptoms, one for recurrent gross hematuria, and one for recurrent urinary tract infections. Four other patients in our series (total 25%) experienced several urinary tract infections with the metallic stent in place. Although there was a mild amount of stone debris, ie, “dust”, noted grossly upon exchange, this was not severe enough to complicate stent removal in any of the cases.²⁰ In the series by Liatsikos et al analyzing 50 patients, six patients (12%) developed macroscopic hematuria, all of which resolved spontaneously, and 10 presented with slight discomfort from bladder irritation. Four of the 10 that presented with bladder symptoms had culture-proven urinary tract infections and were treated with antibiotics. Although macroscopic encrustation was seen on 12 of 54 stents after a mean follow-up of 8.5 months, this did not complicate stent removal in any case.⁸

Nagele et al reported a slightly higher rate of side effects, with six of 14 patients requiring premature removal, as a result of pain in two, encrustation in two, hematuria in one, and recurrent infections in one.²¹ The series by Modi et al noted significant encrustation of three of 76 stents (4%). One of these required percutaneous nephrolithotomy and another required cystolithotomy for removal, despite dwell times of less than one year.⁹

In a recent study of six patients by Cauda et al the Resonance stent was left in place for increasing durations ranging from six to 36 months. At the end of the study period,

each stent was examined by scanning electron microscopy and energy dispersive spectroscopy. Although a bacterial biofilm was found on all stents, only slight precipitation of inorganic compounds was observed, with no epithelial ingrowth. All stents were draining well at the time of removal, with stable imaging results and creatinine levels.²²

Cost effectiveness

One study to date has examined the cost effectiveness of the Resonance stent. Among 13 patients with ureteral obstruction of benign etiology, the yearly cost of metallic stent use was compared with that of polymer stent use. Even after adjusting for early removal in three of the 13 patients, the metallic stent was associated with an annual cost reduction of \$10,394 (43%) per patient per year.²³

Conclusion

The Resonance metallic ureteral stent is a new cost-effective alternative to polymer-based ureteral stents for select patients with upper urinary tract obstruction. The potential advantages of metallic ureteral stents include greater tensile strength and resistance to encrustation allowing increased dwell times. Based mainly on retrospective data, the results among patients with benign strictures, excluding those with severe iatrogenic and ureteroenteric strictures, are promising. Although the metallic stent allows adequate drainage in some patients with malignant obstruction than traditional stents, these stents require close follow-up of patients because failures do occur. A prospective study directly comparing the tolerability of metallic and polymer stents is needed because both are associated with side effects in a large proportion of patients.

Disclosure

The authors report no conflicts of interest in this work.

References

1. Zimskind PD, Fetter TR, Wilkerson JL. Clinical use of long-term indwelling silicone rubber ureteral splints inserted cystoscopically. *J Urol*. 1967;97:840.
2. Venkatesan N, Shroff S, Jayachandran K, Doble M. Polymers as ureteral stents. *J Endourol*. 2010;24:191–198.
3. Miyaoka R, Monga M. Ureteral stent discomfort: Etiology and management. *Indian J Urol*. 2009;25:455–460.

4. Bonkat G, Rieken M, Rentsch CA, et al. Improved detection of microbial ureteral stent colonisation by sonication. *World J Urol*. 2010 Mar 21. [Epub ahead of print].
5. Docimo SG, Dewolf HG. High failure rate of indwelling ureteral stents in patients with extrinsic obstruction: Experience at 2 institutions. *J Urol*. 1989;142:277–279.
6. Feng MI, Bellman GC, Shapiro CE. Management of ureteral obstruction secondary to pelvic malignancies. *J Endourol*. 1999;13:521–524.
7. Wah TM, Irving HC, Cartledge J. Initial experience with the resonance metallic stent for antegrade ureteric stenting. *Cardiovasc Intervent Radiol*. 2007;30:705–710.
8. Liatsikos E, Kallidonis P, Kyriazis I, et al. Ureteral obstruction: Is the full metallic double pigtail stent the way to go? *Eur Urol*. 2010;57:480–486.
9. Modi AP, Ritch CR, Arend D, et al. Multicenter experience with metallic ureteral stents for malignant and chronic benign ureteral obstruction. *J Endourol*. 2010;24:1189–1193.
10. Christman MS, L'Esperance JO, Choe CH, et al. Analysis of ureteral stent compression force and its role in malignant obstruction. *J Urol*. 2009;181:392–396.
11. Blaschko SD, Deane LA, Krebs A, et al. In-vivo evaluation of flow characteristics of a novel metal ureteral stent. *J Endourol*. 2007;21:780–783.
12. Pedro RN, Hendlin K, Kriedberg C, Monga M. Wire-based ureteral stents: Impact on tensile strength and compression. *Urology*. 2007;70:1057–1059.
13. Chung SY, Stein RJ, Landsittel D, et al. 15 year experience with the management of extrinsic ureteral obstruction with indwelling ureteral stents. *J Urol*. 2004;172:592–595.
14. Ganatra AM, Loughlin KR. The management of malignant ureteral obstruction treated with ureteral stents. *J Urol*. 2005;174:2125–2128.
15. Polcari AJ, Hugen CM, Lopez-Huertas HL, Turk MT. Cost analysis and clinical applicability of the Resonance metallic ureteral stent. *Expert Rev Pharmacoecon Outcomes Res*. 2010;10:11–15.
16. Brown JA, Powell CL, Carlson KR. Metallic full-length ureteral stents: Does urinary tract infection cause obstruction? *Scientific World Journal*. 2010;10:1566–1573.
17. Corcoran AT, Smaldone MC, Ricchiuti DD, Averch TD. Management of benign ureteral strictures in the endoscopic era. *J Endourol*. 2009;23:1909–1912.
18. Garg T, Guralnick ML, Langenstroer P, et al. Resonance metallic ureteral stents do not successfully treat ureteroenteric strictures. *J Endourol*. 2009;23:1199–1202.
19. Joshi HB, Chitale SV, Nagarajan M, et al. A prospective randomized single-blind comparison of ureteral stents composed of firm and sift polymer. *J Urol*. 2005;174:2303–2306.
20. Polcari A, Hugen C, Farooq A, et al. The metallic ureteral stent: 12-month outcomes. *J Urol*. 2010;183:496.
21. Nagele U, Kuczyk MA, Horstmann M, et al. Initial clinical experience with full-length metal ureteral stents for obstructive ureteral stenosis. *World J Urol*. 2008;26:257–262.
22. Cauda V, Fiori C, Cauda F. Ni-Cr-Co alloy ureteral stent: Scanning electron microscopy and elemental analysis characterization after long-term indwelling. *J Biomed Mater Res*. 2010;94:501–507.
23. Lopez-Huertas H, Polcari AJ, Acosta-Miranda A, Turk T. Metallic ureteral stents: A cost-effective method of managing benign ureteral obstruction. *J Endourol*. 2010;24:483–485.

Medical Devices: Evidence and Research

Publish your work in this journal

Medical Devices: Evidence and Research is an international, peer-reviewed, open access journal that focuses on the evidence, technology, research, and expert opinion supporting the use and application of medical devices in the diagnosis, treatment and management of clinical conditions and physiological processes. The identification of novel

Submit your manuscript here: <http://www.dovepress.com/medical-devices-evidence-and-research-journal>

Dovepress

devices and optimal use of existing devices which will lead to improved clinical outcomes and more effective patient management and safety is a key feature. The manuscript management system is completely online and includes a quick and fair peer-review system. Visit <http://www.dovepress.com/testimonials.php> to read real quotes from authors.