

Intracranial Chondroma of the Falx Cerebri: A Rare Case Report with Review of Literature

Abstract

Intracranial chondromas are extremely rare, benign slow-growing cartilaginous tumors mostly originating from embryonic rests at sphenothmoidal region and sometimes can originate from the falx, convexity dura, the tentorium, the choroid plexus, or the brain parenchyma. In this article, we present a 22-year-old woman with a chondroma of dural origin. The clinical, radiological, and histopathological findings along with the operative findings and postoperative course are described as well as the pertinent literature regarding intracranial chondromas is reviewed.

Keywords: *Cartilaginous, falx, intracranial chondroma*

Introduction

Intracranial chondroma is a rare entity of primary cerebral tumors. The incidence of these tumors is estimated as 0.2%–0.3%. It was first reported by Hirschfeld in 1851.^[1] These tumors are benign slow growing and usually arise from the embryonic cartilaginous remnants with a predilection of the sphenothmoidal region. These tumors can originate from the falx, convexity dura, the tentorium, the choroid plexus, or the brain parenchyma. Here, we present a case of chondroma of the falx cerebri with a review of the literature.

Case Report

A 22-year-old female patient presented to us with a history of episodic headache, vomiting, and absence seizures for 3 years operated elsewhere 1 year back and started having generalized tonic-clonic seizures following surgery which was poorly controlled on antiepileptic medications. She presented to us in an emergency following an episode of seizure in a drowsy state with left hemiparesis Grade 2 and bilateral papilledema. Her noncontrast computed tomography of the head was suggestive of large extra-axial mass lesion arising from the falx with cystic areas and foci of calcification and absence of the dural tail sign. Magnetic resonance imaging (MRI) of the brain with contrast [Figure 1] revealed

This is an open access journal, and articles are distributed under the terms of the Creative Commons Attribution-NonCommercial-ShareAlike 4.0 License, which allows others to remix, tweak, and build upon the work non-commercially, as long as appropriate credit is given and the new creations are licensed under the identical terms.

For reprints contact: reprints@medknow.com

a large extra-axial mass in the bilateral anterior frontal regions (left > right) arising from both sides of the falx cerebri with both solid and cystic components without surrounding edema. The solid component was hypointense on T1-weighted (T1W) as well as on T2W with heterogeneous postcontrast enhancement. She underwent complete excision of the tumor which had cystic and solid components. The solid component was pearly white in color, hard candle wax like in consistency, avascular, and adhered to the surrounding arachnoid. Histopathology [Figure 2] showed mature hyaline cartilage with increased cellularity, no atypia, mitoses, or necrosis which was compatible with intracranial chondroma. The patient recovered and remained seizure free in the postoperative period. At follow-up after 21 months, her MRI showed no evidence of recurrence, and she remained seizure-free.

Discussion

There are very few cases of intracranial chondroma of the falx cerebri have been reported yet. We are going to discuss many of them along with our case in Table 1.

Review and Conclusion

Intracranial chondromas are slow-growing benign cartilaginous tumors. The incidence has been reported from 0.1% to 1% of intracranial tumors. These tumors occur at the base of the skull mostly, but convexity or falcine chondromas constituted 20%

How to cite this article: Agrawal R, Saroha A. Intracranial chondroma of the falx cerebri: A rare case report with review of literature. *Asian J Neurosurg* 2019;14:911-4.

**Rati Agrawal,
Arun Saroha**

*Department of Neurosurgery,
Max Super Specialty Hospital,
Saket, New Delhi, India*

Address for correspondence:

*Dr. Rati Agrawal,
100/10, Third Floor, Gautam
Nagar, New Delhi - 110 049,
India.*

E-mail: drrati_agr@yahoo.com

Access this article online

Website: www.asianjns.org

DOI: 10.4103/ajns.AJNS_82_19

Quick Response Code:



Table 1: Details of few reported cases along with our case

Author	Age (years)	Sex	Clinical presentation	Case details			Postop radiology findings	Histopathological findings	Immunohistochemistry	Outcome	
				CT scan	Radiological findings	Operative findings					
Luzardo-Small <i>et al.</i> , 1999 ^[9]	14	Male	Headache + weakness + seizures	Left parasagittal frontoparietal mass lesion with contrast enhancement and hydense center	Hypointense (T1W), hyperintense with central hypointensity (T2W), diffuse serpiginous enhancement (T1C)	Large irregular gray, translucent centrally cavitated mass firmly attached to the junction of the middle and posterior third of the falx	Complete excision	Neoplasm displayed mature hyaline cartilage arranged in lobule with a central area of degeneration	Vimentin + S-100 - GFPA, cytokeratin, NSE -	Disease free with no e/o recurrence at 12 months	
Cosar <i>et al.</i> , 2005 ^[10]	44	Male	Headache B/L papilledema		Mass in frontal falicine area hypointense (T1W), iso-hyperintense (T2W)		Complete excision	Mature hyaline cartilage cells with rests of benign appearing cells in lacunae		Disease free with no e/o recurrence at 12 months	
Erdogan <i>et al.</i> , 2006 ^[11]	50	Female	Headache + forgetfulness	Inhomogeneously calcified hyperdense mass with a minimally hypodense center	Iso-hyperintense (T1W), iso-hyperintense (T2W), little enhancement (T1C)	Large grayish-white tumor firmly attached to the falx	Complete excision	Composed of well-differentiated cartilaginous tissue with no mitoses		Disease-free with no e/o recurrence at 18 months	
Fountas <i>et al.</i> , 2008 ^[2]	30	Male	Single episode focal motor seizure	Hyperdense left parasagittal mass	Hypointense (T1W), hyperintense (T2W), slightly and nonhomogeneously enhancing (T1C)	Well-demarcated, pearly white firm mass originated from the falx	Complete excision	Mature hyaline cartilage without calcification, no nuclear polymorphism/atypia or mitotic activity	Vimentin + S-100 - EMA -	Disease-free with no e/o recurrence at 18 months	
Park and Jeun 2013 ^[11]	55	Female	Headache + memory impairment global aphasia area and right side weakness	Intracranial hemorrhage in the left frontal area	Nonenhancing mass-like lesion with heterogeneous signal intensity in the left frontal lobe	Friable and yellowish tumor adherent to the falx	Complete excision				
Our case	22	Female	Episodic headache, vomiting and absence seizures drowsy, left hemiparesis,	Large extra-axial mass lesion arising from the falx with cystic areas and foci of calcification and absence of the dural tail sign	Large extra-axial mass in bilateral anterior frontal regions (left > right) arising from both sides of the falx cerebri with both solid and cystic components without surrounding edema.	Tumor had cystic and solid components. Solid component was pearly white in color, hard candle wax like in consistency,	Complete excision	Mature hyaline cartilage with increased cellularity, no atypia, mitoses or necrosis		Seizure free with no e/o recurrence at 21 months	

Contd...

Author	Age (years)	Sex	Clinical presentation	Case details			Histopathological findings	Immunohistochemistry	Outcome
				Radiological findings	Operative	Postop radiology			
			B/L papilledema	CT scan	MRI scan	Intraoperative findings	Complication	+	-
					The solid component was hypointense on T1W as well as on T2W with heterogeneous postcontrast enhancement	avasascular, adhered to the surrounding arachnoid			

MRI – Magnetic resonance imaging; CT – Computed tomography; EMA – Epithelial membrane antigen; NSE – Neuron specific enolase; GFAP – Glial Fibrillary acidic protein; B/L – Bilateral; + – positive; - – Negative

of all.^[2] Intracranial chondromas may present as solitary lesions or as part of Ollier disease (multiple polysystemic enchondromatosis) or Maffucci syndrome (multiple enchondromatosis associated with soft-tissue angiomas).^[3] These tumors usually occur in young adults with the peak incidence in the third decade; although, the age reported in the literature varies from 15 months to 60 years. There are many reports which showed slightly female preponderance, whereas other reports showed an equal rate of incidence in males and females.^[2] Pathophysiological origin of chondromas arising from the convexity or the falx is controversial. The suggested hypotheses may be categorized into the following two basic groups: (1) the presence of ectopic chondrocytes, as a result of displacement into the meninges during early ontogenesis or in rare cases after traumatic brain injury and (2) chondroid metaplasia of meningeal connective tissue, such as meningeal fibroblasts or metaplasia of perivascular mesenchymal cells, possibly in connection with inflammation or trauma.^[3,4] Clinical presentation depends on the anatomical location, but a new-onset seizure was the presenting symptom in a large number of reported cases of convexity or falcine chondromas.^[2,5] Imaging characteristics are not pathognomonic, but Lacerte *et al.* proposed the classification of these tumors into two distinct types – Type I tumors classic and significantly more common pattern, the whole tumor appears isodense and homogeneous on a computed tomography scan and Type II tumors are characterized by the presence of hypodense central area constitutes a degenerative cyst frequently filled with a tan-colored fluid or a brownish jelly. These have lack of homogeneous enhancement and the absence of dural tail sign.^[6] On MRI, these tumors appear as homogeneous isointense on T1W with a delayed or slight ring-like enhancement on postcontrast or mixed hyper/hypointensity masses on T2W images. Imaging features of chondromas and meningiomas are similar in many ways such as location, the presence of calcification, and hyperostosis. However, contrast enhancement in meningioma is intensely homogeneous, and chondromas do not show homogeneous enhancement and dural tail sign.^[2] They usually lack surrounding tissue edema, and bright signal intensity is due to bone marrow elements. Angiography can sometimes help to differentiate these tumors as an intracranial chondroma should be avascular.^[2,7] Their diagnosis is usually determined by histological evaluation. Weng *et al.* in their case series of 66 patients retrospectively studied and concluded that the therapeutic strategy should be individualized in intracranial chondromas. If the tumor is resectable, gross total excision should be attempted, and in patients with partial resection and evident atypia/mitotic activity, radiotherapy should be recommended.^[8] Complete surgical excision results in excellent long-term outcome.

Declaration of patient consent

The authors certify that they have obtained all appropriate patient consent forms. In the form the

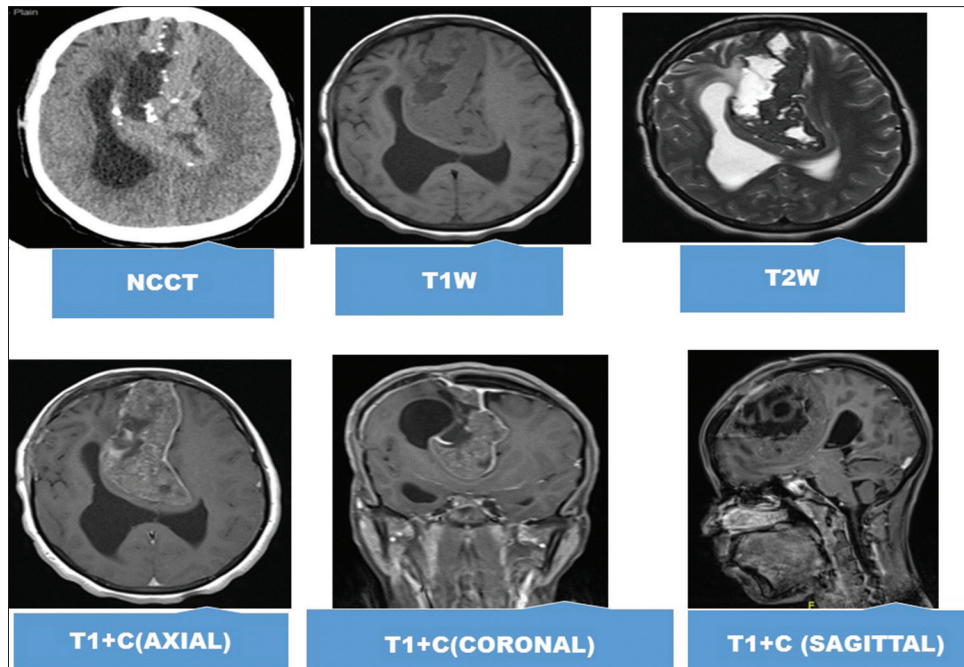


Figure 1: Radiological findings

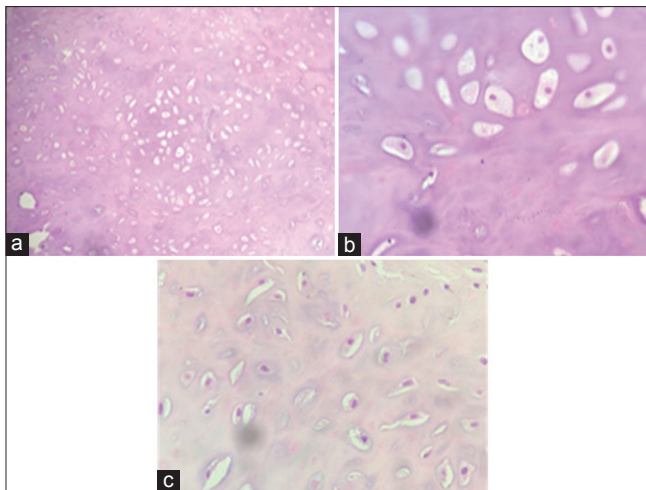


Figure 2: (a-c) Photomicrographs of the tumor showing mature hyaline cartilage with increased cellularity without atypia, necrosis, or mitotic figure (H and E, $\times 100$ [a] and $\times 400$ [b and c])

patient(s) has/have given his/her/their consent for his/her/their images and other clinical information to be reported in the journal. The patients understand that their names and initials will not be published and due efforts will be made to conceal their identity, but anonymity cannot be guaranteed.

Financial support and sponsorship

Nil.

Conflicts of interest

There are no conflicts of interest.

References

1. Erdogan S, Zorludemir S, Erman T, Akgul E, Ergin M, Ildan F, *et al.* Chondromas of the falx cerebri and dural convexity: Report of two cases and review of the literature. *J Neurooncol* 2006;80:21-5.
2. Fountas KN, Stamatou S, Barbanis S, Kourtopoulos H. Intracranial falx chondroma: Literature review and a case report. *Clin Neurol Neurosurg* 2008;110:8-13.
3. Atalay FO, Ozgun G, Tolunay S, Bekar A. Intracranial extra-axial chondroma: A case report. *J Nippon Med Sch* 2014;81:35-9.
4. Reinshagen C, Redjal N, Sajed DP, Nahed BV, Walcott BP. Intracranial dural based chondroma. *J Clin Neurosci* 2016;25:161-3.
5. Uddin MM, Ashraf J, Memon AA, Ali J. Intracranial cystic chondroma: A case report. *J Med Case Rep* 2012;6:432.
6. Lacerte D, Gagné F, Copty M. Intracranial chondroma. Report of two cases and review of the literature. *Can J Neurol Sci* 1996;23:132-7.
7. Somerset HL, Kleinschmidt-DeMasters BK, Rubinstein D, Breeze RE. Osteochondroma of the convexity: Pathologic-neuroimaging correlates of a lesion that mimics high-grade meningioma. *J Neurooncol* 2010;98:421-6.
8. Weng JC, Li D, Li H, Ma JP, Tian KB, Wang L, *et al.* Surgical management and outcomes of intracranial chondromas: A single-center case series of 66 patients. *World Neurosurg* 2017;108:264-77.
9. Luzardo-Small G, Mendez-Martinez O, Cardozo-Duran J. Cavitated (cystic) falxine chondroma: Case report. *Br J Neurosurg* 1999;13:426-8.
10. Cosar M, Iplikcioglu AC, Bek S, Gokduman CA. Intracranial falxine and convexity chondromas: Two case reports. *Br J Neurosurg* 2005;19:241-3.
11. Park JH, Jeun SS. An intracranial chondroma with intratumoral hemorrhage: A case report and review of the literature. *Brain Tumor Res Treat* 2013;1:42-4.