

Case Report

# Treatment of Chemotherapy-Induced Thrombotic Microangiopathy with Eculizumab in a Patient with Metastatic Breast Cancer

Martin Hausberg<sup>a</sup> Helmut Felten<sup>a</sup> Stefan Pfeffer<sup>b</sup>

<sup>a</sup>Department of General Internal Medicine, Nephrology, Rheumatology and Pneumology, Karlsruhe General Hospital, Karlsruhe, Germany; <sup>b</sup>Dialysis Center Ludwigsburg, Ludwigsburg, Germany

## Keywords

aHUS · Atypical Haemolytic Syndrome · Bevacizumab · Breast cancer · Complement · Eculizumab · Metastases · Mitomycin · Thrombotic microangiopathy

## Abstract

The unexpected occurrence of thrombotic microangiopathy (TMA), characterised by microangiopathic haemolytic anaemia and thrombocytopenia, in a patient with cancer requires urgent diagnosis and appropriate management. TMA in patients with metastatic cancer can be a manifestation of the malignancy itself or a therapeutic complication. Distinguishing the cause of TMA is complicated but clinically important to initiate appropriate treatment of metastatic cancer and avoid potential drug toxicity. Eculizumab, which inhibits alternative complement pathway activation, has been shown to be effective in chemotherapy-induced TMA. We report the case of a 69-year-old woman with breast cancer who experienced a mitomycin-C-induced TMA manifestation. TMA did not respond to conservative therapy, plasmapheresis or rituximab and rapidly lead to dialysis dependency. Despite disease progression and metastases, eculizumab treatment was associated with recovered renal function and enabled the patient to avoid dialysis, improving her quality of life.

© 2019 The Author(s)  
Published by S. Karger AG, Basel

## Introduction

Thrombotic microangiopathies (TMAs) represent a heterogeneous group of rare diseases characterised by the clinical manifestation of thrombocytopenia, microangiopathic haemolytic anaemia, and variable end-organ damage resulting from systemic microvascular thrombi [1, 2]. The occurrence of TMA in patients with cancer may be rare but has serious consequences [3]. There are two principle causes of TMA in cancer patients. Firstly, the cancer itself may cause TMA through systemic microvascular metastases or bone marrow metastases. Secondly, many common oncotherapy drugs can induce TMA through direct endothelial damage or through an immune-mediated reaction involving the development of drug-dependent autoantibodies [1, 4].

Oncotherapy-induced TMA can be classified into two types. Type I oncotherapy-induced TMA involves chemotherapeutic agents (e.g. mitomycin-C, cisplatin and gemcitabine [3, 5–7]) and is a serious complication with significant morbidity and mortality that requires early diagnosis and treatment [8]. Typically, the incidence of mitomycin-C-induced TMA is dose-dependent with patients who receive treatment for more than 1 year [4] and a cumulative dose that exceeds 40 mg/m<sup>2</sup> [3] being at greater risk. The prognosis for patients with mitomycin-C-induced TMA is poor: mortality related to renal failure is reported at 75% [4]. Type II oncotherapy-induced TMA involves anti-VEGF agents (e.g. bevacizumab) that are not usually associated with cumulative dose-dependent cell damage [9]. The diagnosis of cancer-induced TMA or oncotherapy-induced TMA is important to allow initiation of the appropriate treatment for metastatic cancer or to avoid continued exposure to a potentially toxic drug [1]. There are limited data on the effective use of plasma therapy to manage chemotherapy-induced TMA. Currently there is no standard of care for the management of mitomycin-C-induced TMA.

Eculizumab, which inhibits alternative complement pathway activation by blocking C5, has recently been shown to be effective in treating chemotherapy-induced TMA [8, 10]. Here, we show that eculizumab may prove effective in treating mitomycin-C-induced aHUS and provide a significant quality of life benefit.

## Case Report

A 69-year-old female patient was treated with paclitaxel and bevacizumab for relapsing metastatic breast cancer. After approximately 2 years of treatment (49 treatment cycles), the patient presented with severe neuropathy resulting in an inability to walk. The treatment regime was changed to mitomycin-C, bevacizumab and capecitabin. After less than 4 weeks, and a cumulative dose of 30 mg/m<sup>2</sup> mitomycin-C, treatment was discontinued because drug toxicity was suspected due to falling platelet count (from 82 × 10<sup>3</sup>/μL to 40 × 10<sup>3</sup>/μL). The patient continued to receive bevacizumab and capecitabin.

The patient experienced a TMA of initially unclear aetiology: haemolytic anaemia with negative direct and indirect Coomb's test, haptoglobin below dictation level, elevated lactate dehydrogenase (LDH), thrombocytopenia with presence of schistocytes, and renal failure. Renal replacement therapy (daily plasmapheresis and haemodialysis for 10 days), rituximab (one 375 mg/m<sup>2</sup> intravenous injection, weekly for 4 weeks) and steroid treatment were initiated. After 2 months, there was no clinical sign of improvement (Fig. 1). ADAMTS13 (a disintegrin and metalloproteinase with a thrombospondin type 1 motif, member 13) activity assay results were normal, therefore, thrombotic thrombocytopenic purpura (TTP) was excluded.

Moreover, there was no history of diarrhoea and Shiga toxin was not detected in the stool specimen. Therefore, mitomycin-C-induced aHUS was diagnosed and eculizumab treatment was initiated (4 weekly doses of 900 mg, followed by 1,200 mg dose on week 5 and every other week thereafter).

Eculizumab treatment resulted in a complete remission of TMA symptoms, reduced LDH (from 975 U/L to 260 U/L) and serum creatinine (from 2.6 mg/dL on dialysis to 1.8 mg/dL), and an increase in platelet count (from  $64 \times 10^3/\mu\text{L}$  to  $82 \times 10^3/\mu\text{L}$ ). With improved renal function the dialysis catheter was removed. However, 6 months after treatment initiation, the patient presented with severe knee pain and requested to stop eculizumab treatment. Eculizumab treatment was discontinued with weekly monitoring. Two months after eculizumab discontinuation, laboratory parameters suggested a new manifestation of TMA (decreased platelet count,  $76 \times 10^3/\mu\text{L}$ ; increased LDH, 362 U/L). Eculizumab treatment was subsequently restarted and kidney function stabilised (serum creatinine, 1.4 mg/dL). However, the patient showed signs of anaemia, high LDH (500 U/L), and platelet levels remained low ( $50\text{--}70 \times 10^3/\mu\text{L}$ ).

The continued increase of LDH and gamma-glutamyl transpeptidase were indicative of known liver metastasis progression. This was confirmed by MRI scan at which time brain metastases were also detected. Bone marrow histology showed an advanced metastasis with minimal residual haematopoiesis, possibly resulting in thrombocytopenia. Further chemotherapy was not feasible due to the extent of treatment already undergone and the risks associated with haematopoietic insufficiency. The patient continued to receive eculizumab alongside palliative care.

## Discussion

We present a case of a 69-year-old woman with breast cancer who suffered a chemotherapeutic-induced TMA manifestation associated to aHUS.

TMA in a patient with cancer requires urgent diagnosis and appropriate management. Commonly, the removal of the causative drug from the treatment regimen is sufficient to resolve haematological and renal parameters [4]. Our case, however, displayed no clinical signs of improvement 2 months after mitomycin-C cessation. aHUS unmasked by mitomycin-C toxicity was therefore suspected. Whether administration of mitomycin-C was singularly responsible for unmasking aHUS is unknown. Our patient received a cumulative dose of  $30 \text{ mg/m}^2$  mitomycin-C, however chemotherapy-induced TMA has been implicated with slightly higher doses [3]. Additionally, other chemotherapeutic agents such as gemcitabine, cisplatin and carboplatin, as well as anti-VEGF agents (bevacizumab) have also been implicated in TMA [8]. Our patient continued to receive bevacizumab, which could have impacted on the TMA and for which the direct, on-target, dose-independent mechanism of TMA has been described [9, 11].

Weakness, weight loss, pulmonary symptoms, and pain are common symptoms in patients with cancer-induced TMA [1]. Our patient experienced severe arthritic knee joint pain, a symptom previously undocumented in the literature. The reason for this symptom remains unclear, however this report may serve to raise awareness for a potential causal relationship.

No universal classification of aHUS exists; aHUS has been used to describe any form of HUS not caused by Shiga toxin-producing *Escherichia coli* (STEC), any HUS not caused by infection, or only HUS where complement involvement can be demonstrated [12]. In a

recently reported classification however, aHUS excludes HUS caused by STEC and is subcategorised into primary and secondary aHUS [12]. Another report however, suggested aHUS may not be an appropriate term and proposed terms that refer to the pathogenic mechanisms involved; complement-HUS, DGKE mutation-HUS, and cobalamin C defect-HUS [13]. A diagnosis of primary aHUS/complement-HUS can be made when an underlying complement abnormality is strongly suspected and other causes of secondary aHUS have been excluded [12, 13]. Our patient was diagnosed with mitomycin-C-induced aHUS due to the persistence of symptoms which became apparent when eculizumab was discontinued. Additionally, ADAMTS13 activity was normal, which ruled out TTP [14]. Treatment with eculizumab resulted in a complete remission of TMA symptoms and haematological normalisation, indicative of underlying complement dysregulation. Limitations of our observation include the lack of biopsy-confirmed evidence of TMA due to thrombocytopenia, and no conclusive evidence of complement involvement. However, using complement abnormality testing as part of the diagnostic workup is unreliable as >30% of tested patients do not have identifiable defects [15], thus, complement/genetic testing should only be used to confirm a diagnosis and inform treatment. In our patient, the rapid return of symptoms when eculizumab was discontinued strongly suggests an underlying complement abnormality.

The relationship between thrombocytopenia and monitoring therapeutic effectiveness and disease progression is worth consideration. Normalised platelet counts are often viewed as a measure of treatment success, however our patient remained thrombocytopenic despite the re-initiation of eculizumab treatment and gain in renal function. Thrombocytopenia in our case was probably due to bone metastases and not ineffective treatment. Persistent thrombocytopenia despite eculizumab treatment in cancer patients with chemotherapeutic-induced aHUS may serve as an indicator for suspecting metastases and disease progression. A recent report of four patients with gemcitabine-induced-HUS who progressed despite stopping chemotherapy showed that eculizumab proved effective in all four patients, normalising haematological parameters and improving kidney function with no severe adverse events [8]. Beyond improvement of TMA symptoms, we demonstrate the patient benefit of treatment with eculizumab including avoiding the need for dialysis thus improving quality of life. Eculizumab appears to be a well-tolerated and effective treatment for mitomycin-C-induced aHUS.

## Conclusion

Our case provides three clinically valuable lessons. First, resolution of TMA symptoms in cancer patients in the presence of continued thrombocytopenia may indicate disease progression and serious metastatic bone marrow infiltration. Second, eculizumab is well-tolerated and effective in treating mitomycin-C-induced TMA in cancer patients. Finally, beyond the resolution of TMA parameters, eculizumab may also provide quality of life improvement to patients with metastatic cancer, avoiding the need for dialysis.

## Acknowledgements

Medical writing support was provided by Dr Jonathan Plumb and Dr Ciaran Wright of Bioscript, Macclesfield, UK, which was funded by Alexion Pharmaceuticals Inc.

### Statement of Ethics

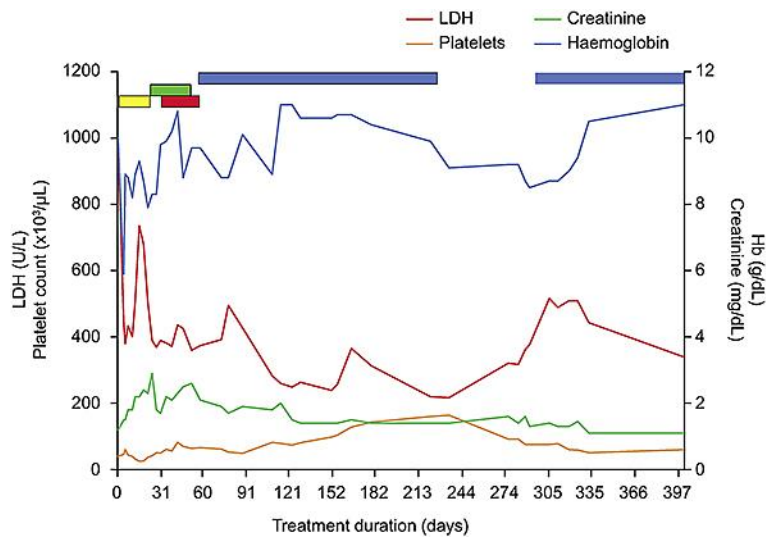
Informed consent was obtained from the patient.

### Disclosure Statement

The authors have no conflicts of interest to declare.

### References

- Morton JM, George JN. Microangiopathic hemolytic anemia and thrombocytopenia in patients with cancer. *J Oncol Pract*. 2016 Jun;12(6):523–30.
- Ducos G, Mariotte E, Galicier L, Canet E, Boutboul D, Lemiale V, et al. Metastatic cancer-related thrombotic microangiopathies: a cohort study. *Future Oncol*. 2014 Aug;10(10):1727–34.
- Garcia G, Atallah JP. Antineoplastic agents and thrombotic microangiopathy. *J Oncol Pharm Pract*. 2017 Mar;23(2):135–42.
- Govind Babu K, Bhat GR. Cancer-associated thrombotic microangiopathy. *Ecancermedscience*. 2016 Jun;10:649.
- Faguer S, Huart A, Frémeaux-Bacchi V, Ribes D, Chauveau D. Eculizumab and drug-induced haemolytic-uraemic syndrome. *Clin Kidney J*. 2013 Oct;6(5):484–5.
- Turner JL, Reardon J, Bekaii-Saab T, Cataland SR, Arango MJ. Gemcitabine-associated thrombotic microangiopathy: response to complement inhibition and reinitiation of gemcitabine. *Clin Colorectal Cancer*. 2016 Sep;16(2):e119–22.
- Valavaara R, Nordman E. Renal complications of mitomycin C therapy with special reference to the total dose. *Cancer*. 1985 Jan;55(1):47–50.
- Al Ustwani O, Lohr J, Dy G, Levea C, Connolly G, Arora P, et al. Eculizumab therapy for gemcitabine induced hemolytic uremic syndrome: case series and concise review. *J Gastrointest Oncol*. 2014 Feb;5(1):E30–3.
- Izzedine H, Perazella MA. Thrombotic microangiopathy, cancer, and cancer drugs. *Am J Kidney Dis*. 2015 Nov;66(5):857–68.
- Starck M, Wendtner CM. Use of eculizumab in refractory gemcitabine-induced thrombotic microangiopathy. *Br J Haematol*. 2013 Dec;164(6):894–6.
- Eremina V, Jefferson JA, Kowalewska J, Hochster H, Haas M, Weisstuch J, et al. VEGF inhibition and renal thrombotic microangiopathy. *N Engl J Med*. 2008 Mar;358(11):1129–36.
- Goodship TH, Cook HT, Fakhouri F, Fervenza FC, Frémeaux-Bacchi V, Kavanagh D, et al.; Conference Participants. Atypical hemolytic uremic syndrome and C3 glomerulopathy: conclusions from a “Kidney Disease: Improving Global Outcomes” (KDIGO) Controversies Conference. *Kidney Int*. 2017 Mar;91(3):539–51.
- Fakhouri F, Zuber J, Frémeaux-Bacchi V, Loirat C. Haemolytic uraemic syndrome. *Lancet*. 2017 Aug;390(10095):681–96.
- Vincent JL, Castro P, Hunt BJ, Jörres A, Praga M, Rojas-Suarez J, et al. Thrombocytopenia in the ICU: disseminated intravascular coagulation and thrombotic microangiopathies-what intensivists need to know. *Crit Care*. 2018 Jun;22(1):158.
- Frémeaux-Bacchi V, Fakhouri F, Garnier A, Bienaimé F, Dragon-Durey MA, Ngo S, et al. Genetics and outcome of atypical hemolytic uremic syndrome: a nationwide French series comparing children and adults. *Clin J Am Soc Nephrol*. 2013 Apr;8(4):554–62.



**Fig. 1.** Response to eculizumab treatment in mitomycin-C-induced TMA. Laboratory parameters over the course of treatment. Treatment periods are indicated by coloured bars: yellow, PE; green, rituximab; red, haemodialysis; blue, eculizumab. Day 0 represents TMA manifestation.