



Evaluation of mandibular buccal shelf characteristics in the Colombian population: A cone-beam computed tomography study

Natalia Escobar-Correa^a
Maria Antonia Ramírez-Bustamante^a
Luis Alejandro Sánchez-Uribe^a
Juan Carlos Upegui-Zea^a
Patricia Vergara-Villarreal^b
Diana Milena Ramírez-Ossa^a

^aDepartment of Orthodontics, Faculty of Dentistry, University of Antioquia, Medellín, Colombia

^bDepartment of Orthodontics, Faculty of Dentistry, University of Cartagena, Cartagena, Colombia

Objective: To evaluate the mandibular buccal shelf (MBS) in terms of the angulation and bone depth and thickness according to sex, age, and sagittal and vertical skeletal patterns in a Colombian population using cone-beam computed tomography (CBCT). Accordingly, the optimal site for miniscrew insertion in this area was determined. **Methods:** This descriptive, retrospective study included 64 hemi-arches of 34 patients. On CBCT images, the angulation, buccal bone depth (4 and 6 mm from the cemento-enamel junction [CEJ] of MBS), and buccal bone thickness (6 and 11 mm from the CEJ of MBS) were measured at the mesial and distal roots of the mandibular first and second molars. **Results:** There were no statistically significant differences in the angulation, depth, and thickness of MBS between male and female patients. The values for the bone around the distal root of the mandibular second molar were significantly greater than the other values. The osseous characteristics were significantly better in participants aged 16–24 years. Class III patients exhibited the best osseous characteristics, with the bone depth at 6 mm being significantly different from that in Class I and Class II patients. Although values tended to be greater in patients with low angles, the difference was not statistically significant. **Conclusions:** MBS provides an optimal bone surface for miniscrew insertion, with better osseous characteristics at the distal root of the mandibular second molar, 4 mm from CEJ. Adolescent patients, Class III patients, and patients with a low angle exhibit the most favorable osseous characteristics in the MBS area.
[Korean J Orthod 2021;51(1):23-31]

Key words: Miniscrew, Cone-beam computed tomography, Bone-implant contact, Anchorage

Received May 13, 2020; Revised August 19, 2020; Accepted August 21, 2020.

Corresponding author: Diana Milena Ramírez-Ossa.
Professor, Orthodontic Program Director, Department of Orthodontics, Faculty of Dentistry, University of Antioquia, Calle 70 # 52-51, Medellín, Colombia.
Tel +57-4-219-6772 e-mail milena.ramirez@udea.edu.co

How to cite this article: Escobar-Correa N, Ramírez-Bustamante MA, Sánchez-Uribe LA, Upegui-Zea JC, Vergara-Villarreal P, Ramírez-Ossa DM. Evaluation of mandibular buccal shelf characteristics in the Colombian population: A cone-beam computed tomography study. Korean J Orthod 2021;51:23-31.

© 2021 The Korean Association of Orthodontists.

This is an Open Access article distributed under the terms of the Creative Commons Attribution Non-Commercial License (<http://creativecommons.org/licenses/by-nc/4.0>) which permits unrestricted non-commercial use, distribution, and reproduction in any medium, provided the original work is properly cited.

INTRODUCTION

The field of modern orthodontics faces the permanent challenge of developing and implementing new techniques, materials, and approaches that improve the efficiency of treatments. Miniscrews were developed to achieve this objective because they prevent anchorage loss in the reaction zone during orthodontic treatment. These miniscrews are inserted in the maxilla and mandible to provide different treatment alternatives in cases with dental crowding or nonsurgical solutions to avoid tooth extractions in cases with certain skeletal discrepancies.^{1,2}

Since the popularization of the first temporary anchorage device in the field of orthodontics,³ the design of such devices has been improved to optimize their use. Although they are temporary and must be removed once their objective has been achieved, their stability is important for successful function. Factors that influence the success or failure of miniscrews could be classified into patient-related factors (age, sex, skeletal pattern, and oral hygiene), miniscrew-related factors (diameter, length, and shape of the device), and treatment-related factors (technique, forces applied to the miniscrews, and their insertion site).⁴

The stability of miniscrews does not depend on osseointegration; rather, it depends on mechanical retention due to the interaction between the miniscrew surface and the surrounding bone. This interaction is known as primary stability,⁵ and satisfactory primary stability requires an anatomical region with specific characteristics in terms of bone density, depth, thickness, and adequacy.⁶

Some researchers have evaluated bone characteristics in different regions of the maxilla, mandible, and alveolar bone in order to identify the best places for miniscrew insertion.^{7,8} The most preferred sites for their placement are the interradicular vestibular alveolar zone, hard palate, and infrazygomatic crest; and in the mandible, these regions include mandibular triangle, retromolar area, and mandibular buccal shelf (MBS).^{1,9-11} In cases requiring retraction of the lower teeth, MBS is the best area for miniscrew insertion in the extra-alveolar bone of the posterior zone of the mandible.^{12,13} MBS is bilaterally located buccal to the roots of the first and second mandibular molars and anterior to the oblique line of the mandibular ramus, and it provides adequate quantity and quality of bone for miniscrew insertion.¹³ However, variations in the depth and thickness of the bone along its course may affect miniscrew placement. Therefore, the purpose of this study was to evaluate MBS in terms of the angulation and bone depth and thickness according to sex, age, sagittal skeletal pattern (SSP), and vertical skeletal pattern (VSP) using cone-beam computed tomography (CBCT) images in a Colombian population.

Accordingly, we explored the optimal site for miniscrew insertion in this area.

MATERIALS AND METHODS

This descriptive, retrospective study included digital lateral cephalograms (DLCs) and CBCT records of 88 patients recruited from different private practices in the cities of Cartagena (n = 10), Medellín (n = 39), and Pereira (n = 39) in the country of Colombia. For all eligible patients, CBCT images were obtained as part of their initial records. These records were collected over a period of 10 months from May 2018 to February 2019 and were preselected according to the following inclusion criteria: 1) male or female patients aged > 16 years; 2) availability of initial records (DLC and unilateral or bilateral mandibular CBCT images) and presence of the second premolar and first and second molars; and 3) provision of informed consent for access to the records of each patient. The exclusion criteria were as follows: 1) incomplete or erroneous CBCT images; 2) extensive coronal restorations on the first and/or second molar; and 3) findings like periapical lesions or periradicular pathologies (endodontic or periodontal in origin), osseous or odontogenic tumors, supernumerary teeth, and horizontal or vertical bone loss in the area of study.

The final sample included a total of 64 hemi-arches (32 on the right side and 32 on the left side) of 34 patients were included (30 with bilateral mandibular records, two with right hemi-arch records, and two with left hemi-arch records) and classified according to sex, age, SSP, and VSP. There was a female predominance (59%), and the mean age for the overall sample, male patients, and female patients was 30.7 ± 10.5 , 28.8 ± 9.4 , and 32.1 ± 11.9 years, respectively.

To define the skeletal diagnosis, DLCs were measured using the overbite depth indicator and the antero-posterior dysplasia indicator, as described by Kim,^{14,15} with Solid Edge 2019 Academic Edition Siemens® PLM software (https://www.plm.automation.siemens.com/plmapp/education/solid-edge/en_us/free-software/student) (Table 1 and Figure 1). With regard to SSP, 44%, 35%, and 21% cases exhibited Class I, II, and III skeletal patterns, respectively. With regard to VSP, 21%, 12%, and 67% cases exhibited high, low, and neutral angles, respectively.

All CBCT records had been obtained using the I-CAT CBCT scanner (Imaging Sciences International, Hatfield, PA, USA) with the following parameters: field of view, 13–17 cm; 120 kVp; 37 mA; acquisition time, 26.9 seconds; and voxel size resolution, 0.25 mm. The records were imported into a 3-dimensional software platform (OsiriX Lite v 10.0.5; Pixmeo, Bernex, Switzerland) for the analysis of digital imaging and communications in

Table 1. Cephalometric analysis according to the method of Kim^{14,15}

Indicator	Definition	Measurement	Interpretation
Anteroposterior dysplasia indicator (APDI)	Determines the sagittal relation between the maxilla and the mandible	The resultant reading obtained from the arithmetic sum of three angles: 1. Frankfort horizontal plane to the facial plane (N-Pog) 2. A-B plane to the facial plane (N-Pog) 3. Palatal plane to the Frankfort horizontal plane	Class I: $81.4^\circ \pm 3.7^\circ$ Class II: $\leq 77.7^\circ$ Class III: $\geq 85.1^\circ$
Overbite depth indicator (ODI)	Determines the vertical relation between the maxilla and the mandible	The resultant reading obtained from the arithmetic sum of the angle of the A-B plane to the mandibular plane (Go-Mn) and the angle of the palatal plane to the Frankfort horizontal plane	Neutral angle: $74.5^\circ \pm 6.07^\circ$ High angle (open bite tendency): $\leq 68.4^\circ$ Low angle (deep bite tendency): $\geq 80.6^\circ$

N, nasion; Pog, pogonion; A, A point; B, B point; Go, gonion; Mn, menton.

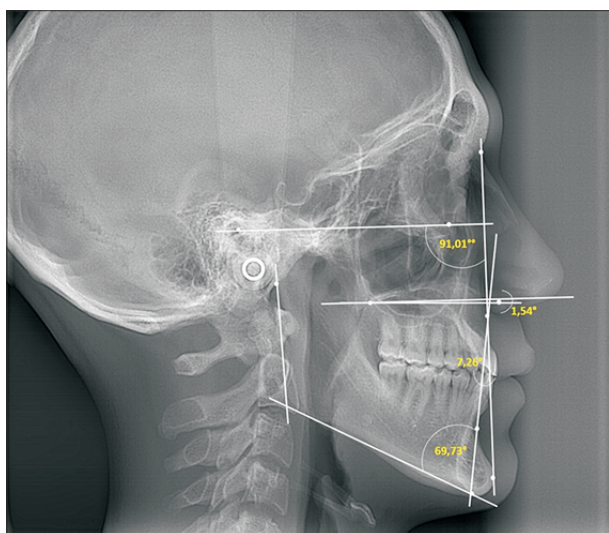


Figure 1. Cephalometric analysis according to the method of Kim.^{14,15}

medicine (DICOM) multiformats. Before the measurements, three reference lines were considered for orientation in the different planes (Figure 2). 1) Axial plane (transverse): This plane runs along the Y axis and allows the image to be moved from top to bottom. It is oriented at the furcation of the first and second mandibular molars; 2) Sagittal plane (anteroposterior): This plane runs along the Z axis and allows the image to be moved from right to left. It is located at the center of the dentoalveolar process from the mesial root of the mandibular first molar to the distal root of the mandibular second mandibular molar; and 3) Frontal/coronal plane (vertical): This plane belongs to the X axis and allows the image to be moved in the anterior and posterior directions. It is located at the axial axis of the four roots being evalu-

ated (mesial and distal roots of the mandibular first and second molars).

For each hemi-arch, four regions were selected for analysis: 1) mesial root of the first molar, 2) distal root of the first molar, 3) mesial root of the second molar, and 4) distal root of the second molar. The measurements made in each region are described below (Figures 3 and 4).

- Angulation of MBS: This was measured as the angle formed by the axial axis of the molar and a tangent to the outermost surface of the buccal shelf (inner angle).

- Apicocoronal depth: The cortical and medullary vestibular bone was measured by drawing two horizontal reference lines from the cemento-enamel junction (CEJ), one at 4 mm and the other at 6 mm parallel to the Y axis. From these, two vertical lines were drawn toward the outermost part of the cortex.

- Thickness: The cortical and medullary buccal bone was measured by drawing two vertical reference lines from CEJ, one at 6 mm and the other at 11 mm parallel to the Z axis. From these, two horizontal lines were drawn toward the outermost part of the cortex.

Bias control

All measurements were performed by three examiners (DMRO, NEC, MARB) and repeated for nine randomly selected patients at an interval of 1 month, after theoretical calibration with a gold standard (LASU – CS). Inter- and intraoperator concordances were evaluated on the basis of intraclass correlation and kappa coefficients, which should be ≥ 0.8 . When the coefficients were < 0.8 , the measurements and analyses were repeated until the established agreement limit was reached.

Statistical analysis

All statistical analyses were performed using IBM SPSS

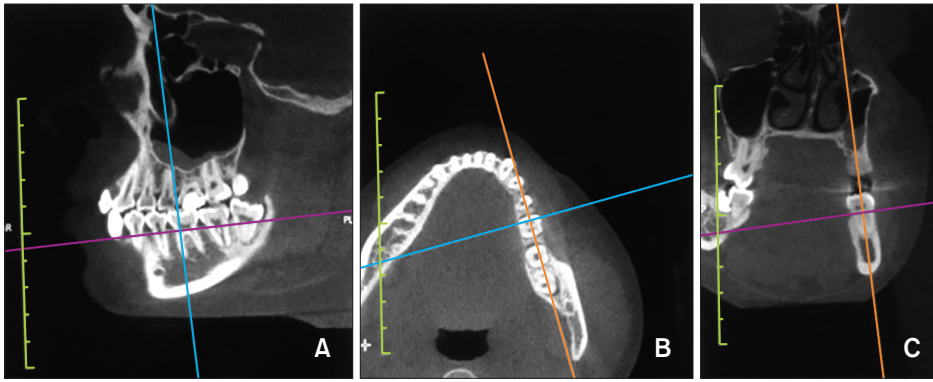


Figure 2. Reference orientation planes. **A**, Axial plane (purple line). **B**, Sagittal plane (blue line). **C**, Frontal/Coronal plane (orange line).

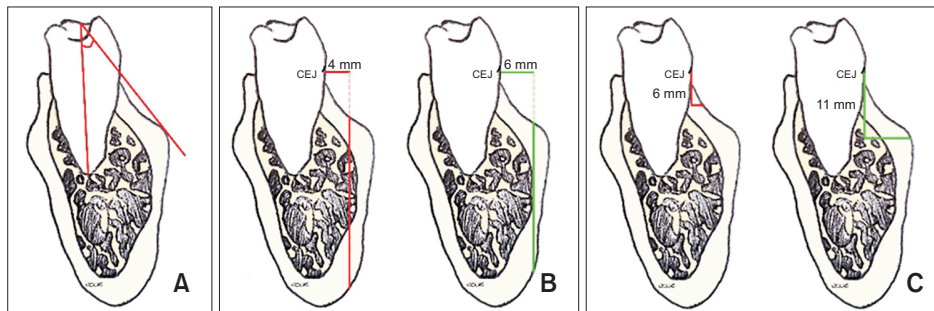


Figure 3. Analysis of the mandibular buccal shelf. **A**, Angulation: This is measured as the inner angle made by the axial axis of the molar and a tangent to the outermost surface of the buccal shelf. **B**, Apicocoronal depth: This is measured using two vertical lines drawn toward the outermost part of the cortex, from two horizontal reference lines from cemento-enamel junction (CEJ), one at 4 mm and the other at 6 mm parallel to the Y axis. **C**, Thickness: This is measured using two horizontal lines drawn toward the outermost part of the cortex, from two vertical reference lines from CEJ, one at 6 mm and the other at 11 mm parallel to the Z axis.

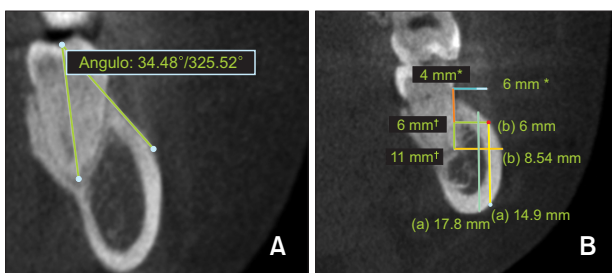


Figure 4. Representative images showing analysis of the mandibular buccal shelf on cone-beam computed tomography images. **A**, Angulation measurement. **B**, Apicocoronal depth and thickness measurements. a: Depth measurements. b: Thickness measurements.

*References lines for depth measurement at 4 and 6 mm from the cemento-enamel junction (CEJ).

†Reference lines for thickness measurement at 6 and 11 mm from CEJ.

Statistics ver. 23.0 (IBM Corp., Armonk, NY, USA). A spreadsheet was generated using Microsoft Excel 2016 (Microsoft, Redmond, WA, USA) to digitize the data

derived from the cephalograms and CBCT images. Descriptive statistics (mean and standard deviation) were used to summarize the MBS measurements (angulation, depth, and thickness). Before the comparative analysis, the distribution of normality was evaluated using the Kolmogorov–Smirnov test.

To evaluate the variability in the osseous characteristics of MBS, Student’s *t*-test for independent samples was performed to compare the values for the angulation, depth, and thickness between the right and left hemi-arches and between male and female patients. One-way analysis of variance (ANOVA) was used to compare the measurements according to the roots (mesial or distal) and molars (first or second), the age ranges, SSP, and VSP. When ANOVA showed statistically significant differences, a post-hoc test was performed; according to the variance homogeneity test, the Tukey or Games–Howell test was applied. A *p*-value of < 0.05 was considered statistically significant.

Ethical considerations

This study was approved by the Committee for the

Development of Research and the Ethics Committee of the Faculty of Dentistry, University of Antioquia (Institutional Review Board number 20-2018). None of the records were acquired for research purposes only.

RESULTS

There was no significant difference in any measurement between the left and right hemi-arches ($p > 0.05$; Table 2). The values progressively increased from the anterior to the posterior area, being significantly lower at the mesial root of the first molar and greater at the distal root of the second molar ($p < 0.05$). The average values were as follows: angulation, $35.1^\circ \pm 7.4^\circ$; bone depth, 18.7 ± 3.8 and 13.9 ± 6.2 mm at 4 and 6 mm from CEJ, respectively; and bone thickness, 5.2 ± 2.1 and 7.6 ± 1.6 mm at 6 and 11 mm from CEJ, respectively (Table 2). For both molars, the bone depth was greater at 4 mm than at 6 mm from CEJ, while the thickness was greater at 11 mm than at 6 mm from CEJ (Table 2).

There were no significant differences in the angulation, depth, and thickness between male and female patients ($p > 0.05$; Table 3). All values were greater for the age range of 16–24 years than for the other age ranges, with a statistically significant difference in the angulation and thickness at 6 mm from CEJ (Table 3).

With regard to SSP, Class III patients showed greater values than did Class I and Class II patients, with a significant difference in the bone depth at 6 mm from CEJ ($p < 0.05$; Table 4). With regard to VSP, the values tend-

ed to be greater for patients with low angles, although the difference was not statistically significant ($p > 0.05$; Table 4).

DISCUSSION

Evidence has identified multiple factors to be related to the success or failure of miniscrews during orthodontic treatment; moreover, it has determined that bone characteristics play a fundamental role in this process in terms of their stability at the insertion site.^{4,16-18}

In the present study, it was observed that the angulation, depth, and thickness of MBS increased progressively from the anterior to the posterior area. This suggests that the best site for miniscrew insertion within MBS, in terms of the bone characteristics, is the bone around the distal root of the second molar, whereas the least indicated site is the bone around the mesial root of the first molar.

With regard to the angulation of MBS, the value was $19.6^\circ \pm 4.0^\circ$ at the distal root of the first molar, $29.6^\circ \pm 4.6^\circ$ at the mesial root of the second molar, and $35.1^\circ \pm 7.4^\circ$ at the distal root of the second molar. Chang et al.¹ documented similar values for an Oriental population (Taiwan), with an increase in the angulation from the first to the second molar as follows: 39.1° (interradicular space between the first and second molars), 40.2° (mesial surface of the second molar), and 55.2° (middle of the second molar). However, in our population, the angulation values were smaller; this suggests that Asian patients exhibit greater projection of MBS.

Table 2. Angulation, depth, and thickness of the mandibular buccal shelf according to the hemi-arch and molar root

Characteristic	Angulation (°)	Depth (mm)		Thickness (mm)		
		4 mm	6 mm	6 mm	11 mm	
Hemi-arch (n = 128)						
Right	24.5 ± 9.0 (22.9–26.0)	12.3 ± 8.3 (10.1–13.8)	7.4 ± 7.5 (6.1–8.8)	2.9 ± 2.1 (2.5–3.2)	5.0 ± 2.8 (4.5–5.4)	
Left	25.4 ± 9.7 (23.7–27.1)	11.1 ± 8.6 (9.6–12.6)	6.3 ± 7.5 (5.0–7.6)	2.7 ± 2.3 (2.3–3.1)	4.6 ± 2.6 (4.1–5.0)	
p-value*	0.418	0.226	0.214	0.490	0.258	
Root (n = 64)						
1M	15.5 ± 4.2 (14.5–16.6)	2.9 ± 6.0 (1.4–4.4)	1.0 ± 3.1 (0.2–1.7)	0.9 ± 0.6 (0.7–1.1)	1.7 ± 0.9 (1.5–1.9)	
1D	19.6 ± 4.0 (18.6–20.6)	9.7 ± 7.9 (7.7–11.7)	3.6 ± 5.7 (2.2–5.0)	1.6 ± 0.8 (1.4–1.8)	3.5 ± 1.3 (3.2–3.8)	
2M	29.6 ± 4.6 (28.5–30.7)	15.5 ± 5.3 (14.2–16.9)	9.0 ± 6.9 (7.3–10.7)	3.3 ± 1.6 (2.9–3.7)	6.2 ± 1.7 (5.8–6.6)	
2D	35.1 ± 7.4 (33.2–36.9)	18.7 ± 3.8 (17.8–19.7)	13.9 ± 6.2 (12.3–15.4)	5.2 ± 2.1 (4.7–5.8)	7.6 ± 1.6 (7.2–8.0)	
p-value†	< 0.001	< 0.001	< 0.001	< 0.001	< 0.001	

Values are presented as mean ± standard deviation (95% confidence interval).

According to Tukey's post-hoc test, all measurements showed differences between the mesial and distal roots.

n, total of measurements; 1M, mesial root of the first molar; 1D, distal root of the first molar; 2M, mesial root of the second molar; 2D, distal root of the second molar.

*p-values per Student's *t*-test.

†p-values per analysis of variance.

Table 3. Angulation, depth, and thickness of the mandibular buccal shelf according to sex and age

Characteristic	Angulation (°)	Depth (mm)		Thickness (mm)	
		4 mm	6 mm	6 mm	11 mm
Sex					
Male patients (n = 96)	24.7 ± 9.0 (22.9–26.5)	11.9 ± 9.2 (10.1–13.8)	7.5 ± 8.2 (5.8–9.2)	2.6 ± 2.0 (2.2–3.0)	4.5 ± 2.6 (4.0–5.0)
Female patients (n = 160)	25.1 ± 9.6 (23.6–26.6)	11.6 ± 7.9 (10.3–12.8)	6.5 ± 7.1 (5.4–7.6)	2.9 ± 2.3 (2.5–3.3)	4.9 ± 2.7 (4.5–5.3)
<i>p</i> -value*	0.760	0.754	0.305	0.235	0.241
Age range					
16–24 (n = 96)	27.3 ± 10.5 [‡] (25.2–29.5)	12.4 ± 8.5 (10.7–14.2)	7.8 ± 7.8 (6.2–9.4)	3.3 ± 2.5 [§] (2.8–3.8)	5.2 ± 2.8 (4.7–5.8)
25–35 (n = 80)	23.6 ± 9.1 (21.6–25.7)	10.1 ± 8.5 (8.2–12.0)	5.3 ± 7.0 (3.7–6.8)	2.8 ± 2.1 (2.3–3.2)	4.6 ± 2.6 (4.0–5.1)
> 35 (n = 80)	23.4 ± 7.4 (21.7–25.0)	12.4 ± 8.2 (10.6–14.2)	7.3 ± 7.4 (5.7–9.0)	2.1 ± 1.6 (1.7–2.5)	4.4 ± 2.6 (3.9–5.0)
<i>p</i> -value [†]	0.007	0.129	0.069	0.001	0.107

Values are presented as mean ± standard deviation (95% confidence interval).

n, total of measurements.

**p*-values per Student's *t*-test.

[†]*p*-values per analysis of variance.

[‡]Difference in the angulation between patients aged 16–24 years and older patients according to Tukey's post-hoc test.

[§]Difference in the thickness at 6 mm from the cemento-enamel junction between patients aged 16–24 years and those aged > 35 years according to Tukey's post-hoc test.

Table 4. Angulation, depth, and thickness of the mandibular buccal shelf according to the sagittal and vertical skeletal patterns

Characteristic	Angulation (°)	Depth (mm)		Thickness (mm)	
		4 mm	6 mm	6 mm	11 mm
Sagittal skeletal pattern					
Class I (n = 108)	24.1 ± 9.3 (22.3–25.9)	11.2 ± 8.6 (9.6–12.9)	6.1 ± 7.1 (4.7–7.4)	2.7 ± 2.0 (2.3–3.1)	4.5 ± 2.6 (4.0–5.0)
Class II (n = 96)	24.4 ± 9.0 (22.6–26.3)	11.0 ± 8.2 (9.3–12.7)	6.1 ± 7.2 (4.7–7.6)	2.6 ± 2.0 (2.2–3.0)	4.6 ± 2.7 (4.1–5.2)
Class III (n = 52)	27.6 ± 9.8 (24.9–30.4)	14.1 ± 8.1 (11.8–16.3)	9.8 ± 8.2 [†] (7.5–12.1)	3.3 ± 2.7 (2.5–4.1)	5.5 ± 2.8 (4.8–6.3)
<i>p</i> -value*	0.065	0.079	0.007	0.131	0.064
Vertical skeletal pattern					
Low angle (n = 32)	28.5 ± 9.8 (24.9–30.4)	12.7 ± 9.6 (11.8–16.3)	8.2 ± 8.7 (7.5–12.1)	3.4 ± 2.5 (2.5–4.1)	5.2 ± 2.7 (4.8–6.3)
High angle (n = 52)	24.5 ± 9.4 (21.8–27.1)	12.3 ± 8.5 (9.9–14.7)	6.1 ± 7.8 (5.8–9.8)	2.7 ± 2.3 (2.1–3.3)	4.7 ± 2.8 (3.9–5.5)
Neutral angle (n = 172)	24.4 ± 9.2 (23.0–25.8)	11.4 ± 8.2 (10.1–12.6)	6.3 ± 7.3 (5.2–7.4)	2.7 ± 2.1 (2.4–3.0)	4.7 ± 2.6 (4.3–5.1)
<i>p</i> -value*	0.071	0.614	0.265	0.248	0.559

Values are presented as mean ± standard deviation (95% confidence interval).

n, total of measurements.

**p*-values per analysis of variance.

[†]Differences in the depth at 6 mm from the cemento-enamel junction between Class III patients and Class I and II patients according to Tukey's post-hoc test.

In terms of bone depth, Nucera et al.¹³ reported a greater depth at 4 mm from CEJ at the distal root of the mandibular second molar, with values of 19.84 ± 3.28 and 19.98 ± 3.22 mm for the right and left sides, respectively. In the present study, the maximum depth was 18.7 ± 3.8 mm, recorded at 4 mm from CEJ at the distal root of the mandibular second molar. This suggests that the closer the miniscrew is to the molar, the greater is the bone depth. However, it may be advisable to maintain a gap of a few millimeters to avoid contact between the root surface and the miniscrew.

With regard to the thickness of MBS, the present findings were in accordance with those of other authors. Nucera et al.¹³ found values of 7.88 ± 1.71 mm on the right side and 7.71 ± 1.69 mm on the left side. Kolge et al.¹⁹ determined a thickness of 6.40 ± 1.35 mm at 8 mm from CEJ at the distobuccal cusp of the mandibular second molar, while Elshebiny et al.¹² documented a value of 8.13 ± 1.97 mm at the same location. The present study also found greater bone thickness at the distal surface of the mandibular second molar, with an average value of 7.6 ± 1.6 mm at 11 mm from CEJ.

With regard to the success factors related to miniscrew stability, diameter and length play an important role, and both are critical for avoiding damage to anatomical structures such as roots, nerves, and blood vessels.⁴ It has been established that miniscrews with a diameter of > 1.4 mm have higher success rates in the mandible, and that the risk of fracture decreases with an increase in the diameter. Moreover, a length of > 8 mm provides higher success rates and greater mechanical retention.⁴ The bone depth and thickness values for MBS in the present study suggest that miniscrews with these dimensions would be appropriate.

Farnsworth et al.⁸ observed that there was no difference in the cortical thickness of the mandibular alveolar bone between men and women. However, they found statistically significant differences between adults and adolescents, with the cortical bone being thicker in the former. In contrast, we found a trend of greater values for the angulation, depth, and thickness of MBS in younger patients (16–24 years), with a statistically significant difference in the angulation and thickness at 6 mm, than in older patients. This difference could be attributed to the fact that the previous study only measured the cortical bone thickness, which is considered to increase in adult populations because of changes in the functional capacity (maximum bite force, masticatory muscle size, and muscle activity). A similar finding has also been observed in the long bones.⁸

Ozdemir et al.⁷ evaluated the cortical thickness of the alveolar bone in the maxilla and mandible according to VSP and found that the cortical bone in both the maxilla and mandible was thicker in patients with low angles. In

the present study, all measured values were greater for patients with low angles, although the differences were not statistically significant. However, it should be noted that the previous studies^{7,8} only considered the cortical thickness of the alveolar bone and did not measure the angular, horizontal, and vertical dimensions of the medullary and cortical bone of MBS.

To our knowledge, no previous study has compared the characteristics of MBS according to SSP. In the present study, Class III patients tended to show greater values for the angulation, depth, and thickness of MBS, with the depth at 6 mm from CEJ being significantly different from that in patients with Class I and Class II malocclusion.

Although the osseous characteristics of MBS were analyzed in our study, the soft tissues of this region must also be considered. As mentioned by Nucera et al.,¹³ the mobility of the alveolar mucosa at the insertion site can affect the long-term stability of the miniscrew. Further studies should analyze the soft tissues in the MBS region according to sex, age, and the skeletal pattern, because these factors, together with those analyzed in this study, may have some influence on the selection of the dimensions and design of miniscrews to be placed in MBS.

When the osseous characteristics of MBS are not adequate, other anatomical regions of the mandible, such as the retromolar triangle,²⁰ also known as Patricia Vergara's Zone, can be used in clinical practice.²¹

The MBS parameters being measured may vary among studies, and this can lead to inaccurate comparisons.

Studies with a larger sample and balance between different groups of skeletal patterns are required to reduce statistical errors.

Only 12% patients in the present sample had low angles, so the results based on VSP must be interpreted with caution. However, according to a study conducted by Plaza et al.²² in 2019, the proportion of patients with a low-angle VSP is low in Colombia, with 57.48%, 25.73%, and 16.79% patients showing neutral, high, and low angles, respectively. Considering this, our sample could be representative of the Colombian population.

CONCLUSION

- There are no significant differences in the osseous characteristics of MBS between the right and left hemi-arches.
- The angulation, bone depth, and thickness progressively increase from the mandibular first to the second molar.
- MBS displays the most favorable bone thickness at 4 mm from CEJ and bone depth at 11 mm from CEJ.
- The buccal bone adjacent to the distal root of the mandibular second molar, at 4 mm from CEJ, provides

the most favorable osseous characteristics for miniscrew insertion in the MBS area.

- The osseous characteristics of MBS are not influenced by sex.
- Younger patients (16–24 years) show greater angulation and bone thickness at 6 mm from CEJ than do older patients.
- Patients with Class III malocclusion and those with low angles show better osseous characteristics in the MBS area.

In summary, MBS could provide an optimal surface for miniscrew insertion in terms of its osseous characteristics.

CONFLICTS OF INTEREST

No potential conflict of interest relevant to this article was reported.

ACKNOWLEDGEMENTS

We would like to express our gratitude to Dr. Hugo Moya and Dr. Juan Pablo Moya for their help with sample acquisition, Dr. Clara Saldarriaga for her advice regarding the CBCT measurements, Dr. Jaime Giraldo for his support during the first phase of the research, PhD Lucelly López and Prof. Luis Gonzalo Álvarez for their assistance with the statistical analyses, and to the Department of Research, Faculty of Dentistry, University of Antioquia for its financial support (Funding 12-2019).

REFERENCES

1. Chang C, Liu SS, Roberts WE. Primary failure rate for 1680 extra-alveolar mandibular buccal shelf mini-screws placed in movable mucosa or attached gingiva. *Angle Orthod* 2015;85:905-10.
2. Suh HY, Lee SJ, Park HS. Use of mini-implants to avoid maxillary surgery for Class III mandibular prognathic patient: a long-term post-retention case. *Korean J Orthod* 2014;44:342-9.
3. Kanomi R. Mini-implant for orthodontic anchorage. *J Clin Orthod* 1997;31:763-7.
4. Ramírez-Ossa DM, Escobar-Correa N, Ramírez-Bustamante MA, Agudelo-Suárez AA. An umbrella review of the effectiveness of temporary anchorage devices and the factors that contribute to their success or failure. *J Evid Based Dent Pract* 2020;20:101402.
5. Rao P, Gill A. Primary stability: the password of implant integration. *J Dent Implant* 2012;2:103-9.
6. Migliorati M, Benedicenti S, Signori A, Drago S, Barberis F, Tournier H, et al. Miniscrew design and bone characteristics: an experimental study of primary stability. *Am J Orthod Dentofacial Orthop* 2012;142:228-34.
7. Ozdemir F, Tozlu M, Germec-Cakan D. Cortical bone thickness of the alveolar process measured with cone-beam computed tomography in patients with different facial types. *Am J Orthod Dentofacial Orthop* 2013;143:190-6.
8. Farnsworth D, Rossouw PE, Ceen RF, Buschang PH. Cortical bone thickness at common miniscrew implant placement sites. *Am J Orthod Dentofacial Orthop* 2011;139:495-503.
9. Yang L, Li F, Cao M, Chen H, Wang X, Chen X, et al. Quantitative evaluation of maxillary interradicular bone with cone-beam computed tomography for bicortical placement of orthodontic mini-implants. *Am J Orthod Dentofacial Orthop* 2015;147:725-37.
10. Becker K, Unland J, Wilmes B, Tarraf NE, Drescher D. Is there an ideal insertion angle and position for orthodontic mini-implants in the anterior palate? A CBCT study in humans. *Am J Orthod Dentofacial Orthop* 2019;156:345-54.
11. Murugesan A, Sivakumar A. Comparison of bone thickness in infrazygomatic crest area at various miniscrew insertion angles in Dravidian population - A cone beam computed tomography study. *Int Orthod* 2020;18:105-14.
12. Elshebiny T, Palomo JM, Baumgaertel S. Anatomic assessment of the mandibular buccal shelf for miniscrew insertion in white patients. *Am J Orthod Dentofacial Orthop* 2018;153:505-11.
13. Nucera R, Lo Giudice A, Bellocchio AM, Spinuzza P, Caprioglio A, Perillo L, et al. Bone and cortical bone thickness of mandibular buccal shelf for mini-screw insertion in adults. *Angle Orthod* 2017;87:745-51.
14. Kim YH. Overbite depth indicator with particular reference to anterior open-bite. *Am J Orthod* 1974;65:586-611.
15. Kim YH, Vietas JJ. Anteroposterior dysplasia indicator: an adjunct to cephalometric differential diagnosis. *Am J Orthod* 1978;73:619-33.
16. Baumgaertel S, Hans MG. Buccal cortical bone thickness for mini-implant placement. *Am J Orthod Dentofacial Orthop* 2009;136:230-5.
17. Wu TY, Kuang SH, Wu CH. Factors associated with the stability of mini-implants for orthodontic anchorage: a study of 414 samples in Taiwan. *J Oral Maxillofac Surg* 2009;67:1595-9.
18. Huang C, Chang CH, Roberts WE. 3D Cortical Bone Anatomy of the Mandibular Buccal Shelf: a CBCT study to define sites for extra-alveolar bone screws to treat Class III malocclusion. *Int J Orthod Implantol* 2016;41:74-82.
19. Kolge NE, Patni VJ, Potnis SS. Tomographic mapping of buccal shelf area for optimum placement of

- bone screws: a three-dimensional cone-beam computed tomography evaluation. *APOS Trends Orthod* 2019;9:241-5.
20. Alves N, de Oliveira Nascimento CM. [Study of the mucosa thickness of the retromolar triangle to facilitate the installation planning of mini-implants in the region]. *Int J Odontostomatol* 2012;6:175-9. Portuguese.
 21. Lin J, White LW, Thavarungkul R. *Creative orthodontics: blending the Damon System & TADs to manage difficult malocclusions*. 3rd ed. Taipei: Yong Chieh Enterprise Co.; 2017. p. 339.
 22. Plaza SP, Reimpell A, Silva J, Montoya D. Relationship between skeletal Class II and Class III malocclusions with vertical skeletal pattern. *Dental Press J Orthod* 2019;24:63-72.