

Case Report

Bilateral fractures of acetabulum in a young girl with osteogenesis imperfecta and epilepsy

Antonio Medici^a, Mariano Giuseppe Di Salvatore^a, Raffaele Pezzella^b,
Andrea Fidanza^{b,*}, Alfonso Maria De Simone^a, Vittorio Calvisi^b

^a AORN S. Giuseppe Moscati, UOC Ortopedia e Traumatologia, Avellino, Italy

^b Department of Life Health & Environmental Sciences, University of L'Aquila, Unit of Orthopaedics and Traumatology, L'Aquila, Italy

ARTICLE INFO

Keywords:

Osteogenesis imperfecta
Protrusio acetabuli
Column fracture
Blue sclera
Epilepsy
Ipoacusia

ABSTRACT

We report a case of bilateral displaced acetabular fractures including both columns (fractures with protrusio acetabuli) in a female patient, aged 15 years, with osteogenesis imperfecta (OI) (Sillence Type I), epilepsy, blue sclera and bilateral ipoacusia. Since OI is a rare genetic disorder characterized by an increased propensity to osteopenia, intraoperative fracture risks and hemorrhagic diathesis, we opted for the open reduction and internal fixation of the acetabula in two surgical steps and using two different approaches. Although the clinical outcomes are not excellent in this report (HHS 45/100), the authors suggest that chances of a good outcome with reconstruction of the acetabulum must be balanced against the benefits of early or late total hip arthroplasty. The goal was to delay a joint replacement as long as possible due to the patient's young age.

Level of evidence: V, case report.

Introduction

Osteogenesis imperfecta (OI) is a rare genetic disorder characterized by abnormal collagen formation associated with increased bone fragility and recurrent fractures throughout life [1]; moreover, patients with OI often have an inherent coagulation defect due to abnormal collagen within endothelial capillaries [2,3].

In a healthy adolescent or adult, a displaced fracture of the acetabulum is usually treated by open reduction and fixation. In OI patients this management may be difficult: in fact, bleeding diathesis and friable tissues should be considered, as well as possible deformities, such as protrusio acetabuli and osteopenia, which reduce the bone stock and increase the risk of intraoperative fracture. Postoperatively, hypertrophic callus or heterotopic ossification (HO) can also be expected in OI patients, which can be used to provide additional stability and a suitable bone stock for future fixation in the event of a new fracture [2].

We have surgically treated bilateral displaced acetabulum fractures in a patient with osteogenesis imperfecta and epilepsy. To our knowledge, it is the first case of a patient with this rare disorder to be described in the literature.

Case report

A 15-year-old woman was diagnosed with osteogenesis imperfecta (Sillence Type I) at a regional reference pediatric hospital. Although a genetic characterization of the disease is currently underway and the patient never underwent a bone density test, she

* Corresponding author at: Piazzale S. Tommasi, 1, 67100 L'Aquila, Italy.

E-mail address: andrea.fidanza@graduate.univaq.it (A. Fidanza).

<https://doi.org/10.1016/j.tcr.2019.100265>

Accepted 6 November 2019

2352-6440/© 2019 The Authors. Published by Elsevier Ltd. This is an open access article under the CC BY-NC-ND license (<http://creativecommons.org/licenses/by-nc-nd/4.0/>).

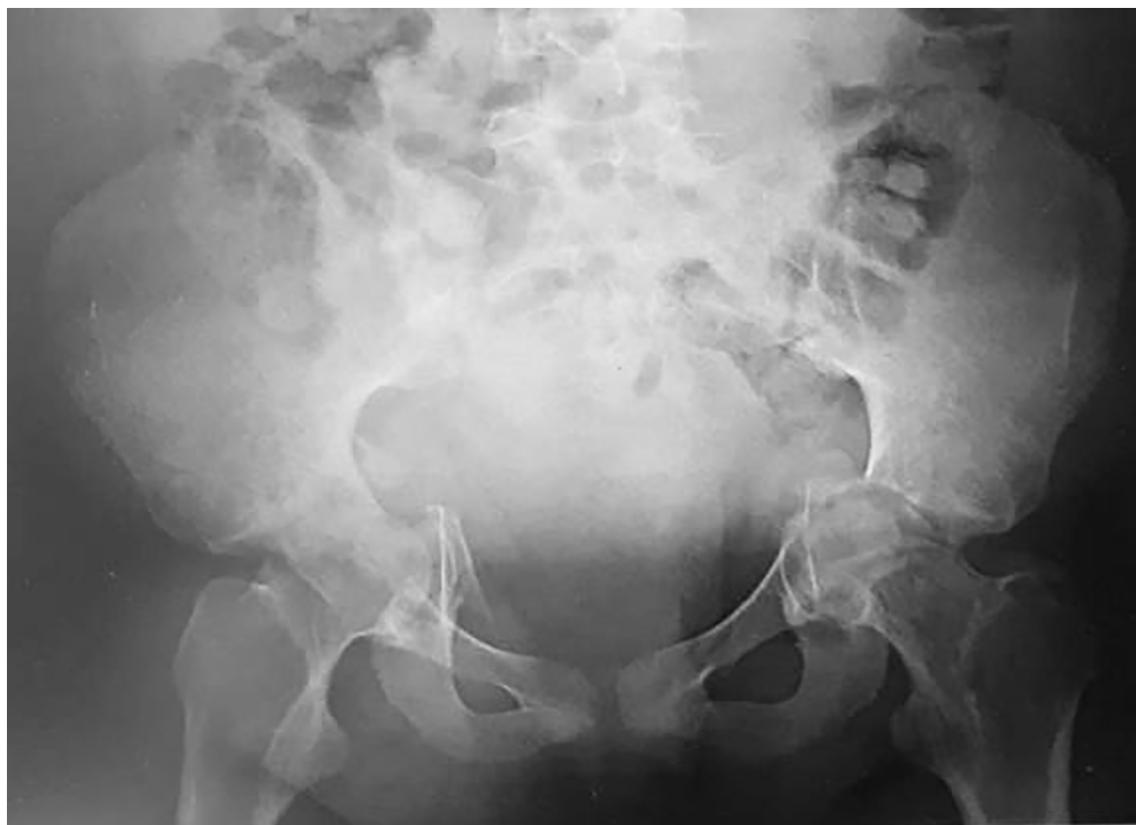

Fig. 1. The first X-ray show bilateral multifragmentary fracture of the acetabulum and protrusion of the femoral heads in the pelvis.

expresses the same phenotypic traits as her mother, who suffers from autosomal dominant OI. Following a fall from a chair during an epileptic seizure, the young patient came to our observation. Medical history did not predict any other fractures. She was not taking bisphosphonates before the injury but she was taking valproic acid for epilepsy.

On physical examination the patient had blue sclera, bilateral ipoacusia, inability to ambulate, and absolute impossibility to active and passive motion of both hips due to pain.

The imaging showed acetabular fractures, which were classified as associated both-column fractures with protrusio acetabuli⁴ (Fig. 1). Three dimensional reconstructed computed tomography (CT) examination revealed a greater degree of comminution and displacement than could be appreciated on the plain radiographs (Fig. 2).

Once informed consent was obtained from the patient and her parents, the preoperative preparation by the orthopaedic and anaesthesia team consisted in typing and cross matching eight units of packed red blood cells, fresh frozen plasma, cryoprecipitate, desmopressin, and intraoperative cell salvage capability available for the operation.

On the fifth post-trauma day, considering the young age of the patient, the comorbidities and the operative duration, we opted for the fixation of the acetabula in two surgical steps.

At first, we performed ORIF of bilateral posterior columns via Iselin approach. A pelvic reconstruction plate was shaped and positioned along the perimeter of the pelvis until its fixation (Fig. 3). The patient was extremely osteopenic, bones were very fragile, and the reduction obtained from the fracture was the best possible given the starting conditions. Since on the right side the posterior synthesis alone appeared insufficient to guarantee a lasting reduction of the femoral head in the acetabulum, we drilled a Kirschner wire to provide stable fixation and to avoid possible future dislocations.

The second surgical step was performed on post-injury day ten via a bilateral modified Stoppa approach and augmented by creating the lateral window of the ilioinguinal approach [5]. Bilaterally, there were multiple devitalised, free-floating, articular fragments medial to the quadrilateral surface that were deemed no-reconstructible. Two dedicated suprapectineal plate® (Stryker corporate, Selzach, Switzerland) were applied to reconstruct anterior column and quadrilateral lamina of both hips.

The post-operative period was uneventful, hemoglobin never fell below 10 mg/dl and intraoperatively the blood loss was less than 400 cl and no blood transfusion was necessary. She was mobilized on crutches with touch weight-bearing for six weeks and partial weight-bearing for another six weeks.

After three weeks, the patient was discharged to home therapy with bisphosphonates and referred to a specialist center for OI disease. We followed the patient weekly for one month, then monthly until the sixth month, with radiographic control at 30, 60 and 120 days (Fig. 4). The hips function was evaluated with Harris Hip Score (HHS) with result of 45/100 at the final follow-up. The

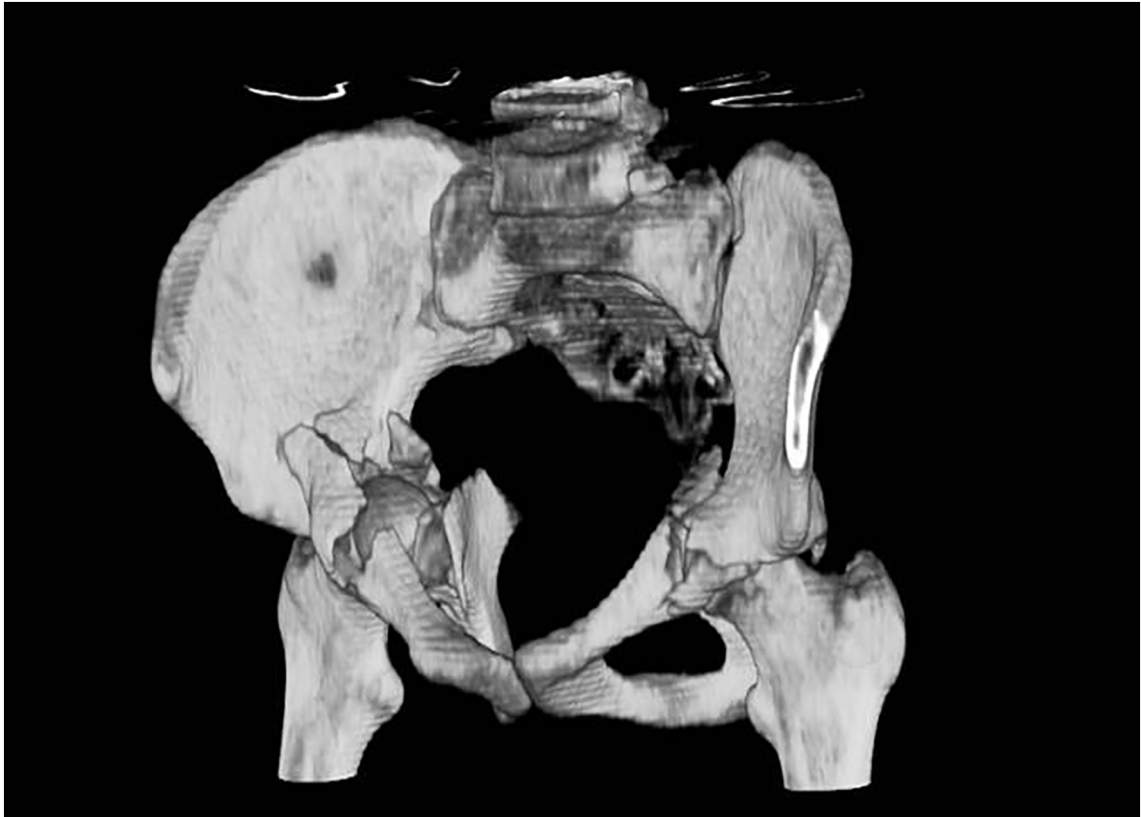

Fig. 2. The three dimensional reconstructed computed tomography gave us further details for planning the operation through intrapelvic and exopelvic vision.

Numeric Pain Rating Scale (NPRS), a segmented numeric version of the visual analog scale (VAS), used to assess pain intensity, reported a score of 5/10 (moderate pain) at the final follow-up. The last radiographic examination showed an adequate reduction of the fracture and a satisfactory wall and bone stock for a subsequent prosthesis: the patient developed a bilateral post-traumatic arthrosis with heterotopic calcifications typical of the underlying disease.

Discussion

Despite the less ominous Type I form of OI, our patient's blue sclera and bilateral hearing aids were a harbinger of the poor bone quality and of increased risk of hemorrhagic blood loss [6,7]. Whilst post-operative HO or hypertrophic callus formation was also anticipated, the primary goal was to achieve a stable reconstruction with minimisation of perioperative blood loss, empirically predictable [1,6].

The mechanism of the injury alone suggested the poor quality of bone stock as our patient suffered an extremely comminuted fracture as a result of low energy kinematics. Low energy acetabular fractures in OI patients have been described in other case reports, but they have not reported the involvement of both columns and both acetabula [8,9].

Darmanis and Bircher described 2 patients with OI each sustaining T-type acetabular fractures, without significant comminution, according to the Judet-Letournel classification system [4,8]. Each fracture had occurred in relatively low energy environments: the two cases involved a 16-year-old man whilst playing football who also sustained a concomitant posterior hip dislocation, and the other a 25-year-old woman who slipped whilst walking [8]. Ziran et al. described a 25-year-old woman with OI who suffered a T-type fracture during a bed-to-chair transfer at home [9]. Liporace and Yoon [10] reported single-stage total hip arthroplasty and fracture fixation on an adult patient with a both column fracture.

In patients with OI, there is a 10%–30% incidence of bleeding diathesis [6]. This coagulation defect is related to decreased capillary strength, as well as to the effect of abnormal collagen on platelet-endothelial cell interactions. In this report, the fracture involved both columns, in accordance with the Judet-Letournel classification [4]. This demanding pattern often requires two surgical approaches, or at the least, the passage of screws through the quadrilateral lamina from one column to the other [8,11]. The surgical technique must be gentle because bony fragments can easily become comminuted. We encountered a protrusio acetabuli and a very thin quadrilateral lamina, and neither the right- nor left-side fractures pattern allowed a screw fixation without penetrating the joint, for this reason we opted for a dedicated plate on the quadrilateral lamina. The main aim of the intervention was to reduce the femoral

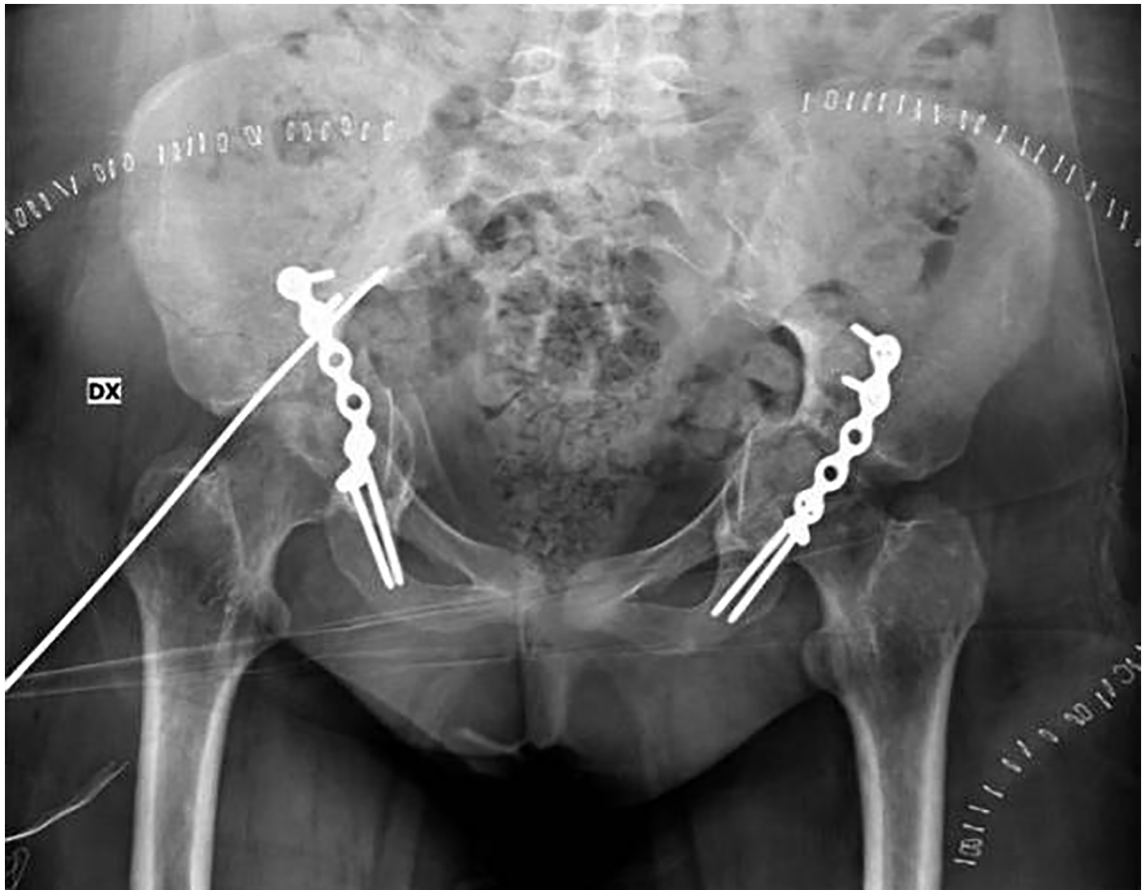


Fig. 3. X-ray control after the first surgical time that consisting in the implant of a posterior pelvic plate and a Kirschner wire in order to maintain the femoral head relocation.

heads inside the acetabulum and stabilize them in order to allow the basic movements for the patient and to restore sufficient a satisfactory medial bone stock to support a hip prosthesis implant in the future. The chances of a good outcome with reconstruction of the acetabulum must be balanced against the benefits of early or late arthroplasty. Although the intraoperative analysis of the acetabular reconstruction yielded a stable construct, and the patient is now autonomous in carrying out normal daily activities, functional result was not very satisfactory and x-rays show an advanced osteoarthritis of both hips.

Despite the high risk of bleeding, poor bone quality, friable tissue, the complexity of these fractures in our opinion exclude the possibility of nonoperative treatment. We do know that an acute total hip arthroplasty yields superior outcomes only if there is a simultaneous synthesis of the fracture [11], however the extremely long surgical times to obtain reduction, synthesis and hip joint replacement in a single step - which in the case described would have been bilateral - would have further exposed the patient to a higher risk of infection, bleeding and a greater rate of cup mobilization [12].

For this reason, we have tried to preserve the native articulation due to the young age of the patient, postponing the joint resurfacing in a moment of clinical stability and therefore as an intervention in election and not in urgency, also applying a correct prophylaxis for heterotopic calcifications.

Conclusion

In summary, acetabular fractures in patients with osteogenesis imperfecta can pose an extremely daunting treatment scenario. The authors suggest that, when choosing treatment options, it is primarily mandatory to try to safeguard the original joint in order to postpone as long as possible a prosthetic replacement, especially in very young patients.

Declaration of competing interest

We declare that authors of this study do not have any financial disclosure and have not received any form of grant for this study.

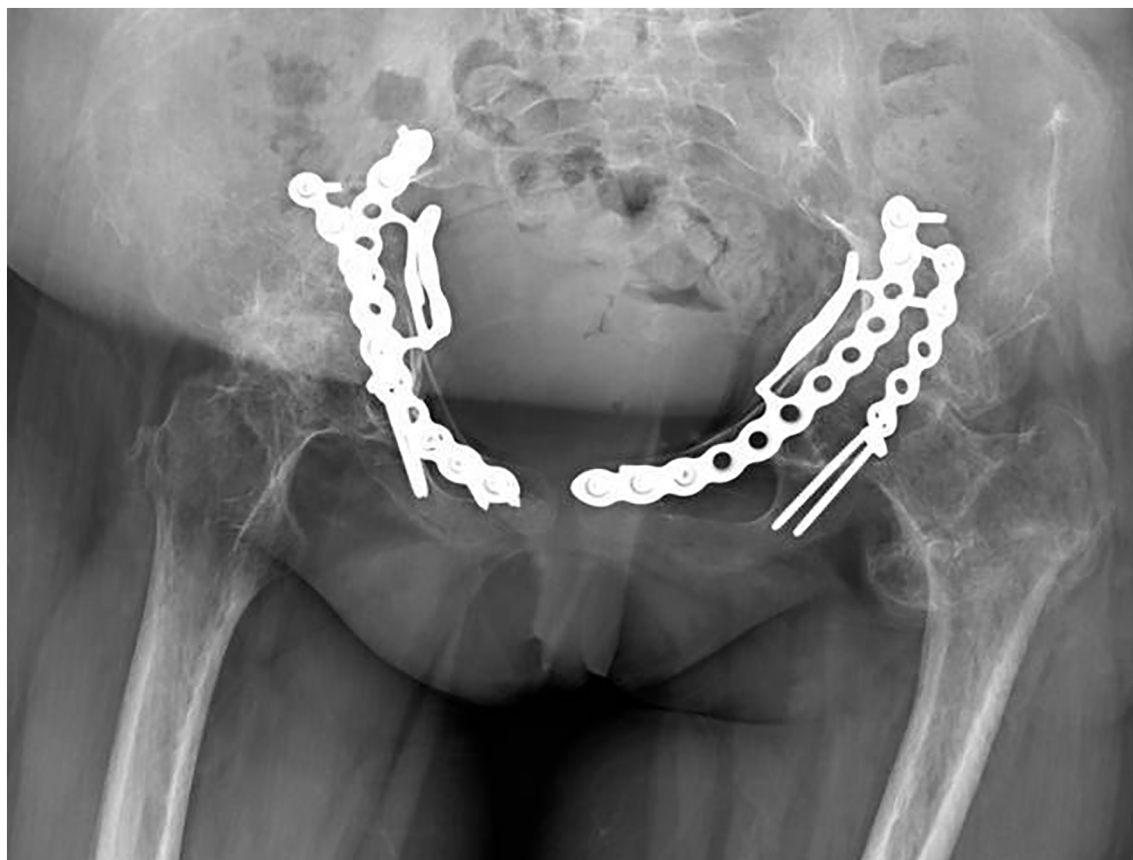


Fig. 4. X-ray control at last follow-up as result of reconstruction of anterior column and quadrilateral lamina that show, despite bone fragility, a good fixation and a satisfactory bone stock to plan a future hip arthroplasty.

References

- [1] D. Basel, R.D. Steiner, Osteogenesis imperfecta: recent findings shed new light on this once well-understood condition, *Genet Med* 11 (2009) 375–385.
- [2] R. Ramaswamy, Y. Kosashvili, H. Cameron, Bilateral total hip replacement in osteogenesis imperfecta with hyperplastic callus, *J Bone Joint Surg Br* 91 (2009) 812–814.
- [3] G.A. Stynowick, J.D. Tobias, Perioperative care of the patient with osteogenesis imperfecta, *Orthopedics* 30 (2007) 1043–1049.
- [4] R. Judet, J. Judet, E. Letournel, Fractures of the acetabulum: classification and surgical approaches for open reduction preliminary report, *J. Bone Joint Surg. Am.* 46 (1964) 1615–1646.
- [5] J.D. Cole, B.R. Bolhofner, Acetabular fracture fixation via a modified Stoppa limited intrapelvic approach description of operative technique and preliminary treatment results, *Clin. Orthop. Relat. Res.* 305 (1994) 112–123.
- [6] M.T. Keegan, B.D. Whatcott, B.A. Harrison, Osteogenesis imperfecta, perioperative bleeding, and desmopressin, *Anesthesiology* 97 (2002) 1011–1013.
- [7] S. Das, K. Bhatnagar, Blue sclera and osteogenesis imperfecta - a rare association, *Kerala J Ophthalmol* 29 (2017) 240–243.
- [8] S. Darmanis, M. Bircher, Fractures of the acetabulum in osteogenesis imperfecta, *J Bone Joint Surg Br* 88 (2006) 670–672.
- [9] N.M. Ziran, J.L. Johnson, S.J. Morgan, W.R. Smith, Femoral artery thrombosis after internal fixation of a transverse acetabular fracture in a patient with osteogenesis imperfecta type I, *Patient Saf Surg* 2 (1) (2008).
- [10] F.A. Liporace, R.S. Yoon, M.A. Frank, J.P. Maurer, R.J. Gaines, Single-stage total hip arthroplasty and fracture fixation for a both column acetabular fracture in type I osteogenesis imperfecta, *Injury* 42 (2011) 1184–1187.
- [11] M. Hanschen, S. Pesch, S. Huber-Wagner, P. Biberthaler, Management of acetabular fractures in the geriatric patient, *SICOT J* 3 (2017) 37.
- [12] P.E. Beaulé, D.B. Griffin, J.M. Matta, The Levine anterior approach for total hip replacement as the treatment for an acute acetabular fracture, *J. Orthop. Trauma* 18 (2004) 623–629.