

OPEN

Practical Aspects of Posttrauma Reconstruction With an Intramedullary Lengthening Nail

Mitchell Bernstein, MD, FRCSC

Summary: Limb equalization using the Ilizarov method has evolved and adapted the use of internal lengthening devices. One of the newest devices, termed “PRECICE,” is a magnetically controlled telescoping nail. Complications such as pin site infection and skin irritation are eliminated. Despite trauma surgeons’ familiarity with intramedullary nailing, the Ilizarov method requires sound knowledge of deformity analysis and awareness of specific complications associated with distraction osteogenesis. This manuscript discusses some of the practical preoperative and intraoperative components of limb lengthening.

Key Words: PRECICE, posttraumatic reconstruction, limb length discrepancy

(*J Orthop Trauma* 2017;31:S20–S24)

Limb equalization using the Ilizarov method has traditionally been accomplished with the use of external fixators. The process, termed “distraction osteogenesis,” is divided into 4 phases. Phase 1: performing a low-energy osteotomy. Phase 2: the latency phase, whereby the bones remain undistracted for a period of time before being pulled apart. The typical latency phase is 7 days. Phase 3: the distraction phase. Ilizarov determined that bone regeneration best occurs with a rate of 1 mm a day, divided into 4 segments of 0.25 mm each.¹ Finally, phase 4: the consolidation phase. It is during this time that the immature regenerate bone forms into mature bone allowing for it to regain its structure and function to allow for full weight bearing. Complications associated with external devices^{2–4} (limb lengthening rails, circular external fixators) have motivated surgeons to evolve with various internal lengthening implants.^{5–8}

PRECICE (Nuvasive Specialized Orthopaedics, Inc, Aliso Viejo, CA) is an implantable magnetic-controlled telescoping internal lengthening nail. Early results are encouraging.^{9–12}

Many orthopaedic trauma surgeons’ practice includes managing complex posttraumatic malunions and nonunions. Limb reconstruction implies that the surgeon will address all components of limb alignment. This includes malalignment in the coronal (varus/valgus angulation and medial/lateral translation), sagittal (procurvatum/recurvatum and anterior/posterior translation), and axial (internal/external rotation and limb length discrepancy) planes. The ability to correct the length discrepancy without the use of an external fixator but rather with an internal lengthening nail has allowed more trauma surgeons to adopt its use. Trauma surgeons are trained to be expert in managing diaphyseal femur and tibia fractures with intramedullary nails. In addition, intramedullary nails have been expanded in use for periarticular and metaphyseal fractures. Adjunct techniques to maintain alignment (blocking screws, femoral-distractors, unicortical plating) have been elucidated. However, regardless if one is using a limb-lengthening rail, circular external fixator, or an implantable magnetic lengthening nail, the science of the Ilizarov method must be understood and adhered to.^{1,13,14} This is analogous to trauma management of complex injuries (eg, calcaneus, Pilon, bicondylar tibial plateau fractures).

This manuscript will discuss some of the practical aspects of limb lengthening surgery using the PRECICE internal lengthening nail. It will discuss preoperative and intraoperative factors that allow for safe and effective execution of the Ilizarov method.

PREOPERATIVE PLANNING—HISTORY AND PHYSICAL EXAMINATION

Managing patients with posttraumatic deformity is complex. Performing a detailed history and physical examination (H & P) is imperative to elucidate all components of the deformity. To be done effectively, posttraumatic reconstruction patients should be viewed as different than most routine trauma clinic patients in the sense that one should be prepared to devote a significant amount of time during the initial clinic visit (45–90 minutes). Practically, one should discuss this with clinic staff, potentially renaming these visits (eg, limb deformity visit). In addition to the routine aspects of history and physical examination, date of injury, mechanism, perioperative complications, and number of surgeries should be sought. Cigarette use, work status, ambulatory status, and what kind of support system should be explored. Allowing patients to describe why they are seeking treatment is effective. Allowing them to discuss their postoperative course often alert you to some of the subtle components (rotation and length) of their deformity. For example, a patient may describe how they reported to their surgical team in the immediate postoperative period

Accepted for publication March 9, 2017.

From the Department of Orthopaedic Surgery and Rehabilitation, Loyola University Medical Center, Maywood, IL.

M. Bernstein serves as a consultant for Nuvasive Specialized Orthopaedics, Smith and Nephew, and Synthes.

Reprints: Mitchell Bernstein, MD, FRCSC, Department of Orthopaedic Surgery and Rehabilitation, Loyola University Medical Center, 2160 S. First Avenue, Maywood, IL 60153 (e-mail: bernstein.mitchell@gmail.com).

Copyright © 2017 The Author(s). Published by Wolters Kluwer Health, Inc. This is an open-access article distributed under the terms of the Creative Commons Attribution-Non Commercial-No Derivatives License 4.0 (CCBY-NC-ND), where it is permissible to download and share the work provided it is properly cited. The work cannot be changed in any way or used commercially without permission from the journal.

DOI: 10.1097/BOT.0000000000000845

that their foot was pointing out and that the therapist thought their limb was short. This also helps determine what radiographs will be required to support the clinical impression.

The clinical examination begins when the patient is appropriately disrobed and placed into shorts so that the limbs may be examined visually. The patient is asked to walk down the hallway of clinic. The surgeon should pay attention to their gait (hip-hiking, Trendelenberg, antalgic), foot progression angle (the position of their foot as they walk) and the direction of their patellae. The other limb (assuming not injured) is examined for reference. Clinical assessment of a limb length discrepancy begins by examining the height of the patient's iliac crests and then trying to level their pelvis with various blocks of known height (Fig. 1). It is also accurate to ask the patient what amount of block height they feel most is comfortable. This is noted and compared with the radiographic analysis. Rotational assessment of the limb is performed by looking at the patient standing with the patellae facing straight forward (Fig. 2A). Femoral rotation is determined by a prone examination of the arc of internal and external rotation. Excessive external rotation in a patient with a femoral malunion would imply that the distal segment is externally rotated. This would also be termed femoral retroversion, femoral retro-torsion or decreased anteversion of the affected side. In the prone position, using a goniometer, the axis of the thigh with the foot is examined and the tight-foot-axis (TFA) is determined (Fig. 2B). A computerized-tomography-rotational profile (axial cuts through the femoral necks, femoral condyles, and ankles) is helpful to corroborate the clinical examination.

PREOPERATIVE PLANNING— RADIOGRAPHIC ANALYSIS

High-quality radiographs are required for accurate assessment of malalignment in the coronal and sagittal planes. In addition, calibrated images that include the entire bone provide preoperative assessment of the intramedullary canal diameter and help choose the osteotomy location (Fig. 3). The smallest nail length (SNL) is calculated according to a formula based the following: The PRECICE implant has a smaller diameter-telescoping segment on the distal aspect that measures 30 mm. Additionally, at least 50 mm of the rod should be stabilizing the bone on the distal end. The smallest nail length = osteotomy location + amount of lengthening + 30 mm (small part of rod at distal end) + 50 mm (thick part of rod to stabilize distal segment) (Fig. 3B).

Length assessment is measured off a standing anteroposterior 51" hip-to-ankle radiograph. The patient should be sent to the x-ray suite with the block that equalizes their limb. The x-ray technicians should be instructed to annotate the film indicating the block height used (Fig. 4A). Joint orientation angles, bone lengths, and limb lengths are measured using the direct and indirect methods (Fig. 4C).¹⁵ The indirect measurement records the length difference from the top of the iliac crests, accounting for the foot and pelvic heights (Fig. 4B). Fig. 5 represents x-rays of the tibia that correlate to the same patient in the previous figures. From his standing x-ray, Fig. 4, his medial proximal tibial angle (MPTA) of 86 degrees with an associated mechanical axis deviation (MAD) of 11 mm medial indicated varus alignment. This coronal alignment is taken into consideration when planning for his

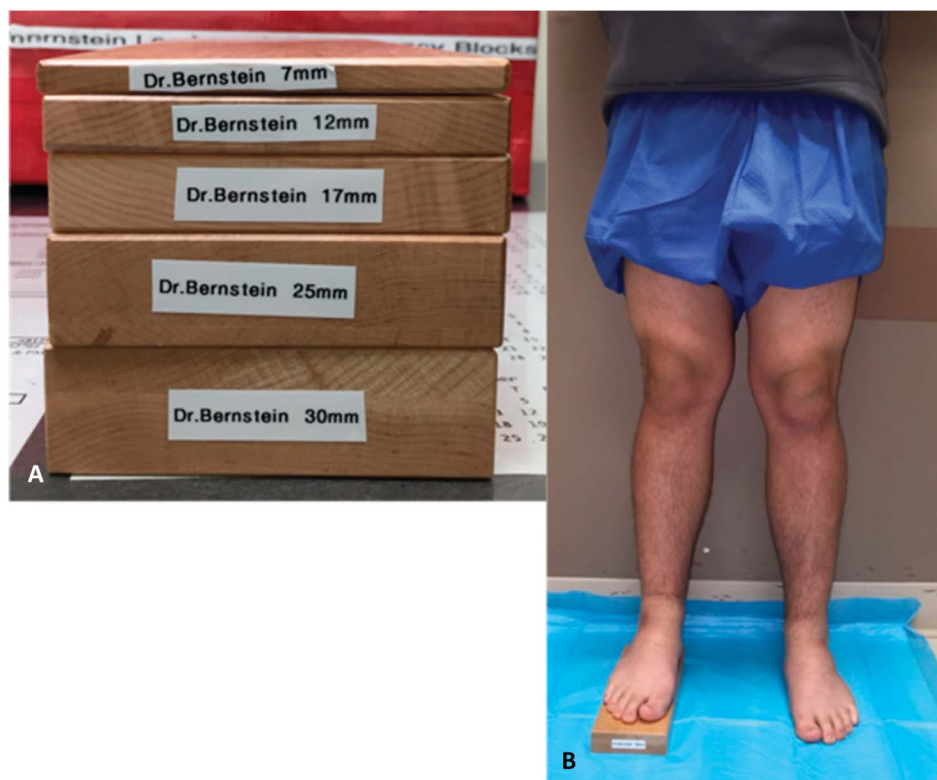

FIGURE 1. A, Clinical photograph of various calibrated solid-wood blocks to equalize limb lengths in the office setting. B, Patient standing on a 30-mm block that he reported felt most accurate in leveling his discrepancy.

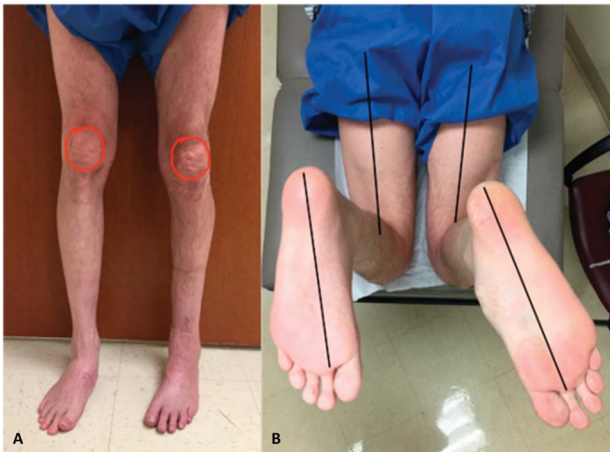

FIGURE 2. Clinical photographs of a 43-year-old male with posttraumatic malunion of his femur and tibia after a motor vehicle accident 20 years prior. The patient had a 30-mm limb-length discrepancy (left side short); however, other components of his malunion were sought during the clinical examination. A, With the patient’s patellae facing forward, an internal rotation deformity of his left lower-extremity was evident. B, The patient is prone on the examining table. The thigh-foot-axis (normal 15 degrees external) is determined with assessing the axis of the thigh and the sole of the foot using a goniometer. Note the internal rotation deformity of the left tibia.

lengthening. The patient had had an ankle fusion and noted ambulating on the lateral aspect of his foot. Therefore, preoperative planning aimed to move his alignment into relative valgus, by increasing his MPTA to 89 degrees (Figs. 5 and 6).

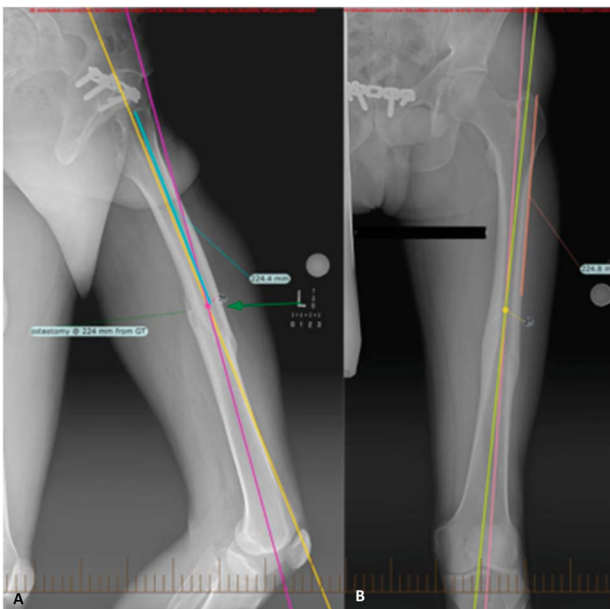


FIGURE 3. X-rays of the left femur of the same patient as in Figure 2. The PRECICE nail is a straight implant; therefore, the osteotomy location is chosen based on the apex of the sagittal bow (or in this case, apex of the malunion) (A). The osteotomy location is template on the AP image (B).

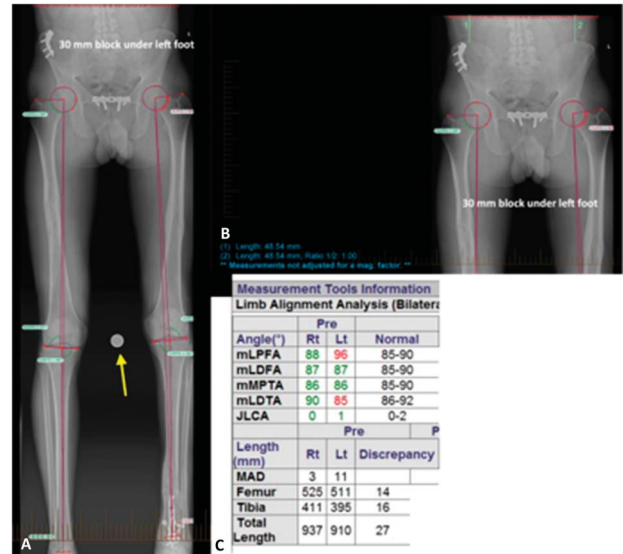


FIGURE 4. Standing 51// hip-to-ankle radiograph of same patient as in Figure 2. Note the calibration marker (yellow arrow) and film annotated that the patient is standing with 30-mm block—this equalizes his pelvis. C, Joint orientation angles, mechanical axis deviation, and limb lengths generated using CAD software.

INTRAOPERATIVE EXECUTION

A detailed step-by-step plan should be outlined in the operating room. The sequences of steps are important. The osteotomy location should be marked according to the preoperative plan (Figs. 3 and 5). A percutaneous incision is made, and the osteotomy site is vented with a large caliber

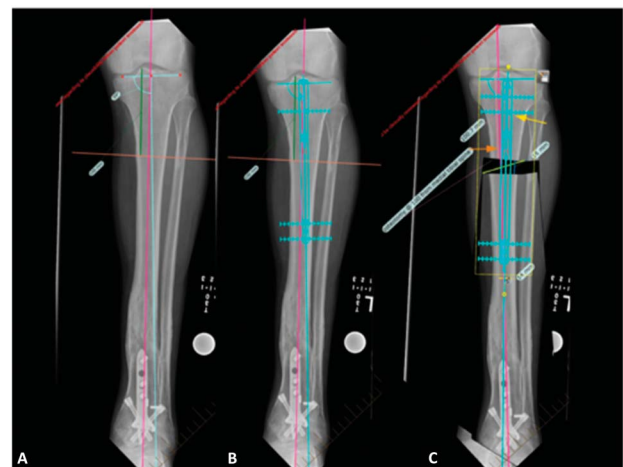
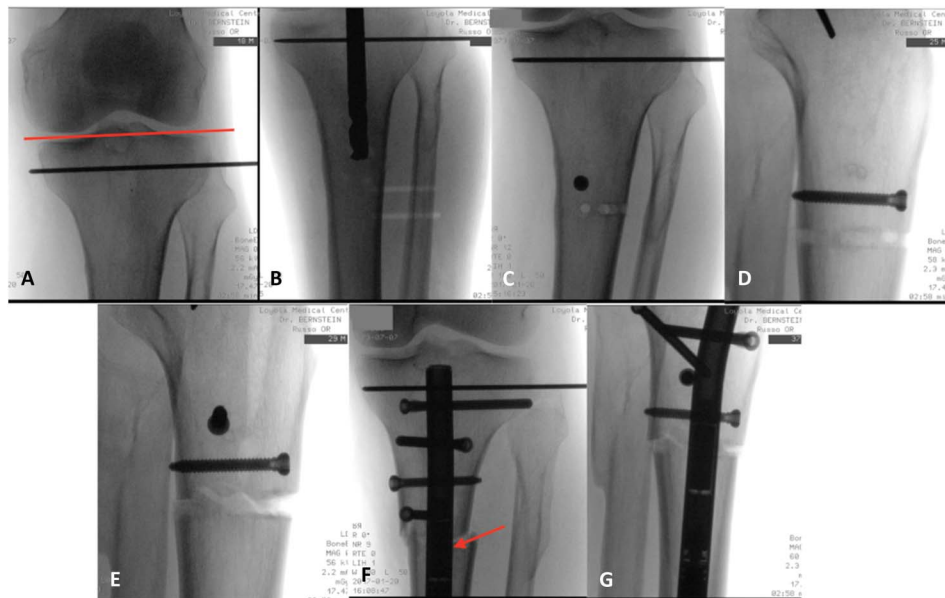


FIGURE 5. A and B, X-rays of the left tibia of the same patient as in Figure 2. In addition to lengthening, the preoperative plan aimed to correct his medial proximal tibial angle (MPTA) to 89 degrees. C, Virtual osteotomy and deformity correction with planned osteotomy location at 100 mm and blocking screws on medial side near osteotomy and lateral side proximally in tibial metaphysis. Planned for a 12.5-mm-diameter PRECICE tibial nail.

FIGURE 6. Intraoperative execution. Guide-wire placed parallel to tibial joint to represent joint orientation line (A). Ten millimeter opening reamer with trajectory collinear with proximal axis, generating new MPTA of 89 degrees consistent with preoperative templating (B). Blocking screw placed medially adjacent to osteotomy, which has been pre-drilled (C and D). Additionally, blocking screw was placed posteriorly in proximal segment to mitigate the procurvatum deformity (E). Intraoperative x-rays after placement of 12.5-mm-diameter PRECICE nail (F and G). Red arrow indicating location of magnet, which is marked on the skin for the patient.



drill-bit (eg, 4.8 mm). This helps reduce the likelihood of fat embolism and deposits bone graft at the osteotomy site to augment regenerate maturation (Figs. 6C, D and 7A). In addition, it is the first step of the low-energy osteotomy for lengthening. The other type of osteotomy used for lengthening is performed with a Gigli saw.¹⁶

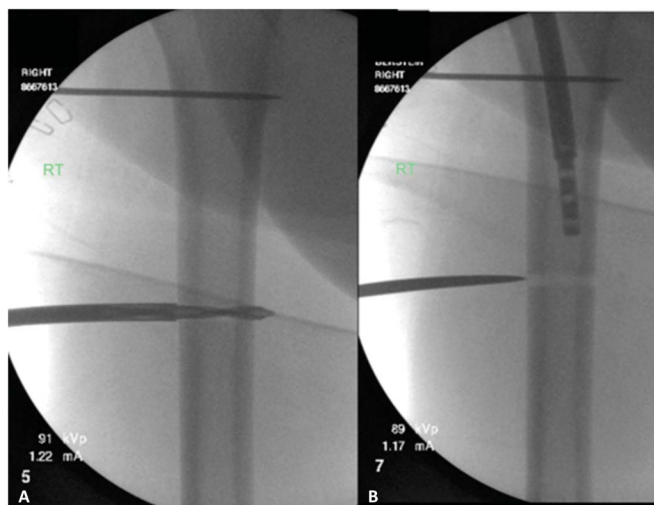
Large caliber (2.4 mm) Steinman pins are used to mark the rotation of the limb before completing the osteotomy. This helps maintain alignment or can be used to correct it as part of the procedure. The intramedullary canal is prepared to accommodate the appropriate-sized PRECICE nail. We typically ream 2 mm over the planned PRECICE nail diameter (eg, ream to 10.5 mm for 8.5 mm nail; 12.5 mm for 10.7 mm nail; 14.5 mm for 12.5 mm nail). Because it is a noncannulated (solid) nail, the guide-wire must be removed before nail insertion. Typically, the nail is advanced into the proximal segment, the low-energy osteotomy is completed, and the nail advanced gently into the distal segment (Fig. 7B).

POSTOPERATIVE REGIMEN

The location of the magnet is marked on the patient’s skin using fluoroscopy (Fig. 6F). It is important that this is marked either with a nonabsorbable stitch or permanent marker, so that the patient has access to this to place the external remote controller (ERC) for activating the lengthening magnet. Range of motion exercises are started immediately with supervision of a physical therapist. Weight bearing is restricted to 50 lbs (8.5 mm and 10.7 mm PRECICE second-generation nails) and 75 lbs (12.5 mm PRECICE second-generation nails). Calibrated x-rays are obtained every 2 weeks to confirm the amount of distraction. The patient is advanced to full weight bearing once 3 out of 4 cortices are fully formed. The nail is removed typically at 1-year postoperatively.

Distraction osteogenesis using the Ilizarov method is an effective strategy to correct complex posttraumatic deformities. The ability to manage these conditions with an internal

FIGURE 7. Intraoperative x-rays of 4.8-mm drill-bit venting femur at osteotomy locations (A). Note Steinman pin in proximal femur that serves as rotational marker. B, PRECICE nail advanced into proximal segment while osteotomy is completed.



lengthening nail has lead to an improved patient's episode of care because most of the problems associated with the Ilizarov method are attributable to the external fixator (pin site infection, soft-tissue irritation, contractures). However, despite the relative ease of use and familiarity of an intramedullary nail, surgeons practicing the Ilizarov method must understand principles of deformity correction (joint orientation angles, limb alignment). Surgeons must be able to accurately quantify all components of limb malalignment and be prepared to manage the complications associated with distraction osteogenesis (poor regenerate, premature consolidation, joint contracture, joint subluxation).

REFERENCES

1. Ilizarov GA. The tension-stress effect on the genesis and growth of tissues: Part II. The influence of the rate and frequency of distraction. *Clin Orthop Relat Res.* 1989;239:263–285.
2. Ghoneem HF, Wright JG, Cole WG, et al. The Ilizarov method for correction of complex deformities. Psychological and functional outcomes. *J Bone Joint Surg Am.* 1996;78:1480–1485.
3. Herzenberg JE, Scheufele LL, Paley D, et al. Knee range of motion in isolated femoral lengthening. *Clin Orthop Relat Res.* 1994;301:49–54.
4. Bernstein M, Fragomen AT, Sabharwal S, et al. Does integrated fixation provide benefit in the reconstruction of posttraumatic tibial bone defects? *Clin Orthop Relat Res.* 2015;473:3143–3153.
5. Krieg AH, Lenze U, Speth BM, et al. Intramedullary leg lengthening with a motorized nail. *Acta Orthop.* 2011;82:344–350.
6. Kenawey M, Krettek C, Liodakis E, et al. Leg lengthening using intramedullary skeletal kinetic distractor: results of 57 consecutive applications. *Injury.* 2011;42:150–155.
7. Guichet JM, Deromedis B, Donnan LT, et al. Gradual femoral lengthening with the Albizzia intramedullary nail. *J Bone Joint Surg Am.* 2003;85-A:838–848.
8. Dincyurek H, Kocaoglu M, Eralp IL, et al. Functional results of lower extremity lengthening by motorized intramedullary nails. *Acta Orthop Traumatol Turc.* 2012;46:42–49.
9. Schiedel FM, Vogt B, Tretow HL, et al. How precise is the PRECICE compared to the ISKD in intramedullary limb lengthening? Reliability and safety in 26 procedures. *Acta Orthop.* 2014;85:293–298.
10. Paley D. PRECICE intramedullary limb lengthening system. *Expert Rev Med Devices.* 2015;12:231–249.
11. Laubscher M, Mitchell C, Timms A, et al. Outcomes following femoral lengthening: an initial comparison of the precise intramedullary lengthening nail and the LRS external fixator monorail system. *Bone Joint J.* 2016;98-B:1382–1388.
12. Kirane YM, Fragomen AT, Rozbruch SR. Precision of the PRECICE internal bone lengthening nail. *Clin Orthop Relat Res.* 2014;472:3869–3878.
13. Ilizarov GA. Clinical application of the tension-stress effect for limb lengthening. *Clin Orthop Relat Res.* 1990;250:8–26.
14. Ilizarov GA. The tension-stress effect on the genesis and growth of tissues. Part I. The influence of stability of fixation and soft-tissue preservation. *Clin Orthop Relat Res.* 1989;238:249–281.
15. Paley D. *Principles of Deformity Correction.* New York, NY: Springer; 2004.
16. Paley D, Tetsworth K. Percutaneous osteotomies. Osteotome and Gigli saw techniques. *Orthop Clin North Am.* 1991;22:613–624.