

Retroperitoneal Fibrosis as a Cause of Chylous Ascites

Adnan Ur Rahman, MBBS, MRCP¹, Rajeswari Ramaraj, MBBS, MRCP¹, Emyr Humphreys, MBBS, FRCP², and Elizabeth Slowinska, MBBS, MRCP³

¹Department of Gastroenterology, University Hospital Llandough, Cardiff, South Wales, United Kingdom

²Department of Rheumatology, Prince Charles Hospital, Merthyr Tydfil, South Wales, United Kingdom

³Department of Gastroenterology, Prince Charles Hospital, Merthyr Tydfil, South Wales, United Kingdom

ABSTRACT

Retroperitoneal fibrosis is a rare condition characterized by chronic inflammation and marked fibrosis of the retroperitoneal tissue, often leading to entrapment of abdominal organs. We report a 69-year-old white man who presented with a 5-week history of gradual onset of progressive abdominal distension. He had no history or risk factors for an underlying liver condition. Ascites and a retroperitoneal mass encasing the major abdominal vessels were revealed on imaging. Biopsies of the mass confirmed the presence of retroperitoneal fibrosis, and the ascitic fluid was milky, consistent with chylous ascites. We discuss this rare presentation and the challenges of treatment for chylous ascites caused by RPF, including the role for supportive treatment.

INTRODUCTION

Retroperitoneal fibrosis (RPF) or Ormond's disease is a rare condition that is characterized by chronic inflammation and marked fibrosis of the retroperitoneal tissue, which often leads to entrapment of the ureters and other abdominal organs.¹ The clinical manifestations heralding RPF are usually non-specific and often are related to localized mass effect and systemic symptoms related to the inflammatory nature of the disease.²

CASE REPORT

A 69-year-old white man presented with a 5-week history of gradual onset of progressive abdominal distension. He did not report any other gastrointestinal symptoms and denied night sweats or recent travel abroad. His comorbid history included ischemic heart disease, with a myocardial infarction 11 years before this presentation. He was a former smoker, having quit 11 years ago (smoked 20 cigarettes per day for 35 years) and denied excessive alcohol intake or recreational drug use. His medications included an angiotensin-converting enzyme (ACE) inhibitor, a beta blocker, and a statin, all of which he had been taking for many years. He reported a family history of cancer, with 2 siblings deceased due to cancer of unknown origin. He had no history of previous blood transfusions, tattoos, or intravenous (IV) drug use. He was a farmer 20 years prior to presentation and had no exposure to asbestos. A clinical examination confirmed shifting dullness and the presence of ascites with no organomegaly. He had no peripheral stigmata of chronic liver disease, and the rest of the systemic examination was unremarkable.

He had a normal complete blood count, clotting, liver function tests, liver screen serum ACE level, and urine analysis, and his renal function was moderately impaired (glomerular filtration rate 51 mL/min). Serum electrophoresis was normal, with a mild but not significant elevation in the immunoglobulin G4 (IgG4) subset. Macroscopic examination of the ascitic fluid revealed a milky color with elevated triglyceride levels consistent with chylous ascites. Microscopic analysis showed a cell count of 80% lymphocytes with no evidence of a bacterial peritonitis or tuberculosis. The transudate had a normal cytological examination. Ultrasonography confirmed a large volume of ascites

ACG Case Rep J 2017;4:e115. doi:10.14309/crj.2017.115. Published online: October 25, 2017.

Correspondence: Adnan Ur Rahman, Department of Gastroenterology, University Hospital of Llandough, Penlan Road, Llandough, Penarth, Cardiff, South East Wales, United Kingdom CF64 7XX (adnanurrahman@gmail.com).



Copyright: © 2017 Ur Rahman et al. This work is licensed under a Creative Commons Attribution-NonCommercial-NoDerivatives 4.0 International License. To view a copy of this license, visit <http://creativecommons.org/licenses/by-nc-nd/4.0>.

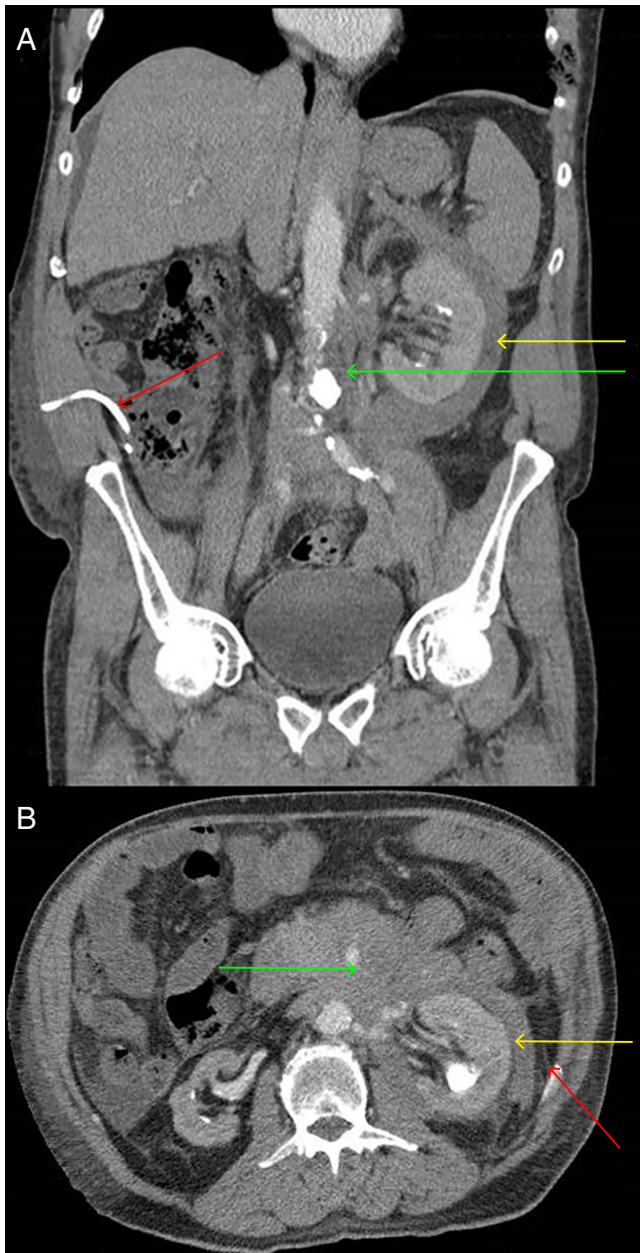


Figure 1. (A) Abdominal and (B) pelvic computed tomography confirming a retroperitoneal mass encasing the main abdominal vessels-mesenteric. Noted on the images are the renal and upper abdominal aorta (green arrow), the residual ascites with pigtail in situ (red arrow), and hydronephrosis with some ureteric obstruction (yellow arrow).

with a normal liver and portal vein. An abdominal and pelvic computed tomography (CT) showed a mildly enhancing soft-tissue mass lesion encasing the mesenteric renal vessels and partly encasing the upper abdominal aorta, and the pancreas was involved as well (Figure 1). There was no overt involvement of the renal areas, but the left kidney appeared slightly enlarged, suggesting a degree of ureteric involvement, although the ureters were noted to be patent. These appearances were reported to be highly suggestive of a

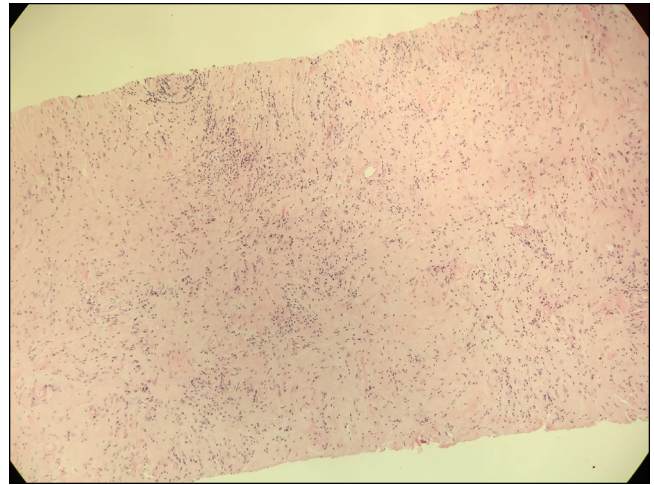


Figure 2. Hematoxylin and eosin stain showing fibrosis and inflammation (magnification 400 \times).

lymphoproliferative disorder with mass lesion. A completion CT staging did not reveal any evidence of lymphadenopathy or other pathology.

Histology of a CT-guided biopsy confirmed a diagnosis of idiopathic RPF (Figure 2). Immunohistochemistry was normal and did not support Ig4 disease. The patient developed worsening renal failure during his hospital stay. A renal consult confirmed clinical intravascular fluid depletion, and IV fluids were commenced, resulting in an improvement in renal function. This confirmed a prerenal cause for the acute deterioration. Once his renal function started to improve, the rheumatologists suggested that he might benefit from corticosteroid therapy. This was mainly to prevent further progression of the inflammatory process of RPF and thereby slow or stop the advancement of obstruction and worsening of renal failure. He was given 3 pulsed doses of 500 mg IV methyl prednisolone. He was discharged and started on daily oral steroids, but the ascites rapidly reaccumulated and kidney function did not improve. Steroid therapy was discontinued. While he was on steroids, he was also started on azathioprine; this immunosuppressant was stopped due to intolerance. Since his discharge, large-volume paracentesis has been performed every 2–3 weeks for recurrent ascites. The patient currently awaits placement of an ascitic pump to allow home management.

DISCUSSION

One case report in the literature reports chylous ascites occurring once during the course of progressive idiopathic RPF.³ To our knowledge, ours is the first case report that describes chylous ascites as an initial presentation of underlying RPF. Chylous ascites frequently presents as a progressive and painless abdominal distension, particularly if due to an

atraumatic cause.⁴ Chylous ascites is an uncommon cause of ascites and occurs due to the leakage of lipid-rich lymph into the peritoneal cavity due to damage or obstruction of the lymphatic system.⁵ A systematic review of the literature suggests that one of the common causes of atraumatic chylous ascites is malignancy (25%), followed by cirrhosis (16%) and a variety of less common causes (23%).⁶ In this particular case, compression of the retroperitoneal lymphatics is a plausible explanation for the manifestation of chylous ascites. We also noted that there was some encasement of the pancreas, which also is not commonly reported in the literature.⁷ Intermittent large-volume paracentesis or even continuous drainage via a catheter is a reasonable management option for symptom relief.⁸

RPF can be idiopathic or secondary. Secondary RPF causes include drugs, underlying malignancy, infections, radiotherapy, and surgery.¹ Idiopathic RPF constitutes about 70% of cases, and the pathogenesis remains unclear, although there is a suggestion that asbestos exposure may be one of the risk factors.^{1,9,10} The primary modality used for diagnosis of RPF is CT or magnetic resonance imaging.¹¹ Biopsies of masses are generally performed to exclude secondary causes, such as malignancy and IgG4-related pathology. The primary treatment of idiopathic RPF is medical therapy, i.e., corticosteroid therapy, and this is mainly to prevent the progression of the inflammatory process and the ensuing consequences, e.g., ureteric obstruction leading to advanced or end-stage renal failure.¹ In cases where RPF is unresponsive to steroid therapy, immunosuppressant therapy can be used.^{12,13} This case report demonstrates a rare presentation and the challenges of treatment for chylous ascites caused by RPF, including the role for supportive treatment.

DISCLOSURES

Author contributions: A. Ur Rahman and R. Ramaraj wrote the manuscript. E. Humphreys and E. Slowinska edited the manuscript. E. Slowinska is the article guarantor.

Financial disclosures: None to report.

Informed consent was obtained for this case report.

Received June 18, 2017; Accepted September 13, 2017

REFERENCES

1. Vaglio A, Salvarani C, Buzio C. Retroperitoneal fibrosis. *Lancet*. 2006;367(9506):241-51.
2. Vaglio A, Palmisano A, Alberici F, et al. Prednisone versus tamoxifen in patients with idiopathic retroperitoneal fibrosis: An open-label randomised controlled trial. *Lancet*. 2011;378(9788):338-46.
3. Sakai Y, Nasu T. Idiopathic retroperitoneal fibrosis. *Acta Pathol Jpn*. 1976;26(5):637-47.
4. Almakdisi T, Massoud S, Makdisi G. Lymphomas and chylous ascites: Review of the literature. *Oncologist*. 2005;10(8):632-5.
5. Cárdenas A, Chopra S. Chylous ascites. *Am J Gastroenterol*. 2002;97(8):1896-900.
6. Steinemann DC, Dindo D, Clavien PA, Nocito A. Atraumatic chylous ascites: Systematic review on symptoms and causes. *J Am Coll Surg*. 2011;212(5):899-905.
7. Zielonko J, Obołonczyk L. Retroperitoneal fibrosis with pancreatic involvement: Radiological appearance. *Pol J Radiol*. 2011;76(4):69-72.
8. Al-Busafi SA, Ghali P, Deschênes M, Wong P. Chylous ascites: Evaluation and management. *ISRN Hepatol*. 2014;2014:240473.
9. Cronin CG, Lohan DG, Blake MA, Roche C, McCarthy P, Murphy JM. Retroperitoneal fibrosis: A review of clinical features and imaging findings. *AJR Am J Roentgen*. 2008;191(2):423-31.
10. Uibu T, Oksa P, Auvinen A, et al. Asbestos exposure as a risk factor for retroperitoneal fibrosis. *Lancet*. 2004;363(9419):1422-6.
11. Feinstein RS, Gatewood OM, Goldman SM, Copeland B, Walsh PC, Siegelman SS. Computerized tomography in the diagnosis of retroperitoneal fibrosis. *J Urol*. 1981;126(2):255-9.
12. Alberici F, Palmisano A, Urban ML, et al. Methotrexate plus prednisone in patients with relapsing idiopathic retroperitoneal fibrosis. *Ann Rheum Dis*. 2013;72(9):1584-6.
13. Adler S, Lodermeier S, Gaa J, Heemann U. Successful mycophenolate mofetil therapy in nine patients with idiopathic retroperitoneal fibrosis. *Rheumatology (Oxford)*. 2008;47(10):1535-8.