



# Anatomic Considerations in Hamstring Tendon Harvesting for Ligament Reconstruction

Anell Olivos-Meza, M.D., Ph.D., Carlos Suarez-Ahedo, M.D.,  
César Alejandro Jiménez-Aroche, M.D., Natalia Pantanali, M.D.,  
Marco Vinicio Valdez-Chávez, M.D., Francisco Javier Pérez-Jiménez, M.D.,  
Brenda Olivos-Díaz, V.M.D., Norma A. Olivos-Gárces, P.M.&R.,  
Antonia González-Hernández, Psy.S., and Clemente Ibarra, M.D., Ph.D.

**Abstract:** Hamstring tendon autograft remains a popular graft choice for anterior cruciate ligament reconstruction. Although the technique of hamstring autograft harvest is relatively straightforward, it is critical to pay attention to several technical steps to avoid iatrogenic anatomic or neurovascular damage as well as to reduce the risk of premature amputation of the graft when using a tendon stripper. We describe a technique of hamstring autograft harvesting using only 2 anatomic references that makes it a simple and reproducible technique for surgeons, especially those in training.

**K**nee ligament injury is a common pathology globally. Anterior cruciate ligament (ACL) rupture accounts for 64% of knee pathologies. The ACL is frequently injured not only in athletes but also in nonathletic individuals, being a health problem in orthopedics.<sup>1</sup>

ACL reconstruction is one of the most common operations performed in the area of arthroscopy and sports medicine.<sup>2,3</sup> This surgical procedure is often performed using either hamstring tendon or patellar tendon autograft. It yields good results, but current techniques are not free of technical complications, especially related to graft harvesting. These include the small diameter of tendons, chronic inflammation with poor-quality hamstring tendons, premature amputation, and anterior knee pain in the case of the patellar

tendon.<sup>4</sup> Semitendinosus-gracilis (ST-G) tendon grafts are currently the most used grafts for cruciate ligament reconstruction, collateral ligament reconstruction, and medial patellofemoral ligament reconstruction. These grafts have several advantages: They are autologous, have less risk of disease transmission, preserve the integrity of the knee extensor mechanism, and have a lower rate of anterior knee pain.<sup>5-7</sup>

Sometimes, it is difficult to correctly identify the anatomic structures in the knee. Because of this, potential complications can occur during graft harvest; these include inadvertent division of the tendons; disinsertion of the pes anserinus; damage to the medial collateral ligament (MCL); and neurologic injury, mostly to the infrapatellar branch of the saphenous nerve (IPBSN).<sup>8,9</sup> The rate of MCL injury can increase during the learning curve for ST-G tendon harvesting. The proximity of the hamstring tendons in the pes anserinus area to the IPBSN predisposes the nerve to damage during harvesting. Vertical, horizontal, and even oblique incision methods have been proposed to reduce the risk of IPBSN injury; nevertheless, no consensus has been reached regarding the optimal incision method in the pes anserinus area for hamstring tendon harvest.<sup>3</sup> Sgaglione et al.<sup>10</sup> reported a 37.5% incidence of infrapatellar paresthesia in patients who had undergone primary repair of a torn ACL with semitendinosus tendon augmentation by an open technique. During harvesting of the ST-G tendons, the knee should be flexed and the hip externally rotated to improve exposure and reduce tension on the saphenous nerve.

*From the Orthopaedic Sports Medicine and Arthroscopy Service, Instituto Nacional de Rehabilitación, Mexico City, Mexico.*

*The authors report that they have no conflicts of interest in the authorship and publication of this article. Full ICMJE author disclosure forms are available for this article online, as [supplementary material](#).*

*Received July 26, 2019; accepted September 24, 2019.*

*Address correspondence to Clemente Ibarra, M.D., Ph.D., Orthopaedic Sports Medicine and Arthroscopy, Instituto Nacional de Rehabilitación "Luis Guillermo Ibarra Ibarra," Calzada México-Xochimilco 289, ZC 14389, Mexico City, Mexico. E-mail: [cibarra.corresponding@hotmail.com](mailto:cibarra.corresponding@hotmail.com)*

© 2019 by the Arthroscopy Association of North America. Published by Elsevier. This is an open access article under the CC BY-NC-ND license (<http://creativecommons.org/licenses/by-nc-nd/4.0/>).

2212-6287/19931

<https://doi.org/10.1016/j.eats.2019.09.021>

Knowledge of the peri-hamstring neurovascular and musculoskeletal anatomy is crucial for a successful harvest with minimal postoperative morbidity. The aim of this article was to describe a reproducible technique for ST-G tendon harvesting through easy identification of 2 main anatomic structures in the knee. The potential benefits of this technique are a reduction in the harvesting time and a decrease in the risk of complications among orthopaedic surgeons. It is important to mention that the technique is based primarily on anatomic references that have not been previously described in this way in the literature. The name of this technique is an acronym of 3 surnames of the authors (Olivos, Ibarra, and Suárez: OLIBAS technique). This technique can be considered innovative and simple and is easily reproducible by other surgeons, especially those at the beginning of the learning curve. A summary of key steps is provided in Table 1, and the technique is presented in Video 1.

Surgical Technique

Patient Positioning

We perform this surgical procedure with the patient under epidural anesthesia in the supine position. Prior to

final positioning, the injured knee is examined under anesthesia to confirm the diagnosis. If there is any concern over the lesions, a diagnostic arthroscopy can be performed prior to harvesting the hamstring tendons. After the examination under anesthesia, a padded non-sterile tourniquet is placed high on the operative thigh, and the patient is positioned such that the operative leg is hanging off the end of the operating table (Fig 1A). The operative leg is prepared and draped in standard fashion.

Anatomic Landmarks

Two main anatomic landmarks are considered and drawn for hamstring tendon harvesting in this technique: the tibial tubercle (TT) (Fig 1B) and the medial border of the tibia (MBT). The MBT is drawn as a “hockey stick” shape (Fig 1 E and F). Because arthroscopy is performed in all cases, additional references are drawn for standard portals including the patellar contour and patellar tendon (Fig 1). One important tip for precisely defining the main anatomic landmarks is to place the knee in 90° of flexion; otherwise, the landmarks may be poorly referred, the incision may be made outside of the correct area, and finding the tendons may be very difficult with a higher risk of complications.

Skin Incision Placement

Once the tip of the TT and the MBT are identified, a horizontal line is drawn to connect these structures (Fig 2 A and B). This horizontal line is divided into thirds (Fig 2C), and a vertical incision mark (or oblique incision if preferable to the surgeon) of approximately 15 to 20 mm is drawn (Fig 3A).

Two scalpel blades are used: A No. 20 blade is first used to approach the skin (Fig 3A); then, with a No. 15 blade, the incision is carried through the subcutaneous tissue (SCT) (Fig 3B), enlarging the incision subcutaneously, cutting only the SCT proximally and distally. This facilitates the displacement of the skin, permitting more laxity and a better view of the deeper planes through a smaller skin incision. During this step, it is very important to perform careful superficial dissection with the scalpel, avoiding going too deep. Blunt dissection of the SCT is performed medially and laterally using 2 Farabeuf retractors (Fig 4A) over the sartorial fascia (SF) to reduce the risk of injury to the infrapatellar and sartorial branches of the saphenous nerve. Once the SCT is displaced with the retractors, a wet gauze is introduced into the incision, while the surgeon makes 360° circular movements with the index finger to clean out the remnants. With this step, the risk of cutting the underlying superficial MCL is avoided.

SF Approach

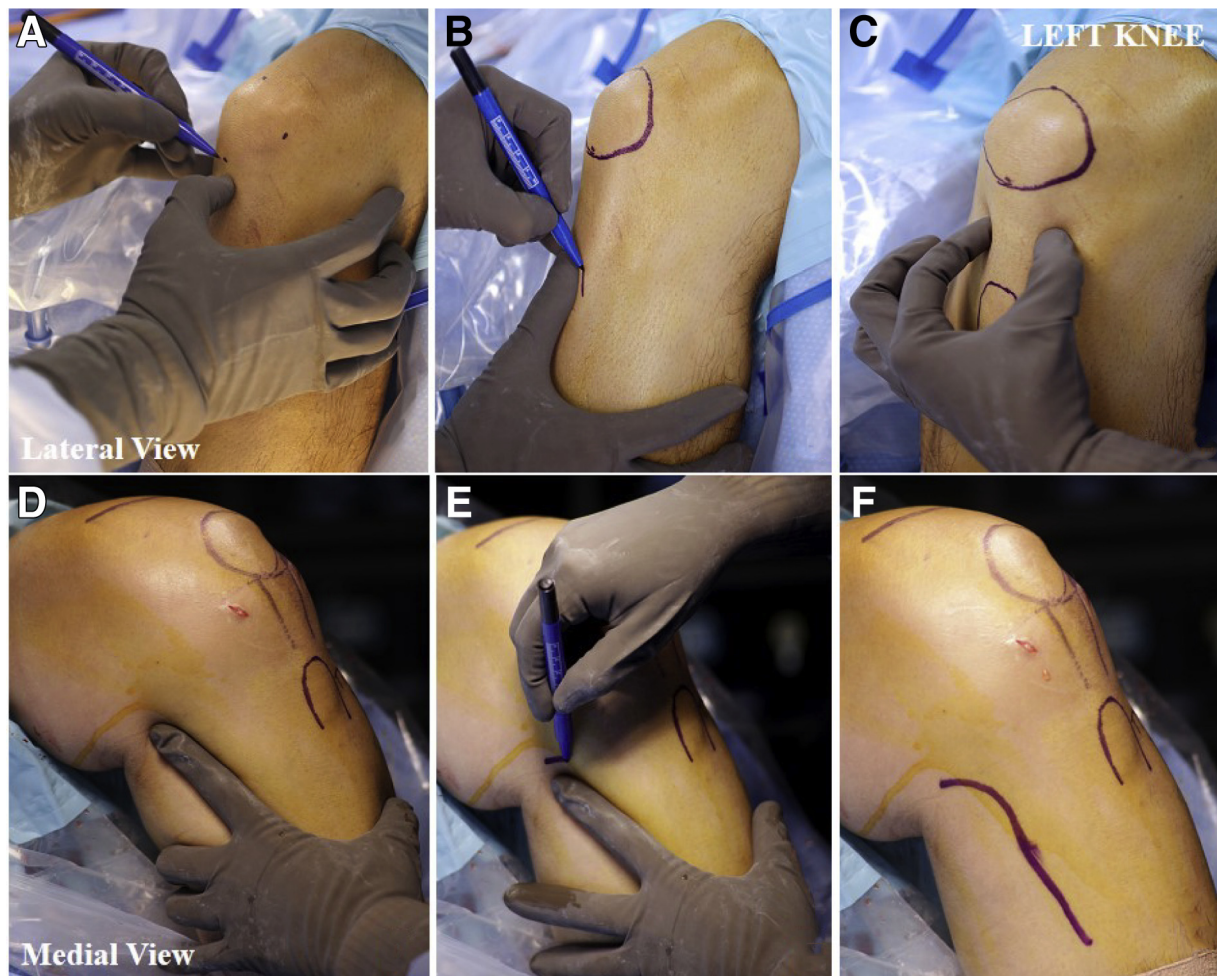
After blunt cleaning out of the SCT, the SF is observed as a pearly white layer into the deeper plane. During this step, it is important to keep the knee in 90° of flexion;

Table 1. Essential Stages for OLIBAS Hamstring Tendon Harvesting Technique

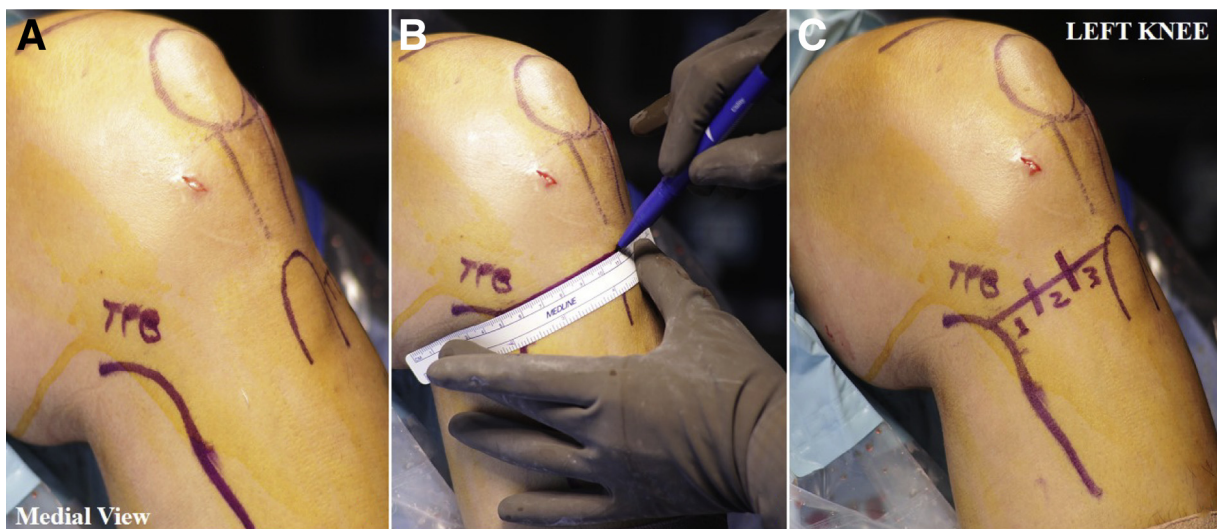
Identify the anatomic landmarks
Identify the TT
Identify the MBT
Draw the skin incision
Mark a horizontal line from the tip of the TT to the MBT
Divide the line into thirds
In the middle third, mark a 15- to 20-mm incision (vertical or oblique)
Perform blunt dissection of the subcutaneous tissue
Perform superficial dissection with a scalpel
Perform displacement of fat medially and laterally with 2 retractors
Clean the fat tissue 360° from the SF
Perform the SF approach
Identify the horizontal step formed by the trajectory of the hamstring
Introduce the tip of a Kelly forceps behind the horizontal step
Open the forceps to make a blunt horizontal incision between the SF and bone
With the scalpel, make the vertical incision of the SF adjacent to the TT
Perform graft harvesting
Evert the SF in an “open wallet” shape to expose the tendons
With a Kelly forceps, release the tendon from the SF
Grasp the tendon and roll it into a clamp to prevent loosening
Maintain tension with a grasper
Push the tendon stripper firmly

NOTE. The most important steps are correct identification of the anatomic references with the knee in 90° of flexion, blunt dissection of the over-elevation in the SF, release of the tendon bands (especially in the semitendinosus), and rolling up the tendon over the forceps to maintain appropriate tension and avoid tendon retraction.

MBT, medial border of tibia; SF, sartorial fascia; TT, tibial tubercle.

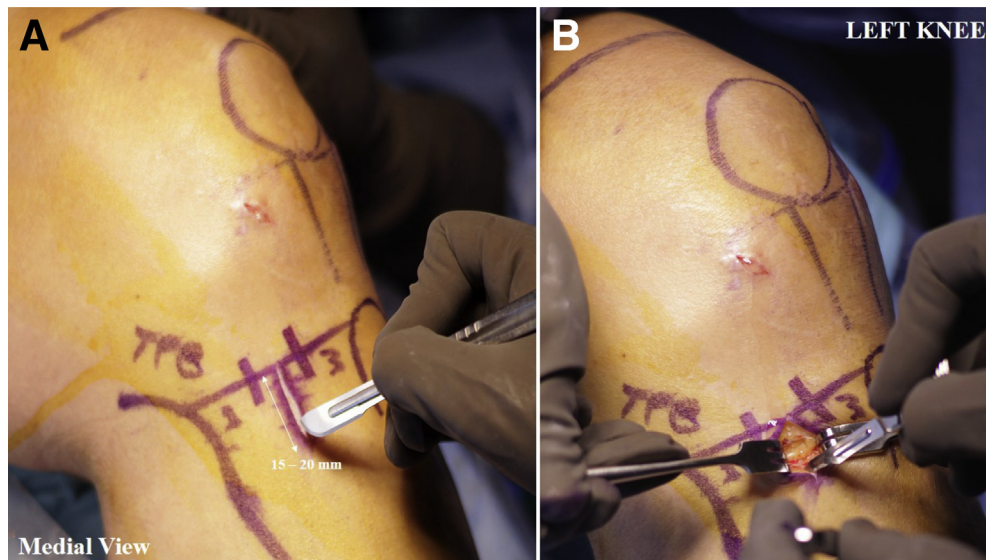


**Fig 1.** Anatomic landmarks for arthroscopy and graft harvesting on a left knee. From a lateral view, (A) left knee at 90° of flexion. (B) Contour of patella and tibial tuberosity are marked. (C) The patellar tendon (PT) is identified, and the access points for arthroscopic standard portals are marked. From a medial view, (D) the medial border of the tibia is identified. (E, F) The posterior border of the tibia is marked in a hockey-stick shape.



**Fig 2.** Crucial landmarks for hamstring tendon harvesting on a left knee. Medial view, (A) medial posterior border of tibia (TPB). (B) Horizontal line from tip of tibial tuberosity to marked tibial border. (C) The horizontal line is divided into thirds.





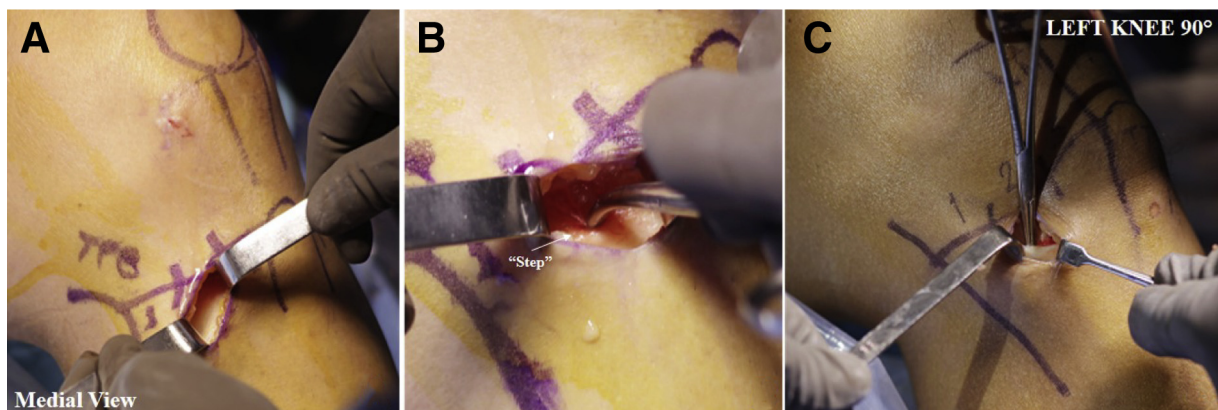
**Fig 3.** Skin incision. (A) An incision is made in the second third. (B) The skin is separated with 2 retractors, and a subcutaneous tissue incision is extended subcutaneously proximally and distally. (TPB, tibial posterior border.)

this position permits tensioning of the hamstring tendons, and the formation of a horizontal “over-elevation” or “step” is identified in the most proximal area of the incision that corresponds to the gracilis tendon pathway. This over-elevation is a very important landmark that allows entry directly into the plane under the SF in a blunt manner, eliminating the risk of cutting the MCL. To go into this plane, the tip of a Kelly forceps is gently introduced from proximal to distal in the over-elevation between the MCL and SF (Fig 4B). The Kelly forceps is opened to allow blunt dissection of the SF (Fig 4C). Then, with the second scalpel (No. 15 blade), a vertical incision is made close to the TT to form an inverted L-shaped incision. The superolateral vertex of the SF is held with an Allis forceps to elevate and detach the SF in the vertical incision adjacent to the TT from proximal to distal to avoid damage to the MCL with the blade edge of the scalpel toward this latter structure (Figs 5 and 6).

With curved Metzenbaum scissors, the horizontal incision of the SF is extended medially to allow eversion of this layer in the shape of an open wallet, a maneuver that immediately exposes the ST-G tendons from proximal to distal (Fig 7).

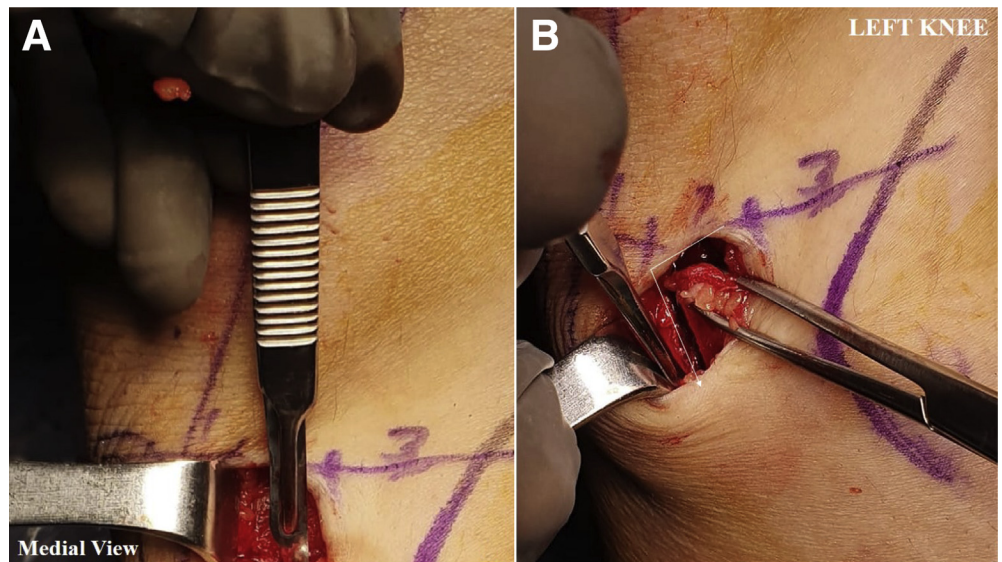
#### Graft Harvesting

With a curved Kelly forceps, the semitendinosus is detached from the SF by inserting the tip from distal to proximal; the forceps then pulls between the fascia and tendon toward the vertical cut to release it from its insertion (Fig 8 A and B). The tendon is grasped about 5 to 10 mm from the tip with the Kelly forceps and is turned 3 to 4 times, rolling it into a clamp to prevent loosening and retraction (Fig 8C). This allows greater tension to release it from its deepest path. It should be remembered that the gracilis rarely has bands, so it is easier to release. When the tendon is free of the deep plane, an arthroscopic forceps is



**Fig 4.** Sartorial fascia (SF) identification on a left knee from medial view. (A) Blunt dissection of the subcutaneous tissue is performed with 2 retractors over the SF; it is observed as a pearly white layer. (B) The knee should be kept in 90° of flexion to maintain the tendon's tension and the formation of a horizontal step. (C) A Kelly forceps is introduced behind the step and is opened to allow dissection of the SF, eliminating the risk of medial collateral ligament injury. (TPB, tibial posterior border.)

**Fig 5.** Inverted L-shaped incision in sartorial fascia. (A) A horizontal incision is completed with a scalpel in the junction with the tibial tuberosity. (B) After the horizontal incision is made, a vertical incision is made close to the tibial tuberosity to form an inverted L-shaped incision.

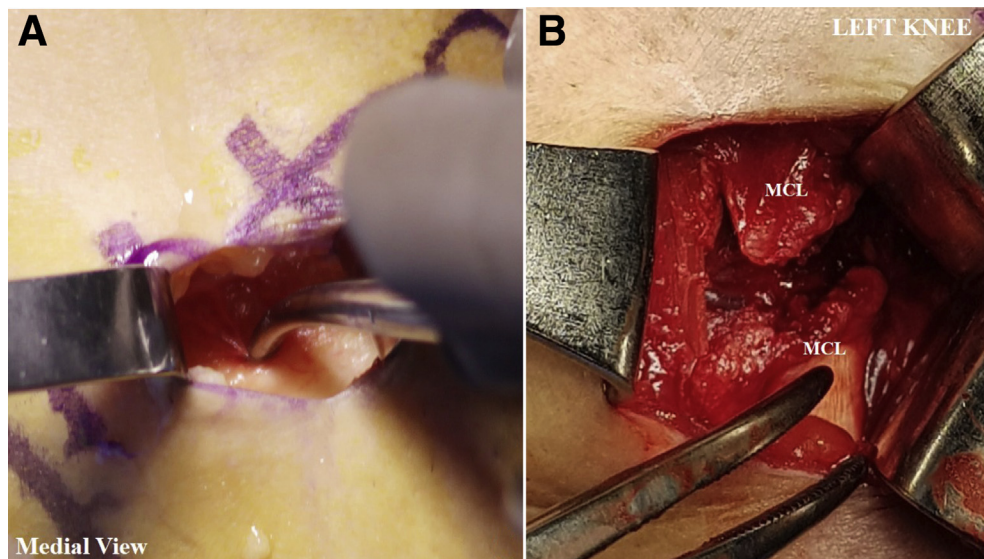


inserted in the hole of the closed stripper, the tendon is held with the tip of the forceps, and then this is exchanged with a strong forceps. The tip of the tendon is held perpendicularly with the strong forceps and rolled up as many times as necessary to allow the knuckles of the surgeon who is taking the graft to rest on the patient's knee; with this method, better control of tension is granted, decreasing the problem of tendon retraction. If the surgeon who takes the graft is right-handed, it is recommended that the left hand be used to apply tension to the tendon with the help of the strong forceps and the dominant hand be used to push firmly toward the deep plane using the stripper until the tendon is released.

Once released, the tendon is passed with the strong forceps to the preparation table. In the case of the semitendinosus, to avoid amputation of the graft, it is very

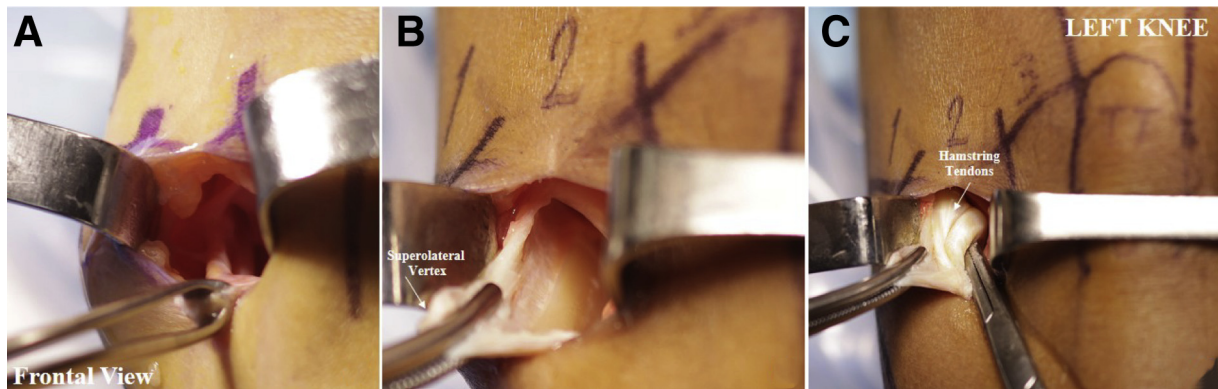
important to adequately release the bands that are present. The surgeon should introduce the index finger following the tendon path and rotate it 360° clockwise from superficial to deep to identify the bands; usually 3 to 4 are found. If the bands are quite deep, we recommend that the surgeon identify them with the finger, hook them with a Kelly forceps to expose them through the incision, and cut them with a scalpel or electrocautery (Fig 9). Once both tendons are released and free, they can be harvested (Figs 10 and 11).

When the tendon is released circumferentially and in its longitudinal path, the surgeon should proceed to perform harvesting as described for the gracilis. At the junction of the horizontal and vertical incisions of the SF, the previously used Allis forceps is left in place to avoid retraction of the fascia; a wet gauze is introduced

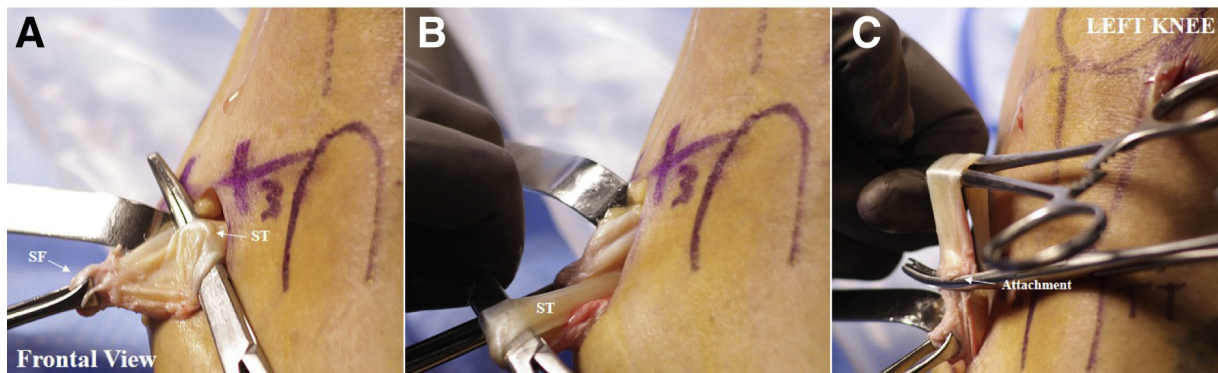

**Fig 6.** Avoiding iatrogenic damage to medial collateral ligament (MCL). (A) Blunt dissection of horizontal incision of sartorial fascia with Kelly forceps. (B) The use of a scalpel too deep can produce iatrogenic damage to the MCL.

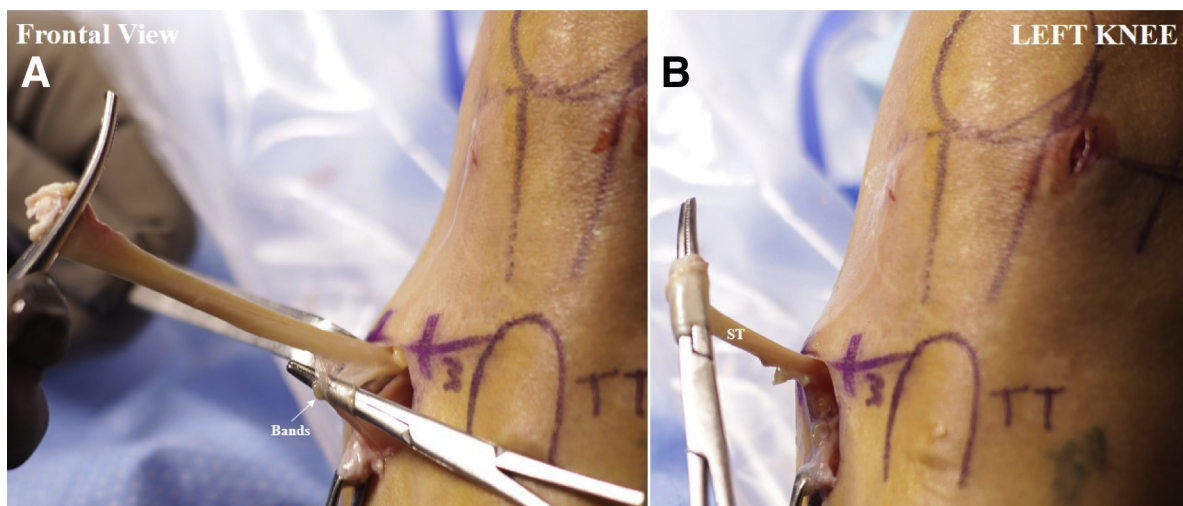




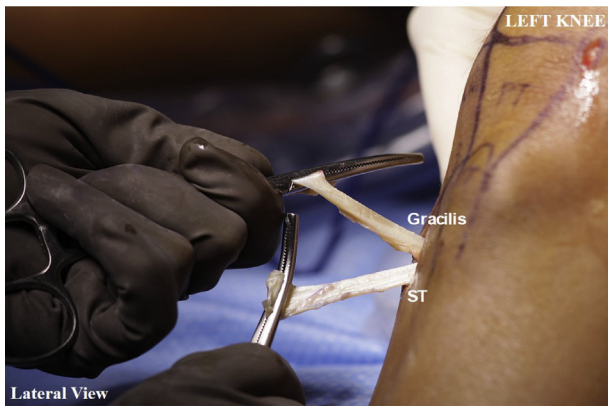
**Fig 7.** Sartorial fascia identification from a frontal view of a left knee. (A, B) Elevation and detachment of superolateral vertex (arrow) of sartorial fascia in vertical incision adjacent to tibial tubercle. (C) Medial extension of the horizontal incision of the sartorial fascia allows this layer's eversion in the shape of an open wallet, immediately exposing the hamstring tendons (arrow) through the incision.



**Fig 8.** Semitendinosus (ST) graft release. (A) A Kelly forceps is used to detach the ST from the sartorial fascia (SF) by inserting the tip. (B) The forceps is pulled between the fascia and tendon toward the vertical cut to release it. (C) The tendon is grasped from the tip, and its attachment is cut.



**Fig 9.** Release of semitendinosus (ST) bands. (A) The bands are identified with the index finger rotated 360°, hooked with a forceps to expose them, and cut. (B) The tendon is grasped with the forceps and rolled into a clamp to prevent loosening and retraction.



**Fig 10.** Hamstring tendon harvesting. Once the bands are released, the semitendinosus (ST) and gracilis can be identified and harvested with a tendon stripper.

underneath the fascia while the tunnels for the ACL reconstruction are made. The same incision, under the SF, is useful for the placement of the tibial tunnel; care should always be taken not to drill too proximal or on the MCL.

### Final Steps

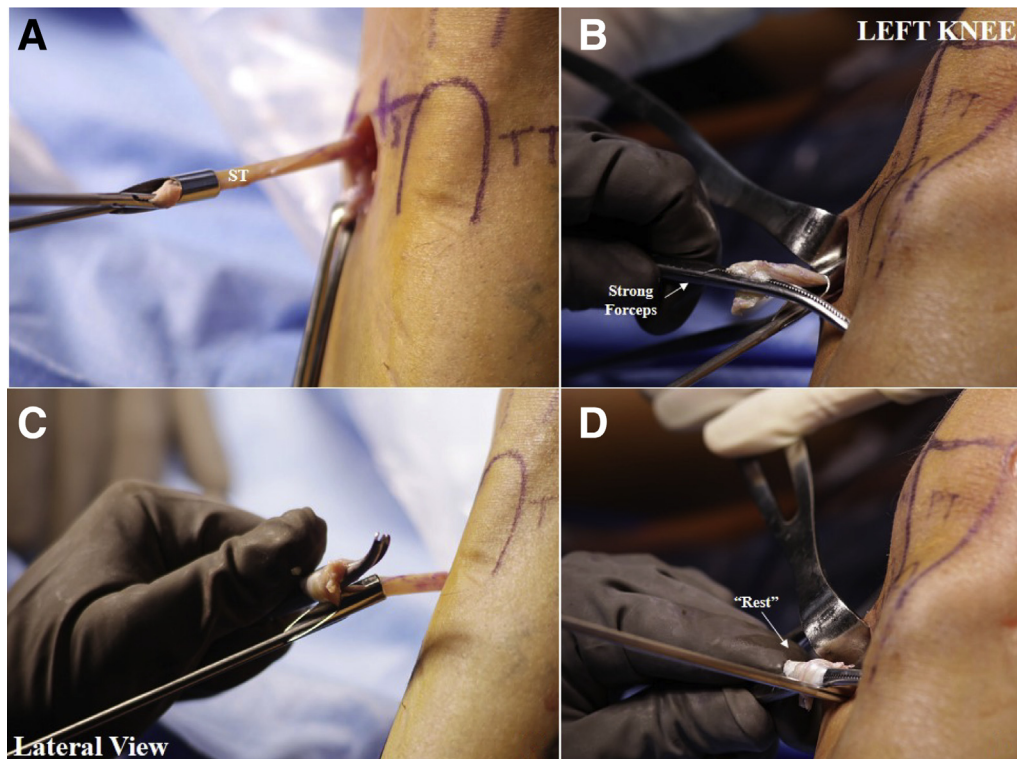
Once the procedure is concluded, a cross suture with No. 1-0 Vicryl (Ethicon) is placed at the apex of the SF approaching toward the TT with the Allis forceps;

finally, a simple suture is placed in the middle third of the horizontal incision and another simple suture is placed in the middle third of the vertical incision of the SF. This allows an anatomic closure and adequate coverage of the tibial tunnel fixation implants. The subcutaneous cellular tissue is closed with 2 to 3 inverted sutures with No. 3-0 Vicryl, and finally, the skin is closed with vertical mattress or subcuticular suture technique with No. 3-0 Monocryl (Ethicon). The wounds are covered with gauze and a simple bandage. The procedure may be performed in some cases without ischemia; however, this is the surgeon's preference.

### Discussion

Lack of knowledge of the anatomy of the insertion of the hamstring tendons may lead to technical problems during harvesting, such as injury to the saphenous nerve and technical difficulty in harvesting because the incision was made in an inappropriate location.<sup>8,11,12</sup> It is very common for the hamstring tendons to be lost, with a consequent need to harvest another graft from a second donor site.<sup>1,12</sup>

There is a shortage of articles in the literature relating to basic applied anatomy specifications of the ST-G tendons focused on correct harvesting. Incision placement at the correct location is the first step toward success in this



**Fig 11.** Semitendinosus (ST) tendon harvesting. (A) An arthroscopic forceps is inserted into the closed tendon stripper. (B) The tendon is held with the tip of the forceps and then exchanged with a strong forceps. (C) The tendon is rolled up. (D) The knuckles of the surgeon should rest on the patient's knee.



procedure. One common mistake is to make the incision too proximally, which creates difficulty in finding the hamstring tendons. In such cases, greater wounding of soft tissues is necessary to harvest the tendon.

Arthroscopically assisted ACL reconstruction using medial hamstring tendons is not free of complications such as disinsertion of the pes anserinus, amputation of the graft, and injury to the IPBSN.<sup>13</sup> Vertical, horizontal, and even oblique incision methods have been proposed for medial hamstring tendon harvesting, at an approximate distance of 2.5 to 4 cm from the tibial tuberosity.

Risks and limitations are always present when it comes to surgical techniques, and our technique is no exception. One of the most important things to consider is that there will always exist the risk of a mistake, such as injury to other structures. The intention with our technique is to show, as we mentioned previously, a reduction in the rate of errors. Of course, as in any technique, there is always the limitation of the surgeon's individual skills, but we trust that in the case of our technique, the learning curve could be faster.

The described procedure provides direct access to the hamstring tendons with easily palpable anatomic landmarks without large incisions from the tibial tuberosity. The fascia remains intact in a repairable condition and therefore is attached back to its insertion site. This reattachment can play an important role in post-operative wound healing and in the early rehabilitation period. Furthermore, the procedure leaves a good cosmetic result after surgery with a minimal scar, in addition to little donor-site morbidity.

### Acknowledgment

The authors express their gratitude to Francisco Suárez-Bravo (photography); Ivonne Trigueros-Anaya, Gloria Gonzalez-Vellano, Leticia Balderas-Lopez, Ana Maria Godinez-Monroy, Catalina Cano-Alvarado, and Carmen González-Vellano (arthroscopy surgical nursing team); and Renata Diez-González (audio) for their assistance in preparing and conducting this study.

### References

1. Mahajan PS, Chandra P, Negi VC, Jayaram AP, Husein SA. Smaller anterior cruciate ligament diameter is a predictor of subjects prone to ligament injuries: An ultrasound study. *Biomed Res Int* 2015;2015:845689.
2. Henry BM, Tomaszewski KA, Pe PA, Ewa S. Oblique incisions in hamstring tendon harvesting reduce iatrogenic injuries to the infrapatellar branch of the saphenous nerve. *Knee Surg Sports Traumatol Arthrosc* 2018;26:1197-1203.
3. Yucens M, Aydemir AN. Trends in anterior cruciate ligament reconstruction in the last decade: A web-based analysis. *J Knee Surg* 2019;32:519-524.
4. Mahapatra P, Horriat S, Anand BS. Anterior cruciate ligament repair—Past, present and future. *J Exp Orthop* 2018;5:20.
5. Papastergiou SG, Voulgaropoulos H, Mikalef P, et al. Injuries to the infrapatellar branch(es) of the saphenous nerve in anterior cruciate ligament reconstruction with four stand hamstring tendon autograft: Vertical versus horizontal incision for harvest. *Knee Surg Sports Traumatol Arthrosc* 2006;14:789-793.
6. Goldblatt JP, Fitzsimmons SE, Balk E, Richmond JC. Reconstruction of the anterior cruciate ligament: Meta-analysis of patellar tendon versus hamstring tendon autograft. *Arthroscopy* 2005;21:791-803.
7. Tuncay I, Kucuker H, Uzun I, Karalezli N. The fascial band from semitendinosus to gastrocnemius: The critical point of hamstring harvesting: An anatomical study of 23 cadavers. *Acta Orthop* 2007;78:361-363.
8. Tapasvi SR, Shekhar A, Patil SS. Primary anterior cruciate ligament repair with augmentation. *Arthrosc Tech* 2018;7:e139-e145.
9. Śmigielski R, Zdanowicz U, Drwięga M, Cizek B, Williams A. The anatomy of the anterior cruciate ligament and its relevance to the technique of reconstruction. *Bone Joint J* 2016;98-B:1020-1026.
10. Sgaglione NA, Warren RF, Wickiewicz TL, Gold DA, Panariello RA. Primary repair with semitendinosus tendon augmentation of acute anterior cruciate ligament injuries. *Am J Sports Med* 1990;18:64-73.
11. Ackmann T, Von Düring M, Teske W, Ackermann O, Müller P, Von Schulze Pellengahr C. Anatomy of the infrapatellar branch in relation to skin incisions and as the basis to treat neuropathic pain by percutaneous cryodenervation. *Pain Physician* 2014;17:E339-E348.
12. Frank RM, Hamamoto JT, Bernardoni E, et al. ACL reconstruction basics: Quadruple (4-strand) hamstring autograft harvest. *Arthrosc Tech* 2017;6:e1309-e1313.
13. Kodkani PS, Govekar DP, Patankar HS. A new technique of graft harvest for anterior cruciate ligament reconstruction with quadruple semitendinosus tendon autograft. *Arthroscopy* 2004;20:e101-e104.