

# Acquired Optic Pits Associated with Laser-assisted *In Situ* Keratomileusis: A Case Series

Andrew K Smith<sup>1</sup>, Igor Bussel<sup>2</sup>, John Ling<sup>3</sup>, Sameh Mosaed<sup>4</sup>

## ABSTRACT

**Purpose:** To present an association between acquired pits of the optic nerve (APON) and prior laser-assisted *in situ* keratomileusis (LASIK).

**Materials and methods:** A retrospective case series of patients with an optic disk pit on clinical exam and a history of LASIK. Spectralis Optical Coherence Tomography images and Humphrey Visual Fields were reviewed from prior visits. Extended-depth optical coherence tomography was performed of the optic nerve head at subsequent visits after patients were identified.

**Results:** Seven patients, aged 45–73 years, were identified each with unilateral optic disk pits. Optic disk pits were located inferior in six patients and centrally in one patient. All demonstrated thinning on optical coherence tomography and six patients had corresponding visual field defects. Four patients identified these defects after their LASIK procedure while two patients were unaware of their reproducible visual field defects. All patients were treated with drops initially. One patient underwent laser trabeculoplasty, and three underwent a trabeculectomy after demonstrating progression on maximum tolerated medical therapy.

**Conclusion:** This series describes a possible association between LASIK and APON. Given the similarity and severity of vision loss associated with the optic nerve pits in these patients after LASIK, increased awareness and caution is suggested while considering LASIK in susceptible individuals.

**Keywords:** Glaucoma, Laser assisted *in situ* keratomileusis, Optic nerve pit.

*Journal of Current Glaucoma Practice* (2020); 10.5005/jp-journals-10078-1284

## INTRODUCTION

Acquired pits of the optic nerve (APON) are focal excavations of the neuro-retinal rim with localized breaks or disinsertion of the lamina cribrosa and depression of the prelaminar tissue.<sup>1</sup> These acquired optic nerve pits typically lead to corresponding and significant retinal nerve fiber layer (RNFL) thinning with conforming paracentral visual field defects.<sup>2–4</sup> Additionally, eyes with APON have been shown to progress faster in relation to both visual field defects and RNFL thinning compared to other glaucomatous eyes.<sup>5,6</sup> While APON is more commonly associated with low tension glaucoma and female gender, susceptibility and other possible triggering events have not been well elucidated.

Large intraocular pressure (IOP) shifts can cause the lamina cribrosa to deform, typically resulting in a posterior shift in the position.<sup>7,8</sup> The higher and more rapid the IOP shift, the greater the displacement of lamina tissue. This displacement is greatest at the peripheral optic nerve head and exerts significant shearing forces distributed to the peripheral lamina cribrosa. Additionally, high myopia and connective tissue disorders have been noted to result in larger lamina and prelaminar displacement than the normal population under increased IOP.<sup>9</sup>

During flap creation in laser-assisted *in situ* keratomileusis (LASIK), IOP ranges from 80 to 120 mm Hg, typically lasting less than a minute.<sup>10,11</sup> However, pressures have been recorded as high as 300 mm Hg in association with improper positioning and docking. This combination of high myopia plus very high pressures during the LASIK flap creation may increase the risk of APON with progressive visual field loss in susceptible individuals.<sup>9,12</sup>

In this case series, we discuss seven patients with optic nerve pits and progressive visual field loss despite controlled IOP following LASIK.

---

<sup>1–4</sup>Department of Ophthalmology, University of California, Gavin Herbert Eye Institute, Irvine, California, USA; University of California, Irvine School of Medicine, Irvine, California, USA

**Corresponding Author:** Andrew K. Smith, Department of Ophthalmology, University of California, Gavin Herbert Eye Institute, Irvine, California, USA; University of California, Irvine School of Medicine, Irvine, California, USA, Phone: +91 9494331588, e-mail: andrewks@uci.edu

**How to cite this article:** Smith AK, Bussel I, Ling J, *et al.* Acquired Optic Pits Associated with Laser-assisted *In Situ* Keratomileusis: A Case Series. *J Curr Glaucoma Pract* 2020;14(3):106–108.

**Source of support:** Nil

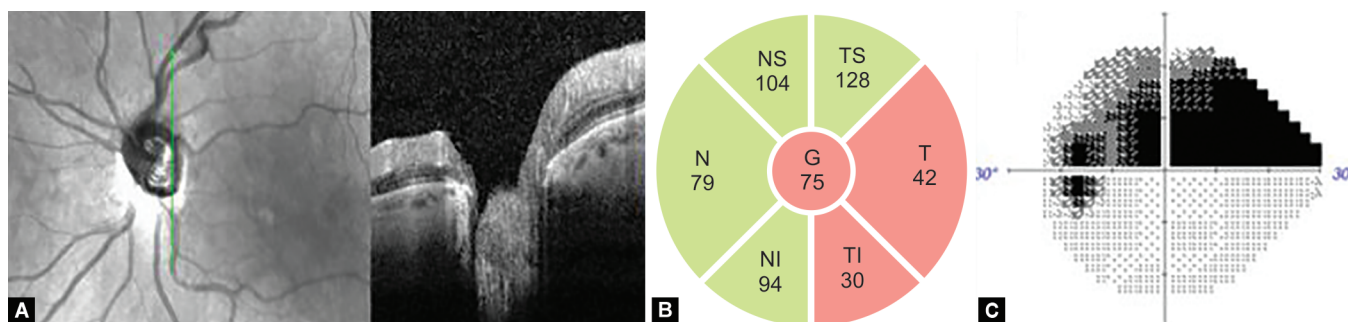
**Conflict of interest:** None

---

## MATERIALS AND METHODS

This study was a retrospective chart review of patients of a tertiary academic glaucoma specialist (S.M). These patients were identified by doing a search query of patients that presented for follow-up between March 1, 2018, and March 1, 2019, with a diagnosis of optic nerve pit and a history of LASIK. The study was approved by the Institutional Review Board at the University of California, Irvine. Clinical history, exam, and structural imaging (Spectralis Optical Coherence Tomography; Heidelberg Engineering), as well as functional testing (Humphrey Visual Field; Zeiss), were reviewed. After identification of patients, extended-depth optical coherence tomography (ED-OCT; Spectralis, Heidelberg Engineering) of the optic nerve head was performed.

This study was approved by the University of California Irvine Office of Research Institutional Research Board and adhered to the



**Figs 1A to C:** (A) Left eye inferior optic nerve pit with (B) corresponding retinal nerve fiber layer thinning and (C) superior visual field defect

tenets of the Declaration of Helsinki. As this was a retrospective study, the need for informed consent was waived.

## RESULTS

Seven eyes (three OD and four OS) from seven patients were identified who met inclusion criteria. Five of seven patients had >3 years of follow-up. The average age was 57 years old (range 45–73). Only three patients had a family history of glaucoma. The average pachymetry was 492  $\mu\text{m}$  (range 404–612). All patients had open and unremarkable gonioscopy exams. All optic disk pits were unilateral, six of which were located inferiorly and the other centrally. Retinal nerve fiber layer thinning on OCT was noted in all seven patients with corresponding visual field defects in six patients while the last patient remained preperimetric. Extended-depth optical coherence tomography was obtained and demonstrated laminar breaks at the location of the optic disk pit seen on the clinical exam (Fig. 1). Four patients subjectively identified these visual field defects after LASIK while the other two patients were unaware of the reproducible visual field defects noted on exam following LASIK.

An ED-OCT image demonstrates a break in the lamina cribrosa inferiorly (A). Corresponding temporal and inferotemporal retina nerve fiber layer thinning (B) and a superior hemifield defect (C) were detected.

The patients had an average IOP of 17 mm Hg (range 12–33 mm Hg) and appropriate topical medical treatment was initiated and escalated as needed to control glaucomatous progression. Despite maximal medical therapy, visual field progression continued in four patients who later required surgical intervention. One patient subsequently underwent selective laser trabeculoplasty and three patients underwent trabeculectomy. In the study cohort, three patients demonstrated visual field progression in accordance with the location of their optic disk pit despite good IOP control.

## DISCUSSION

To our knowledge, this is the first case series suggesting an association between LASIK and APON. This association is significant as RNFL thinning and visual field defect progression are more likely in patients with APON.<sup>2</sup> Compared to their counterparts without optic disk pits, patients with an APON are two to three times more likely to have a progression of glaucomatous visual field defects.<sup>6</sup> This progression can proceed despite aggressive IOP control.

In addition, eyes that have undergone LASIK, likely have unique ocular anatomical differences that may risk further glaucoma progression. First, those with high myopia, who are more likely to seek LASIK vision correction, have greater laminar deformation during the procedure and may be at higher risk for the development

or progression on APON.<sup>9</sup> Second, eyes that have undergone LASIK develop decreased corneal hysteresis which may increase the risk of glaucoma under-diagnosis and under-treatment.<sup>13</sup> Lastly, thinner pachymetry measurements secondary to the LASIK procedure require even lower IOP targets.

Management of glaucomatous progression in patients with these risk-factors is particularly challenging. If trabeculectomy becomes indicated, these patients are often at increased risk for complications related to hypotony.<sup>14,15</sup> Additionally, OCT interpretation with pathological myopia is more challenging and confounding by the anatomic abnormalities associated with high myopia.

Consideration of optic nerve pit development and increased awareness is needed given the similarity and severity of vision loss associated with the optic nerve pits in the six patients presented here. It has been proposed that APON may signal an abnormal susceptibility of the optic nerve to the damaging effects of IOP.<sup>16</sup> The creation of a new APON or the expediting of pending visual field defects from an existing APON may be incurred by subjecting patients to transient yet significant elevations in IOP during the LASIK procedure. Furthermore, improper docking can result in even higher elevations of IOP and for longer periods than is planned, putting some patients at greater risk.<sup>9</sup> Beyond the direct effect of the IOP increase during LASIK flap creation, the thinning of the cornea after ablation may also play a role.<sup>17</sup> Decreased corneal hysteresis can alter IOP readings and may also permit more fluctuation in IOP with blinking, eye rubbing, and any other mechanical manipulation of the eye. Additionally, optic nerve pits are common in highly myopic eyes and can be difficult to identify on ophthalmoscopy, but can be visualized with OCT.<sup>9</sup> Therefore, caution should be taken when performing LASIK in patients with a history of high myopia, glaucoma, or a strong family history of glaucoma. Extended-depth optical coherence tomography should be considered to identify preexisting APON in patients with high myopia or other factors before LASIK.

## REFERENCES

- Choi YJ, Lee EJ, Kim BH, et al. Microstructure of the optic disc pit in open-angle glaucoma. *Ophthalmology* 2014;121(11):2098–2106.e2. DOI: 10.1016/j.ophtha.2014.06.005.
- Lee SH, Lee EJ, Kim TW. Structural characteristics of the acquired optic disc pit and the rate of progressive retinal nerve fiber layer thinning in primary open-angle glaucoma. *JAMA Ophthalmol* 2015;133(10):1151–1158. DOI: 10.1001/jamaophthalmol.2015.2453.
- Moghimi S, Zangwill LM, Manalastas PIC, et al. Association between lamina cribrosa defects and progressive retinal nerve fiber layer loss in glaucoma. *JAMA Ophthalmol* 2019;137(4):425–433. DOI: 10.1001/jamaophthalmol.2018.6941.

4. Nduaguba C, Ugurlu S, Caprioli J. Acquired pits of the optic nerve in glaucoma: prevalence and associated visual field loss. *Acta Ophthalmol Scand* 1998;76(3):273–277. DOI: 10.1034/j.1600-0420.1998.760304.x.
5. You JY, Park SC, Su D, et al. Focal lamina cribrosa defects associated with glaucomatous rim thinning and acquired pits. *JAMA Ophthalmol* 2013;131(3):314–320. DOI: 10.1001/jamaophthalmol.2013.1926.
6. Faridi OS, Park SC, Kabadi R, et al. Effect of focal lamina cribrosa defect on glaucomatous visual field progression. *Ophthalmology* 2014;121(8):1524–1530. DOI: 10.1016/j.ophtha.2014.02.017.
7. Fazio MA, Johnstone JK, Smith B, et al. Displacement of the lamina cribrosa in response to acute intraocular pressure elevation in normal individuals of African and European descent. *Invest Ophthalmol Vis Sci* 2016;57(7):3331–3339. DOI: 10.1167/iovs.15-17940.
8. Yan DB, Coloma FM, Metheetrairut A, et al. Deformation of the lamina cribrosa by elevated intraocular pressure. *Br J Ophthalmol* 1994;78(8):643–648. DOI: 10.1136/bjo.78.8.643.
9. Ohno-Matsui K, Akiba M, Moriyama M, et al. Acquired optic nerve and peripapillary pits in pathologic myopia. *Ophthalmology* 2012;119(8):1685–1692. DOI: 10.1016/j.ophtha.2012.01.047.
10. Quigley H, Arora K, Idrees S, et al. Biomechanical responses of lamina cribrosa to intraocular pressure change assessed by optical coherence tomography in glaucoma eyes. *Invest Ophthalmol Vis Sci* 2017;58(5):2566–2577. DOI: 10.1167/iovs.16-21321.
11. Vetter JM, Schirra A, Garcia-Bardon D, et al. Comparison of intraocular pressure during corneal flap preparation between a femtosecond laser and a mechanical microkeratome in porcine eyes. *Cornea* 2011;30(10):1150–1154. DOI: 10.1097/ICO.0b013e318212110a.
12. Zhao H, Ai Y, Niu C, et al. Research on influences of transient high IOP during LASIK on retinal functions and ultrastructure. *J Ophthalmol* 2009;2009:230528. DOI: 10.1155/2009/230528.
13. Hwang ES, Stagg BC, Swan R, et al. Corneal biomechanical properties after laser-assisted in situ keratomileusis and photorefractive keratectomy. *Clin Ophthalmol* 2017;11:1785–1789. DOI: 10.2147/OPHT.5142821.
14. Seah SK, Prata Jr JA, Minckler DS, et al. Hypotony following trabeculectomy. *J Glaucoma* 1995;4(2):73–79. DOI: 10.1097/00061198-199504000-00002.
15. Fannin LA, Schiffman JC, Budenz DL. Risk factors for hypotony maculopathy. *Ophthalmology* 2003;110(6):1185–1191. DOI: 10.1016/S0161-6420(03)00227-6.
16. Javitt JC, Spaeth GL, Katz LJ, et al. Acquired pits of the optic nerve. Increased prevalence in patients with low-tension glaucoma. *Ophthalmology* 1990;97(8):1038–1043. DOI: 10.1016/S0161-6420(90)32466-1discussion 1043-4.
17. Kozobolis V, Konstantinidis A, Sideroudi H, et al. The effect of corneal refractive surgery on glaucoma. *J Ophthalmol* 2017;2017:8914623. DOI: 10.1155/2017/8914623.