

CASE REPORT



## Maggot debridement therapy for a patient with critical limb ischaemia and severe cardiac dysfunction: possibility of limb salvage

Akio Nishijima<sup>a</sup>, Naoto Yamamoto<sup>a</sup>, Ryuichi Yoshida<sup>a</sup>, Koji Hozawa<sup>b</sup>, Satoshi Yanagibayashi<sup>a</sup>, Megumi Takikawa<sup>a</sup>, Rie Hayasaka<sup>a</sup>, Junko Nishijima<sup>a</sup>, Tadasu Okada<sup>c</sup> and Mitsuru Sekido<sup>d</sup>

<sup>a</sup>Department of Plastic and Reconstructive Surgery, New Tokyo Hospital, Matsudo, Chiba, Japan; <sup>b</sup>Department of Cardiovascular Medicine, New Tokyo Hospital, Matsudo, Chiba, Japan; <sup>c</sup>Department of Dermatology, Mami Dermatology Clinic, Koshiba, Nara, Japan; <sup>d</sup>Department of Plastic and Reconstructive Surgery, University of Tsukuba, Tsukuba, Ibaraki, Japan

### ABSTRACT

Ischaemic skin ulcer occurred on the foot of a 73-year-old man who had a history of fulminant myocarditis with severe cardiac dysfunction. We attempted wound bed preparation by maggot debridement therapy and salvaged his limb. It can be one of the adjuvant treatment strategies for critical limb ischaemia.

### ARTICLE HISTORY

Received 6 February 2017  
Accepted 2 May 2017

### KEYWORDS

Critical limb ischemia; cardiac dysfunction; fulminant myocarditis; maggot debridement therapy; wound bed preparation

### Introduction

Maggot therapy is categorised as a debridement for chronic infectious wounds using disinfected live maggots for medical use (herein referred to as maggots). Since the 1930s, maggot debridement therapy (MDT) has been conducted mainly in North America [1]. In Japan, Mitsui et al. first conducted MDT in 2004 and reported the healing of an ulcerated lesion, leading to the avoidance of major amputation of a limb of a patient with severe CLI for whom neither a revascularization procedure nor a transplantation of bone marrow and peripheral mononuclear cells to the lower limb was effective [2].

Wound healing is intractable in most CLI patients who have reduced blood flow in the skin; therefore, revascularization is the most important factor for successful management [3]. In addition, the debridement of wounds with no sufficient tissue blood flow may deteriorate ischaemic lesions. Therefore, MDT has been relatively contraindicated for ischaemic limbs [4,5].

Treatment decisions are often difficult for CLI patients with a reduced cardiac function and surgical intervention or endovascular surgery for revascularization is risky, or not clinically and technically possible [6].

Herein, we report a CLI patient with severe cardiac dysfunction for whom highly invasive surgery, such as bypass surgery, was impossible due to a history of fulminant myocarditis, but functional limb salvage was achieved after wound bed preparation (WBP) with MDT.

### Case report

A 73-year-old man consulted our institution for a skin ulcer of the left third toe in September 2014. He had a clinical history of fulminant myocarditis, myocardial infarction, acute cardiac failure, chronic renal failure (undergoing dialysis), arteriosclerosis obliterans of the lower limb, hypertension, diabetes and visual disturbance. He was a non-smoker, living by himself, and he could walk with support.

His notable illness was an episode of fulminant myocarditis and acute cardiac failure in December 2011, which was treated in the ICU for 15 days, and he was discharged from hospital 3 months later. At the time of discharge, he still had significant cardiac functional disorder with an ejection fraction (EF) rate of less than 20%.

**CONTACT** Akio Nishijima ✉ [handbal1016@yahoo.co.jp](mailto:handbal1016@yahoo.co.jp) 📍 Department of Plastic and Reconstructive Surgery, New Tokyo Hospital, 1271 Wanagaya, Matsudo, Chiba 270-2232, Japan

© 2017 The Author(s). Published by Informa UK Limited, trading as Taylor & Francis Group.

This is an Open Access article distributed under the terms of the Creative Commons Attribution-NonCommercial License (<http://creativecommons.org/licenses/by-nc/4.0/>), which permits unrestricted non-commercial use, distribution, and reproduction in any medium, provided the original work is properly cited.

In April 2014, he developed ulceration of the right toes, diagnosed as arteriosclerosis obliterans of the lower limb at the cardiovascular medicine department and underwent percutaneous transluminal angioplasty (PTA). In September 2014, delayed healing of the ulceration of the skin was noted; thus, he was referred to the plastic surgery department.

Upon the first consultation at the plastic surgery department, ischaemic ulcer of the left third toe was seen and his EF rate was 18.4%. Table 1 shows his biologic and haematologic data, detected bacteria and treatment course. Biological data on the left limb were examined between the revascularization procedure and surgical management, and blood test and wound culture were examined at the time of surgical management. Revascularization procedure by PTA was not conducted after October 2016.

In September 2014, after performing PTA for the left lower limb, amputation of the left third toe was conducted. In December 2014, re-stenosis of the bilateral below-knee arteries and necrosis of the left first toe were noted, thus re-PTA was conducted for the bilateral limbs. Subsequently, amputation of the left first toe was performed. In September 2015, arterial re-stenosis of the lower extremity developed along with necrosis of all the left toes, plantar and dorsum, and so PTA was performed again; transmetatarsal amputation (TMA) was also performed in the same month. However, delayed wound healing, infection and necrosis progressed in the transected surface of the left limb. Therefore, in January 2016, the first and second toes were amputated at Lisfranc's joint, and the other three toes were further amputated at the base of the transmetatarsal bone, and the amputated surface was left as an open wound for WBP and post-operative infection management. At the time of the amputation, extensive arterial contraction and severe arteriosclerosis were noted in the left lower limb; thus, an additional revascularization procedure by PTA could not be performed. Subsequently, cleansing of the wound, topical ointment of sulfadiazine silver, venous drip infusion of an antibiotic agent (daptomycin), and surgical debridement at the bedside were conducted daily, but the yellowish necrosis lesion did not reduce, and his pain aggravated (Figure 1(a)).

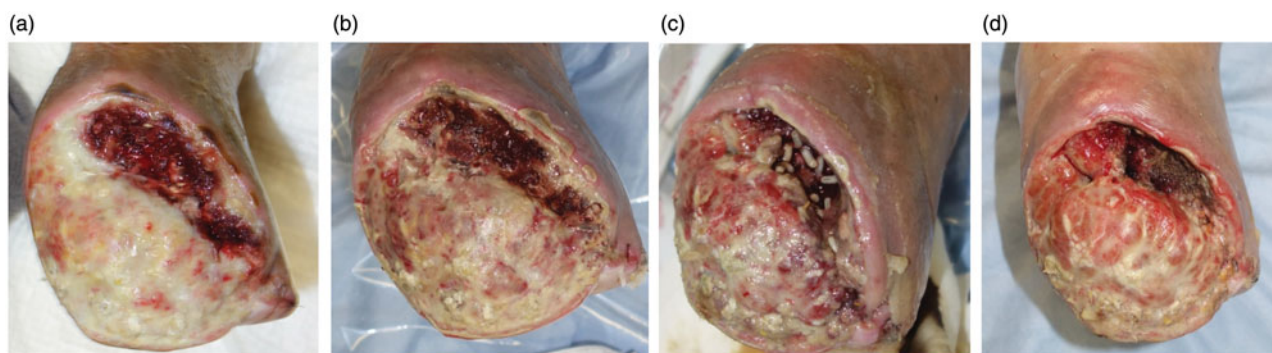
The patient strongly desired to save his limb and refused to undergo major amputation of the limb. Debridement at the bedside was difficult due to pain at that time. Surgical management under general anaesthesia (such as bypass surgery) or extensive and highly invasive debridement for a long time was also considered unacceptable, because the patient fulfilled three items of the Revised Cardiac Risk Index (history

Table 1. Time-course treatment outcome of the left lower limb and laboratory data.

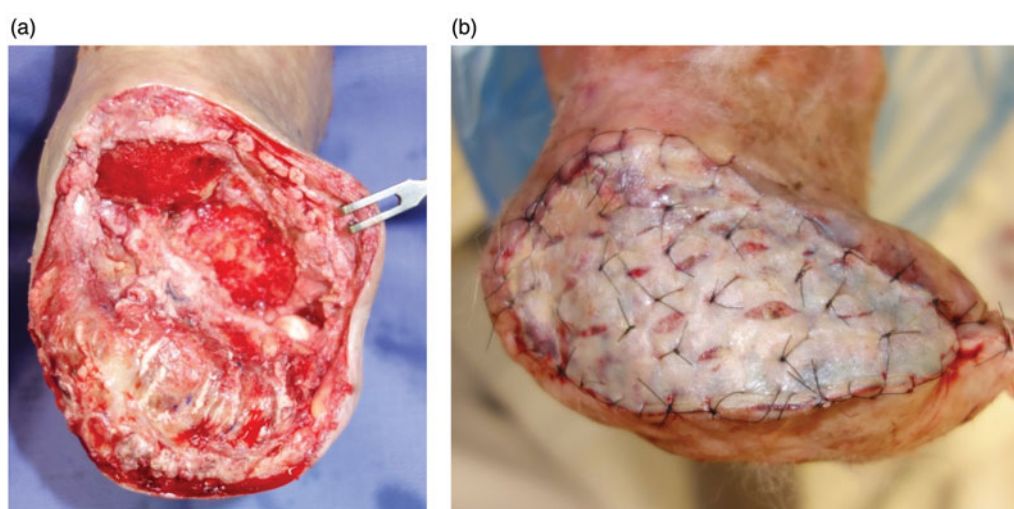
Time	September 2014	December 2014	September 2015	January 2016	February 2016	March 2016	September 2016
Area of necrosis	Third toe	First toe	All toes, plantar, dorsum of foot	All of cut surface	All of cut surface	Plantar of cut surface	Marginal ulcer
PTA	+	+	+	-	-	-	-
Surgical treatment	Toe amputation	Toe amputation	Transmetatarsal amputation AJB, Sedation	Lisfranc's joint amputation SNB, Sedation	Maggot therapy	Skin graft	-
Analgesia method	AJB	AJB	AJB, Sedation	SNB, Sedation	NSAIDs	SNB, Sedation	-
Ankle brachial index	1.09	1.18	1.1	1.16	1.3	1.3	1.14
Skin perfusion pressure (mmHg)							
dorsum	62	37	51	15	-	16	9
plantar	53	40	38	58	-	55	Unmeasurable
Albumin (mg/dL)	3.2	3.6	3.1	3.2	3	2.6	2.8
Total cholesterol (mg/dL)	185	101	133	97	97	86	-
WBC	3960	6240	4550	4080	4430	5400	3770
CRP (mg/dL)	0.18	3.37	2	0.57	1.33	8.4	1.78
HbA1c (%)	6.1	5.9	6.5	5.9	6.1	6.2	-
B-type natriuretic peptide (pg/mL)	3,590	2675	5820	2301	-	2250	-
Detected bacteria by wound culture	MRSA	MRSA	MRSA	Not detected	Not detected	<i>Morganella morganii</i> <i>S. maltophilia</i>	MRSA <i>Alcaligenes faecalis</i>
	<i>Acinetobacter iwoffii</i> <i>Serratia marcescens</i> <i>Bacteroides fragilis</i>						

AJB: ankle joint nerve block; CRP: C-reactive protein; MRSA: methicillin-resistant *Staphylococcus aureus*; PTA: percutaneous transluminal angioplasty; SNB: sciatic nerve block; *S. maltophilia*: *Stenotrophomonas maltophilia*.

Note: The data were obtained after PTA and before surgical intervention. Endovascular surgery was not conducted after October 2016.



**Figure 1.** Treatment course of maggot therapy. (a) Before maggot therapy. Necrotic tissue is seen on the surface of the wound. (b) After one session (48 h) of treatment, the reduction of necrotic tissues is seen. (c) Maggots growing from second to third instar larvae. (d) After six sessions of treatment, debridement was conducted to the deep portion from the ulcerated base, and favourable granulation can be seen on the amputated surface.



**Figure 2.** Intra-/post-operative view. (a) Intra-operative. Additional debridement is done. (b) Three post-operative weeks. Approximately 70% of the skin graft was taken. After conducting partial simple reefing, split thickness skin graft of 20/1000 inches was used.

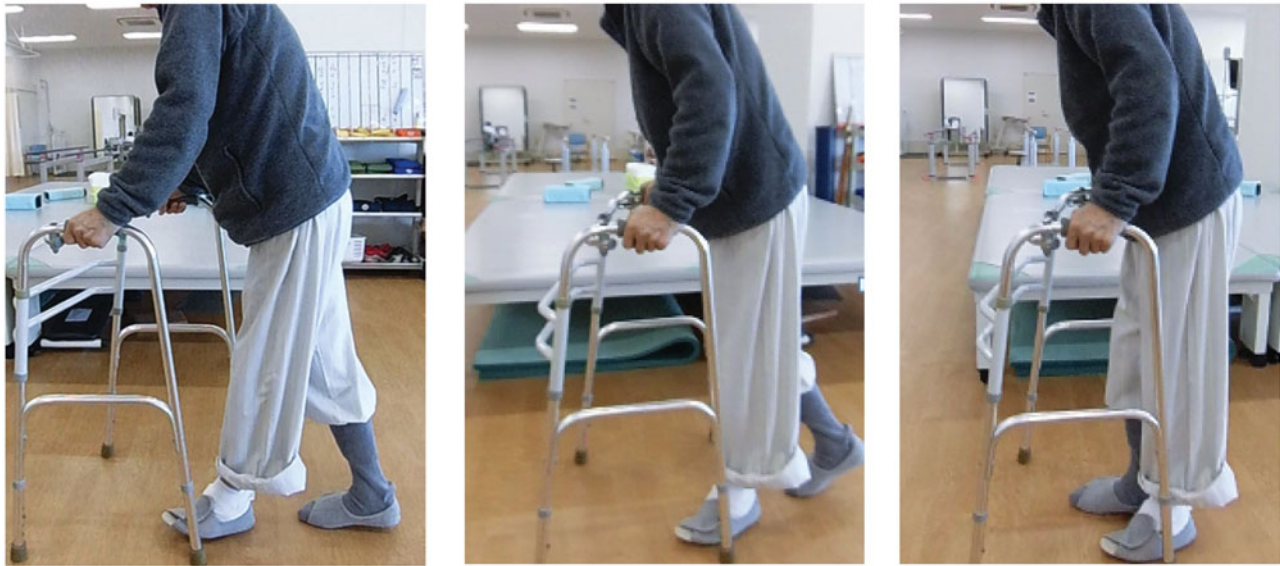of cardiac failure, insulin-dependent diabetes and renal failure), had EF of 18.4% and had a constantly high level of B-type natriuretic peptide (over 2000 pg/mL). As conventional treatment methods were considered difficult for the patient to tolerate, MDT was started from February 2016. The Barthel Index [7] before MDT was a score of 45.

Second instar larvae of maggots were placed on the surface of the skin ulcer at six larvae per 1 cm<sup>2</sup>, covered by a mesh sheet and dressing was performed. The maggots were removed when they grew to third instar larvae and were replaced by second instar larvae. By defining a 48-h duration as one session, a total of six sessions were conducted. For pain control, the oral administration of NSAIDs was performed and he could tolerate the pain, although it remained to a certain extent. Subsequently, compared with the conventional treatment, the reduction of necrotic tissues at

the ulceration site was noted each time the maggots were replaced, and favourable granulation was observed. MDT was particularly effective in the portion where the margin between the granulation and necrosis was unclear, and the deep portion of the ulceration where manual debridement was difficult (Figure 1(b–d)). Wound closure was achieved in March 2016.

Intraoperative and post-operative views are shown in Figure 2(a,b). Under sciatic nerve block, additional debridement and partial simple reefing suture were done, and skin graft with a split thickness of 20/1000 inches was conducted, harvesting the graft from his left inguinal region. The operation took 1 h and 40 min, and the amount of bleeding was 140 mL.

Post-operatively, about 70% of the grafted skin was taken, although it was unstable for 2 weeks, and his pre-operative pain markedly reduced. Although some raw surface remained, the range was relatively small,



**Figure 3.** Treatment outcome at one post-operative months. The Barthel Index improved from a score of 45 to 80, and the patient started to walk using a four-point walker.

and additional surgical management was unnecessary. After rehabilitation exercise, as of one post-operative months, he became able to stand with assistance when moving from a wheelchair, walk using a four-point walker, and his Barthel Index improved to a score of 80 (Figure 3(b)).

## Discussion

In patients with CLI, debridement may deteriorate necrosis by inducing ischaemia of normal tissues. Therefore, blood flow evaluation and the revascularization procedure are important before conducting debridement. However, clinically or technically, up to (maximum) 14% of CLI patients are unable to undergo surgical management or endovascular surgery for angioplasty [6]. Also, Soga et al. reported a vascular restenosis rate of 86.0% and re-occlusion rate of 52.8% in CLI patients who underwent endovascular management [8]. In our patient, although the preoperative Ankle Brachial Index and skin perfusion pressure were relatively maintained, arterial restenosis of the lower extremity was seen before healing, and PTA was conducted three times. In addition, vascular reconstruction by additional PTA was difficult after October 2016.

Some CLI patients are unable to undergo highly invasive surgery because of a reduced cardiac function. Shiraki et al. reported that 15.6% of their CLI patients had an EF rate of less than 50% and 41.1% had coronary artery disease (CAD) [9]. In addition, a mortality rate of less than 25% has been reported within a year for CLI patients [10]. Physiologic classification of the American Society of Anesthesiologists

(ASA) reports perioperative mortality rate of class-III patients (angina, old myocardial infarction, and insulin-dependent diabetes) and class-IV patients (unstable angina) of 1.8% and 7.8%, respectively [11]. The Revised Cardiac Risk Index, which is commonly used to predict cardiovascular events during a perioperative period, defines six risk factors: ischaemic cardiac disease, history of cardiac failure, cerebrovascular disease, insulin-dependent diabetes, renal failure and high-risk surgical management [12]. If a patient has three or more of these risk factors, when conducting non-cardiac surgery, the average cardiovascular complication rate is reported to be 9.1% and mortality due to cardiovascular disease is 3.6% [12,13]. Our patient had three of these risk factors, suggesting a high risk during the perioperative period.

Adjuvant therapies for ischaemic ulcer, other than MDT, include hyperbaric oxygen therapy [14], cell therapy [15], gene therapy (intravascular growth factor) [16] and LDL apheresis [17]. However, these therapies require special equipment and qualification as a specialist; thus, they are difficult to perform flexibly depending on the needs of a particular situation. On the other hand, MDT can be conducted less problematically in ordinary hospitals or outpatient clinics, although it is categorised as a private practice in Japan and thus not covered by the Japanese national health insurance system [18].

Four debridement methods are considered for the selective removal of necrotic tissues: (1) surgical debridement, (2) enzymatic debridement, (3) autolytic debridement and (4) biological debridement. Surgical debridement removes necrotic tissues with scissors or

a scalpel, which entails bleeding and pain of patients, as well as damage to peripheral intact tissues to some extent. Enzymatic debridement uses chemical agents for liquefaction of necrotic tissues and is also called chemical debridement. This can be done without anaesthesia and is relatively simple to perform with little risk of bleeding; however, it is a time-consuming procedure and thus not suitable for situations requiring more immediate results. Autolytic debridement involves the application of wound dressing materials such as ointments or hydrocolloid materials, making it suitable for wounds that locate near the body surface or autonomic healing power of the wound is maintained.

There are three major benefits of WBP by MDT for CLI patients [19–21]. First, selective and efficient debridement can be performed. Even for wounds with unclear margins with the surrounding normal tissues, maggots selectively englobe and liquefy only necrotic tissues [22]. In addition, as maggots naturally favour darker environments (negative phototaxis), maggots reach to the deep portions of a wound where surgical debridement is difficult. Pain associated with MDT can be controlled with oral analgesics or by controlling the number of applied maggots, making local or surface anaesthesia unnecessary [23]. Further, the technique for MDT is relatively straightforward and easily learned, so a certain efficacy can be obtained irrespective of the proficiency of each surgeon. Even for patients of advanced age, with dementia, or unfavourable systemic conditions, for whom surgical debridement is problematic, MDT can be utilised.

A second benefit is the antibacterial action associated with MDT. Maggots have a sterilising effect both *in vivo* and *in vitro*. In the body, maggots eliminate bacteria through a digesting process in their foregut, midgut and hindgut [24]. In an extracorporeal (*in vitro*) study, antibacterial peptide contained in maggots' secretion was shown to be effective against Gram-positive bacterium, including *Methicillin-resistant Staphylococcus aureus* (MRSA) [25]. Thus, MDT is considered suitable for CLI patients who likely face the presence of multiple drug-resistant bacteria at high incidence, because of relative immune deficiency and long-term hospitalisation. Harmful bacteria including MRSA were not detected in wound cultures of our patient in the months of January and February 2016, while MDT was being conducted, suggesting effective antibacterial action of the maggots' secretions.

A third benefit is a promotion of granulation formation with MDT. Maggot secretions promote the cellular processes, which is related to increased healing activity. Such processes include activation of fibroblast

migration, angiogenesis (the formation of new blood vessels from pre-existing vessels) within the wound bed and an enhanced production of growth factors within the wound environment [19,20]. These are believed to have been part of the success of WBP with our patient although his skin perfusion pressure (SPP) in the dorsum of the foot was only 15 mmHg before MDT. A recent case report also indicated the possibility of MDT to improve blood flow, in addition to supporting its effectiveness for debridement, showing the increased skin perfusion pressure by 42 mmHg in the dorsum and 27 mmHg in the plantar [26]. Nevertheless, the number of published articles on this aspect is limited, and thus further investigation will be necessary before clear determination can be made.

Our case presented with five problematic conditions: (1) delayed WBP due to circulation failure, (2) difficulty of angioplasty after re-stenosis, (3) contraindication of highly invasive treatment, (4) infection by MRSA and (5) pain. To cope with these difficulties, MDT provided the benefits of the following: (1) capability of WBP by removing necrotic tissues with unclear margins, (2) possibility of improving blood flow, (3) effective debridement with low invasiveness, (4) antibiotic effect on MRSA and (5) capability of pain control using analgesics, adjusting the number of maggots and duration of treatment. The Barthel Index at the time of discharge from the hospital was a score of 80; thus, we considered that functionally meaningful limb salvage could be pursued.

From these facts, MDT is believed to be an effective method to improve the wound surface with delayed healing, under the condition that a certain revascularization procedure is performed. MDT is one of the promising adjuvant treatments for patients with an unfavourable systemic condition and difficulty in undergoing highly invasive surgery.

## Conclusions

In conclusion, we could achieve functionally meaningful lower limb salvage by WBP with MDT for an ulcerated lower limb lesion in a CLI patient who had a severe cardiac disorder, delayed healing of the wound surface and difficulty in undergoing a revascularization procedure after arterial restenosis. MDT is considered one of the adjuvant treatment strategies even for patients with CLI, provided it is performed appropriately.

## Disclosure statement

The authors certify that there is no actual or potential conflict of interest in relation to this article.

None of the authors received any financial support in association with this study and have no relationships that may pose an actual or potential conflict of interest.

## References

- Bear WS. The treatment of chronic osteomyelitis with the maggot. *J Bone Joint Surg.* 1931;13:438–475.
- Mitsui H, Kawabata T, Ugaki S, et al. Successful treatment of severe ischemic foot ulcer with sterile maggots: the first case in this country. *Jpn J Vasc Surg.* 2005;14:653–657.
- Slovut DP, Sullivan TM. Critical limb ischemia: medical and surgical management. *Vasc Med.* 2008;13:281–291.
- Sherman RA. Maggot therapy for foot and leg wounds. *Int J Low Extrem Wounds.* 2002;1:135–142.
- Okada T, Mitsui H. The role of maggot therapy in control of chronic infection wounds. *J Jpn Soc Limb Salvage Podiatr Med.* 2015;7:25–30.
- Marston WA, Davies SW, Armstrong B, et al. Natural history of limbs with arterial insufficiency and chronic ulceration treated without revascularization. *J Vasc Surg.* 2006;44:108–114.
- Mahoney FI, Barthel DW. Functional evaluation: The Barthel Index. *Md State Med J.* 1965;14:61–65.
- Soga Y, Iida O, Hirano K, et al. Impact of cilostazol on angiographic restenosis after balloon angioplasty for infrapopliteal artery disease in patients with critical limb ischemia. *Eur J Vasc Endovasc Surg.* 2012;44:577–581.
- Shiraki T, Iida O, Takahara M, et al. Predictive scoring model of mortality after surgical or endovascular revascularization in patients with critical limb ischemia. *J Vasc Surg.* 2014;60:383–389.
- Hirsch AT, Haskal ZJ, Hertzler NR, et al. ACC/AHA 2005 Practice Guidelines for the management of patients with peripheral arterial disease (lower extremity, renal, mesenteric, and abdominal aortic): a collaborative report from the American Association for Vascular Surgery/Society for Vascular Surgery, Society for Cardiovascular Angiography and Interventions, Society for Vascular Medicine and Biology, Society of Interventional Radiology, and the ACC/AHA Task Force on Practice Guidelines (Writing Committee to Develop Guidelines for the Management of Patients With Peripheral Arterial Disease): endorsed by the American Association of Cardiovascular and Pulmonary Rehabilitation; National Heart, Lung, and Blood Institute; Society for Vascular Nursing; TransAtlantic Inter-Society Consensus; and Vascular Disease Foundation. *Circulation.* 2006;113:e463–654.
- Vacanti CJ, VanHouten RJ, Hill RC. A statistical analysis of the relationship of physical status to postoperative mortality in 68,388 cases. *Anesth Analg.* 1970;49:564–566.
- Lee TH, Marcantonio ER, Mangione CM, et al. Derivation and prospective validation of a simple index for prediction of cardiac risk of major noncardiac surgery. *Circulation.* 1999;100:1043–1049.
- Devereaux PJ, Yang H, POISE Study Group, et al. Effects of extended-release metoprolol succinate in patients undergoing noncardiac surgery (POISE trial): a randomised controlled trial. *Lancet.* 2008;371:1839–1847.
- Abidia A, Landen G, Kuhan G, et al. The role of hyperbaric oxygen therapy in ischemic diabetic lower extremity ulcers: a double-blind randomized-controlled trial. *Eur J Vasc Endovasc Surg.* 2003;25:513–518.
- Ishigatsubo Y, Ihata A, Kobayashi H, et al. Therapeutic angiogenesis in patients with systemic sclerosis by autologous transplantation of bone-marrow-derived cells. *Mod Rheumatol.* 2010;20:263–272.
- De Haro J, Acin F, Lopez-Quintana A, et al. Meta-analysis of randomized, controlled clinical trials in angiogenesis: gene and cell therapy in peripheral arterial disease. *Heart Vessels.* 2009;24:321–328.
- Norgen L, Hiatt WR, Dormandy JA, et al. Inter society consensus for management of peripheral arterial disease (TASCII). *Eur J Vasc Endovasc Surg.* 2007;33:S1–S270.
- Okada T, Mitsui H. A way of using maggot therapy at outpatient clinic. *J Jpn Plast Surg.* 2015;58:887–894.
- Nigam Y, Morgan C. Does maggot therapy promote wound healing? The clinical and cellular evidence. *J Eur Acad Dermatol Venereol.* 2016;30:776–782.
- Pritchard DI, Nigam Y. Maximising the secondary beneficial effects of larval debridement therapy. *J Wound Care.* 2013;22:610.
- Cazander G, Pritchard DI, Nigam Y, et al. Multiple actions of *Lucilia sericata* larvae in hard-to-heal wounds: larval secretions contain molecules that accelerate wound healing, reduce chronic inflammation and inhibit bacterial infection. *BioEssays.* 2013;35:1083–1092.
- Chambers L, Woodrow S, Brown AP, et al. Degradation of extracellular matrix components by defined proteinases from the greenbottle larva *Lucilia sericata* used for the clinical debridement of non-healing wounds. *Br J Dermatol.* 2003;148:14–23.
- Courtenay M, Church JC, Ryan TJ. Larva therapy in wound management. *J R Soc Med.* 2000;93:72–74.
- Mumcuoglu KY, Miller J, Mumcuoglu M, et al. Destruction of bacteria in the digestive tract of the maggot of *Lucilia sericata* (Diptera: Calliphoridae). *J Med Entomol.* 2001;38:161–166.
- Anderson AS, Sandvang D, Schnorr KM, et al. A novel approach to the antimicrobial activity of maggot debridement therapy. *J Antimicrob Chemother.* 2010;65:1646–1654.
- Maeda TM, Kimura CK, Takahashi KT, et al. Increase in skin perfusion pressure after maggot debridement therapy for critical limb ischaemia. *Clin Exp Dermatol.* 2014;39:911–914.