



Contents lists available at ScienceDirect

## International Journal of Surgery Case Reports

journal homepage: [www.casereports.com](http://www.casereports.com)

## Perforation of the cecum resulting from a closed-loop obstruction in a patient with an adenocarcinoma of the sigmoid colon: a case report



Jefferson Sing Toledo Junior, Marley Moreira Correia, Rafael Rodrigues Coutinho, Eduardo Fukamachi Kifer, Diego de Faria Magalhães Torres\*

Estácio de Sá University, Brazil

### ARTICLE INFO

#### Article history:

Received 10 March 2017  
Received in revised form 12 May 2017  
Accepted 14 May 2017  
Available online 18 May 2017

#### Keywords:

Colorectal neoplasms  
Intestinal obstruction  
Colectomy  
Intestinal perforation  
Adenocarcinoma  
Case report

### ABSTRACT

**INTRODUCTION:** Bowel obstruction is one of the principal non-traumatic causes of general surgery emergencies, both in Brazil and worldwide. This condition can be classified according to the degree (complete or incomplete), clinical course (acute or chronic) or nature (mechanical, vascular or functional) of the obstruction.

**CASE REPORT:** ESS, a 62-year old Brazilian woman from Rio de Janeiro, was admitted to the emergency department complaining of constipation of two weeks' duration. She also reported fever and fecal vomiting in the preceding two days. A syndromic diagnosis of bowel obstruction was made, and the patient was referred for CT. The sigmoid colon, descending colon, transverse colon, ascending colon, the cecum and the terminal ileum were resected.

**DISCUSSION:** Colorectal cancer is one of the most common forms of cancer in the elderly, perforation of the cecum occurs in only around 3–8% of cases. This can be explained by the fact that patients with colorectal cancer present with wasting syndrome before the bowel lumen becomes completely obstructed. In a literature review conducted for this study, only one publication was found in which rupture of the cecum was associated with colorectal cancer.

**CONCLUSION:** Although rupture of the cecum associated with colorectal cancer is a rare pathology, it constitutes a surgical emergency; therefore, all surgeons should be aware of the possibility.

© 2017 The Author(s). Published by Elsevier Ltd on behalf of IJS Publishing Group Ltd. This is an open access article under the CC BY-NC-ND license (<http://creativecommons.org/licenses/by-nc-nd/4.0/>).

### 1. Introduction

Bowel obstruction is one of the principal non-traumatic causes of general surgery emergencies, both in Brazil and worldwide. This condition can be classified according to the degree (complete or incomplete), clinical course (acute or chronic) or nature (mechanical, vascular or functional) of the obstruction [1].

The principal etiologies of bowel obstruction vary with the part of the intestinal tract that is affected. The pathologies that generally affect the small bowel are adhesions, while those affecting the large intestine tend to be inflammatory processes (ulcerative colitis and Crohn's disease) or tumor development [2].

The most common symptoms in cases of obstruction affecting the large intestine are diffuse abdominal pain and abdominal dis-

ension in 65% of cases. The abdomen may be hypertympanic at physical examination. In addition, constipation or stool and flatus retention may also occur. In cases of mechanical obstruction, the possibility of malignancy must be taken into consideration; therefore attention should be paid to associated wasting symptoms such as weight loss, anorexia and weakness [3,4].

The progression of bowel obstruction, particularly when the ileocecal valve is competent, may result in excessive dilatation of the cecum, which corresponds to the region of the colon with the maximum diameter, greater wall tension, and where the right veins are longest. The condition makes the cecum dependent on parietal infusions, and regions of fragility appear due to the precariousness of vascular anastomoses [5]. This hastens progression to bowel perforation, generating fecal peritonitis and considerably increasing the risk of morbidity and mortality in such cases [6].

Although bowel obstruction is diagnosed clinically, four imaging tests are theoretically useful to confirm diagnosis and determine the treatment plan: simple radiography, echography, magnetic resonance imaging and computed tomography (CT) [4]. CT is considered the gold standard for diagnosis. According to Beattie et al., the large intestine is considered dilated when greater than 6 cm, except for the cecum where the limit is 9 cm [6].

\* Corresponding author at: Rua Riachuelo 27, Center, 20230-010 Rio de Janeiro, RJ, Brazil.

E-mail addresses: [jeffjunior.med@gmail.com](mailto:jeffjunior.med@gmail.com) (J.S. Toledo Junior), [marleymoreirac@gmail.com](mailto:marleymoreirac@gmail.com) (M.M. Correia), [rafael.coutinho@yahoo.com.br](mailto:rafael.coutinho@yahoo.com.br) (R.R. Coutinho), [eduardofkr@hotmail.com](mailto:eduardofkr@hotmail.com) (E.F. Kifer), [diegofmtorres@gmail.com](mailto:diegofmtorres@gmail.com) (D.d.F.M. Torres).

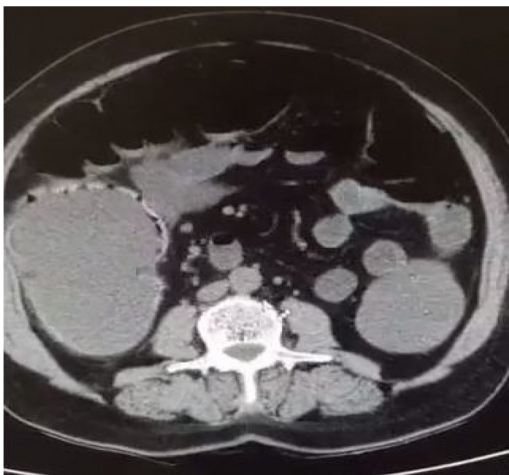

Fig. 1. Computed tomography image showing the cecum dilated to 12 cm.

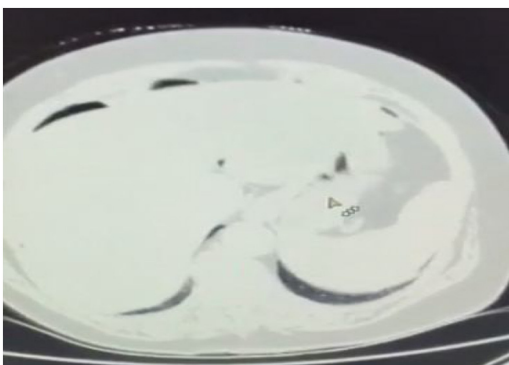


Fig. 2. Pneumoperitoneum at computed tomography with lung window, showing perforation of the cecum.

The objective of the present study was to describe a case of an adenocarcinoma of the sigmoid colon resulting in closed-loop obstruction with perforation of the cecum in a patient admitted to the emergency department of a tertiary level hospital in the city of Rio de Janeiro.

## 2. Case report

ESS, a 62-year old Brazilian woman from Rio de Janeiro, was admitted to the emergency department complaining of constipation of two weeks' duration. She also reported fever and fecal vomiting in the preceding two days.

Physical examination showed the patient to be lucid, oriented in time and space, in a generally good clinical condition, anicteric, acyanotic, afebrile, and with normal, unlabored breathing. Her abdomen was distended, with diffuse pain at surface and deep palpation. In general, the abdomen was hypertympanic, while it was tympanic in the region of the liver. No remarkable alterations were found in any of the other systems.

The patient reported no comorbidities and prior surgeries consisted of three previous Cesarean sections.

A syndromic diagnosis of bowel obstruction was made, and the patient was referred for CT. Blood samples were collected for laboratory tests. White blood cell count was  $13,400/\text{mm}^3$  with 8% bands; hematocrit 37%; glucose 88 mg/dl; urea 20 mg/dl; creatinine 0.8 mg/dl, sodium 136 mEq/l; and potassium 4 mmol/l. Pancreas and liver function tests were all normal. CT showed diffuse dilatation of the colon, with the cecum dilated to 12 cm (Fig. 1), and

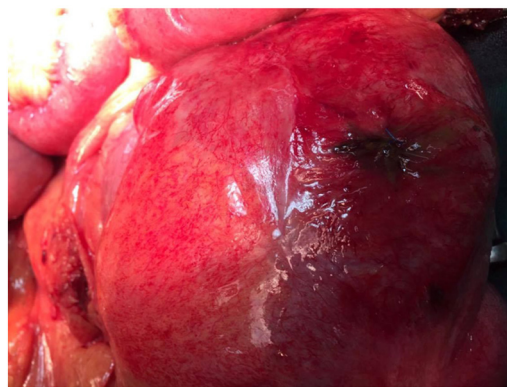


Fig. 3. Pinhole perforation in the cecum.

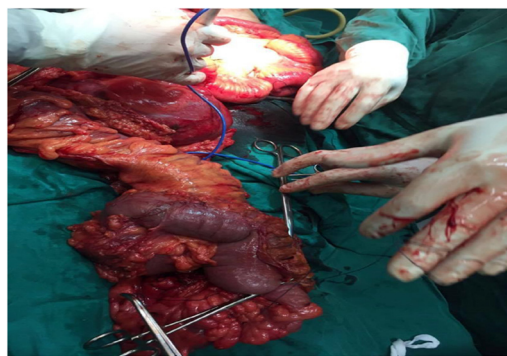


Fig. 4. Surgical specimen following total colectomy.

pneumoperitoneum (Fig. 2). The patient was referred for emergency surgery.

An incision was made from the xiphoid process to the symphysis pubis and the layers were dissected until the abdominal cavity was reached. A pinhole perforation of the cecum was found (Fig. 3), with manipulation resulting in the spilling of large amount of feces. In addition, a tumor was found in the redundant sigmoid colon. The mesocolon and the ileocolic artery were dissected and ligated. Next, the sigmoid colon, descending colon, transverse colon, ascending colon, the cecum and the terminal ileum were resected (Fig. 4). Finally, the rectal stump was closed using 3.0 Prolene sutures. An appropriate drain was placed on the left side of the pelvis, the cavity was thoroughly washed, and a Brooke ileostomy was fashioned on the right. The layers were then sutured until the skin was closed and a sterile bandage was applied.

The patient remained stable during the 5-h surgery and there was no need for blood transfusion. She was then transferred to the intensive care unit (ICU). Pathology showed a well-differentiated adenocarcinoma of the sigmoid colon with no infiltration of the submucosa.

In the ICU, the patient remained under antibiotic therapy for three days, with the regimen consisting of ciprofloxacin 400 mg administered every 12 h and metronidazole 500 mg three times daily. Blood gasometry as well as hematology and biochemical results improved daily, and after five days the patient was transferred from the ICU to a ward where she remained for another two days until her discharge from hospital. She was then referred to the oncology department and gave informed consent to publish your case report, according Ethical Committee approval number 47691715.4.0000.5284.

### 3. Discussion

According to data published by the World Health Organization (WHO), colorectal cancer is the third leading cause of cancer in men worldwide (10% of all cases) and the second cause in women (9.2% of all cases). It is the most common form of cancer of the gastrointestinal tract in both sexes. It accounts for 8.5% of all deaths from cancer, with the number of deaths being higher in less developed countries [7]. The estimates of the Brazilian National Cancer Institute (INCA) for this country in 2016 were around 16,660 new cases in men and 17,620 in women. This highlights the importance of recognizing this form of cancer, particularly in view of recent statistical surveys [8].

Life expectancy in cases of colorectal cancer (including all stages) is five years in 65% of cases. Life expectancy decreases as the stage of the disease increases: at stage I, 95% of patients have a life expectancy of around 5 years compared to 60% of patients with stage III of the disease and 10% of patients with stage IV colorectal cancer [9]. Phipps et al. showed an association between smoking and increased mortality in patients diagnosed with colorectal cancer [10]. Dehal et al. found an association between the presence of type 2 diabetes mellitus and a greater risk of mortality. However, further studies are required to confirm the effect of these associated risk factors and the occurrence of perforations as well as the development of tumors [11].

When colorectal cancer is classified as stage I-T1, polypectomy is recommended, while for cases of stage I-T2 colorectal cancer the surgical procedure indicated is colectomy of the affected segment with regional lymphadenectomy. For stages II and III, surgery is always indicated as long as the medical facility has the capacity to perform the procedure. Chemotherapy following surgery may not be useful in the case of patients classified as stage II; however, it is always indicated for patients at stage III [12].

Colorectal cancer generally metastasizes to the liver through the hepatic portal system and to the lungs through the vena cava. Such cases are classified as stage IV colorectal cancer, with these patients being referred for palliative care. Nevertheless, some studies such as that conducted by Roberts et al. in 2014 have shown that metastases can be resected. In such cases, the treatment recommended in the National Comprehensive Cancer Network (NCCN) guidelines consists of three possibilities: colectomy and metastasectomy + adjuvant chemotherapy; neoadjuvant chemotherapy + colectomy and metastasectomy + adjuvant chemotherapy; or colectomy + adjuvant chemotherapy + metastasectomy + adjuvant chemotherapy. The choice of treatment depends on the local availability of resources [12,13].

For patients with a bowel obstruction of malignant origin, in addition to colectomy a metallic stent can be placed in the colon. The advantages with this technique include reducing the complications of open surgery and gaining time to enable elective surgery to be scheduled. In addition, the technique serves to provide relief to patients for whom surgical resection is not appropriate. The principal disadvantage with this technique is that it cannot be used in cases such as the one reported here in which the cecum is perforated [14].

Although colorectal cancer is one of the most common forms of cancer in the elderly, perforation of the cecum occurs in only around 3–8% of cases [15]. This can be explained by the fact that patients with colorectal cancer present with wasting syndrome before the bowel lumen becomes completely obstructed. In a literature review conducted for this study, only one publication was found in which rupture of the cecum was associated with colorectal cancer. The authors used the SCARE Statement Paper to describe this case report [16].

### 4. Conclusion

Although rupture of the cecum associated with colorectal cancer is a rare pathology, it constitutes a surgical emergency; therefore, all surgeons should be aware of the possibility.

#### Conflicts of interest

Nothing to declare.

#### Sources of funding

Nothing to declare.

#### Ethical approval

Nothing to declare.

#### Consent

Nothing to declare.

#### Author contribution

- 1) Jefferson Sing Toledo Junior – study concept, data collection, data analysis and writing the paper.
- 2) Marley Moreira Correia – data analysis and writing the paper.
- 3) Rafael Rodrigues Coutinho – data analysis and writing the paper.
- 4) Eduardo Fukamachi Kifer – data analysis and writing the paper.
- 5) Diego de Faria Magalhães Torres – data analysis and writing the paper.

#### Guarantor

All authors.

#### References

- [1] H.W. Pinotti, *Obstrução Intestinal Tratado de Clínica Cirúrgica do Aparelho Digestivo*, vol. 2, 4ª edição, Atheneu, 2017, pp. 723–741.
- [2] S.J.V. Crespo, E. Marchiori, L.F. Mendes, *Obstrução em alça fechada com ruptura do ceco: aspectos na tomografia computadorizada – relato de um caso*, *Radiol. Bras.*, São Paulo 34 (June (3)) (2001) 187–189.
- [3] S.R. Ejatollahi, O. Etemad, *Concurrent occurrence of tumor in colon and small bowel following intestinal obstruction: a case report and review of the literature*, *Case Rep. Surg.* 1–4 (2016), ISSN: 20906900.
- [4] S. Malaquin, C. de Vaumas, B. Robert, L. Rebibo, H. Dupont, *Syndromes occlusifs*, *EMC – Anesth.-Réanim.* 12 (3) (2015) 726–750.
- [5] D. Regent, C. Balaj, F. Jausset, A. Oliver, C. Sellal-Aubriot, V. Croise-Laurent, *Perforations du tube digestif*, *EMC – Radiol. Imag. Méd. – Abdom. – Dig.* 7 (2012) 1–21.
- [6] G.C. Beattie, et al., *Computed tomography in the assessment of suspected large bowel obstruction*, *ANZ J. Surg.* 77 (3) (2007) 160–165, ISSN: 14451433.
- [7] *Estimativa 2016. incidência de câncer no Brasil/Instituto Nacional de Câncer José Alencar Gomes da Silva – Rio de Janeiro: INCA, 2015.*
- [8] J. Ferlay, I. Soerjomataram, M. Ervik, R. Dikshit, S. Eser, C. Mathers, M. Rebelo, D.M. Parkin, D. Forman, F. Bray, *GLOBOCAN 2012 v1.0, Cancer Incidence and Mortality Worldwide: IARC CancerBase No. 11*. Lyon, France: International Agency for Research on Cancer; 2013. Available at: <http://globocan.iarc.fr>. (Accessed on: 09 January 2017).
- [9] *Surveillance, Epidemiology, and End Results Program. SEER Stat Fact Sheets: Colon and Rectum Cancer*. National Cancer Institute. Available at: <http://seer.cancer.gov/stafacts/colorect.html>. (Accessed on: Janeiro 09, 2017).
- [10] A.I. Phipps, J. Baron, P.A. Newcomb, *Prediagnostic smoking history, alcohol consumption, and colorectal cancer survival: the Seattle Colon Cancer Family Registry*, *Cancer* 117 (November (21)) (2011) 4948–4957.
- [11] A.N. Dehal, C.C. Newton, E.J. Jacobs, et al., *Impact of diabetes mellitus and insulin use on survival after colorectal cancer diagnosis: the Cancer Prevention Study-II Nutrition Cohort*, *J. Clin. Oncol.* 30 (January (1)) (2012) 53–59.

- [12] National Comprehensive Cancer Network NCCN Clinical Practice Guidelines in Oncology: Colon Cancer. V.1.2016.
- [13] K.J. Roberts, et al., Cost-utility analysis of operative versus non-operative treatment for colorectal liver metastases: Análisis del coste-utilidad del tratamiento quirúrgico versus no quirúrgico para las metástasis hepáticas de cáncer colorrectal, *Br. J. Surg.* 102 (4) (2015) 388–398, ISSN: 00071323.
- [14] H.S. Tilney, et al., Comparison of colonic stenting and open surgery for malignant large bowel obstruction, *Surg. Endosc.* 21 (2) (2007) 225–233, Germany, ISSN: 1432-2218.
- [15] T. Jaffe, W.M. Thompson, Large-bowel obstruction in the adult: classic radiographic and CT findings, etiology, and mimics, *Radiology* 275 (3) (2015) 651–663.
- [16] R.A. Agha, A.J. Fowler, A. Saetta, I. Barai, S. Rajmohan, Orgill DP, for the SCARE group. the SCARE statement: consensus-based surgical case report guidelines, *Int. J. Surg.* 34 (2016) 180–186.

#### Open Access

This article is published Open Access at [sciencedirect.com](http://sciencedirect.com). It is distributed under the [IJSCR Supplemental terms and conditions](#), which permits unrestricted non commercial use, distribution, and reproduction in any medium, provided the original authors and source are credited.