

# Cutaneous lymphangiectasia of the vulva secondary to tuberculosis

Ramesh M. Bhat, Celia S. Saldanha, Srinath M. Kambil, S. Dandakeri

Department of Dermatology, Venereology and Leprosy, Father Muller Medical College, Mangalore, Karnataka, India

**Address for correspondence:**

Dr. Ramesh M. Bhat, Department of Dermatology, Venereology and Leprosy, Father Muller Medical College, Kankanady, Mangalore - 575 002, India. E-mail: rameshderma@yahoo.com

**Abstract**

Cutaneous lymphangiectasia, also called as acquired lymphangioma, is a benign cutaneous disorder involving the dermal and subcutaneous lymphatic channels. It can rarely occur on the vulva. We describe a 35-year-old woman who came with multiple raised lesions over the vulva and left upper thigh of 1 year duration. She gave history of getting treated for multiple swellings that developed over right side of the neck and inguinal regions on both sides three decades ago. On local genital examination, the patient had a large polypoidal growth involving both sides of the vulva, left upper thigh, and over pubic area. Multiple linear scars were present over the upper thighs and groin bilaterally. The patient underwent simple vulvectomy and left thigh growth excision. Histopathological examination of the vulvectomy specimen confirmed our diagnosis.

**Key words:** Acquired lymphangioma, lymphangiectasia, lymphangioma circumscriptum

**INTRODUCTION**

Acquired cutaneous lymphangiectasia (ACL), also called as acquired lymphangioma, is a rare condition characterized by simple dilatation of surface lymphatic vessels. It has to be differentiated from lymphangioma circumscriptum (LC) which is a developmental defect of the deep dermal and subcutaneous lymphatics, although clinically and histologically they resemble each other. However, the differentiation is possible on the basis of history because lymphangiomas are present since birth or early childhood, while acquired cutaneous lymphangiectasia develop later and are associated with various causes.<sup>[1,2]</sup> There are less than 30 cases of vulval lymphangiectasia reported in the literature.<sup>[3]</sup> We describe a case of acquired

cutaneous lymphangiectasia of the vulva, secondary to childhood tuberculosis.

**CASE REPORT**

A 35-year-old female presented with a history of multiple raised lesions over the vulva of 1 year duration. She was asymptomatic initially, later associated with foul smelling discharge and pain. She had similar lesions over the left upper thigh. She was otherwise healthy and there was no history of constitutional symptoms. Thirty three years ago, she was treated for multiple swellings that developed over the right side of her neck and inguinal regions on both sides. Treatment history was suggestive of antituberculosis treatment. She did not undergo any surgery or radiation therapy in the past. Her menstrual cycles were regular. She is married and has four healthy children.

On local genital examination, there was a large tender polypoidal growth measuring around 10 × 6 cm involving both sides of the vulva including bilateral labia majora, clitoris, labia minora, and anterior fourchette with clear, foul

**Access this article online**

<b>Quick Response Code:</b> 	<b>Website:</b> www.ijstd.org
	<b>DOI:</b> 10.4103/0253-7184.93817

**How to cite this article:**

Bhat RM, Saldanha CS, Kambil SM, Dandakeri S. Cutaneous lymphangiectasia of the vulva secondary to tuberculosis. Indian J Sex Transm Dis 2012;33:35-7.

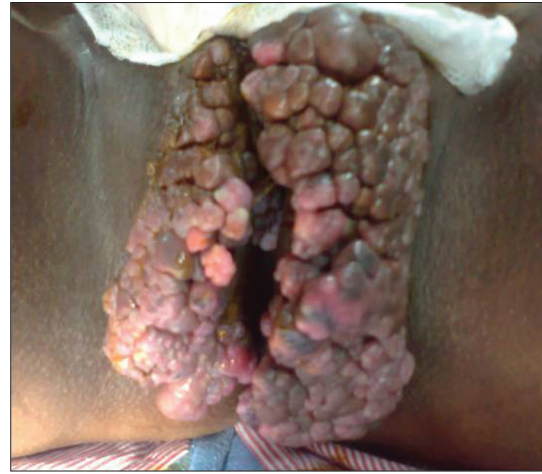smelling discharge in a few areas [Figure 1]. The lesion was firm to hard in consistency. There were few grouped papules of similar morphology over the left upper thigh and over pubic area [Figure 2]. Vulval edema was present. Multiple linear scars were present over the upper thighs and groins bilaterally. There was no regional lymphadenopathy. Complete analysis on blood, liver and renal function tests, urinalysis, and stool examinations were within normal limits. Gynecological workup and ultrasonography of the pelvic organs revealed no abnormality. Mantoux test was negative. Screening tests for human immunodeficiency virus and hepatitis B virus were nonreactive. The patient underwent simple vulvectomy and excision of left thigh growth under spinal anesthesia. Histopathological examination of the vulvectomy specimen revealed thin-walled and ectatic lymphatic channels in the superficial dermis. The dermal papillae and the dermis showed proliferating, congested capillary sized blood vessels, melanophages, and diffuse as well as perivascular mixed inflammatory infiltrate [Figure 3]. Section from the papillomatous growth over left medial thigh showed a similar picture. With the above findings, we came to a diagnosis of lymphangiectasia of vulva.

## DISCUSSION

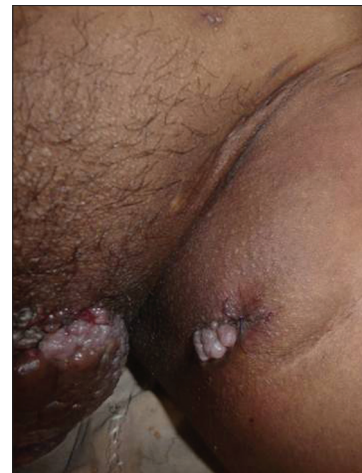Cutaneous lymphangiectasias are not true neoplasms or hamartomas. They arise due to the obstruction of the lymphatics secondary to radiation, surgery, trauma, keloid, scrofuloderma, pregnancy, scleroderma, neoplasia, or infections such as filariasis, tuberculosis, recurrent erysipelas and lymphogranuloma venereum. Vulval lymphangiectasia is a rare disease and is usually reported following surgery/radiotherapy for carcinoma of the cervix or vulva, tubercular inguinal lymphadenitis, or Crohn's disease of the vulva.<sup>[1-3]</sup>

The lymphatic vessels of the superficial dermal plexus drain a fixed area of skin through the vertical collecting lymphatics to the deep plexus. Damage to the deep lymphatic vessels leads to back-pressure and dermal backflow, with subsequent dilatation of the upper dermal lymphatics.<sup>[2]</sup> The lesions are typically known arising approximately 7–15 years after lymph node dissection and radiotherapy of the genitalia.<sup>[4]</sup> The disease affects females aged 22–75 years with mean age 48.5 years.<sup>[5]</sup>

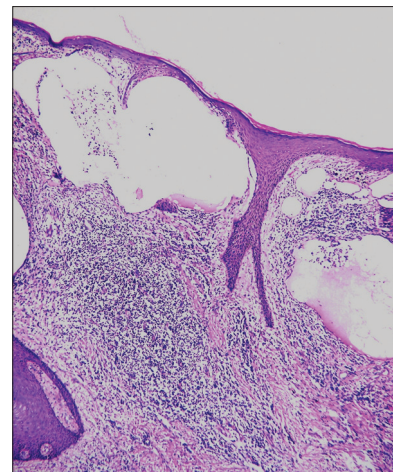
Vulvar lymphangiectasia can be asymptomatic, pruritic, burning, or painful. It is an unpleasant but benign condition.<sup>[6]</sup> Our patient was asymptomatic. Clinically, lymphangiectasia is characterized by thin-walled translucent vesicles filled with clear



**Figure 1: Large polypoidal growth measuring around 10 × 6 cm involving the vulva including bilateral labia majora, clitoris, labia minora, and anterior fourchette**



**Figure 2: A few grouped papules of similar morphology over the left upper thigh**



**Figure 3: Thin-walled, ectatic lymphatic channels in the superficial dermis. The dermal papillae and the dermis showed proliferating, congested capillary sized blood vessels, melanophages, and diffuse as well as perivascular mixed inflammatory infiltrate (H and E stain, magnification 10 × 10)**

colorless fluid, which may be scattered or grouped like frog spawn. Sometimes the vesicles may be blood tinged and sometimes smooth flesh colored nodules can occur.<sup>[2,3,6]</sup> Rarely, the lesions can have a firm hyperkeratotic appearance.<sup>[3,6]</sup> This variation in the morphology is due to gradual tissue organization, probably enhanced by the presence of lymphoedema or recurrent cellulitis.<sup>[3,7]</sup> They are often misdiagnosed as herpes, genital warts, or molluscum contagiosum.<sup>[2,3,5]</sup> Our patient had diffuse polypoidal mass with hyperkeratotic surface on the genitalia and vesicles on the extragenital sites (pubic area and left side of the thigh).

Histologically, dilated lymphatic channels are present in the superficial and mid-dermis, few dilated lymphatics are seen in the deep dermis. The overlying epidermis may display varying degrees of hyperkeratosis, acanthosis, and papillomatosis, and it may appear to enclose the ectatic lymphatic channels. These dilated lymphatic channels may contain scattered lymphocytes and red blood cells, imparting a purplish tinge to the lesion. Vulvar lymphangiectasia has to be distinguished from lymphangioma circumscriptum. LC is a congenitally derived hamartoma with early onset of the lesions. Histologically, LC tends to have more extensive involvement of the deep dermis and subcutis. Other conditions such as mucin secreting metastatic adenocarcinoma mimicking acquired lymphangioma, benign lymphangioendothelioma, syringoma, and condyloma should be ruled out.<sup>[1]</sup>

Diagnosis and treatment of the lesions are important because they may be associated with pain, chronic oozing, and infection, occasionally leading to cellulitis. The diagnosis is mainly clinical, aided by histopathological finding of dilated lymphatics in the dermis. Treatment is aimed at reduction of underlying lymphedema and control of infection.<sup>[3]</sup> In cases where infection is responsible, treatment should be instituted as early as possible to lessen the damage to the lymphatics.<sup>[2]</sup> Daily compression bandage yields good results, but such a measure is difficult in sites like vulva.<sup>[3]</sup> Excisional surgery and carbon dioxide laser are two major treatment modalities in addition to cryotherapy, electrocoagulation, and sclerosing agent injection. Excisional surgery eliminates the abnormal subcutaneous lymph vessels and cisterns and corrects the aesthetic appearance of the edematous vulva.<sup>[4]</sup> Lesion recurrence is frequent but resection

can be repeated several times with no adverse effects.<sup>[8]</sup> Examination of the frozen section of the lateral and deep margins of the excised tissue during the surgery helps to reduce the recurrence.<sup>[1]</sup> Carbon dioxide laser vaporizes the lesion superficially and it seals the underlying lymph vessels and diminishes recurrence. The laser therapy can be repeated if any recurrences occur.<sup>[4]</sup> However, carbon dioxide laser ablation may lead to pain, aggravation of the lesions, and keloid formation. Sclerotherapy with OK-432 is a new medical treatment especially effective in macrocystic lesions.<sup>[9]</sup> As our patient did not show any evidence of active tuberculosis, we managed the patient by surgical excision in the form of vulvectomy.

The prognosis for patients with diffuse lymphangiomas is poor if the condition is resistant to standard therapies. Propranolol, as a new modality of treatment, has been successfully used and is safe in children and may be an important alternative in the treatment of this disease in infants and children with congenital lymphangiomas.<sup>[10]</sup> However, its role in lymphangiectasia has not been studied.

## REFERENCES

1. Chang MH, Shiao GH, Tseng CR. Lymphangiectasia - Report of one case and review of the literature. *Dermatol Sinica* 1997; 15:275-9.
2. Singh N, Kumari R, Thappa DM. Vulval lymphangiectasia secondary to tubercular lymphadenitis. *Indian J Sex Transm Dis* 2007;28:38-9.
3. Haneef NS, Ramachandra S, Metta AK, Haritha K. Lymphangiectasias of vulva. *Indian Dermatol Online J* 2011;2:40-2.
4. Okur MI, Köse R, Yildirim AM, Cobanoğlu B. Lymphangiectasia of the vulva accompanying congenital lymphedema. *Dermatol Online J* 2009;15:13.
5. Horn LC, Kuhndel K, Pawlowitsch T, Leo C, Eienkel J. Acquired lymphangioma circumscriptum of the vulva mimicking genital warts. *Eur J Obstet Gynecol Reprod Biol* 2005;123:118-20.
6. Amouri M, Masmoudi A, Boudaya S, Amouri A, Ben Ali I, Bouassida S, *et al.* Acquired lymphangioma circumscriptum of the vulva. *Dermatol Online J* 2007;13:10.
7. Sharma R, Tomar S, Chandra M. Acquired vulval lymphangiectases mimicking genital warts. *Indian J Dermatol Venereol Leprol* 2002;68:166-7.
8. Vignes S, Arrault M, Trevidic P. Surgical resection of vulva lymphoedema Circumscriptum. *J Plast Reconstr Aesthet Surg* 2010;63:1883-5.
9. Eftal MA. Lymphangioma circumscriptum of the vulva: A case report and review of literature. *Anatol J Obstet Gynecol* 2010;2:4.
10. Ozeki M, Fukao T, Kondo N. Propranolol for intractable diffuse lymphangiomas. *N Engl J Med* 2011;364:1380-2.

**Source of Support:** Nil. **Conflict of Interest:** None declared.