

Empyema Caused by *Peptoniphilus asaccharolyticus* and Complicated by Secondary Pulmonary Infection from *Acinetobacter baumannii*: A Case Report

Min Chai^{1,*}, Patajiang Yusufu^{2,*}, Yixin Chen¹, Jiannan Chai³, Xinran Yang¹, Yuqi Xiao¹, Hongwei Long⁴, Dilimulat Maimaiti², Dahai Xu¹

¹Department of Emergency Medicine, The First Hospital of Jilin University, Changchun, Jilin, People's Republic of China; ²Department of Emergency Medicine, Seventh Affiliated Hospital of Xinjiang Medical University, Urumqi, Xinjiang, People's Republic of China; ³Department of Laboratory, The First Hospital of Jilin University, Changchun, Jilin, People's Republic of China; ⁴Department of Neurosurgery, Meihoukou Central Hospital, Changchun, Jilin, People's Republic of China

*These authors contributed equally to this work

Correspondence: Dahai Xu, Department of Emergency Medicine, The First Hospital of Jilin University, No. 1 Xinmin Street, Chaoyang District, Changchun, Jilin, People's Republic of China, Tel +8615043032548, Email xudahai0319@jlu.edu.cn; Dilimulat Maimaiti, Department of Emergency Medicine, Seventh Affiliated Hospital of Xinjiang Medical University, No. 1986, Qidaowan Road, Shuimogou District, Urumqi City, Xinjiang, People's Republic of China, Tel +8617704972862, Email 3090760383@qq.com

Abstract: *Peptoniphilus asaccharolyticus* is a gram-positive anaerobic coccus that can cause infections in immunocompromised individuals. *P. asaccharolyticus* causing empyema has not been reported earlier. Here, we present a novel case of empyema caused by *P. asaccharolyticus*. A 72-year-old male had a constant fever with difficulty breathing. A chest computed tomography scan revealed infiltration in the right lower lobe and pleural effusion. Following hospital admission, pleural fluid drainage was conducted, and the culture isolated *P. asaccharolyticus*. Initially treated with piperacillin/tazobactam, the patient experienced excessive thick sputum production, prompting a tracheostomy. Subsequent sputum cultures identified *Acinetobacter baumannii*. After transitioning to cefoperazone/sulbactam for antibiotic treatment and continued pleural effusion drainage, recovery was achieved. Empyema can be caused by *P. asaccharolyticus* and further complicated by a secondary infection with *A. baumannii*. Management should include appropriate antibiotic therapy, pleural drainage, vigilant monitoring, and supportive care. We aim to raise clinicians' awareness of the potential for *P. asaccharolyticus* to cause empyema in immunocompromised patients and to provide early treatments, thereby improving morbidity and mortality.

Keywords: Peptoniphilus asaccharolyticus, empyema, Acinetobacter baumannii, case report

Introduction

Peptoniphilus asaccharolyticus, a Gram-positive anaerobic coccus, belongs to the genus *Streptococcus* and is commonly found in the human oral, upper respiratory, digestive, reproductive, and urinary systems. This pathogen can cause infections in immunocompromised patients, typically affecting the skin and soft tissues, joints and spine, kidneys and ureters, lungs, tonsils, genital tract, brain, and heart.¹ Severe pleural cavity infection from *P. asaccharolyticus* and presenting as empyema has never been described previously. *Acinetobacter baumannii* is a common pathogen associated with hospital-acquired pneumonia.² It is often found in water and soil and can colonize various parts of the human body, including the skin, respiratory system, and gastrointestinal tract.³ In particular, carbapenem-resistance *A. baumannii* (CRAB) is of great concern due to its antibiotic resistance.⁴

Here, we report a patient with respiratory distress who was finally diagnosed with empyema caused by *P. asaccharolyticus*. During the hospital admission, this patient developed a secondary infection from *Acinetobacter baumannii*. His condition finally improved after treatments with multiple antibiotics and continuous pleural effusion drainage. We describe this case and share the experience to remind clinicians of this infrequent clinical situation.

Case Presentation

On February 14, 2024, a 72-year-old male presented to the Emergency Department of the First Hospital of Jilin University, China. His chief complaint was intermittent fever for more than three months and persistent fever with difficulty breathing for the last five days. Three months ago, the patient started to have chills and fever. The maximum temperature could reach 39.1°C, with temporary relief by medication. Five days ago, he had a persistent fever, accompanied by difficult breathing, which was not relieved by antipyretics and antitussives. The medical history of this patient included uncontrolled hypertension for 20 years, acute myocardial infarction with two coronary stent placements (January 2023), and cerebral infarction with residual right extremity weakness and aphasia (2016). This study was approved by the ethics committee of the First Hospital of Jilin University, China. The First Hospital of Jilin University has approved that case details can be published. The written informed consent was obtained from the patient.

At our Emergency Department, the vital signs of this patient were temperature 38.1°C, pulse 110 beats/min, respiration 26 breaths/min, blood pressure 130/67 mmHg, and oxygen saturation (SpO₂) 91% on 3L/min oxygen through a nasal cannula. The patient was lethargic and opened his eyes on verbal commands, with a Glasgow Coma Score of 8. The physical examination revealed mixed aphasia and residue right arm and leg weakness. Both lungs had coarse breathing sounds, with slight dry and wet rales. The laboratory tests showed elevated white blood cell count (WBC), neutrophil percentage (NE%), C-reactive protein (CRP), and procalcitonin (PCT). The levels of lymphocyte percentage (LY%) and hemoglobin (HB) level were slightly decreased ([Supplementary Table 1](#)). Arterial blood gas analysis reported an oxygen partial pressure of 81 mmHg (on 3L/min oxygen through a nasal cannula. [Supplementary Table 2](#)). The chest computed tomography (CT) scan demonstrated right lower lobe infiltration with pleural effusion ([Figure 1A–D](#)). The patient was admitted to the medical floor with a diagnosis of right lower lobe pneumonia with right pleural effusion.

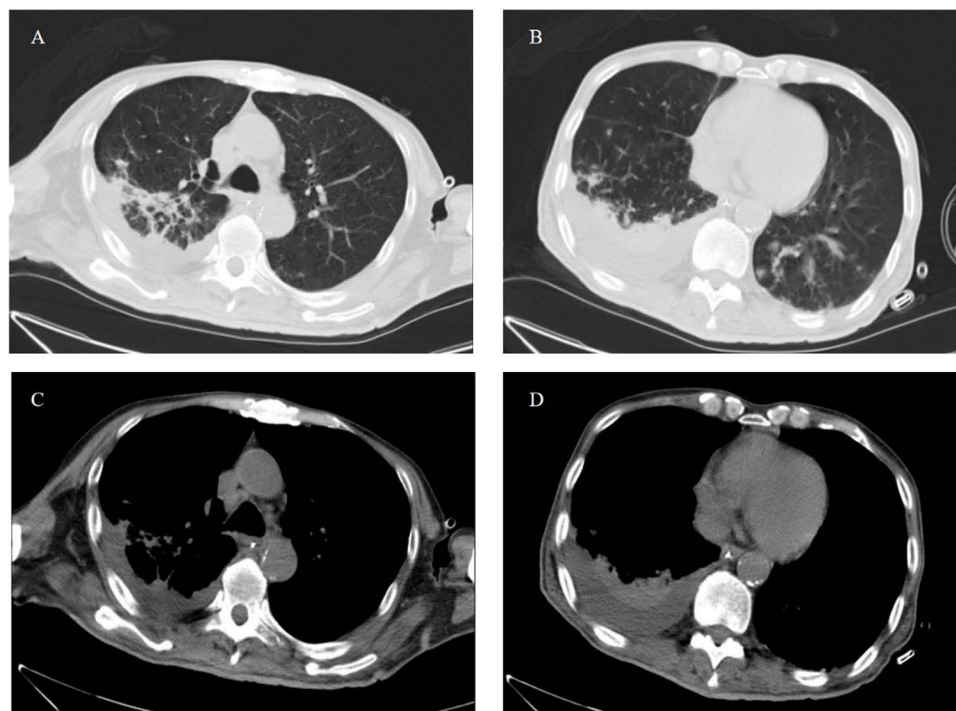


Figure 1 Chest computed tomography scan shows right lower lobe infiltration (**A, C**) with pleural effusion (**B, D**) at the initial hospital presentation. (**A** and **B**) are the lung window, and (**C** and **D**) are the mediastinal window.

On the first day of hospital admission, the patient began receiving antibiotic treatments with intravenous cefepime (2 g, twice daily) and moxifloxacin (250 mg, daily). Additional treatments included oxygen supplementation, antipyretics, doxophylline (0.3 g, daily), nebulized budesonide (1 mg), and terbutaline (5 mg). The following day, laboratory tests indicated positive IgM for parainfluenza virus and a negative test for tuberculosis, prompting the addition of oseltamivir (75 mg, twice daily). By the sixth day, despite these interventions, the patient still had a persistent fever with worsening respiratory distress. Consequently, his antibiotics were empirically switched to intravenous meropenem (1 g, twice daily), linezolid (600 mg, daily), and oral voriconazole (200 mg, daily).

A right-side thoracentesis yielded yellow purulent fluid with a foul odor (Figure 2). The pleural fluid analysis revealed a protein level of 23.8 g/L, a negative Rivalta test, an erythrocyte count of $25,000 \times 10^6/L$, a leukocyte count of $69,072 \times 10^6/L$, 69% multinucleated cells, 32% single nucleated cells, glucose at 0.1 mmol/L, lactate dehydrogenase at 2,293 U/L, adenosine deaminase at 38.9 U/L, and carcinoembryonic antigen at 1.8 ng/mL. The tuberculosis smear returned negative. Notably, most cells exhibited lobulated nuclei. Following the thoracentesis, a chest tube was placed for continuous drainage of pleural fluid. Subsequently, the patient's fever gradually subsided. His respiratory symptoms also showed significant improvement.

On day 8 after the hospital admission (February 22), the pleural fluid culture was reported as *P. asaccharolyticus* (confidence level of 99.9%, VITEK mass spectrometry analysis, Figure 3). As our hospital was unable to conduct the bacterial susceptibility test, we performed a literature review that found commonly used antibiotics for *P. asaccharolyticus* included penicillin, piperacillin/tazobactam, vancomycin, linezolid, and tigecycline.¹ We discontinued meropenem, linezolid, and voriconazole, and switched to piperacillin/tazobactam (4.5 g, three times daily). Afterward, the patient's temperature remained in the normal range.

However, on day 25 after admission (March 10), the patient had a strong cough and a large amount of thick sputum, with SpO₂ lower to 60%. He was transferred to the intensive care unit and received sputum aspiration and transnasal high-flow oxygen supply. His SpO₂ rose to 90%. The patient still had difficulty in expectorating sputum. He underwent a tracheostomy with oxygen supply (oxygen concentration 40%, flow rate 40 L/min) on day 27 (March 12). The patient's condition was stabilized by timely suctioning through the tracheotomy. Meanwhile, the patient received daily respiratory function training from the rehabilitation department to promote sputum discharge, which included respiratory training (once a day), bedside simple spirometry (once a day), whole-body plyometrics (once a day), and low-frequency electrotherapy for bilateral internal intercostal muscles, external intercostal muscles, and diaphragm muscles. Following these treatments, the patient's condition gradually became stable.

A pleural fluid culture was performed again on day 25, which was negative, suggesting that the *P. asaccharolyticus* had been cleared. However, his sputum culture grew *Acinetobacter baumannii*, which was sensitive to cefoperazone/sulbactam but resistant to piperacillin/tazobactam. The antibiotic sensitivity test reported that the minimum inhibitory concentrations were cefoperazone/sulbactam = 16, colistin ≤ 0.5 , minocycline = 4, and piperacillin/tazobactam $\geq 128 \mu\text{g}/\text{mL}$. Therefore, we changed from piperacillin/tazobactam to cefoperazone/sulbactam (1.5 g, twice daily).




Figure 2 Yellow, purulent, foul fluid drained from thoracentesis.

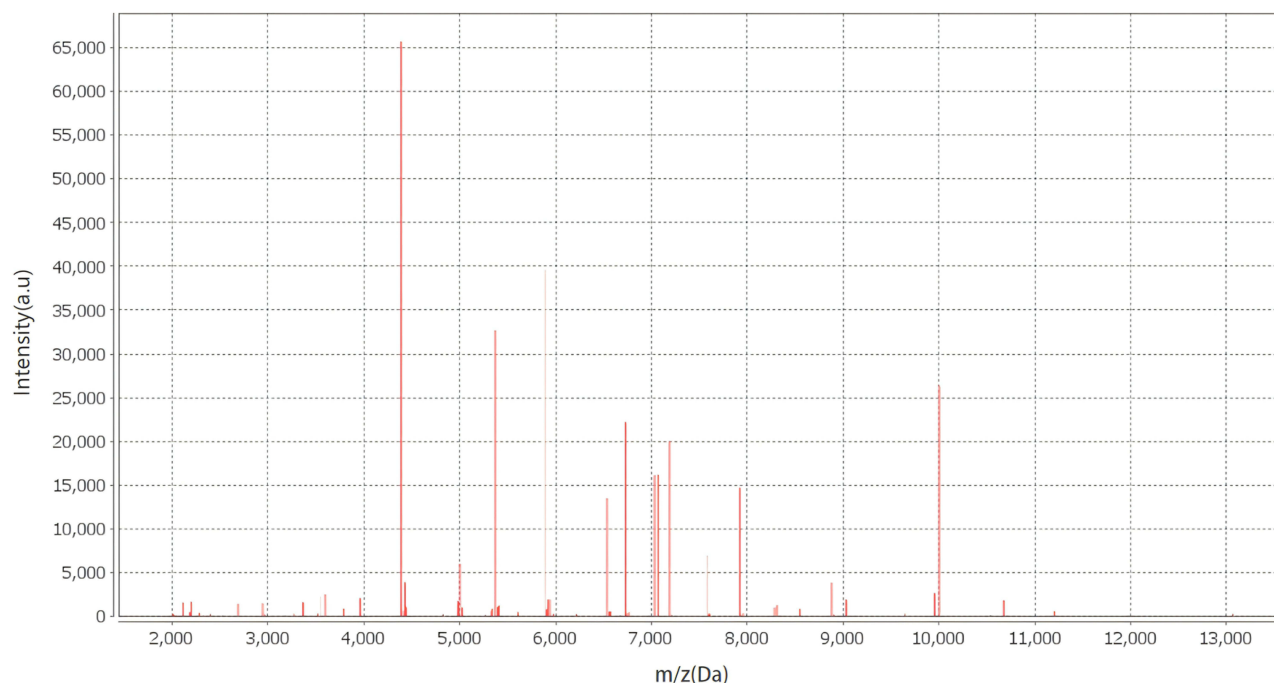


Figure 3 Spectrum of the strain of *Peptoniphilus asaccharolyticus* by the VITEK Matrix-assisted laser desorption ionization-time of flight mass spectrometry (Horizontal axis: ratio of mass charge to Dalton; Vertical axis: intensity. The protein compositions are different among different microorganisms. Statistical clustering analysis was performed on the unknown sample spectra collected by the equipment, and the results were compared with the spectra of known bacterial species in the database to identify the potential microorganisms. This graph is consistent with *Peptoniphilus asaccharolyticus*).

On day 32 (March 17), a chest color Doppler ultrasound showed only a small amount of pleural effusion (< 10 mm in depth). The drainage from the chest tube persisted low at <100 mL daily. The laboratory tests also significantly improved WBC count, PCT, and CRP. Clinically, the patient had no fever, cough, or difficulty breathing. The chest tube was removed, and he was discharged from the hospital with tracheostomy and daily suction when necessary. Two months later, the patient was followed up in the clinic and reported no discomfort.

Discussion

P. asaccharolyticus is a conditionally anaerobic pathogenic bacterium.⁵ Infection from this pathogen was rarely reported, probably due to its stringent culture conditions and the dominance of parthenogenetic aerobic bacteria to inhibit the proliferation of anaerobic bacteria in a polymicrobial culture environment.⁶ *P. asaccharolyticus* does not usually cause human infection and disease. Only under certain situations and populations, *P. asaccharolyticus* may behave like opportunistic pathogens and cause clinically important infections. The elderly, people with implanted artificial joints, and immunocompromised patients are at an increased risk of infections from *P. asaccharolyticus*.¹ Most human infections from *P. asaccharolyticus* were reported in the skin and soft tissues, bone, joint, solid organ infections, or bloodstream.^{7–12} De Crescenzo et al reported the identification of *P. asaccharolyticus* in humeral head cultures of patients undergoing total shoulder arthroplasty.¹³ Wang et al described a cervical cancer patient whose blood cultures grew *P. asaccharolyticus*.¹⁰ Verma et al presented a case of septic arthritis and osteomyelitis caused by *P. asaccharolyticus* in a woman with underlying diabetes.¹⁴ We did not find any previous report about empyema caused by the infection from *P. asaccharolyticus*.

Empyema is an accumulation of pus from infection in the pleural cavity. It is a severe illness with high morbidity and mortality rates.¹⁵ The common sources of empyema are direct, hematogenous, or lymphatic spreading of bacteria.¹⁶ Pneumonia was the most common cause.¹⁷ Other causes included post-thoracic and abdominal surgery,¹⁸ trauma,¹⁹ and surrounding soft tissue infections.²⁰ In the present case, the blood and sputum cultures were negative. His pleural fluid culture grew *P. asaccharolyticus*. We consider that the bacteria directly spread from the lung to the

pleural cavity. The patient had a history of cerebral infarction with residual aphasia, which increased the risk of aspiration pneumonia,²¹ which might have contributed to the spread of infection and also secondary pulmonary infection from *A. baumannii*. The pulmonary infection could increase the capillary permeability in the visceral pleura, with subsequent bacterial infection causing empyema.²² Empyema caused by *P. asaccharolyticus* was never reported previously. This case reminded us to consider rare pathogens in empyema patients with poor baseline health status. Extensive bacterial cultures on sputum, blood, and pleural fluid should be performed. Inter-disciplinary consultation with infectious disease specialists may be required to choose appropriate bacterial detection methods, such as metagenomic next-generation sequencing test, in addition to the bacterial culture. Antibiotic selection should also consider rare pathogens, such as *P. asaccharolyticus*.

Our patient was treated with antibiotics, but unfortunately, he developed a secondary pulmonary infection. The sputum culture confirmed the pathogen to be *A. baumannii*. *A. baumannii* is one of the most common bacteria responsible for nosocomial infections.²³ Affected patients could develop pneumonia, bacteremia, meningitis, cellulitis, osteomyelitis, or urinary tract infections. Unlike *P. asaccharolyticus*, which remains sensitive to many antibiotics, *A. baumannii* is commonly resistant to multiple antibiotics.²⁴ Many reports have been about treatment options for infection caused by *A. baumannii*. Katip et al reported that a long course of colistin therapy in colistin-sensitive CRAB infection resulted in lower mortality and better clinical outcomes in critically ill patients compared with short-term colistin therapy, with no difference in nephrotoxicity.²⁵ The excellent synergistic activity of the combination of colistin–sulbactam has been reported to have therapeutic potential for treating colistin-resistant *Acinetobacter baumannii* infections.²⁶ Katip et al proposed loading doses of colistin to effectively treat patients with CRAB, which required close monitoring of renal function.²⁷ A retrospective study indicated that there was no significant difference in 30-day survival in patients receiving intravenous colistin with or without nebulized colistin, suggesting that the addition of nebulized colistin did not provide additional benefit in terms of survival, clinical or microbiological response, or nephrotoxicity.²⁸ In our patient, we selected cefoperazone/sulbactam to treat *A. baumannii* based on the drug sensitivity analysis. The patient recovered and was discharged from the hospital.

The patient's compromised baseline health status due to a previous stroke heightened his risk for pulmonary infections. During antibiotic treatment, he struggled to expectorate thick sputum, necessitating a tracheostomy. This case underscores the importance of closely monitoring respiratory status in patients with poor baseline health to prevent complications such as sputum-induced asphyxiation and hypoxemia. A recent study reported and validated scoring systems to predict short- and long-term mortalities in patients with bloodstream infection. In addition to the types of pathogen, patient age, body mass index, laboratory tests including platelet and leukocyte counts and CRP level, comorbidities, and acquisition location could all contribute to the increased mortality.²⁹ Therefore, a comprehensive evaluation of patient medical history, clinical presentation, and laboratory test results is required to identify patients with high mortality who require prompt management.

Our study had several limitations, such as a single case report in a local area. Depending on strains and patient populations, the bacterial sensitivity and resistant profile may have regional differences. Careful clinical monitoring, re-evaluations, and bacterial identification are required in patients with suspected infection.

Conclusion

Rare pathogens, such as *P. asaccharolyticus* can cause empyema. The necessity for prolonged antibiotic treatment and extended hospital stays can further complicate the situation, potentially leading to secondary hospital-acquired pneumonia caused by *A. baumannii*. It is crucial to administrate appropriate antibiotics and perform pleural drainage while closely monitoring respiratory status in these patients, particularly those with compromised baseline health. When selecting appropriate antibiotics for empyema, clinicians should consider rare pathogens, such as *P. asaccharolyticus*, to avoid missed diagnosis and treatment. Secondary infection from another pathogen, such as *A. baumannii*, should be considered in patients without improvement or recurrent clinical symptoms. Further appropriate diagnostic tests should be applied for such patients.

Abbreviations

P. asaccharolyticus, *Peptoniphilus asaccharolyticus*; GCS, Glasgow Coma Scale; WBC, White blood cell count; NE%, Neutrophil percentage; LY%, Lymphocyte percentage; CRP, C-reactive protein; PCT, Procalcitonin; CT, Chest computed tomography.

Data Sharing Statement

The datasets generated and analyzed during the present study are available from the corresponding author upon reasonable request.

Ethics Approval and Consent to Participate

This study was approved by the ethics committee of the First Hospital of Jilin University, China. The written informed consent to participate was obtained from the patient.

Acknowledgment

We thank *Medjaden Inc.* for their scientific editing and proofreading of this manuscript.

Funding

This study did not receive any funding in any form.

Disclosure

The authors declare that they have no conflict of interest.

References

- Althaqafi A, Munshi A, Altayib H, Alsubhi N, Alnajjar D, Al-Amri A. Septic abortion secondary to *Peptoniphilus asaccharolyticus* complicated by bacteremia: a case report and review of literature. *Cureus*. 2023;15(3):e35978. doi:10.7759/cureus.35978
- Shein AMS, Hongsing P, Smith OK, et al. Current and novel therapies for management of *Acinetobacter baumannii*-associated pneumonia. *Crit Rev Microbiol*;2024. 1–22. doi:10.1080/1040841X.2024.2369948
- Bartal C, Rolston KVI, Neshler L. Carbapenem-resistant *Acinetobacter baumannii*: colonization, infection and current treatment options. *Infect Dis Ther*. 2022;11(2):683–694. doi:10.1007/s40121-022-00597-w
- Castillo-Ramírez S. Genomic epidemiology of *Acinetobacter baumannii* goes global. *mBio*. 2023;14(6):e0252023. doi:10.1128/mbio.02520-23
- Murdoch DA. Gram-positive anaerobic cocci. *Clin Microbiol Rev*. 1998;11(1):81–120. doi:10.1128/CMR.11.1.81
- Müller-Schulte E, Heimann KC, Treder W. *Peptoniphilus asaccharolyticus* - Commensal, pathogen or synergist? Two case reports on invasive *Peptoniphilus asaccharolyticus* infection. *Anaerobe*. 2019;59:159–162. doi:10.1016/j.anaerobe.2019.07.001
- Stein GE, Tyrrell KL, Dybas LA, Citron DM, Nicolau DP, Goldstein EJ. Anti-anaerobic activity of serum from patients treated with tigecycline for skin/soft tissue infections. *Anaerobe*. 2011;17(4):213–215. doi:10.1016/j.anaerobe.2011.02.006
- Brown K, Church D, Lynch T, Gregson D. Bloodstream infections due to *Peptoniphilus* spp.: report of 15 cases. *Clin Microbiol Infect*. 2014;20(11):O857–860. doi:10.1111/1469-0691.12657
- Abbas HA, Taha AA, Sulaiman GM, et al. Antibacterial and hemocompatibility potentials of nano-gold-cored alginate preparation against anaerobic bacteria from acne vulgaris. *Sci Rep*. 2024;14(1):6984. doi:10.1038/s41598-024-57643-5
- Wang H, Yang JL, Chen C, et al. Identification of *Peptoniphilus vaginalis*-like bacteria, *Peptoniphilus septimus* sp. nov. from blood cultures in a cervical cancer patient receiving chemotherapy: case and implications. *Front Cell Infect Microbiol*. 2022;12:954355. doi:10.3389/fcimb.2022.954355
- Sarantis M, Argyrou C, Tzefronis D, Stasi S, Macheras G. Sonication fluid isolation of *peptoniphilus asaccharolyticus* after total hip arthroplasty. *Cureus*. 2022;14(1):e21419. doi:10.7759/cureus.21419
- Kitano H, Hieda K, Kitagawa H, et al. Case report: emphysematous pyelonephritis with a congenital giant ureterocele. *Front Pediatr*. 2021;9:775468. doi:10.3389/fped.2021.775468
- De Crescenzo A, Fontanarosa A, Lassandro N, Fortunato M, Ricciardi IR, Garofalo R. Unexpected positive cultures of humeral head detected with dithiothreitol in primary shoulder arthroplasty. *J Shoulder Elbow Surg*. 2024;33(10):2142–2148. doi:10.1016/j.jse.2024.04.010
- Verma R, Morrad S, Wirtz JJ. *Peptoniphilus asaccharolyticus*-associated septic arthritis and osteomyelitis in a woman with osteoarthritis and diabetes mellitus. *BMJ Case Rep*. 2017;2017:bcr-2017.
- Corcoran JP, Wrightson JM, Belcher E, DeCamp MM, Feller-Kopman D, Rahman NM. Pleural infection: past, present, and future directions. *Lancet Respir Med*. 2015;3(7):563–577. doi:10.1016/S2213-2600(15)00185-X
- Duan Y, Feng W, Shen Y, et al. Severe pneumonia with empyema caused by *Parvimonas micra* and *Streptococcus constellatus* co-infection: a case report. *J Int Med Res*. 2023;51(11):3000605231210657. doi:10.1177/03000605231210657
- Hamm H. The treatment of parapneumonic effusions and pleural empyemas. *Pneumologie*. 2005;59(10):696–703. doi:10.1055/s-2005-870982
- Henschke P, Guglielmetti LC, Hillinger S, et al. Risk factors influencing postoperative pleural empyema in patients with pleural mesothelioma: a retrospective single-centre analysis. *Eur J Cardiothorac Surg*. 2024;65(4). doi:10.1093/ejcts/ezae137.

19. Ghisalberti M, Madioni C, Ghinassi G, et al. A strange case of traumatic pleural effusion: pleural empyema due to *Actinomyces meyeri*, a case report. *Life*. 2023;13(7):1450. doi:10.3390/life13071450
20. Foster S, Maskell N. Bacteriology of complicated parapneumonic effusions. *Curr Opin Pulm Med*. 2007;13(4):319–323. doi:10.1097/MCP.0b013e3281864691
21. Jitpratoom P, Boonyasiri A. Factors associated with an increased risk of developing pneumonia during acute ischemic stroke hospitalization. *PLoS One*. 2024;19(1):e0296938. doi:10.1371/journal.pone.0296938
22. Ferreira L, Porcel JM, Bielsa S, Toubes ME, Álvarez-Dobaño JM, Valdés L. Management of pleural infections. *Expert Rev Respir Med*. 2018;12(6):521–535. doi:10.1080/17476348.2018.1475234
23. Shi J, Cheng J, Liu S, Zhu Y, Zhu M. *Acinetobacter baumannii*: an evolving and cunning opponent. *Front Microbiol*. 2024;15:1332108. doi:10.3389/fmicb.2024.1332108
24. Rafailidis P, Panagopoulos P, Koutserimpas C, Samonis G. Current therapeutic approaches for multidrug-resistant and extensively drug-resistant *Acinetobacter baumannii* infections. *Antibiotics*. 2024;13(3):261.
25. Katip W, Rayanakorn A, Oberdorfer P, Taruangsri P, Nampuan T. Short versus long course of colistin treatment for carbapenem-resistant *A. baumannii* in critically ill patients: a propensity score matching study. *J Infect Public Health*. 2023;16(8):1249–1255. doi:10.1016/j.jiph.2023.05.024
26. Srisakul S, Wannigama DL, Higgins PG, et al. Overcoming addition of phosphoethanolamine to lipid A mediated colistin resistance in *Acinetobacter baumannii* clinical isolates with colistin-sulbactam combination therapy. *Sci Rep*. 2022;12(1):11390. doi:10.1038/s41598-022-15386-1
27. Katip W, Uitrakul S, Oberdorfer P. Clinical efficacy and nephrotoxicity of the loading dose colistin for the treatment of carbapenem-resistant *Acinetobacter baumannii* in critically ill patients. *Pharmaceutics*. 2021;14(1):31. doi:10.3390/pharmaceutics14010031
28. Katip W, Rayanakorn A, Sornsuvit C, et al. High-loading-dose colistin with nebulized administration for Carbapenem-Resistant *Acinetobacter baumannii* Pneumonia in critically ill patients: a retrospective cohort study. *Antibiotics*. 2024;13(3):287. doi:10.3390/antibiotics13030287
29. Tacconelli E, Göpel S, Gladstone BP, et al. Development and validation of BLOOMY prediction scores for 14-day and 6-month mortality in hospitalised adults with bloodstream infections: a multicentre, prospective, cohort study. *Lancet Infect Dis*. 2022;22(5):731–741. doi:10.1016/S1473-3099(21)00587-9

Infection and Drug Resistance

Dovepress

Publish your work in this journal

Infection and Drug Resistance is an international, peer-reviewed open-access journal that focuses on the optimal treatment of infection (bacterial, fungal and viral) and the development and institution of preventive strategies to minimize the development and spread of resistance. The journal is specifically concerned with the epidemiology of antibiotic resistance and the mechanisms of resistance development and diffusion in both hospitals and the community. The manuscript management system is completely online and includes a very quick and fair peer-review system, which is all easy to use. Visit <http://www.dovepress.com/testimonials.php> to read real quotes from published authors.

Submit your manuscript here: <https://www.dovepress.com/infection-and-drug-resistance-journal>