

# Arthroscopic Bone Graft for Intraosseous Lunate Bone Ganglion



Clément Prénaud, M.D., Daphné Querel, M.D., Christophe Mathoulin, M.D., and Lorenzo Merlini, M.D.

**Abstract:** Intraosseous lunate bone ganglia (ILBG) are known to be a cause of chronic wrist pain and disability. Standard treatment consists of curettage and autologous bone grafting. Open procedures have shown good results with few recurrences, but with frequent stiffness or persistent pain. Arthroscopic techniques are more recent and seem very reliable. Several arthroscopic techniques have been reported for ILBG approach and treatment. The present study describes an approach that preserves all the lunate cartilage of both radiocarpal and midcarpal surfaces. The surgical technique allows easy and direct access to the bone ganglia, passing through the intermediate portion of the scapholunate ligament, with the scope in the 1-to-2 portal and instrumentation through the 3-to-4 portal. The rest of the procedure is straightforward: curettage and bone grafting are performed through this specific approach, similarly to other techniques. This an easy and accurate approach that avoids any damage to the major cartilage surfaces of the lunate, with easy and reliable access to the intraosseous lunate bone ganglion, allowing cyst curettage and autologous bone graft in a proper and noninvasive way.

Intraosseous lunate bone ganglia (ILBG) or cysts are relatively uncommon in the general population. Their incidence is difficult to estimate.<sup>1</sup> They are most frequently painless and asymptomatic, and they are usually discovered by chance on plain radiographies, magnetic resonance imaging (MRI), or computerized tomography (CT) examination. Patients with ILBG can develop symptoms, however: mostly pain, if the cyst is responsible for a lunate fracture or an opening into the scapholunate joint space.<sup>2</sup> Intraosseous ganglia can occur in all carpal bones but are mainly located in the lunate, sometimes bilaterally,<sup>3</sup> and can be associated with soft tissue wrist ganglia.<sup>4</sup> Though ILBG are mostly idiopathic, the pathogenesis remains unclear and seems to be closely related to the common dorsal soft tissue ganglion.<sup>5,6</sup>

The surgical treatment of this pathology has evolved over the years, from open procedures to arthroscopic-assisted to all-arthroscopic techniques, mostly consisting of curettage of the cyst combined with bone grafting (usually autologous), yielding good functional results and low recurrence rates.<sup>6,7</sup> Open treatment has been associated with wrist stiffness, persistent pain,<sup>8</sup> and vascular disorders of the lunate.<sup>7,9</sup> Wrist arthroscopy techniques have allowed enhancement of ILBG curettage and grafting, overcoming the complications of the open approach.<sup>7,10,11</sup>

The goal of this study is to describe a minimally invasive technique that consists of arthroscopically passing through the proximal, nonvascularized portion of the scapholunate ligament. It can allow direct access

**Table 1.** Advantages and Disadvantages

Advantages	Disadvantages
Preserve carpal ligaments	Not the most cost-effective solution
Preserve scapholunate stability	Learning curve of wrist arthroscopy
No drilling or trans osseous approach	
Palmar cysts can be treated with a volar central radiocarpal approach	
Only 2 portals are required	
Associated radiocarpal and midcarpal lesions can be diagnosed and treated	
Better cosmetic results	

From the Institut de la Main, Clinique Bizet, Paris, France.

The authors report that they have no conflicts of interest in the authorship and publication of this article. Full ICMJE author disclosure forms are available for this article online, as [supplementary material](#).

Received June 13, 2021; accepted August 5, 2021.

Address correspondence to Clément Prénaud, M.D., Institut de la Main, Clinique Bizet, 22 bis, Rue Georges Bizet, 75116, Paris, France. E-mail: [clementprenaud@gmail.com](mailto:clementprenaud@gmail.com)

© 2021 by the Arthroscopy Association of North America. Published by Elsevier. This is an open access article under the CC BY-NC-ND license (<http://creativecommons.org/licenses/by-nc-nd/4.0/>).

2212-6287/21891

<https://doi.org/10.1016/j.eats.2021.08.027>

**Table 2.** Pearls and Pitfalls

Step	Pearls	Pitfalls
Locating and curettage of the cyst	For palmar cyst, the arthroscopic technique is still possible : keep the scope in the 1-to-2 portal and use a volar central radiocarpal approach <sup>25</sup> for instrumentation Create a passage through the proximal portion of the ligament with the needle with up and down movements. It makes it easier to put the shaver straight forward to the lunate cyst cavity	
Bone graft harvesting and application	The bone graft is harvested from the lister tubercle or the radial styloid  Go back and forth with the trocar to take the graft until the defect is being filled	Take care around the sensory branches of the radial nerve and the first and second extensor compartments

to the cyst, which frequently opens into the scapholunate joint, for curettage and bone grafting.

## Technique

### Patient Preparation

The procedure is performed under regional anesthesia using a tourniquet, on an outpatient care basis. The patient's arm is secured to the arm board. Finger traps are used to apply 5 to 7 kg (11 to 15.5 lb) of traction along the arm's axis. The advantages and surgical pearls of the technique are summarized in [Tables 1](#) and [2](#), and the steps are demonstrated in the [Video 1](#).

### Radiocarpal Exploration

The scope (30°, 2.4-mm diameter; Karl Storz, Tuttingen, Germany) is introduced in the 3-to-4 portal, and the shaver (2.9 mm, Karl Storz), in the radiocarpal 1-to-2 portal. The first phase of the arthroscopic procedure consists of complete synovectomy with a shaver, reversing the shaver and scope positions. With the scope

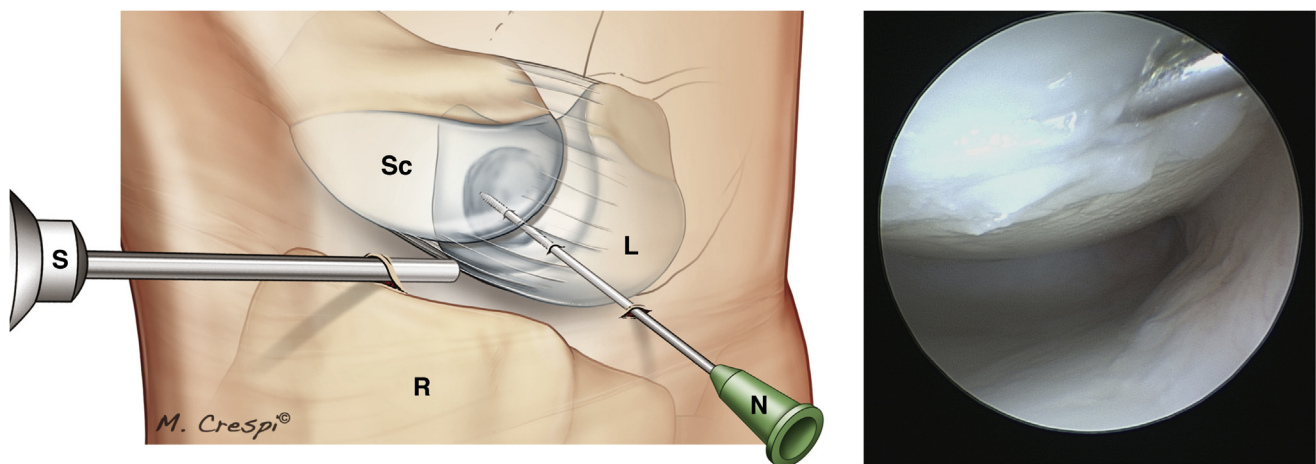
in the 1-to-2 portal, the scapholunate ligament—specifically, its proximal portion—can be located.

### Locating and Curettage of the Cyst

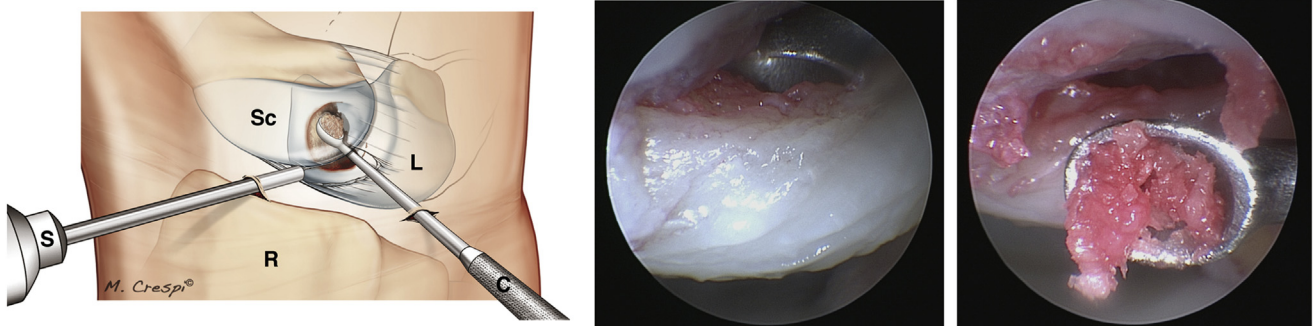
With the scope in the 1-to-2 portal, an intramuscular needle is introduced in the 3-to-4 portal with its tip aimed at the proximal portion of the ligament. The needle is inserted through the ligament to locate the intraosseous cyst, the outer wall of which has collapsed ([Video 1](#); [Fig 1](#)). The ganglion is usually on the volar side. Once the ganglion has been located, a curette is inserted through the ligament under arthroscopic guidance ([Video 1](#); [Fig 2](#)). The entire ganglion is then resected using the curette and the shaver. This step can be performed either with saline irrigation or dry.

### Bone Graft Harvesting

The bone graft is harvested from the ipsilateral wrist. An incision is made on the lateral side of the wrist between the first and second extensor compartments. The sensory branches of the radial nerve are identified and protected.



**Fig 1.** Locating the cyst (right wrist). Scope in the 1-to-2 portal, needle in the 3-to-4 portal through the proximal portion of the scapholunate ligament, to the ganglion. Abbreviations: L, lunate; N, needle; R, radius; Sc, scaphoid; S, scope.



**Fig 2.** Curettage of the cyst (right wrist). Scope in the 1-to-2 portal, curettage of the ganglion from the 3-to-4 portal through the proximal portion of the scapholunate ligament. The entire ganglion is then resected using the curette and the shaver. Abbreviations: C, curette; L, lunate; R, radius; Sc, scaphoid; S, scope.

The periosteum under the extensor tendons in the first and second compartments is roughened with a bone rasp to free up the graft collection area. A 3-sided osteotomy is performed while leaving a “bone cap” attached to the radius. The bone graft is harvested with a curette; its volume must be larger than the defect being filled. After the graft has been collected, the cap is placed back on the harvest site.

**Bone Graft Application**

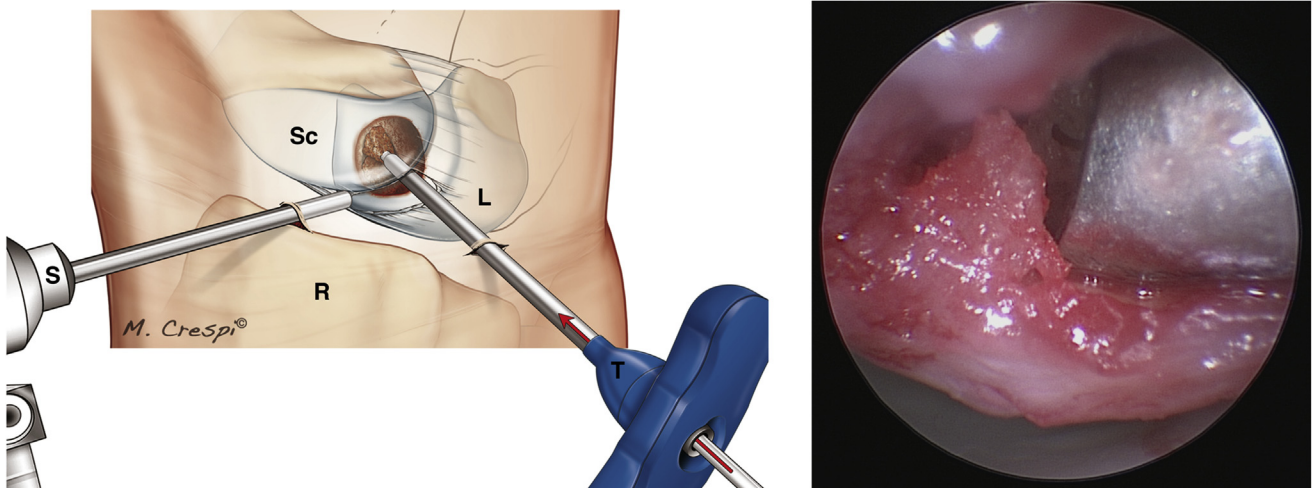
The next step is performed in a dry environment. If the initial part of the procedure was performed with irrigation, all the fluid must be aspirated. The bone graft is inserted into a trocar, and the trocar’s tip is placed in the cyst cavity (Video 1; Fig 3). The graft is pushed into the trocar with a blunt guide wire until the cyst cavity is filled (Video 1; Fig 4). The bone graft is packed down with a blunt guide wire (Video 1; Fig 5).

**Postoperative Care**

The wrist is immobilized until union is achieved. Rehabilitation is initiated once the splint is removed around week 6.

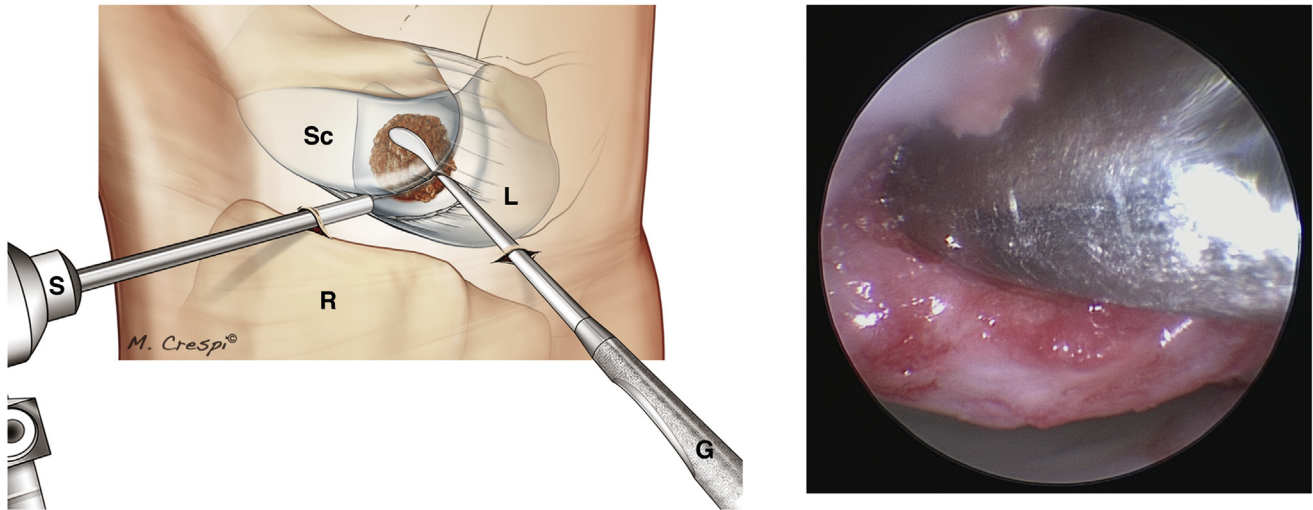
**Discussion**

Intraosseous ganglia cysts of the lunate are relatively rare but nonetheless represent a cause of chronic wrist pain, stiffness, or loss of strength.<sup>6</sup> This etiology must be well known not to miss the diagnosis, which is rendered quite easily through simple radiological examination such as plain radiography, MRI, or CT.<sup>12,13</sup> Although most ganglia are often asymptomatic,<sup>7</sup> complications such as lunate wall perforation or fracture, and even secondary flexor tendon injury,<sup>14</sup> can occur and be responsible for a mild to severe handicap of the wrist.<sup>2</sup>



**Fig 3.** Bone graft application (right wrist). This step is performed in a dry environment. Scope in the 1-to-2 portal, bone graft is brought into the lunate with a trocar through the 3-to-4 portal. The bone graft is inserted into a trocar, and the trocar’s tip is placed in the cyst cavity. The graft is pushed into the trocar with a blunt guide wire until the cyst cavity is filled. Abbreviations: L, lunate; R, radius; Sc, scaphoid; S, scope; T, trocar.



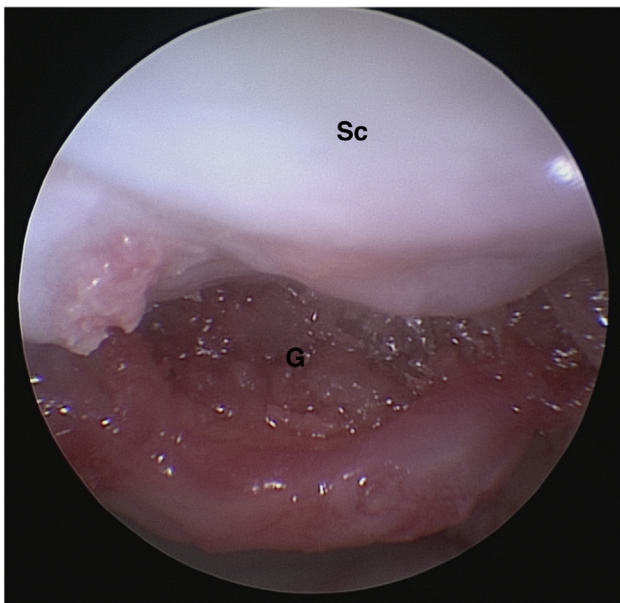


**Fig 4.** Bone graft application (right wrist). Scope in the 1-to-2 portal, bone graft is pushed into the cyst cavity with a blunt guide wire until completely filled. Abbreviations: G, blunt guide wire; L, lunate; R, radius; Sc, scaphoid; S, scope.

Intraosseous ganglia can occur or coexist in other carpal bones, usually scaphoid, capitate, and triquetrum; multiple locations are not rare.<sup>1,3</sup> Bilateral presentation has been noted in some cases.<sup>1</sup> The typical population is rather young (25 to 40 years), with female predominance ( $\leq 80\%$  in some series).<sup>1,5,15</sup> Open procedures of curettage and bone grafting have been the standard treatment for many years, enabling good results with low recurrence rates. The open dorsal approach, however, leads to frequent stiffness and persistent pain.<sup>1,3-5,16</sup>

Less invasive techniques using wrist arthroscopy have been more recently described. Through classic dorsal portals, the ILBG can be visualized, curetted, and grafted in a proper fashion. Studies have reported satisfactory outcomes, with very low recurrence rate and good functional results.<sup>6,7,11,17-19</sup> Several arthroscopic techniques have been reported for ILBG approach and treatment. Ashwood and Bain<sup>11</sup> and Bain et al.<sup>6</sup> proposed direct drilling of the lunate, either dorsal or volar, under fluoroscopic control (respectively 8 and 10 cases); Bhatia<sup>18</sup> suggested a similar direct “cystoscopy” through cartilage drilling (1 case), along with Cerlier et al.,<sup>7</sup> who also performed direct transosseous approach on the articular side of the lunate, the location of the cyst beforehand specified on CT (4 cases). Rimokh et al.<sup>17</sup> recently reported a comparable method (7 cases). Curettage and bone grafting (harvested from either distal radius or iliac crest) are performed as standard steps by all authors. Some have proposed injection of phosphate bone cement, but only in open techniques.<sup>19,20</sup>

This present study describes an approach for ILBG, passing through the proximal portion of the scapholunate ligament, with the scope in the 1-to-2 portal and instrumentation through the 3-to-4 portal (Video 1; Figs 1 through 4), thus preserving all the lunate cartilage of both radiocarpal and midcarpal surfaces. Scapholunate stability is ensured by the volar and dorsal portions of the scapholunate ligament, along with the dorsal capsulo-scapholunate septum.<sup>21</sup> The proximal (or intermediate) portion of the scapholunate ligament being anecdotic from a biomechanical perspective,<sup>22</sup> it can be used a harmless passage to the lateral wall of the lunate, which is very often opened by the cyst. This approach allows a quite easy and direct access to the ILBG. The rest of the procedure is straightforward: curettage and bone grafting (from distal radius using a



**Fig 5.** Final aspect of the graft (left wrist). Scope in the 1-to-2 portal, final aspect of the lunate grafted cyst cavity. Abbreviations: G, graft; Sc, scaphoid.

Jamshidi trocar; BD, Franklin Lakes, NJ) are performed through this specific approach, similarly to other techniques.<sup>17</sup>

Wrist arthroscopy is not without risks, and it demands strong experience and mastery before achieving it safely.<sup>23</sup> It also requires logistics and is not the most cost-effective solution for ILBG treatment.<sup>24</sup> Nevertheless, it seems to be an easy and reliable technique, avoiding the risks of open treatment.

### Conclusion

This is an easy, and accurate approach avoiding any damage to the major cartilage surfaces of the lunate, with easy and reliable access to the ILBG, allowing cyst curettage and autologous bone graft in a proper and noninvasive way.

### References

1. Uriburu IJ, Levy VD. Intraosseous ganglia of the scaphoid and lunate bones: Report of 15 cases in 13 patients. *J Hand Surg Am* 1999;24:508-515.
2. Osagie L, Gallivan S, Wickham N, et al. Intraosseous ganglion cysts of the carpus: Current practice. *Hand (N Y)* 2015;10:598-601.
3. Ikeda M, Oka Y. Cystic lesion in carpal bone. *Hand Surg* 2000;5:25-32.
4. Tham S, Ireland DC. Intraosseous ganglion cyst of the lunate: diagnosis and management. *J Hand Surg Br* 1992;17:429-432.
5. Waizenegger M. Intraosseous ganglia of carpal bones. *J Hand Surg Br* 1993;18:350-355.
6. Bain GI, Turner PC, Ashwood N. Arthroscopically assisted treatment of intraosseous ganglions of the lunate. *Tech Hand Up Extrem Surg* 2008;12:202-207.
7. Cerlier A, Gay A-M, Levadoux M. Arthroscopic treatment of intraosseous ganglion cyst of the lunate bone. *Arthrosc Tech* 2015;4:e513-e518.
8. Kligman M, Roffman M. Bilateral intraosseous ganglia of the scaphoid and lunate bones. *J Hand Surg Br* 1997;22:820-821.
9. Fontaine C, Wavreille G, Aumar A, et al. [Osseous vascular anatomy in the hand and wrist]. *Chir Main* 2010;29:S11-S20 (suppl 1).
10. Mathoulin C. *Wrist arthroscopy techniques*. Stuttgart, Germany: Thieme, 2015.
11. Ashwood N, Bain GI. Arthroscopically assisted treatment of intraosseous ganglions of the lunate: A new technique. *J Hand Surg Am* 2003;28:62-68.
12. Paparo F, Fabbro E, Piccazzo R, et al. Multimodality imaging of intraosseous ganglia of the wrist and their differential diagnosis. *Radiol Med* 2012;117:1355-1373.
13. Dumas P, Georgiou C, Chignon-Sicard B, et al. Kystes synoviaux intraosseux du carpe: Intérêt de la tomodensitométrie systématique pour l'évaluation du risque fracturaire. *Chir Main* 2013;32:3-7.
14. Yamazaki H, Kato H, Murakami N. Closed rupture of the flexor tendons of the index finger caused by a pathological fracture secondary to an intraosseous ganglion in the lunate. *J Hand Surg Eur* 2007;32:105-107.
15. Calcagnotto G, Sokolow C, Saffar P. [Intraosseous synovial cysts of the lunate bone: Diagnostic problems]. *Chir Main* 2004;23:17-23.
16. Mogan JV, Newberg AH, Davis PH. Intraosseous ganglion of the lunate. *J Hand Surg Am* 1981;6:61-63.
17. Rimokh J, Najjari H, Rotari V, et al. Arthroscopy-assisted treatment of scaphoid and lunate cysts: Clinical evaluation of 7 cases. *Hand Surg Rehabil* 2018;37:358-362.
18. Bhatia DN. Direct "cystoscopic" approach for arthroscopic decompression of an intraosseous ganglion of the lunate. *Arthrosc Tech* 2015;4:e223-e229.
19. Li S, Sun C, Zhou X, et al. Treatment of intraosseous ganglion cyst of the lunate: A systematic review. *Ann Plast Surg* 2019;82:577-581.
20. Yajima H, Murata K, Kawamura K, et al. Treatment of intraosseous ganglia and bone cysts of the carpal bones with injectable calcium phosphate bone cement. *Hand Surg* 2008;13:167-173.
21. Overstraeten L, Camus E, Wahegaonkar A, et al. Anatomical description of the dorsal capsulo-scapholunate septum (DCSS)—Arthroscopic staging of scapholunate instability after DCSS sectioning. *J Wrist Surg* 2013;2:149-154.
22. Sokolow C, Saffar P. Anatomy and histology of the scapholunate ligament. *Hand Clin* 2001;17:77-81.
23. Leclercq C, Mathoulin C, Members of EWAS. Complications of wrist arthroscopy: A multicenter study based on 10,107 arthroscopies. *J Wrist Surg* 2016;5:320-326.
24. Pang EQ, Zhang S, Harris AHS, et al. Cost minimization analysis of ganglion cyst excision. *J Hand Surg Am* 2017;42:750.e1-750.e4.
25. Corella F, Ocampos M, Cerro M, et al. Volar central portal in wrist arthroscopy. *J Wrist Surg* 2016;5:80-90.