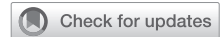

Aortoscopy in pressurized aortic root during valve-sparing root replacement: A useful maneuver



Rong Hui (Misté) Chia, MBBS (Hons), MTrauma (HD), GradDipClinUS,^a and Pragnesh Joshi, MBBS, MS, DNB, MCh, FRACS,^{a,b} Nedlands and Perth, Australia

From the ^aUniversity of Western Australia, Perth, Australia; and ^bDepartment of Cardiothoracic Surgery, Sir Charles Gairdner Hospital, Nedlands, Australia.

Disclosures: The authors reported no conflicts of interest.

The *Journal* policy requires editors and reviewers to disclose conflicts of interest and to decline handling or reviewing manuscripts for which they may have a conflict of interest. The editors and reviewers of this article have no conflicts of interest.

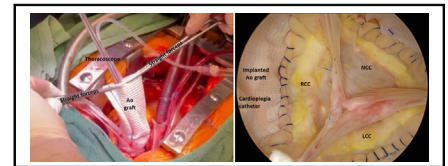
Received for publication Dec 29, 2022; revisions received May 6, 2023; accepted for publication May 22, 2023; available ahead of print May 30, 2023.

Address for reprints: Pragnesh Joshi, MBBS, MS, DNB, MCh, FRACS, Sir Charles Gairdner Hospital, Hospital Ave, Nedlands, WA 6009, Australia (E-mail: pragnesh_joshi@yahoo.com).

JTCVS Techniques 2023;20:20-3
2666-2507

Copyright © 2023 The Authors. Published by Elsevier Inc. on behalf of The American Association for Thoracic Surgery. This is an open access article under the CC BY-NC-ND license (<http://creativecommons.org/licenses/by-nc-nd/4.0/>).

<https://doi.org/10.1016/j.jtc.2023.05.009>



Aortoscope setup and illustration of good coaptation of aortic cusps in a pressurized aortic root.

CENTRAL MESSAGE

We describe a method of performing direct aortic valve inspection via aortoscopy to assess cusp geometry and function in a pressurized root during valve-sparing root replacement before cross-clamp removal.

Video clip is available online.

Intraoperative aortic valve (AV) inspection upon completion of valve-sparing root replacement (VSRR) plays an important role in confirming leaflet symmetry and the absence of regurgitation. Although transesophageal echocardiography (TEE) is a reliable method for assessing the AV, it does not avoid the need for a second bypass run and graft re-clamping if further surgical revision is necessary. Therefore, it is essential to have intraoperative methods to assess the AV prior to cross-clamp removal. Currently described methods include the use of a dedicated cusp caliper¹ and the saline test (also known as the sealing test)^{2,3} conducted with manual retraction of AV commissural posts radially. However, these assessments have some drawbacks because they are performed in unpressurized aortic roots, rely on the amount of traction applied on suspension sutures by assistants, and visual inspection relies on the experience of the surgeon. Herein, we describe a technique to inspect the AV using a thoracoscope in a pressurized root before bypass wean, which can supplement the currently available methods (Video 1). A pressurized root allows equal distribution of tension along

the leaflet edges and distends the body of leaflets, making the assessment of AV leaflet coaptation and symmetry easier.

SURGICAL TECHNIQUE

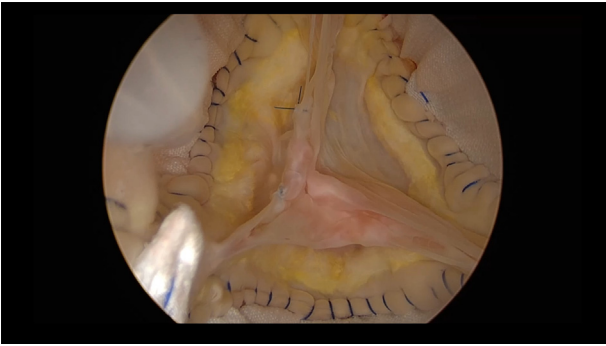
We routinely perform VSRR through reimplantation. Video-assisted AV inspection may be performed before or after coronary button reimplantation and distal aortic anastomosis.

Equipment and Setup

A cardioplegia catheter (Calmed R) is connected directly to the cardioplegia line (Figure 1, A). A 5-mm 0° thoracoscope is set up for use. Both the cardioplegia catheter and scope are held vertically through the implanted aortic graft. The distal end of the implanted aortic graft is clamped horizontally using 2 straight 14-cm hemostat forceps (Figure 1, B).

Controlled Aortic Root Pressurization

Crystalloid cardioplegia (if the maneuver is performed after coronary reimplantation) or normal saline is used to allow a clear view of the AV. It is delivered into the aortic root via the soft cardioplegia catheter to induce a diastolic pressure of 80 to 120 mm Hg within the implanted graft,



VIDEO 1. Aortoscopy for direct aortic valve inspection to assess cusp geometry and function in a pressurized root during valve-sparing root replacement prior to cross-clamp removal. Video available at: [https://www.jtcvs.org/article/S2666-2507\(23\)00183-9/fulltext](https://www.jtcvs.org/article/S2666-2507(23)00183-9/fulltext).

with constant pressure monitoring by the perfusionist. Alternatively, a 3-way valve may be connected to the cardioplegia catheter to monitor aortic root pressure. A small leak should be allowed at the distal end of the implanted aortic graft, where haemostat forceps are applied, to avoid excessive aortic root pressurization in cases where coronary reimplantation is not yet completed.

Final Inspection of AV

This technique enables clear magnified view of the AV under pressure (Figures 2 and E1). The AV is assessed for gross competency, coaptation symmetry, and cusp prolapse. Any additional repair is added if necessary. At the completion of VSRR and subsequent bypass wean, TEE is performed again to confirm AV geometry and function.

DISCUSSION

Engaging all leaflets can be difficult in patients with excess leaflet tissues, and it is sometimes challenging to decide which leaflet requires plication. The technique described above involves evaluating the AV in a pressurized aortic root under near-normal physiological root pressure. It enables real-time AV cusp assessment whilst under controlled hydraulic pressure that stretches all leaflets simultaneously for clear visualization of leaflet coaptation and symmetry. Correlation may be made with preoperative TEE findings. This allows easier identification if any further AV repair is needed before bypass wean, thereby reducing the need for a second bypass run for surgical revision and avoiding its associated morbidities. Moreover, this technique is relatively simple, reproducible, and can be completed fairly rapidly.

The described video-assisted AV inspection may be completed before or after coronary reimplantation. In the former, careful monitoring of the aortic root pressure using a pressure line and allowing a small leakage at the level of haemostat clamps can prevent excessive root pressure build-up. This is our preferred method as the AV remains clearly visible. Alternatively, this technique may be performed after coronary reimplantation to reduce the risk of overpressurizing the root. However, there may be constant coronary ostia backflow impeding a clear view of the AV. Saline or crystalloid cardioplegia infusion should then be continued until the AV becomes clearly visible.

Although the aortic root is pressurized with this technique, the ventriculoaortic junction and basal ring are not fully distended. The impact of this limitation is yet to be determined. The main purpose of publishing this method

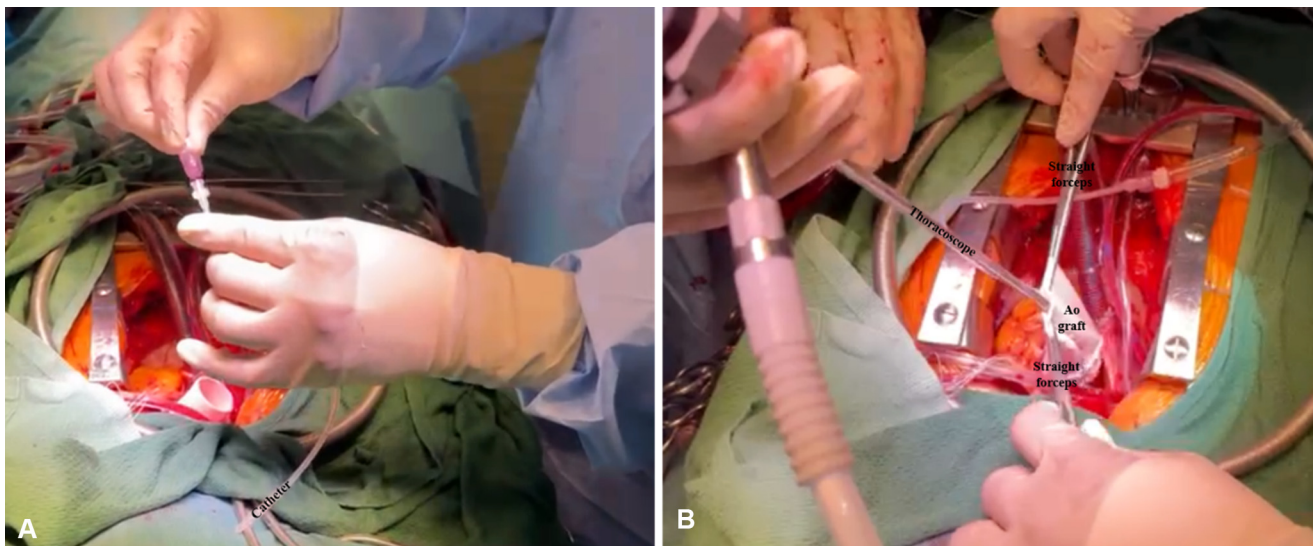


FIGURE 1. A, A soft tip catheter being connected to the cardioplegia line used subsequently for induction of diastolic pressure. B, The final setup of equipment for our technique. Ao, Aortic.

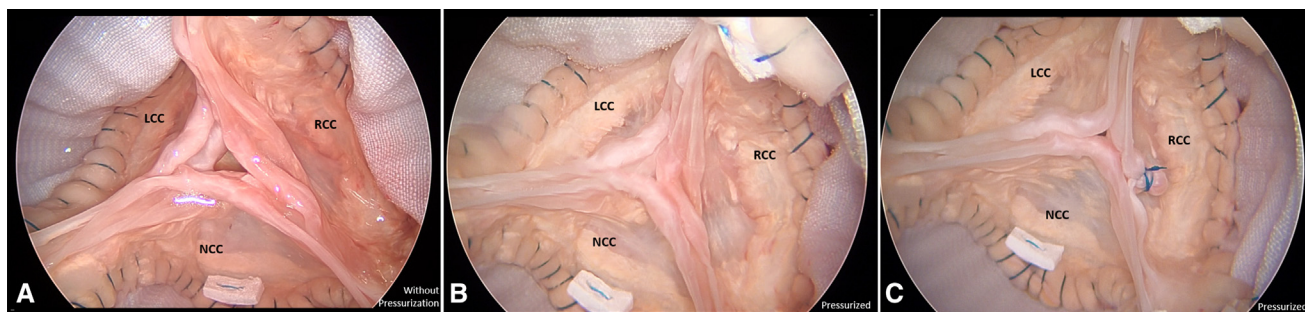


FIGURE 2. The effect of root pressurization on the aortic valve during final inspection during reimplantation. A, Standard view of the aortic valve and root post-reimplantation without root pressurization. B, View of the aortic valve and root using aortoscopy in a pressurized root showing redundancy only in right coronary cusp (*RCC*) requiring plication. C, Adequate *RCC* plication with good aortic valve coaptation in all 3 leaflets in a pressurized root. *LCC*, Left coronary cusp; *NCC*, noncoronary cusp.

is to add an additional tool to assess the AV over currently available methods.

We believe this simple method may assist surgeons to perform a more reliable examination of the reimplanted AV. It adds as a valuable adjunct to currently used techniques to assess leaflets post-repair.

References

1. Schäfers HJ, Bierbach B, Aicher D. A new approach to the assessment of aortic cusp geometry. *J Thorac Cardiovasc Surg.* 2006;132:436-8.
2. Sultan I, Komlo CM, Bavaria JE. How I teach a valve sparing root replacement. *Ann Thorac Surg.* 2016;101:422-5.
3. Mastrobuoni S, de Kerchove L, Navarra E, Jahanyar J, van Saane S, Segreto A, et al. Valve sparing-aortic root replacement with the reimplantation technique in acute type A aortic dissection. *Ann Cardiothorac Surg.* 2016;5:397-400.

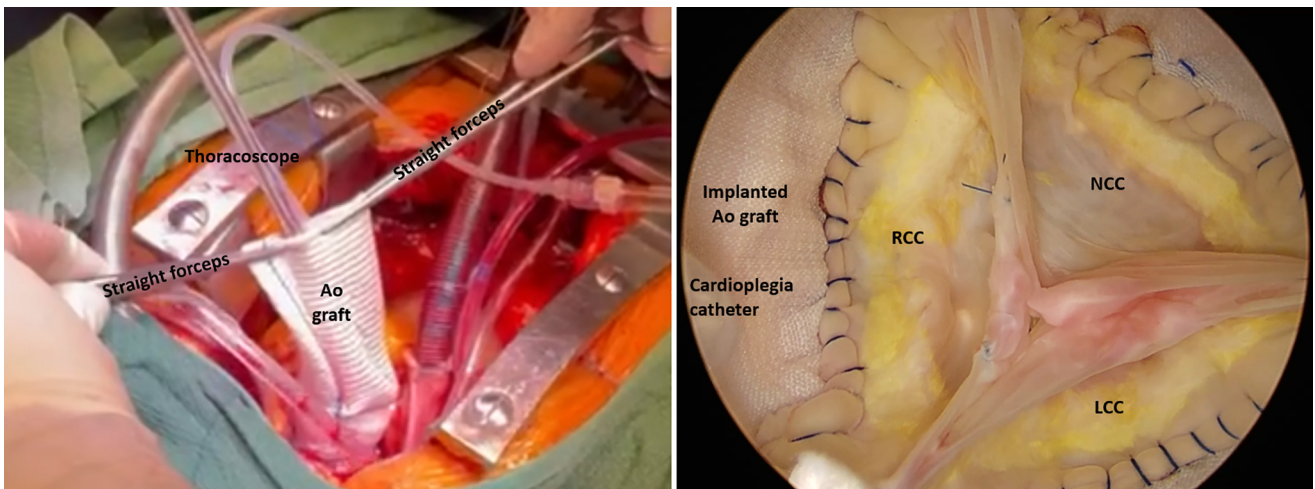


FIGURE E1. The aortoscope setup and illustration of good coaptation of aortic cusps in a pressurized aortic root. *Ao*, Aortic; *RCC*, right coronary cusp; *NCC*, noncoronary cusp; *LCC*, left coronary cusp.