



King Saud University  
The Saudi Dental Journal

www.ksu.edu.sa  
www.sciencedirect.com



CASE REPORT

# Preserving esthetics, occlusion and occlusal vertical dimension in a patient with fixed prostheses seeking dental implant treatment



Abdulaziz Al Baker, Syed Rashid Habib\*, Mohammad D. Al Amri

Department of Prosthetic Dental Sciences, College of Dentistry, King Saud University, Riyadh, Saudi Arabia

Received 25 February 2015; accepted 23 May 2016

Available online 18 October 2016

## KEYWORDS

Esthetics;  
Occlusal vertical dimension;  
Dental implants;  
Fixed partial dentures;  
Occlusion;  
Immediate dentures

**Abstract** The preservation of esthetics and occlusal vertical dimension is critical in patients with existing full-arch tooth-retained fixed prostheses. This clinical report describes the provision of a maxillary immediate complete denture in a patient with a maxillary full-arch fixed dental prosthesis over nonviable teeth. The existing fixed dental prosthesis was used in the fabrication of the maxillary immediate complete denture to preserve esthetics. The technique involved recording and preservation of the occlusal vertical dimension and occlusion of the existing prosthesis. The technique is simple, quick, cost-effective and less challenging clinically and technically.

© 2016 The Authors. Production and hosting by Elsevier B.V. on behalf of King Saud University. This is an open access article under the CC BY-NC-ND license (<http://creativecommons.org/licenses/by-nc-nd/4.0/>).

## 1. Introduction

The demand for dental treatment from patients with missing teeth is increasing worldwide. Various types of treatment, including the use of conventional complete and partial dentures and tooth- and implant-supported fixed and removable prostheses, may be indicated for partially or completely eden-

tulous patients. The purpose of dental treatment is to respond to unique patients' needs. Thus, treatment should be highly individualized according to the patient and the disease (Allen et al., 2011; Jivraj and Chee, 2006; Nadig et al., 2011; Shahghaghian et al., 2014; Zitzmann et al., 2010).

The treatment of patients seeking dental implants and presenting with failed fixed dental prostheses is challenging. Many concerns arise in such cases, including preservation of the esthetics and occlusal vertical dimension (OVD) of the existing prosthesis, preservation of the horizontal relationship of the dentition, atraumatic removal of the existing prosthesis (alone, or with the abutment teeth in cases of poor prognosis), surgical placement of dental implants, and temporization of the dentition with a provisional fixed or removable prosthesis. Each of these factors is important for the clinical and technical success of treatment (Chaimattayompol et al., 2002; Palmer et al., 2000). With the advent of dental implant-supported prostheses and the increased life expectancy of the elderly population, the

\* Corresponding author at: Department of Prosthetic Dental Sciences, College of Dentistry, King Saud University, P.O. Box 60169, King Abdullah Road, Riyadh 11545, Saudi Arabia. Fax: +966 1 467 8548.

E-mail address: [rashidhabib@hotmail.com](mailto:rashidhabib@hotmail.com) (S.R. Habib).  
Peer review under responsibility of King Saud University.



Production and hosting by Elsevier

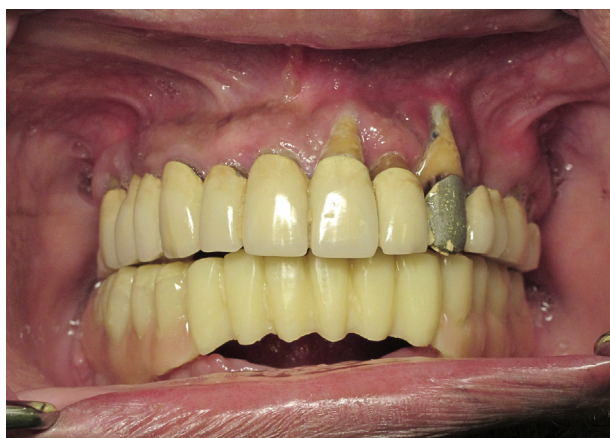restoration of mastication, phonetic function, and esthetics in elderly patients is a challenging task, even for the experienced clinician. However, the use of implants and restorations has reached a reasonably predictable level of success (Kammeyer et al., 2002). This case report illustrates a method by which a failed fixed prosthesis was converted into complete denture in a middle-aged patient.

## 2. Case report

A 43-year-old man reported to the Department of Prosthodontics, College of Dentistry, King Saud University, Riyadh, Kingdom of Saudi Arabia, with the chief complaint of tooth mobility. On general physical examination, the patient seemed to be in good general health. He had maxillary (14-unit) and mandibular (12-unit) full-arch splinted fixed prostheses (Fig. 1). Detailed clinical and radiographic examinations revealed generalized advanced periodontitis at the 11 maxillary abutment teeth (Fig. 2). The patient had used the maxillary prosthesis for 9 years, and was satisfied with its esthetics despite chipped porcelain at tooth #23 (Fig. 1). The occlusal vertical dimension and horizontal jaw relationship were found to be satisfactory, but the patient's oral hygiene status was not satisfactory. No other intraoral pathology was observed, and salivary flow was adequate.

A diagnosis of maxillary fixed dental prosthesis failure was made. The treatment options available initially were removal of the prosthesis and extraction of all maxillary teeth, followed by provision of an immediate complete denture and then a permanent conventional complete denture; or provision of an immediate complete denture over implants, followed by provision of a screw-retained implant-supported fixed prosthesis.

The patient was eager to receive implant treatment, but refused immediate provision of a new denture; he wanted to preserve the esthetics of the existing maxillary fixed prosthesis. The prosthodontist and implant surgeon discussed the case again in detail, and formulated a new treatment plan based on the patient's demand and consideration of his local and general health condition. This plan included the removal of the existing maxillary fixed prosthesis, extraction of all maxillary teeth, placement of six maxillary implants, and utilization of the existing fixed prosthesis in the fabrication of an immedi-



**Figure 1** Preoperative frontal view of the maxillary fixed prosthesis.

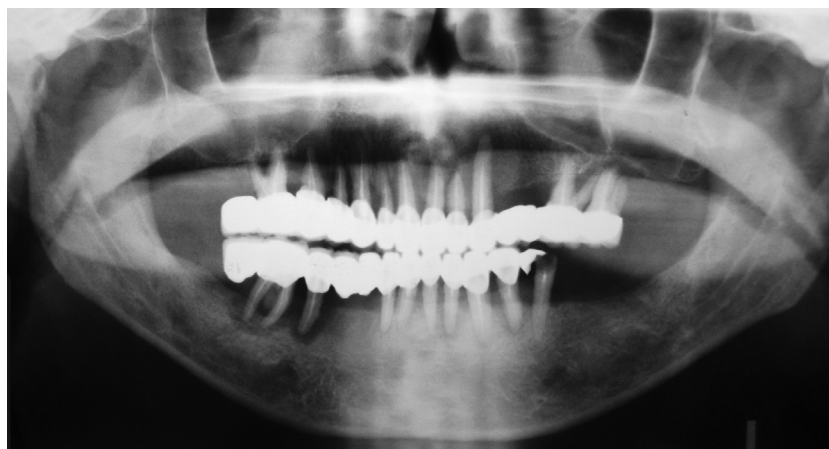
ate maxillary complete denture to be fitted over the implants. This approach preserved the maxillary esthetics and involved the provision of an implant-supported fixed prosthesis after complete healing and osseointegration of the dental implants.

The risks and benefits of all options were explained to the patient, and he accepted the modified treatment option. A final comprehensive treatment plan was drafted. The objective was to preserve esthetics and the vertical and horizontal jaw relationships by including the existing fixed dental prosthesis in the interim complete denture. The initial diagnostic phase included the improvement of oral hygiene and review of the patient's history and medical condition.

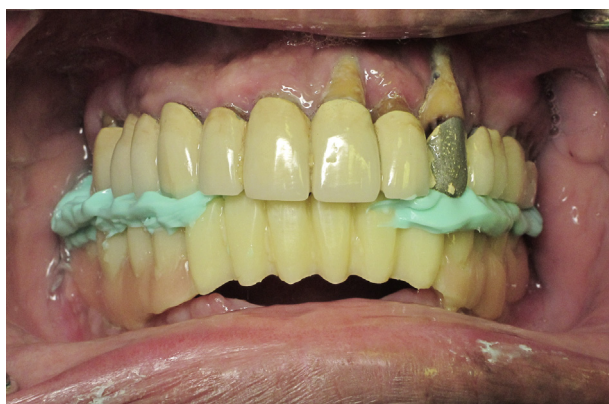After the elimination of active disease and potential causes of future disease, the surgical and prosthetic rehabilitation phase was initiated. The vertical and horizontal dimensions of occlusion were analyzed thoroughly. Before removal of the maxillary fixed prosthesis, a silicone bite registration index (Imprint™ Bite Registration Material; 3M ESPE, Minnesota, USA) and facebow record were made to document the jaw relationships (Fig. 3). Using Niswonger's method (Millet et al., 2010), marks were placed on the tip of the nose and chin to record the vertical dimension of occlusion. After informing the patient about possible complications and obtaining his consent, the maxillary prosthesis was removed under local anesthesia (Xylestesin™-A, 3M ESPE, Seefeld, Germany) using a crown remover and forceps. The prosthesis was removed without damage, and teeth #15, 21, and 27 were extracted along with it (Fig. 4). These teeth were then removed from the prosthesis, and the prosthesis was cleaned and disinfected in the laboratory and stored for future use (Fig. 5). All remaining maxillary teeth were extracted (Fig. 5), and the patient was then transported to the implant surgeon's clinic, where six implants were placed (Fig. 6).

The patient returned to our clinic for the fabrication of the immediate maxillary complete denture. The fixed prosthesis was seated in the patient's mouth with the help of the previously made silicone putty index (Fig. 7). The patient was asked to close the jaws lightly, and the vertical dimension of occlusion was verified with reference to the marks placed before prosthesis removal. Using polyvinyl siloxane bite registration material (Imprint™; 3M ESPE), the relationship between the intaglio surface of the old prosthesis and the maxilla was recorded with the same vertical dimension of occlusion (Fig. 8). An alginate (Jeltrate®; Dentsply, Surrey, UK) maxillary impression was then made carefully (Fig. 9). In the laboratory, maxillary and mandibular casts were poured with type II gypsum stone (Shera; Werkstoff Technologie GmbH, Lemförde, Germany). The upper cast was then mounted on an articulator with the lower cast, utilizing the previously obtained maxillary and mandibular records, along with the maxillary prosthesis. A wax-up of the immediate maxillary complete denture, incorporating the old prosthesis, was made. Investment of the denture in flasks, de-waxing, packing of the mold with heat-cured acrylic resin (Dentsply), and curing of the denture using a short cycle (Athar et al., 2009) were then performed in the laboratory. After finishing and polishing, the denture was ready for insertion (Fig. 10).

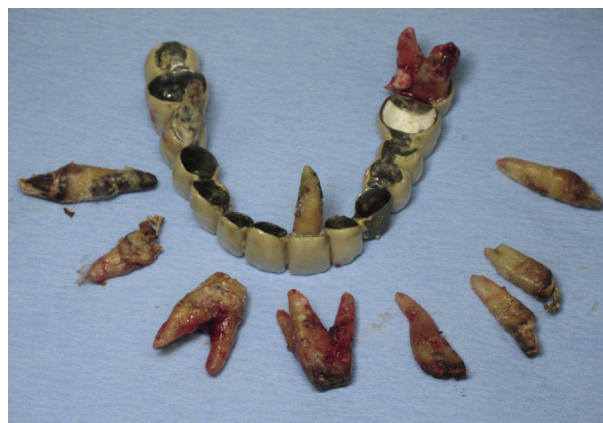In the clinic, the denture was then tried in the patient's mouth (Fig. 11). Pressure-indicating paste (Mizzy Inc., New Jersey, USA) was used to identify and address any areas of pressure caused by the intaglio surface of the denture. The occlusion was verified and the immediate denture was delivered to the



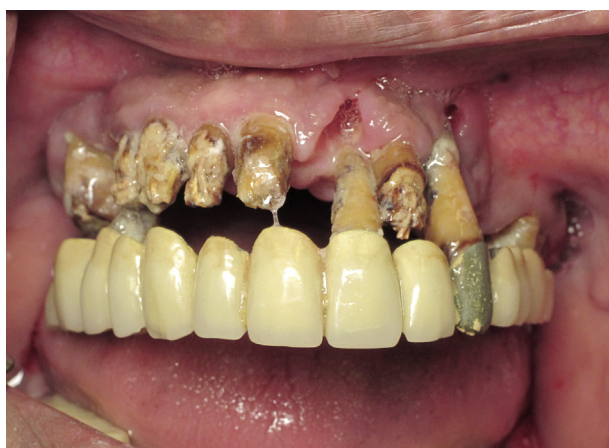**Figure 2** Pretreatment panoramic radiograph.



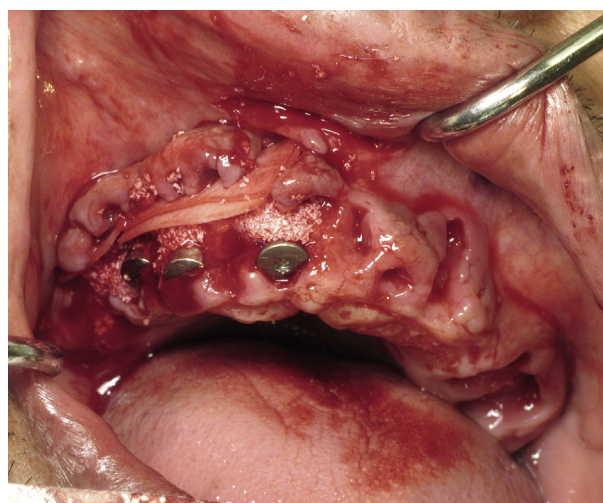
**Figure 3** Recording the occlusal relation with the silicone index.



**Figure 5** Extracted teeth along with the prosthesis.



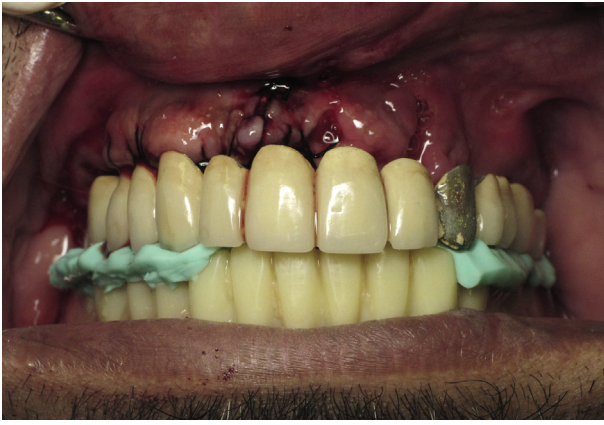**Figure 4** Removal of the maxillary fixed prosthesis.



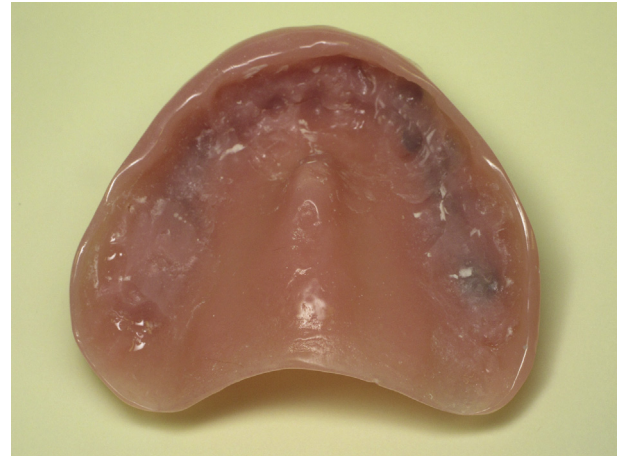**Figure 6** Maxillary arch after extractions and implant placement.

patient with instructions for use (Fig. 12) (Holt, 1986). The patient was asked to report back for review and follow up 24 h and 1 week later. At the follow-up visits, the patient verified that he was satisfied with the overall function, esthetics, occlusion, and phonetic function of the new denture. This method is simple and utilizes materials and equipment com-

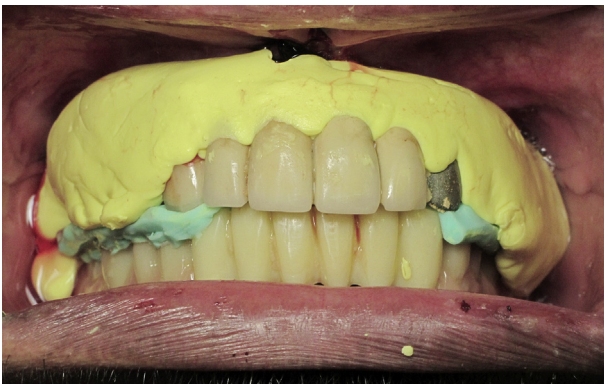
monly available in almost all dental surgery facilities. The patient was supposed to use this denture for 3 months, before the third phase of treatment. The various clinical and technical stages of the treatment are summarized in Table 1.



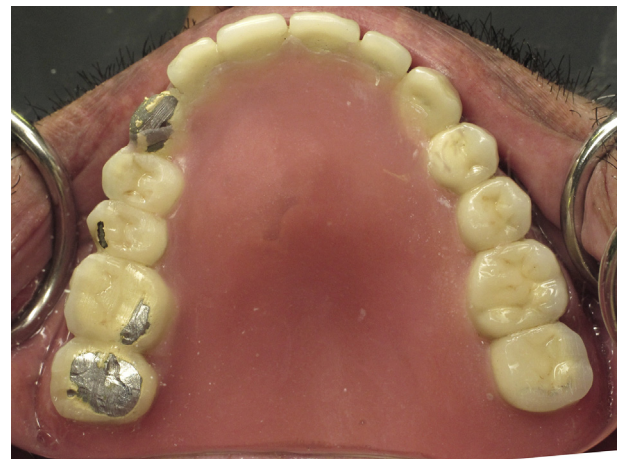**Figure 7** Verification of vertical dimension of occlusion.



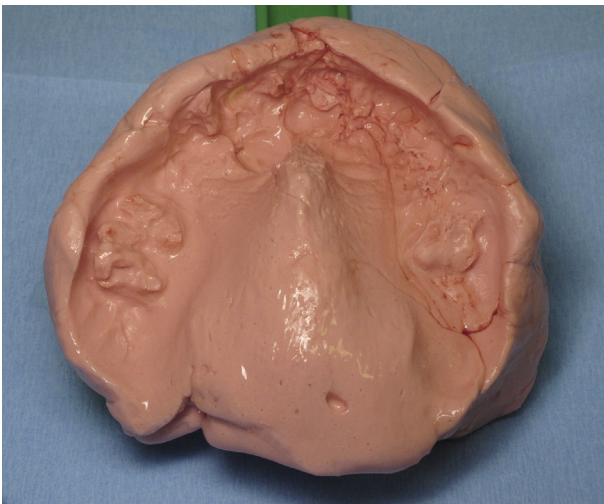
**Figure 10** Intaglio surface of immediate complete denture.



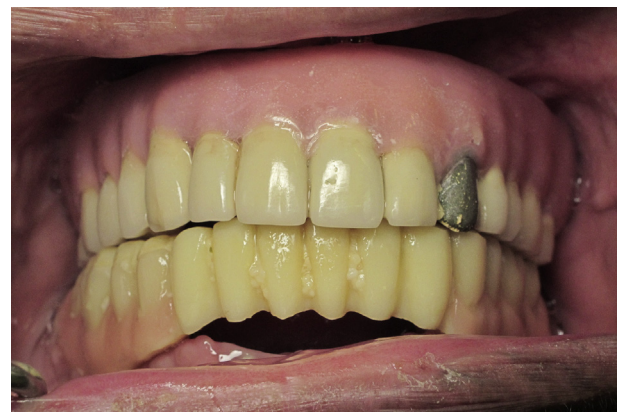**Figure 8** Recording interarch relationship using the old prosthesis and silicone bite registration.



**Figure 11** Occlusal and polished surfaces of maxillary immediate complete denture.



**Figure 9** Alginate wash impression of the maxillary arch.

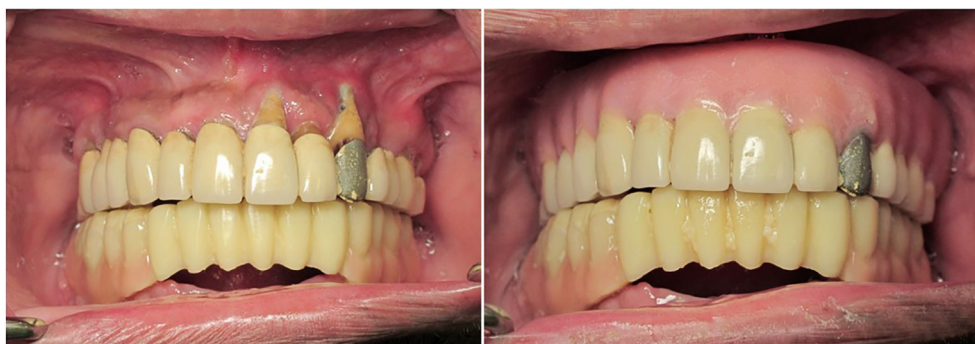

**Figure 12** Frontal view of maxillary immediate complete denture.

### 3. Discussion

Today, patients have high expectations regarding esthetics, in addition to function (Mehl et al., 2011). In patients seeking dental implant treatment, provisionalization and preservation

of the esthetics of the existing dentition in the esthetic zone are difficult tasks for prosthodontists. Diagnosis and treatment planning should be emphasized; in most situations, proper diagnosis dictates the appropriate treatment plan



**Figure 13** Preoperative (left) and post-treatment (right) photographs.

**Table 1** Clinical and Laboratory procedures for conversion of fixed into removable prosthesis.

Steps	Stage	Detail	Suggestions
1.	Clinical	Diagnosis and treatment plan If the pt. is suitable, making of primary impressions	List those aspects of the existing prosthesis that will be modified or used in the future prosthesis
2.	Lab	Construct primary diagnostic casts	
3.	Clinical	Face bow record and centric relation using silicone index Recording and marking the OVD with Niswonger's method	It is important to mark and measure the vertical dimension of occlusion
4.	Clinical	Fixed Prosthesis Removal and extraction of all the abutment teeth Implant placement. Suturing of the extraction sites if required	Careful removal of the fixed prosthesis in order to preserve its esthetics
5.	Clinical	Recording wash impression of the upper edentulous arch	Record the wash impression with a free flowing elastic impression material like alginate
6.	Clinical	Verifying the vertical and horizontal jaw relations with the index made at step 2	The marking should be preserved and not washed with the surgical procedures
7.	Lab	Mounting, Final wax up, Flasking, Dewaxing, Packing of acrylic, Curing, Finishing and Polishing of dentures	If required, wax can be added to the palate in the upper arch and wax up is finalized for a removable prosthesis before flasking
8.	Clinical	Denture insertion	Selective spot grinding of the teeth intraorally Removal of the pressure spots from the intaglio surface of denture with the use of pressure indicating paste
9.	Clinical	Patient follow up	

(Chaimattayompol et al., 2002; Palmer et al., 2000). Coordination among the prosthodontist, the implant surgeon, and the dental technician is critical for successful conversion of an existing fixed dental prosthesis into an immediate denture in the esthetic zone. Inadequately planned or executed treatment fails to meet ideal treatment goals and achieve patient satisfaction (Kammeyer et al., 2002; Strong, 2012).

The technique described here preserves the esthetics, occlusion, and occlusal vertical dimension by transforming the patient's existing fixed dental prosthesis into an immediate complete denture over the submerged dental implants (Fig. 13). It also eliminates interim implant placement and allows healing prior to definitive implant abutment selection. The patient wore the prosthesis for 3 months, until healing of the tissues and implant osseointegration were completed.

An alternative approach would be to fabricate an immediate maxillary complete denture, which would require major alteration of the diagnostic cast and might not produce an esthetic result that is perceivable and acceptable to the patient (St George et al., 2010). The technique described in this case report gives the patient the option of preserving the same esthetics, with the added advantage of preserving the occlusion and occlusal vertical dimension. Ideal retention in the maxillary immediate denture may not be achievable in such cases. The goals of treatment should be realistic and achievable, and take into account the patient's esthetics, confidence, and comfort, as well as function and cost. The patient should be fully involved in treatment decisions.

#### 4. Conclusion

This report describes the conversion of a maxillary full-arch fixed dental prosthesis into an interim complete denture to function during implants healing. The technique is simple and has the advantages of preserving occlusion, occlusal vertical dimension, and esthetics.

#### Conflict of interest

There is no conflict of interest.

#### References

Allen, P.F., McKenna, G., Creugers, N., 2011. Prosthodontic care for elderly patients. *Dent. Update* 38. 460-2,465-6,469-70.

- Athar, Z., Juszczak, A.S., Radford, D.R., Clark, R.K., 2009. Effect of curing cycles on the mechanical properties of heat cured acrylic resins. *Eur. J. Prosthodont. Restor. Dent.* 17 (2), 58–60.
- Chaimattayompol, N., Emtiaz, S., Woloch, M.M., 2002. Transforming an existing fixed provisional prosthesis into an implant supported fixed provisional prosthesis with the use of healing abutments. *J. Prosthet. Dent.* 88, 96–99.
- Holt Jr., R.A., 1986. Instructions for patients who receive immediate dentures. *J. Am. Dent. Assoc.* 112 (5), 645–646.
- Jivraj, S., Chee, W., 2006. Transitioning patients from teeth to implants. *Br. Dent. J.* 201 (11), 699–708.
- Kammeyer, G., Proussaefs, P., Lozada, J., 2002. Conversion of a complete denture to a provisional implant-supported screw retained fixed prosthesis for immediate loading of a completely edentulous arch. *J. Prosthet. Dent.* 87, 473–476.
- Mehl, C.J., Harder, S., Kern, M., Wolfart, S., 2011. Patients' and dentists' perception of dental appearance. *Clin. Oral Invest.* 15 (2), 193–199. <http://dx.doi.org/10.1007/s00784-010-0393-y>. Epub 2010 Mar 16.
- Millet, C., Leterme, A., Jeannin, C., Jaudoin, P., 2010. Vertical dimension in the treatment of the edentulous patient. *Rev. Stomatol. Chir Maxillofac* 111 (5–6), 315–330.
- Nadig, R.R., Usha, G., Kumar, V., Rao, R., Bugalia, A., 2011. Geriatric restorative care – the need, the demand and the challenges. *J. Conserv. Dent.* 14 (3), 208–214.
- Palmer, R.M., Palmer, P.J., Newton, J.T., 2000. Dealing with esthetic demands in the anterior maxilla. *Periodontology* 2003 (33), 105–118.
- Shahghaghian, S., Taghva, M., Abduo, J., Bagheri, R., 2014. Oral health related quality of life of removable partial denture wearers and related factors. *J. Oral Rehabil.* <http://dx.doi.org/10.1111/joor.12221>.
- St George, G., Hussain, S., Welfare, R., 2010. Immediate dentures: 1. Treatment planning. *Dent. Update* 37 (2), 82–4, 86–8, 91.
- Strong, S.M., 2012. Conversion from fixed bridge to implant-supported restoration in the esthetic zone. *Gen. Dent.* 60 (3), 182–185.
- Zitzmann, N.U., Krastl, G., Hecker, H., Walter, C., Waltimo, T., Weiger, R., 2010. Strategic considerations in treatment planning: deciding when to treat, extract, or replace a questionable tooth. *J. Prosthet. Dent.* 104 (2), 80–91. [http://dx.doi.org/10.1016/S0022-3913\(10\)60096-0](http://dx.doi.org/10.1016/S0022-3913(10)60096-0).