

# Which is better for predicting pelvic lymph node metastases in patients with cervical cancer

## Fluorodeoxyglucose-positron emission tomography/computed tomography or a sentinel node biopsy? A retrospective observational study

Tomohito Tanaka, MD, PhD<sup>a,\*</sup>, Shun Sasaki, MD<sup>a</sup>, Hiromitsu Tsuchihashi, MD<sup>a</sup>, Yoshito Terai, MD, PhD<sup>a</sup>, Kazuhiro Yamamoto, MD, PhD<sup>b</sup>, Takashi Yamada, MD, PhD<sup>c</sup>, Masahide Ohmichi, MD, PhD<sup>a</sup>

### Abstract

Systematic pelvic lymph node resection may not be needed for patients with cervical cancer, especially in the early stage, if the pre- or intraoperative diagnosis of lymph node status is correct. The aim of this study was to evaluate the diagnostic accuracy of pelvic lymph node metastasis for fluorodeoxyglucose-positron emission tomography/computed tomography (FDG PET/CT) and sentinel node biopsy (SNB) of cervical cancer patients.

Forty-eight patients with cervical cancer were imaged with FDG PET/CT before radical hysterectomy and underwent an SNB followed by systematic pelvic lymph node dissection. The diagnostic accuracy for predicting pelvic node metastases for FDG PET/CT and SNB compared with the ultimate histologic status was analyzed.

Among 96 hemi-pelvises (HPs) in 48 patients, pelvic lymph node metastases were obtained in 12 HPs. The sensitivity of pelvic node metastases for FDG PET/CT and SNB was 8.3% and 75.0%, respectively. The specificity for FDG PET/CT and SNB was 97.6% and 94.0%, respectively. The negative predictive value for FDG-PET/CT and SNB was 88.2% and 100%, respectively.

SNB is more suitable for detecting pelvic node metastases than FDG PET/CT. The omission of systematic pelvic lymphadenectomy should be considered based on the findings of SNB, not FDG PET/CT.

**Abbreviations:** <sup>99m</sup>Tc = 99m-Technetium, BMI = body mass index, FDG PET/CT = fluorodeoxyglucose-positron emission tomography/computed tomography, FIGO = International Federation of Gynecology and Obstetrics, H&E = hematoxylin and eosin, HPs = hemi-pelvises, ICG = indocyanine green, IDC = indigocarmine, PLND = pelvic lymph node dissection, SD = standard deviation, SLN = sentinel lymph node, SNB = sentinel node biopsy.

**Keywords:** cervical cancer, lymph node metastasis, pelvic lymph node, PET, sentinel lymph node

### 1. Introduction

Pelvic lymph node dissection (PLND) remains an important surgical procedure in patients undergoing radical hysterectomy for cervical cancer. Although the lymph node status is not included in the current International Federation of Gynecology

and Obstetrics (FIGO) staging system,<sup>[1]</sup> lymph node metastasis is considered an important prognostic factor.<sup>[2–4]</sup> However, PLND may be associated with many complications, including vascular and nerve injury, increased blood loss, longer surgery, lymphocyst formation, deep venous thromboembolism, and lower limb lymphedema.<sup>[5–8]</sup> The frequency of lymph node metastasis is approximately 0% to 2% in stage IA cervical cancer, 11.5% to 22% in stage IB, 26.7% to 33% in stage IIA, and 39.2% to 63% in stage IIB<sup>[9–11]</sup>; systematic PLND may be omitted in cases of early disease.

To avoid the complications associated with systematic PLND, the sentinel lymph node (SLN) concept has been applied to the treatment of cervical cancer. Confirmation of this concept brings benefits to cervical cancer patients. Over the last decade, 18F-fluorodeoxyglucose (FDG) positron emission tomography/computed tomography (PET/CT) has become an increasingly important component of tumor staging by virtue of its ability to identify disease, including lymph node-involving distant disease and recurrent disease, in patients with cervical cancer. When pelvic lymph node metastasis can be pre- or intraoperatively diagnosed by a SLN biopsy (SNB) or FDG PET/CT, systematic PLND may not be needed.

The aim of this study was to evaluate the diagnostic accuracy of pelvic lymph node metastases for FDG PET/CT and SNB in patients with cervical cancer.

Editor: Shirish Shukla.

The authors have received no funding for this article.

The authors declare no conflict of interest. The authors alone are responsible for the content and writing of the paper.

<sup>a</sup> Department of Obstetrics and Gynecology, <sup>b</sup> Department of Radiology,

<sup>c</sup> Department of Pathology, Osaka Medical College, Takatsuki, Osaka, Japan.

\* Correspondence: Tomohito Tanaka, Department of Obstetrics and Gynecology, Osaka Medical College, 2–7, Daigaku-machi, Takatsuki, Osaka 569–8686, Japan (e-mail: gyn123@osaka-med.ac.jp).

Copyright © 2018 the Author(s). Published by Wolters Kluwer Health, Inc.

This is an open access article distributed under the terms of the Creative Commons Attribution-Non Commercial-No Derivatives License 4.0 (CCBY-NC-ND), where it is permissible to download and share the work provided it is properly cited. The work cannot be changed in any way or used commercially without permission from the journal.

Medicine (2018) 97:16(e0410)

Received: 8 October 2017 / Received in final form: 13 February 2018 /

Accepted: 16 March 2018

<http://dx.doi.org/10.1097/MD.00000000000010410>

## 2. Materials and methods

### 2.1. Participants

Between September 2013 and January 2016, a total of 48 Japanese cervical cancer patients who underwent preoperative FDG PET/CT and intraoperative sentinel node procedures at Osaka Medical College in Japan were retrospectively reviewed. Patients who met the following criteria were eligible for inclusion in the study: had cervical cancer with FIGO stage of IA2, IB, or IIA disease; underwent laparoscopic or abdominal radical hysterectomy including systematic PLND with or without bilateral salpingo-oophorectomy; underwent preoperative FDG PET/CT and an intraoperative SLB; and did not receive any treatment, including chemotherapy and radiotherapy, before surgery. Radical hysterectomy with systematic PLND was performed regardless of the detection and status of SLN. The present study was approved by the institutional review board, and the participants gave their written informed consent.

### 2.2. SLN mapping procedure

We previously reported the procedure of SLN mapping.<sup>[12]</sup> Briefly, all of the tracers were sub-mucosally injected into 4 quadrants of the cervix at 0, 3, 6, and 9 o'clock. The cervical injection was about 5 mm in all cases.<sup>[13,14]</sup> On the day before the operation, 2.0 mL of fluid containing 110 MBq <sup>99m</sup>Tc-Technetium (<sup>99m</sup>Tc)-labeled tin colloids was injected into the patient's cervix. Lymphoscintigraphy was performed within 6 hours, and hot spots, indicating SLNs, were identified. On the day of the operation, 5 mL of indigocarmine (IDC) (4 mg/mL) and/or indocyanine green (ICG) (50 μg/mL) was injected into the cervix at the start of surgery. The tracers were mixed at the concentration described above when IDG and ICG were used together. SLNs were detected after entering the retroperitoneal cavity. Radioactive lymph nodes were located using a gamma-probe (Navigator GPS; RMD Instruments Inc., Watertown, MA). IDC-stained lymph nodes were detected by direct inspection. ICG fluorescence-positive lymph nodes were detected using a color fluorescence camera (Hyper Eye Medical System; MIZUHO Medical Co., Ltd., Tokyo, Japan, for laparotomy; Camera Control Unit JC300, MC Medical Co., Tokyo, Japan, for laparoscopy). After the SLN biopsy, the area of the pelvic lymph nodes was surveyed by direct observation, and the lack of any remaining radioactive tissue was confirmed with a color fluorescence camera or a gamma-probe.

### 2.3. Pathology and SLN analyses

An intraoperative pathological examination was performed. The SLN was cut in half, parallel to the longest axis to obtain the maximum section area. One half was used to create a frozen section. The specimen was cut every 2 mm into 5 μm thick sections that were stained with hematoxylin and eosin (H&E). The specimens were evaluated at the time that the frozen sections were obtained. The other half and the non-SLN specimens were fixed in 10% formalin for a permanent section procedure; the specimen was cut parallel to the longest axis every 2 mm. After fixation, the 5 μm thick sections were stained with H&E and examined.

### 2.4. FDG PET/CT

All of the patients underwent FDG PET/CT within 4 weeks before surgery. All studies were performed with a PET/CT scanner

(Discovery 710; GE Healthcare, Milwaukee, WI). Patients fasted for at least 6 hours before the intravenous administration of 3.7 MBq/kg of <sup>18</sup>F-FDG. The preinjection blood glucose level was measured to ensure that the values were below 150 mg/dL. During the distribution phase, the patients lay in the supine position in a quiet room. Combined image acquisition began 60 minutes after tracer injection. The patients were scanned on a flat-panel, carbon-fiber composite table insert. First, an unenhanced CT scan (3.3 mm slice thickness) from the base of the skull to the inferior border of the pelvis was acquired during shallow breathing (140 kV, 60–80 mA). A subsequent PET scan was acquired in 3-dimensional mode acquisition, with 3 minutes for each bed position, iterative reconstruction (ordered subset expectation maximization) with 128 × 128 matrix size, attenuation, random, and scatter correction. Attenuation correction was performed based on the CT scan data.

The image readouts were obtained on a Xeleris Workstation (GE Healthcare), which allows for the visualization of PET, CT, and fused sections in transverse, coronal, and sagittal planes. Images were evaluated in consensus by 2 radiologists (one was a nuclear medicine physician) who had been informed of the clinical data. The focal tracer accumulation deviation from the physiological distribution of each tracer was regarded as indicating positivity for disease. A lymph node was considered PET-positive if its FDG uptake was greater than the blood pool activity or surrounding background tissue, regardless of its size.

### 2.5. Sensitivity and specificity

Systematic PLND was carried out in the external iliac, internal iliac, common iliac, obturator, and cardinal lymph node areas bilaterally for all patients: the right and left pelvic regions were analyzed separately. The hemi-pelvises (HPs) include common iliac nodes, external iliac nodes, internal iliac nodes, and obturator nodes. The cardinal lymph nodes were excluded from the statistical analysis because dissection of these nodes is required at radical hysterectomy. The HP was considered positive on each examination, including the SNB, FDG PET/CT, and final pathology, if at least one of the corresponding 4 subregions had metastasis and negative if all 4 regions were negative. The sensitivity was defined as a sum of the HPs with PET-positive nodes and involved SLNs divided by the total number of HPs with positive nodes. Specificity was defined as a sum of the HPs with PET-negative nodes or no involved SLNs divided by the total number of HPs without nodal metastasis.

For accuracy of FDG PET/CT on primary cervical cancer, the sensitivity was defined as the sum of PET-positive patients divided by the total number of patients who had cervical cancer on final pathology. The specificity was defined as the sum of PET-negative patients divided by the total number of patients who had no cancer lesion on final pathology, which means the cancer lesion was completely resected by conization.

### 2.6. Statistical analyses

All of the statistical analyses were performed using the JMP software package (version 13.1.0). Continuous variables are expressed as the mean ± standard deviation (SD). The Mann-Whitney *U* test was used to compare continuous variables, and Fisher exact test was used to compare frequencies. *P* values of <.05 were considered to indicate statistical significance.

**Table 1**

**The characteristics of the patients with cervical cancer who underwent FDG-PET/CT and sentinel lymph node biopsy.**

Total number of patients	48
Age, y	43.8 ± 9.5
BMI	21.7 ± 3.8
Nulliparous (%)	16 (33.3)
FIGO stage (%)	
IA2	3 (6.3)
IB1	34 (70.8)
IB2	2 (4.2)
IIA1	7 (14.6)
IIA2	2 (4.2)
Histological type (%)	
Squamous cell carcinoma	27 (56.2)
Adenocarcinoma	21 (43.8)
Conization	18 (33.3)
Surgical method (%)	
Laparoscopy	20 (41.7)
Laparotomy	28 (58.3)
Resected lymph nodes*	35.8 ± 12.3
Pelvic lymph node metastasis	9 (18.8)

BMI=body mass index, FDG-PET/CT=18F-fluorodeoxyglucose positron emission tomography/computed tomography, FIGO=International Federation of Gynecology and obstetrics.

\*Based on an ANOVA (mean ± SD).

### 3. Results

#### 3.1. Characteristics of study participants

Forty-eight patients with uterine cervical cancer underwent preoperative FDG PET/CT and intraoperative SNB. The mean age of the patients was 43.8 ± 9.5 years, and the mean body mass index (BMI) was 21.7 ± 3.8. Sixteen (33.3%) patients were nulliparous. A total of 3 patients had FIGO stage IA2 disease, 34 had stage IB1 disease, 2 had stage IB2 disease, 7 had stage IIA1 disease, and 2 had IIA2 disease. Histologically, 27 patients had squamous cell carcinoma, and 21 had adenocarcinoma. Eighteen (33.3%) patients had a history of cervical conization, and none received chemotherapy or radiotherapy preoperatively. Twenty (41.7%) patients underwent laparoscopic surgery; 28 (58.3%) patients underwent laparotomy. All patients underwent systematic PLND after SNB. The total number of resected lymph nodes was 35.8 ± 12.3. Nine patients (18.8%) had lymph node metastasis (Table 1).

#### 3.2. The information obtained with FDG PET/CT and SNB

The SLN procedure was performed with <sup>99m</sup>Tc in 44 (91.7%) patients, IDC in 44 (91.7%) patients, and ICG in 37 (77.1%) patients. The number of patients who received a combination of tracers, including, <sup>99m</sup>Tc with IDC, <sup>99m</sup>Tc with ICG, IDC with ICG and triple tracers, was 11 (22.9%), 4 (8.3%), 4 (8.3%), and 29 (60.4%), respectively. No patient received a single tracer. The mean number of detected SLNs was 3.0 ± 1.4. The detection rate was 91.7% (Table 2).

The mean maximum tumor diameter of cervical cancer on final pathology was 18.9 ± 14.3 mm. The mean SUV<sub>max</sub> for primary tumors was 6.8 ± 6.1. Among 48 patients with cervical cancer, 9 had no lesion on final pathology because the disease had been completely resected by cervical conization; the sensitivity and specificity of FDG PET/CT for predicting cervical cancer was 87.2% and 55.6%, respectively. The kappa statistic was 0.41 [95% confidence interval (95% CI) 0.10–0.73] (Table 3).

**Table 2**

**Information obtained from the sentinel lymph node biopsy.**

Total number of patients	48
Tracers (%)	
<sup>99m</sup> Tc	44 (91.7)
IDC	44 (91.7)
ICG	37 (77.1)
<sup>99m</sup> Tc + IDC	11 (22.9)
<sup>99m</sup> Tc + ICG	4 (8.3)
IDC + ICG	4 (8.3)
<sup>99m</sup> Tc + IDC + ICG	29 (60.4)
Sentinel lymph nodes*	3.0 ± 1.4
Detection rate	91.7%

<sup>99m</sup>Tc=99m-Technetium-labeled tin colloids, ICG=indocyanine green, IDC=indigocarmine.

\*Based on an ANOVA (mean ± SD).

#### 3.3. Accuracy of FDG PET/CT and SNB

Among 48 patients with cervical cancer, 12 HPs in 9 patients had lymph node metastasis. In these cases, FDG PET/CT predicted only 1 HP, making the sensitivity 8.3% (1/12). In contrast, SNB predicted 9 HPs, for a sensitivity of 75.0% (9/12). There was no metastasis in the remaining 84 HPs. FDG PET/CT predicted metastasis in 2 HPs and did not predict the metastasis in 82 HPs; the specificity, false positive rate, false negative rate, positive predictive value, and negative predictive value were 97.6% (82/84), 2.4% (2/84), 91.7% (11/12), 33.3% (1/3), and 88.2% (82/93), respectively. In these 84 HPs without metastasis, SNB detected no metastasis in 79 HPs; the specificity was 94.0% (79/84), and the negative predictive value was 100% (79/79) (Fig. 1). FDG PET/CT had a lower sensitivity (8.3% vs 75.0%,  $P < .01$ ) and negative predictive value (88.2% vs 100%,  $P < .01$ ) than SNB. The specificity was not significantly different between FDG PET/CT and SNB ( $P = .8$ ). In each HP in which the short axis diameter of the largest metastatic lymph node was <5 mm, the sensitivity of FDG PET/CT and SNB was 0% and 100%, respectively, but 16.7% and 50%, respectively, in each HP in which the short axis diameter of the largest metastatic lymph node was ≥5 mm (Table 4). When the diagnosis was made via SNB for HPs in which SLN had been detected and via FDG PET/CT for HPs in which SLN was not detected, the sensitivity and specificity were 75.0% and 100%, respectively; there were no differences between SNB and the combination of FDG PET/CT (Fig. 2). There were 14 HPs in 11 patients with discrepancies between the images, including FDG PET/CT and SNB findings, and final pathology. Among 3 HPs with nodal metastases where SLNs could not be detected, 2 were associated with multiple nodal metastasis, and the short axis diameter of the largest metastatic lymph node was ≥5 mm in all 3 HPs. The most common region for metastatic lymph nodes and SLNs was the

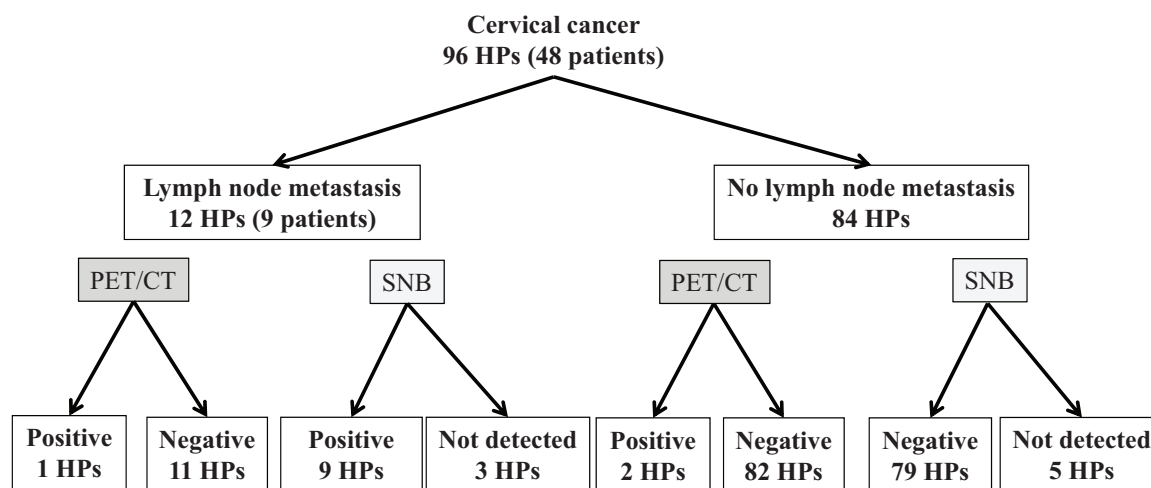
**Table 3**

**Information obtained from FDG-PET/CT for primary cervical tumors.**

Total number of patients	48
Maximum tumor diameter, mm*	18.9 ± 14.3
SUV <sub>max</sub> for primary tumors	6.8 ± 6.1
Sensitivity	87.2%
Specificity	55.6%
Kappa statistics	0.41 (0.10–0.73)

<sup>99m</sup>Tc=99m-Technetium-labeled tin colloids, ICG=indocyanine green, IDC=indigocarmine.

\*Based on an ANOVA (mean ± SD).



**Figure 1.** The results of SNB and FDG PET/CT for predicting lymph node metastasis. Among 48 patients with cervical cancer, 12 hemi-pelvises (HPs) in 9 patients had lymph node metastasis. In these metastasis cases, FDG PET/CT predicted only 1 HPs, making the sensitivity 8.3% (1/12). In contrast, SNB predicted 9 HPs, for a sensitivity of 75.0% (9/12). There was no metastasis in the remaining 84 HPs. FDG PET/CT predicted metastasis in 2 HPs and did not predict the metastasis in 82 HPs; the specificity, false positive rate, false negative rate, positive predictive value, and negative predictive value were 97.6% (82/84), 2.4% (2/84), 91.7% (11/12), 33.3% (1/3), and 88.2% (82/93), respectively. In the 84 HPs without metastasis, SNB detected no metastasis in 79 HPs; the specificity was 94.0% (79/84).

superior part of the obturator region where the lymphatic trunks cross over the obliterated umbilical artery. Among 12 HPs with nodal metastasis, only 1 showed positive findings on FDG PET/CT. The short axis diameter of the largest metastatic lymph node was 11 mm in this case. The discrepancy between the imaging findings and final pathology was not significantly different between the squamous cell carcinomas and adenocarcinomas (26% vs 19%). Among 84 HPs with no nodal metastasis, 2 HPs were positive for FDG PET/CT. The age of these 2 patients was 35 and 33 years. No patient underwent cervical conization preoperatively. Although we found no reason to explain the false negative findings, tumor inflammation or ovulation might cause the uptake of FDG (Table 5).

**4. Discussion**

To our knowledge, this is the largest study to compare the diagnostic accuracy of pelvic lymph node metastasis on FDG PET/CT and SNB. In the current study, SNB had higher sensitivity for detecting pelvic lymph node metastasis than FDG PET/CT. The specificity was not markedly different between FDG PET/CT and SNB. SNB is more useful for predicting pelvic lymph node metastasis than FDG PET/CT.

A meta-analysis showed that the SLN detection rate in cervical cancer was 89.2% to 93.0%.<sup>[15-17]</sup> The detection rates with blue dye, the isotope, and a combination of both tracers were 80.9%

to 87.5%, 90% to 90.9%, and 92.3% to 97%, respectively.<sup>[15-17]</sup> In contrast, the sensitivity of radiotracers has been reported to be 87% to 94.4%.<sup>[15-17]</sup> The use of a radiotracer in combination with blue dye did not increase the sensitivity to a significant extent (88% to 91.3%). Similarly, blue dye used alone did not decrease the sensitivity to a significant extent (86.3% to 87.2%).<sup>[15-17]</sup> The sensitivity with fluorescent imaging was 90.9%.<sup>[15-17]</sup> The sensitivity of SNBs in our study was lower than in previously published studies. This difference is due to the method for calculating the sensitivity; the patients or lymph nodes that could not be detected were excluded in most previous studies. The sensitivity of the detected SLNs was 100% in our study. In our experience, the detection rate of <sup>99m</sup>Tc, IDC, and ICG was 85.8%, 20.2%, and 61.6%, respectively. The rate of specificity and false negatives were not significantly different among the tracers. The combination of <sup>99m</sup>Tc and ICG raised the detection rate by about 5%. Furthermore, we believe that a laparoscopic procedure is more useful for SNB than open surgery, given recent technological advances in surgical devices, including scopes and gamma probes.<sup>[12]</sup>

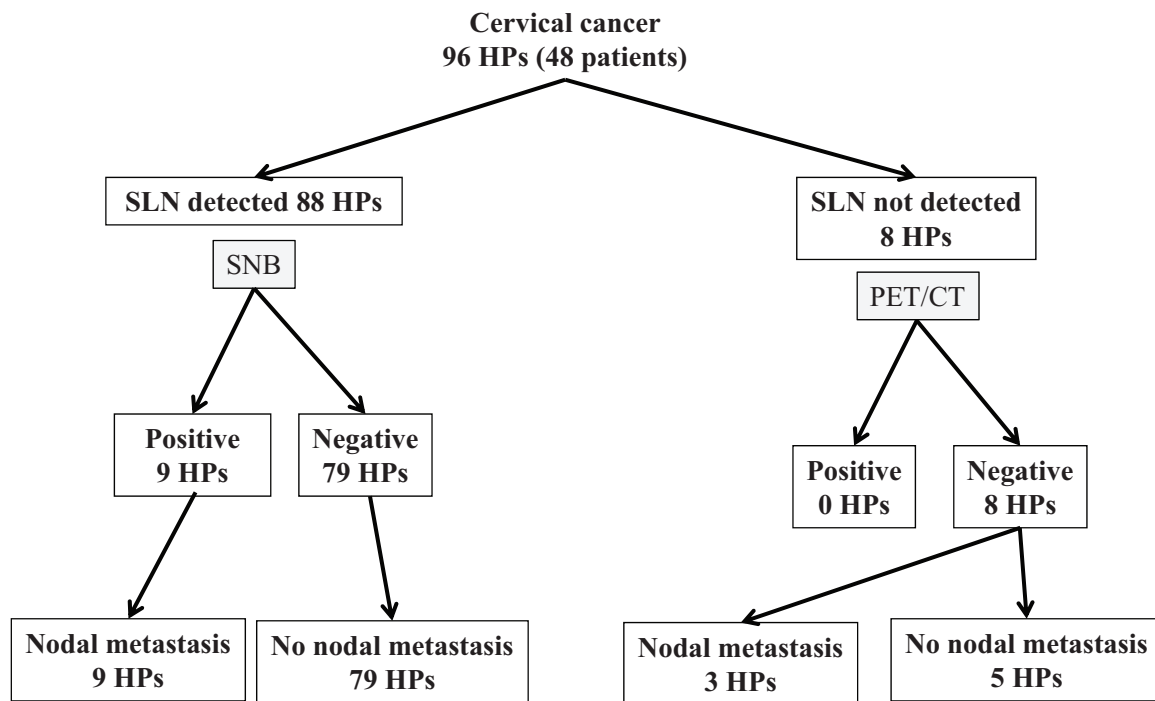
As surgical procedures including SNB may have intra- and postoperative complications, FDG PET/CT may be useful as a noninvasive method for detecting pelvic lymph node metastasis preoperatively. A number of studies have examined pelvic lymph node metastasis with FDG PET/CT.<sup>[18-23]</sup> However, these studies differ in many respects, such as in disease staging, the number of resected lymph nodes, and the calculation methods. Atri et al<sup>[18]</sup> showed that FDG PET/enhanced CT had a sensitivity of 83% and specificity of 63% for pelvic lymph node metastasis in patients with advanced cervical cancer. Their analysis was conducted at the patient level, considering the lymph node region. In that study, 50% of patients had paraaortic lymph node metastasis. Furthermore, the median number of lymph nodes removed from the pelvis was 13.<sup>[18]</sup> Kuan et al reported that the patient-based sensitivity and specificity of PET/CT for the detection of lymph node metastasis were 100% and 91%, respectively, and the node-based sensitivity and specificity were 91% and 98.4%, respectively. Among the 87 cases, 34 (39.1%) were confirmed as having lymph node metastasis. The mean number of resected

**Table 4**  
**Comparison of accuracy of sentinel node biopsy and FDG PET/CT for prediction of pelvic lymph node metastasis.**

	FDG PET/CT	SNB	P
Sensitivity	8.3%	75.0%	<.01
Short axis <5mm	0%	100%	<.01
Short axis ≥5mm	16.7%	50%	.2
Specificity	97.6%	94.1%	.8
Negative predict value	88.2%	100%	<.01

FDG PET/CT = 18F-fluorodeoxyglucose positron emission tomography/computed tomography, SNB = sentinel node biopsy.





**Figure 2.** The combination of FDG PET/CT and SNB. Among the 8 HPs in which SLN was not detected, lymph node metastasis was identified in 3 on final pathology; however, no HPs showed positive findings on FDG PET/CT.

lymph nodes was 13.4.<sup>[19]</sup> Choi et al<sup>[23]</sup> reported a patient-based sensitivity and specificity of FDG PET/CT of 76.9% and 55.5%, respectively. The region-based sensitivity and specificity were 57.6% and 92.6%, respectively. Thirteen of 22 patients (59.1%) had lymph node metastasis.<sup>[23]</sup> In contrast, Chou et al<sup>[24]</sup> reported that the sensitivity of FDG PET/CT was only 10%.<sup>[24]</sup> The authors commented that the higher the ratio of histologic pelvic lymph node metastasis and/or simultaneous MRI/CT-positive pelvic lymph nodes, the greater the added benefit of FDG PET/CT. In our study, the sensitivity and specificity were 8.3% and 97.6%, respectively. Nine of 48 patients (18.8%) had pelvic

lymph node metastasis. The mean number of resected lymph nodes were 35.8. The sensitivity in our study was markedly lower than that of the studies mentioned above. In those studies, the rate of patients who had lymph node metastasis was higher than in our study; however, the number of dissected lymph nodes was lower than in our study. In those studies, only apparent metastatic lymph nodes may have been dissected, and small metastatic lymph nodes may have remained. Most participants in our study were patients with early-stage cervical cancer. Furthermore, the number of removed lymph nodes was higher in our study than in previous studies. These findings suggest that

**Table 5**

**Clinico-pathological data of patients with lymph node metastasis and positive SNB and FDG PET/CT findings.**

Case	Number of lymph node metastases	Location of metastatic lymph node	SNB	Location of SLN	FDG PET/CT	Short axis diameter of the largest metastatic lymph node, mm	Age, y	FIGO stage	Histology	Conization	Recurrence
1	2	0	+	0	+	11	43	1B1	sq	+	+
2	1	0	+	0	-	4	41	1B1	ad	-	-
3	1	0	+	0	-	3	39	1B1	sq	-	-
4	1	0	+	0	-	4	48	2A1	sq	-	-
5	0	-	-	0	+	-	35	1B1	ad	-	-
6	4	0	+	0	-	5	45	1B1	sq	-	-
7	1	IE	+	IE	-	4	30	1B1	sq	-	-
8	2	II	+	II	-	4	32	2A2	sq	-	+
	1	II	N.D.	-	-	5	-	-	-	-	-
9	4	0 IE II	N.D.	-	-	8	27	1B2	ad	-	+
	10	0 IE II	N.D.	-	-	7	-	-	-	-	-
10	1	0	+	0	-	4	48	1B1	sq	-	-
	1	0	+	0	-	9	-	-	-	-	-
	0	-	-	0	+	-	33	1B2	ad	-	-

ad = adenocarcinoma, FDG PET/CT = fluorodeoxyglucose-positron emission tomography/computed tomography, FIGO, SNB = sentinel lymph node biopsy, FDG PET/CT = fluorodeoxyglucose-positron emission tomography/computed tomography, FIGO = International Federation of Gynecology and Obstetrics; sq, squamous cell carcinoma, IE = iliac external, II = iliac internal, N.D. = not detected, 0 = obturator, SNB = sentinel lymph node biopsy.

it is difficult to detect small metastatic lymph nodes on preoperative FDF PET/CT, so these small metastatic lymph nodes were likely detected on final pathology in our study. We believe that the sensitivity in our study may be appropriate in early-stage cervical cancer patients who do not require systematic PLND. Despite advances in imaging technology, SNB are more useful for detecting pelvic lymph node metastasis than FDG PET/CT in early-stage cervical cancer at present.

In the NCCN guideline, SNB algorithm is suggested, as SLN mapping requires the performance of side-specific nodal dissection in cases of failed mapping and the removal of any suspicious or grossly enlarged nodes regardless of mapping.<sup>[25]</sup> We considered that FDG PET/CT might be useful in cases of failed mapping. Among the 8 failed mapping cases, 3 had positive nodes in the present study. Unfortunately, FDG PET/CT failed to suggest metastasis in any of these cases, suggesting that the combination of FDG PET/CT and an SNB was not useful in our study.

This study is associated with 3 major limitations that may reduce its value. First, it was impossible to detect any significant differences in staging or tumor size because of the small sample size. Second, the study included bias; for instance, the surgeons knew the results of PET/CT before surgery. Third, ultrastaging or immunohistochemistry was not performed. As such, our results must be confirmed in further studies.

In conclusion, SNBs had higher sensitivity for detecting pelvic lymph node metastasis than FDG PET/CT. The specificity was not markedly different between FDG PET/CT and SNB. SNB is more useful for predicting pelvic lymph node metastasis than FDG PET/CT, especially in early-stage cervical cancer.

## Author contributions

**Conceptualization:** Tomohito Tanaka, Masahide Ohmichi.

**Data curation:** Tomohito Tanaka, Shun Sasaki, Hiromitsu Tsuchihashi, Yoshito Terai, Kazuhiro Yamamoto, Takashi Yamada.

**Formal analysis:** Tomohito Tanaka, Shun Sasaki, Hiromitsu Tsuchihashi, Yoshito Terai, Kazuhiro Yamamoto, Takashi Yamada.

**Writing original draft:** Tomohito Tanaka.

**Writing review and editing:** Masahide Ohmichi.

## References

- Pecorelli S, Zigliani L, Odicino F. Revised FIGO staging for carcinoma of the cervix. *Int J Gynaecol Obstet* 2009;105:107–8.
- Delgado G, Bundy B, Zaino R, et al. Prospective surgical-pathological study of disease-free interval in patients with stage IB squamous cell carcinoma of the cervix: a Gynecologic Oncology Group study. *Gynecol Oncol* 1990;38:352–7.
- Yuan C, Wang P, Lai C, et al. Recurrence and survival analyses of 1,115 cervical cancer patients treated with radical hysterectomy. *Gynecol Obstet Invest* 1999;47:127–32.
- Biewenga P, van der Velden J, Mol BW, et al. Prognostic model for survival in patients with early stage cervical cancer. *Cancer* 2011; 117:768–76.
- Kim SI, Lim MC, Lee JS, et al. Impact of lower limb lymphedema on quality of life in gynecologic cancer survivors after pelvic lymph node dissection. *Eur J Obstet Gynecol Reprod Biol* 2015;192:31–6.
- Tanaka T, Terai Y, Ono YJ, et al. Genitofemoral neuropathy after pelvic lymphadenectomy in patients with uterine corpus cancer. *Int J Gynecol Cancer* 2015;25:533–6.
- Abu-Rustum NR, Alektiar K, Iasonos A, et al. The incidence of symptomatic lower-extremity lymphedema following treatment of uterine corpus malignancies: a 12-year experience at Memorial Sloan-Kettering Cancer Center. *Gynecol Oncol* 2006;103:714–8.
- Homesley HD, Kadar N, Barrett RJ, et al. Selective pelvic and periaortic lymphadenectomy does not increase morbidity in surgical staging of endometrial carcinoma. *Am J Obstet Gynecol* 1992;167:1225–30.
- Togami S, Kamio M, Yanazume S, et al. Can pelvic lymphadenectomy be omitted in stage IA2 to IIB uterine cervical cancer? *Int J Gynecol Cancer* 2014;24:1072–6.
- Sakuragi N, Satoh C, Takeda N, et al. Incidence and distribution pattern of pelvic and paraaortic lymph node metastasis in patients with Stages IB, IIA, and IIB cervical carcinoma treated with radical hysterectomy. *Cancer* 1999;85:1547–54.
- Yoneda JY, Braganca JF, Sarian LO, et al. Surgical treatment of microinvasive cervical cancer: analysis of pathologic features with implications on radicality. *Int J Gynecol Cancer* 2015;25:694–8.
- Tanaka T, Terai Y, Ashihara K, et al. The detection of sentinel lymph nodes in laparoscopic surgery for uterine cervical cancer using 99m-technetium-tin colloid, indocyanine green, and blue dye. *J Gynecol Oncol* 2017;28:e13.
- Abu-Rustum NR, Khoury-Collado F, Gemignani ML. Techniques of sentinel lymph node identification for early-stage cervical and uterine cancer. *Gynecol Oncol* 2008;111(2 Suppl):S44–50.
- Eiriksson LR, Covens A. Sentinel lymph node mapping in cervical cancer: the future? *BJOG* 2012;119:129–33.
- Wang XJ, Fang F, Li YF. Sentinel-lymph-node procedures in early stage cervical cancer: a systematic review and meta-analysis. *Med Oncol* 2015;32:385.
- Wu Y, Li Z, Wu H, et al. Sentinel lymph node biopsy in cervical cancer: a meta-analysis. *Mol Clin Oncol* 2013;1:1025–30.
- Kadkhodayan S, Hasanzadeh M, Treglia G, et al. Sentinel node biopsy for lymph nodal staging of uterine cervix cancer: a systematic review and meta-analysis of the pertinent literature. *Eur J Surg Oncol* 2015;41:1–20.
- Atri M, Zhang Z, Dehdashti F, et al. Utility of PET-CT to evaluate retroperitoneal lymph node metastasis in advanced cervical cancer: results of ACRIN6671/GOG0233 trial. *Gynecol Oncol* 2016;142:413–9.
- Lv K, Guo HM, Lu YJ, et al. Role of 18F-FDG PET/CT in detecting pelvic lymph-node metastases in patients with early-stage uterine cervical cancer: comparison with MRI findings. *Nucl Med Commun* 2014;35: 1204–11.
- Groheux D, Hindie E, Baillet G, et al. [Advantages of PET-CT in the work-up of cervical cancer]. *Bull Cancer* 2009;96:199–211.
- Chao A, Ho KC, Wang CC, et al. Positron emission tomography in evaluating the feasibility of curative intent in cervical cancer patients with limited distant lymph node metastases. *Gynecol Oncol* 2008;110:172–8.
- Sironi S, Buda A, Picchio M, et al. Lymph node metastasis in patients with clinical early-stage cervical cancer: detection with integrated FDG PET/CT. *Radiology* 2006;238:272–9.
- Choi HJ, Roh JW, Seo SS, et al. Comparison of the accuracy of magnetic resonance imaging and positron emission tomography/computed tomography in the presurgical detection of lymph node metastases in patients with uterine cervical carcinoma: a prospective study. *Cancer* 2006;106:914–22.
- Chou HH, Chang TC, Yen TC, et al. Low value of [18F]-fluoro-2-deoxy-D-glucose positron emission tomography in primary staging of early-stage cervical cancer before radical hysterectomy. *J Clin Oncol* 2006; 24:123–8.
- National Comprehensive Cancer Network. Cervical Cancer (Version 1.2018). Available at: [https://www.nccn.org/professionals/physician\\_gls/pdf/cervical.pdf](https://www.nccn.org/professionals/physician_gls/pdf/cervical.pdf). Accessed March 19, 2018.