

REVIEW ARTICLE

Imaging of Tuberculosis of the Abdominal Viscera: Beyond the Intestines

Sree Harsha Tirumani, Vijayanadh Ojili¹, Gowthaman Gunabushanam², Alampady Krishna Prasad Shanbhogue¹, Arpit Nagar³, Najla Fasih⁴, Kedar N Chintapalli¹

Department of Imaging, Dana Farber Cancer Institute, Harvard Medical School, Boston, MA, ¹Department of Radiology, University of Texas Health Science Center at San Antonio, San Antonio, Texas, ²Diagnostic Radiology, Yale University School of Medicine, Connecticut, USA, ³Division of Abdominal Imaging, Department of Radiology, Ohio State University Medical Center, Columbus, Ohio, USA, ⁴Diagnostic Imaging, The Ottawa Hospital, Ottawa, Ontario, Canada

Address for correspondence:

Dr. Vijayanadh Ojili,
Department of Radiology,
University of Texas Health Science
Center at San Antonio, 7703 Floyd Curl
Drive MS 7800, San Antonio 78229,
Texas, United States of America.
E-mail: ojili@uthscsa.edu



Received : 14-02-2013

Accepted : 09-03-2013

Published : 30-04-2013

ABSTRACT

There is an increasing incidence of both intra- and extra-thoracic manifestations of tuberculosis, in part due to the AIDS epidemic. Isolated tubercular involvement of the solid abdominal viscera is relatively unusual. Cross-sectional imaging with ultrasound, multidetector computed tomography (CT), and magnetic resonance imaging (MRI) plays an important role in the diagnosis and post treatment follow-up of tuberculosis. Specific imaging features of tuberculosis are frequently related to caseous necrosis, which is the hallmark of this disease. However, depending on the type of solid organ involvement, tubercular lesions can mimic a variety of neoplastic and nonneoplastic conditions. Often, cross-sectional imaging alone is insufficient in reaching a conclusive diagnosis, and image-guided tissue sampling is needed. In this article, we review the pathology and cross-sectional imaging features of tubercular involvement of solid abdominopelvic organs with a special emphasis on appropriate differential diagnoses.

Key words: Abdomen, computed tomography, magnetic resonance imaging, tuberculosis

INTRODUCTION

There has been a resurgence of tuberculosis with the advent of the HIV/AIDS epidemic. Extra-pulmonary tuberculosis is also increasing in incidence due to

multidrug resistant tubercle bacilli and certain genetic variations in mycobacteria such as phospholipase c gene D (plcD) mutations.^[1] Genitourinary tuberculosis has been reported to be the most common site for extrapulmonary tuberculosis.^[2] Abdominal solid organ involvement other than the genitourinary tract is less common, constituting 15-20% of abdominal tuberculosis in various studies.^[3,4] Imaging diagnosis of solid visceral tuberculosis is often elusive as only 15% of patients with abdominal tuberculosis have evidence of pulmonary involvement.^[5] Further, radiological features are nonspecific, mimicking a wide gamut of pathologies such as lymphoma, leukemia, metastasis, sarcoidosis, histoplasmosis, and pyogenic

Access this article online**Quick Response Code:****Website:**

www.clinicalimagingscience.org

DOI:

10.4103/2156-7514.111234

Copyright: © 2013 Tirumani S H. This is an open-access article distributed under the terms of the Creative Commons Attribution License, which permits unrestricted use, distribution, and reproduction in any medium, provided the original author and source are credited.

This article may be cited as:

Tirumani SH, Ojili V, Shanbhogue AK, Nagar A, Fasih N, Chintapalli KN, Gunabushanam G. Imaging of Tuberculosis of the Abdominal Viscera: Beyond the Intestines. J Clin Imaging Sci 2013;3:17. Available FREE in open access from: <http://www.clinicalimagingscience.org/text.asp?2013/3/1/17/111234>

infections. The diagnosis of tuberculosis is therefore not made prospectively. Accordingly, the aim of this article is to provide a comprehensive cross-sectional imaging review of tuberculosis of abdominal solid organs, including genitourinary tuberculosis.

PATHOGENESIS OF TUBERCULOSIS IN SOLID ABDOMINAL VISCERA

The most common route of spread of tuberculosis to the solid abdominal viscera is the hematogenous route and less commonly the lymphogenous route. The disseminated bacilli lodge in the visceral parenchyma and multiply within the macrophages producing granulomatous inflammation consisting of epithelioid macrophages and Langhans giant cells eventually resulting in caseous necrosis. In the kidney, the bacilli lodge in the cortex in the glomerular and peritubular capillaries and form caseous granulomas that can cavitate and communicate with collecting tubules with subsequent dissemination into renal pelvis, ureter, and urinary bladder. In the immune-competent patients, the caseous necrosis is gradually replaced by fibrosis and calcification resulting in calcified granulomas.^[6] In the immunocompromised patients, the granulomas are less well-formed and caseous necrosis is not a feature.^[7]

Renal tuberculosis

Genitourinary tuberculosis is the most common site of extra-pulmonary tuberculosis and accounts for 15-20% of extra-pulmonary infections.^[8] Although the mode of spread to the kidneys is primarily hematogenous, the disease is often more severe in one kidney.^[8] Ultrasound findings of renal tuberculosis are nonspecific, including hypoechoic parenchymal masses, dilated irregular calices, and hydronephrosis with debris.^[9] Computed tomography (CT) findings include hypodense parenchymal lesions, miliary nodules [Figure 1], and renal abscess [Figure 2]. Chronic cases demonstrate cortical thinning and parenchymal scarring. CT urography is helpful in demonstrating collecting system involvement, including findings such as abnormal urothelial thickening and enhancement,

uneven caliectasis, infundibular stricturing [Figure 3], and hydronephrosis giving the appearance of a multiloculated cyst.^[10] CT also demonstrates calcification in over 50% cases. Magnetic resonance imaging (MRI) has limited additional diagnostic value in renal tuberculosis.^[11] Tubercular lesions are iso- to hypointense on T1-weighted (T1W) images and iso-, hypo-, or hyperintense on T2-weighted (T2W) images; depending on presence or absence of caseous necrosis. MR urography may show changes similar to CT urography [Figure 4]. The radiological differential diagnosis of early renal parenchymal tuberculosis includes pyogenic renal infections and fungal infections. Correlation with clinical presentation usually helps in differentiating them from tuberculosis. Chronic tuberculosis may be indistinguishable from xanthogranulomatous inflammation.^[12] Renal sarcoidosis, which occurs in 7-22% cases can be confused with tuberculosis but presence of noncaseating granulomas, hypercalcemia, and nephrocalcinosis can help in differentiating from tuberculosis.^[13] Solitary renal tuberculoma can mimic renal neoplasm like renal cell carcinoma (RCC), especially the papillary type; lymphoma; or metastases.^[7]

Hepatic tuberculosis

The liver is the second most common site of involvement in tuberculosis of the abdominal solid organs. A wide variety of terms have been used by different authors to describe focal hepatic tuberculosis including: Atypical tuberculosis, tubercular hepatitis, tubercular cholangitis, and serohepatic tuberculosis.^[14,15] One proposed comprehensive classification of hepatic tuberculosis included the following types: Micronodular, macronodular, mixed, and isolated tubercular abscess.^[5]

Micronodular tuberculosis refers to miliary tuberculosis where the lesions range in size from 0.5-1.0 cm. Macronodular or pseudotumor type is characterized by nodules of 1-3 cm size.^[5,15] Mixed type of hepatic tuberculosis demonstrates both micro and macronodules. Isolated tubercular abscess is the rarest type of hepatic parenchymal tuberculosis, seen in immunocompromised patients, and characterized by a

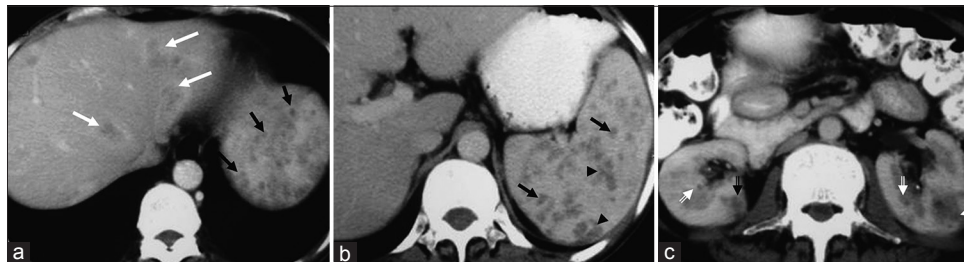


Figure 1: 42-year-old man with hepatic, splenic, and renal tuberculosis. (a-c) Axial contrast-enhanced computed tomography images of the abdomen demonstrate coalescent hypodense lesions (macronodular) in the liver (white arrows in a), tiny hypodense lesions (micronodular or miliary) in the spleen (black arrows in a, b), and the kidneys (double-lined white arrows in c). Note the conglomeration of some of the splenic (black arrowheads in b) and renal lesions (double-lined black arrow in c) resulting in macronodular appearance.

large caseous granuloma that mimics an abscess. However, the prognostic significance of this classification remains unclear.

The only imaging finding in micronodular type may be hepatomegaly if the lesions are below the resolution of ultrasonography (US) or computed tomography (CT).^[15] US and CT may demonstrate lesions as tiny hypoechoic or hypodense lesions of varying size with a “bright liver pattern” on US.^[16] The differential diagnosis of micronodular hepatic tuberculosis includes metastases, lymphoma, leukemia, sarcoidosis, and fungal infection.

The macronodular form is seen as large lesions with peripheral rim enhancement and central low attenuation on CT. This appearance is due to caseous necrosis [Figure 1].^[5,17] Macronodular form may appear identical to pyogenic abscess, metastases, and primary liver tumors like hepatocellular carcinoma and cholangiocarcinoma.^[15,18,19] Isolated tubercular abscess mimics pyogenic liver abscess on imaging [Figure 5]. Calcified granulomas may be the only evidence of tuberculosis in the healed phase. MRI demonstrates tubercular lesions as hypointense with peripheral hypointense rim on T1W images

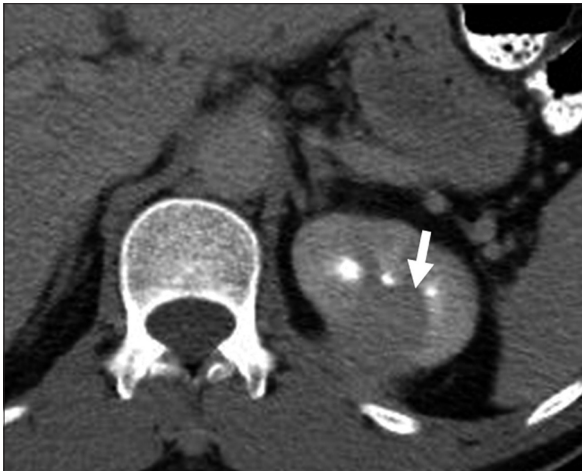

Figure 2: 38-year-old man with renal tuberculosis. Axial CECT image of the abdomen in the excretory phase reveals a hypodense parenchymal mass (arrow) in the upper pole of left kidney with perinephric extension. Biopsy of the lesion revealed tubercular abscess.

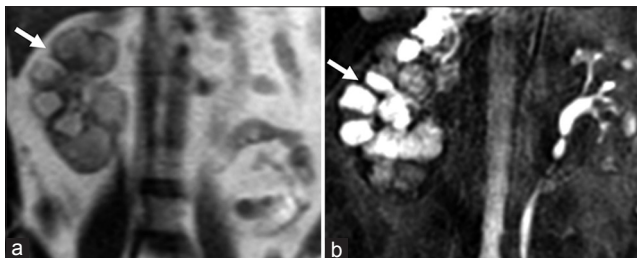


Figure 4: 51-year-old woman with renal tuberculosis. (a) Coronal T2-weighted (T2W) and (b) heavily T2W (long TR) magnetic resonance (MR) images reveal grossly hydronephrotic right kidney (arrow) due to chronic upper ureteric tubercular stricture.

and hypo-, iso- or hyperintense lesions with peripheral less intense rim on T2W images, and rim or heterogeneous enhancement on postgadolinium images [Figure 6].^[5,20] Image-guided biopsy may be required to obtain a definitive histological diagnosis.^[14,21]

Splenic tuberculosis

The spleen is rendered vulnerable to tuberculosis due to its extensive network of reticuloendothelial cells. Indeed, 80-100% of disseminated tuberculosis demonstrates splenic involvement in various autopsy series.^[5] Splenic tuberculosis may manifest as isolated splenomegaly, micronodular, or macronodular form.^[22,23] Micronodular lesions that occur as a part of miliary disease are usually beyond the resolution of US but may be seen on CT as hypodense foci [Figure 1]. Macronodular disease is seen as solitary or multifocal lesions of 1-3 cm size that are hypodense on CT, but with a peripheral rim of enhancement [Figure 1].^[15,24] MRI findings of splenic tuberculosis are variable depending on the stage of evolution of tuberculomas. Lesions may demonstrate gradual peripheral enhancement with complete fill-in of the lesions, with no central caseous necrosis.^[23,25,26] Differential diagnosis of splenic tuberculosis includes pyogenic infections and disseminated fungal infections like candidiasis. Leukemic and lymphomatous infiltration is indistinguishable from tuberculosis. Fine needle aspiration of splenic lesions for confirmation of diagnosis is indicated in patients with no other evidence of tuberculosis or those that are unresponsive to treatment.^[21,27]

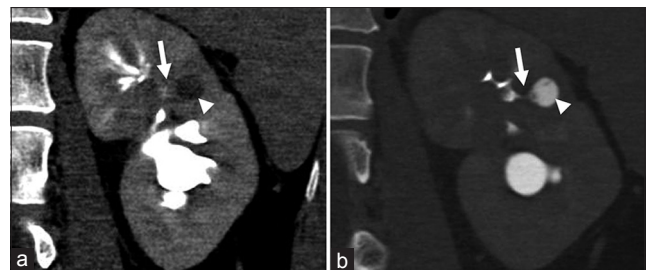


Figure 3: 43-year-old woman with renal tuberculosis. (a, b) Coronal reformatted CECT urography images demonstrate infundibular stricture (white arrow) with a calyceal diverticulum (arrowhead).

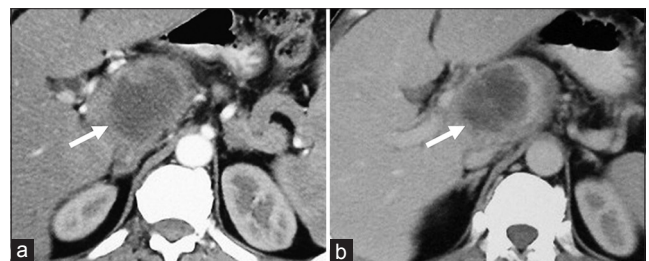


Figure 5: 62-year-old man with hepatic tubercular abscess. Axial CECT images of the liver in (a) arterial and (b) portal venous phases reveal a solitary well-defined hypodense lesion (arrow) with peripheral rim of enhancement in the caudate lobe. Ultrasound guided fine needle aspiration biopsy (not shown) of the lesion revealed caseous necrosis with tubercle bacillus and epithelioid giant cells.

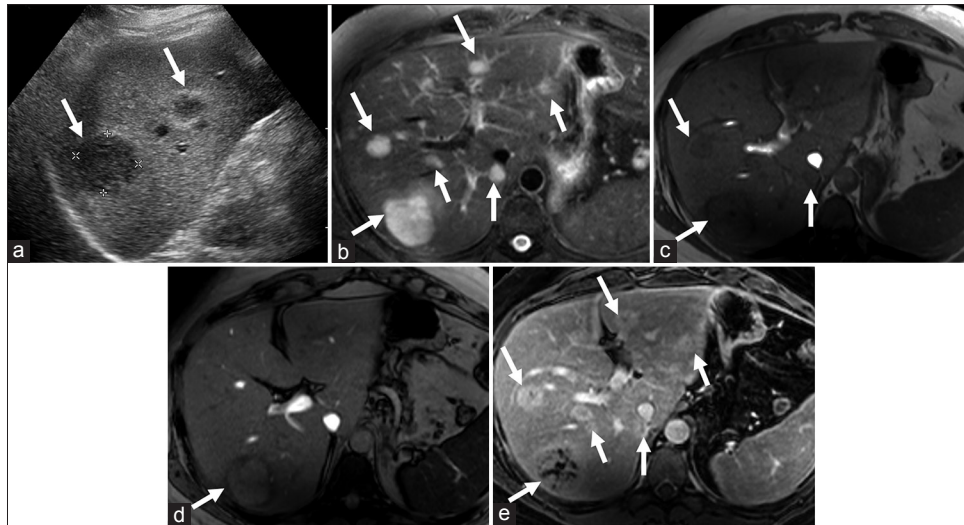

Figure 6: 28-year-old man with HIV associated hepatic tuberculosis. (a) Transverse ultrasound image of the liver demonstrates well-defined hypoechoic lesions (arrows) in the right lobe. (b) Axial T2W MR image of the liver reveals high-signal intensity of the lesions (arrows). (c, d) Axial dual-echo in- and out-of-phase T1-weighted (T1W) MR images reveal the lesions (arrows) to be iso- to hypointense with peripheral hypointense rim. Note that the larger lesion has greater signal loss on the longer TE (in-phase) sequence which is most likely explained by the caseous necrosis. (e) Axial T1W fat suppressed postgadolinium MR image in the venous phase demonstrates heterogeneous enhancement of the lesions (arrows). Ultrasound-guided biopsy of the lesions revealed granulomatous inflammation with acid-fast bacilli consistent with tuberculosis.

Adrenal tuberculosis

Tuberculosis of adrenal glands is the most common cause of chronic adrenal insufficiency in developing countries.^[28,29] Involvement is bilateral in up to 90% of cases as the tubercular bacilli reach the adrenal gland by the hematogenous or lymphatic route and both glands are equally susceptible.^[30] Adrenal insufficiency usually occurs when 90% of the gland is destroyed.

CT and MRI reflect the typical pathologic changes.^[25,26] In the caseous granulomatous stage, there is mass-like enlargement of the adrenal glands with or without contour preservation. Caseous necrosis is seen as a low attenuation center on CT scans.^[31] The glands are usually hypo- to isointense on T1W images and hyperintense on T2W images. Adrenal glands may also enhance homogeneously or demonstrate peripheral rim enhancement in the presence of central necrosis [Figure 7].^[32] In this stage, adrenal tuberculosis may appear identical to metastases, lymphoma, hemorrhage, histoplasmosis, or primary tumors. In a study of 108 patients, Yang et al.,^[31] showed that bilaterality, preserved contour and peripheral rim enhancement were more often seen in adrenal tuberculosis than in primary tumors. In chronic adrenal tuberculosis, the glands are atrophic and demonstrate calcification on CT and low signal on all MRI sequences.

Pancreatic tuberculosis

The pancreas is uncommonly affected by tuberculosis, with an incidence in various autopsy series of 4.7%.^[33] Spread of the bacillus to the pancreas is either from the hematogenous route or by contiguous extension of

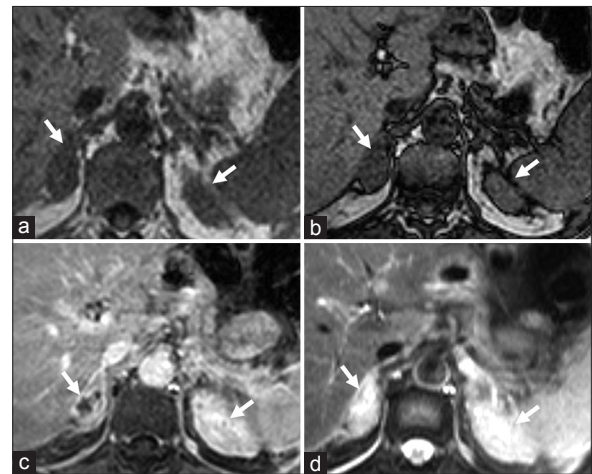


Figure 7: 45-year-old woman with pulmonary tuberculosis complicated by adrenal involvement. (a, b) Axial dual echo in- and out-of-phase T1W MR images reveal bilateral adrenal nodules (arrows) with no significant intravoxel lipid. Note the preserved contour of the adrenal glands. (c, d) Axial T1W fat suppressed postgadolinium MR image in the venous and delayed phases demonstrate peripheral rim enhancement of the right adrenal nodule and heterogeneous enhancement of the left adrenal nodule in the venous phase (arrows in c) with progressive increase in enhancement of both the nodules in delayed phase (arrows in d). CT-guided biopsy of the right adrenal lesion revealed granulomatous inflammation.

tubercular lymphadenopathy. The usual imaging appearance is that of a mass in the pancreas mimicking pancreatic cancer.^[21,34] On US, pancreatic tuberculosis is seen as one or more solid hypoechoic masses in the pancreatic parenchyma that may sometimes show central liquefaction.^[5] Hypodense hypovascular masses with adjacent necrotic or non-necrotic lymphadenopathy are features encountered on CT [Figure 8].^[21] Peripheral rim enhancement may be seen in some cases.^[34] Masses in the pancreatic head region may result in obstructive

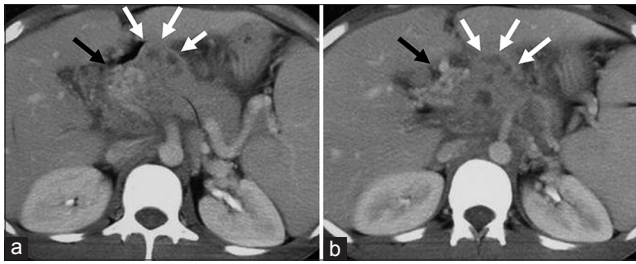


Figure 8: 23-year-old woman with pancreatic tuberculosis and previous history of pulmonary tuberculosis. (a, b) Axial CECT images of the upper abdomen demonstrate hypodense mass with nonenhancing necrotic areas (white arrows) in the pancreatic head and uncinate process region causing portal vein thrombosis with cavernous transformation (black arrow). The radiological picture is indistinguishable from pancreatic cancer. Note the absence of arterial encasement. Ultrasound guided fine needle aspiration biopsy revealed granulomatous inflammation. The patient was treated with standard antitubercular therapy with marked improvement.

cholangiopathy and portal vein thrombosis [Figure 8]. The differential diagnosis for pancreatic tuberculosis includes pancreatic cancer, chronic pancreatitis, metastases, fungal infections, sarcoidosis, and Castelman's disease.^[35,36] The major challenge on imaging is to differentiate pancreatic tuberculosis from pancreatic adenocarcinoma. Most cases reported in the literature required percutaneous image-guided biopsy for a definitive diagnosis.^[36] Soft pointers to a tubercular etiology include absence of vascular invasion or pancreatic duct dilatation, known primary tuberculosis, and necrotic lymphadenopathy.

Male genital tuberculosis

Tubercular involvement of the male genital tract may occur either from extension of the upper urinary tract tuberculosis, or from hematogenous or lymphatic spread.^[10] Caseous necrosis in tubercular prostatitis or prostatic abscess is seen on US as hypoechoic areas with surrounding hyperemia and on CT as peripheral rim enhancing hypodense regions mimicking pyogenic abscess.^[10] On transrectal US (TRUS), tubercular lesions occur as hypoechoic lesions in the peripheral gland in the posterior and lateral lobes, and difficult to distinguish from adenocarcinoma.^[37] CT helps in demonstrating extension of the prostatic abscess into adjacent organs and forming sinuses and fistulas with the perineum. T2W MR images demonstrate prostatic abscess as a heterogeneous high signal lesion with radiating streaky regions of low signal intensity giving the appearance of 'watermelon skin'.^[38] TRUS due to its ability for real time depiction of the prostatic anatomy, can help in transrectal biopsies and drainages.

Tubercular epididymitis is seen on US as homogeneous or heterogeneous hypoechoic, enlarged, nodular epididymis whereas tubercular orchitis is seen as multiple hypoechoic intratesticular nodules [Figure 9].^[9] Scrotal wall thickening,

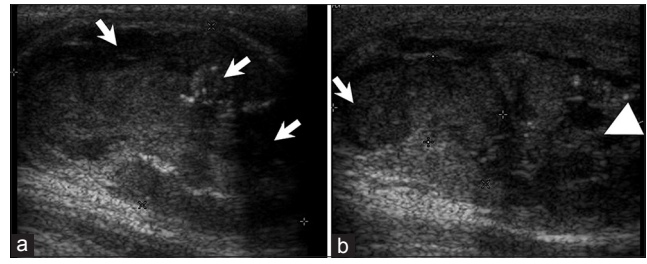


Figure 9: 31-year-old man with tubercular orchitis. (a, b) Longitudinal ultrasound images of the testis demonstrate enlarged, markedly heterogeneous hypoechoic appearance of the testis (arrows) with an ill-defined collection (arrowhead, b) in the lower pole.

abscess, sinus tracts, hydroceles, and calcifications are other findings seen in severe forms. MRI may show enlarged epididymis with low signal on T2W images in chronic cases due to chronic inflammation and fibrosis.^[10]

Female genital tuberculosis

The most common site of female genital tuberculosis is the fallopian tube which can be seen in 94% of patients.^[38] The second most common manifestation is tubercular endometritis, seen in 50% of cases with fallopian tube tuberculosis.^[10] Salpingitis is often bilateral and results in infertility. Conventional hysterosalpingography (HSG) remains the main stay for investigating fallopian tube patency. HSG findings include tubal occlusion, stricturing, rigid pipe stem tubes, endometritis with adhesions (causing Asherman syndrome), and T-shaped distortion of the endometrial cavity.^[39] US and CT allow for the evaluation of the adnexa, which may show tubo-ovarian abscesses and chronic calcifications [Figure 10]. MRI better demonstrates changes such as uterine adhesions, hydrosalpinx, and tubo-ovarian abscess [Figure 11].

IMAGING OF SOLID VISCERAL TUBERCULOSIS IN IMMUNOCOMPROMISED PATIENTS

Tuberculosis tends to be more often extra-pulmonary and widely disseminated in immunosuppressed patients. On imaging, tubercular lesions have a similar appearance to the lesions in immunocompetent patients. However, in severely immunosuppressed patients, the lesions tend to be larger with ill-defined margins. Miliary tuberculosis is more common in the immunocompromised patients, however the miliary nodules are poorly formed and may manifest just as organomegaly.^[7]

CONCLUSION

Although tuberculosis of solid abdominal organs is uncommon, awareness of the imaging findings is important both due to its increasing incidence and the fact that it may

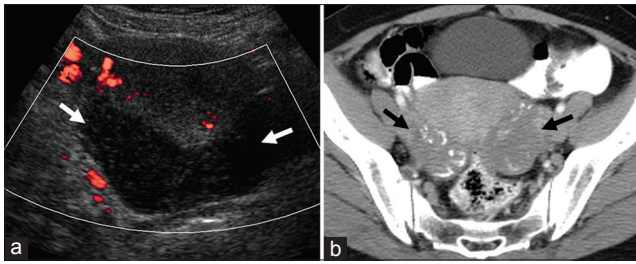


Figure 10: 26-year-old woman with chronic tubercular salpingo-oophoritis. (a) Transverse ultrasound image of the pelvis reveals hypoechoic masses (arrow) in both the adnexae. (b) Axial CECT image through the pelvis demonstrates bilateral tubo-ovarian masses with calcification (arrows).

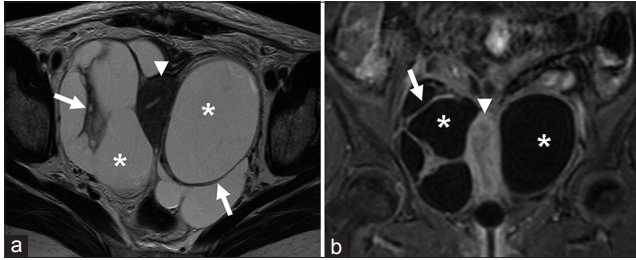


Figure 11: 38-year-old woman with chronic tubercular hydrosalpinges. (a) Axial T2W MR image reveals bilateral (asterisk) multi-loculated high signal intensity (arrows) adnexal lesions with intercommunicating loculi owing to incomplete septae suggestive of hydrosalpinges. (b) Coronal T1W fat suppressed postgadolinium (arrows) MR image demonstrates heterogeneous enhancement of the septations with no nodules. Note the compressed uterus in the midline (arrowhead).

mimic a variety of intra-abdominal pathologies. There is a wide ranging differential diagnosis for solid visceral organ tuberculosis on imaging. However, this diagnosis should be considered in individuals who are immunosuppressed, have other risk factors or have a history of pulmonary tuberculosis. To be sure, cross-sectional imaging features alone may be insufficient to reach a definitive diagnosis; and image-guided tissue sampling is often necessary.

REFERENCES

- Yang Z, Yang D, Kong Y, Zhang L, Marrs CF, Foxman B, et al. Clinical relevance of Mycobacterium tuberculosis plcD gene mutations. *Am J Respir Crit Care Med* 2005;171:1436-42.
- Gunal S, Yang Z, Agarwal M, Koroglu M, Arıcı ZK, Durmaz R. Demographic and microbial characteristics of extrapulmonary tuberculosis cases diagnosed in Malatya, Turkey, 2001-2007. *BMC Public Health* 2011;11:154.
- Sinan T, Sheikh M, Ramadan S, Sahwney S, Behbehani A. CT features in abdominal tuberculosis: 20 years experience. *BMC Med Imaging* 2002;2:3.
- Tan KK, Chen K, Sim R. The spectrum of abdominal tuberculosis in a developed country: A single institution's experience over 7 years. *J Gastrointest Surg* 2009;13:142-7.
- Vanhoenacker F, De Backer AI, Op de BB, Maes M, Van Altena R, Van Beckevoort D, et al. Imaging of gastrointestinal and abdominal tuberculosis. *Eur Radiol* 2004;14 Suppl 3:E103-15.
- Frieden TR, Sterling TR, Munsiff SS, Watt CJ, Dye C. Tuberculosis. *Lancet* 2003;362:887-99.
- Eastwood JB, Corbishley CM, Grange JM. Tuberculosis and the kidney. *J Am Soc Nephrol* 2001;12:1307-14.
- Gibson MS, Puckett ML, Shelly ME. Renal tuberculosis. *Radiographics* 2004;24:251-6.
- Matos MJ, Bacelar MT, Pinto P, Ramos I. Genitourinary tuberculosis. *Eur J Radiol* 2005;55:181-7.
- Jung YY, Kim JK, Cho KS. Genitourinary tuberculosis: Comprehensive cross-sectional imaging. *AJR Am J Roentgenol* 2005;184:143-50.
- Matsui N, Morita T. Magnetic resonance imaging as a clue to successful diagnosis of renal tuberculosis: A case report. *Cases J* 2009;2:8879.
- Izbudak-Oznur I, Sözen S, Işık S. Renal tuberculosis mimicking xanthogranulomatous pyelonephritis: Ultrasonography, computed tomography and magnetic resonance imaging findings. *Turk J Pediatr* 2002;44:168-71.
- Bhatt S, MacLennan G, Dogra V. Renal pseudotumors. *AJR Am J Roentgenol* 2007;188:1380-7.
- Levine C. Primary macronodular hepatic tuberculosis: US and CT appearances. *Gastrointest Radiol* 1990;15:307-9.
- Pereira JM, Madureira AJ, Vieira A, Ramos I. Abdominal tuberculosis: Imaging features. *Eur J Radiol* 2005;55:173-80.
- Leder RA, Low VH. Tuberculosis of the abdomen. *Radiol Clin North Am* 1995;33:691-705.
- Akhan O, Pringot J. Imaging of abdominal tuberculosis. *Eur Radiol* 2002;12:312-23.
- Brookes MJ, Field M, Dawkins DM, Gearty J, Wilson P. Massive primary hepatic tuberculoma mimicking hepatocellular carcinoma in an immunocompetent host. *MedGenMed* 2006;8:11.
- Cao BS, Li XL, Li N, Wang ZY. The nodular form of hepatic tuberculosis: Contrast-enhanced ultrasonographic findings with pathologic correlation. *J Ultrasound Med* 2010;29:881-8.
- Kawamori Y, Matsui O, Kitagawa K, Kadoya M, Takashima T, Yamahana T. Macronodular tuberculoma of the liver: CT and MR findings. *AJR Am J Roentgenol* 1992;158:311-3.
- Saluja SS, Ray S, Pal S, Kukeraja M, Srivastava DN, Sahni P, et al. Hepatobiliary and pancreatic tuberculosis: A two decade experience. *BMC Surg* 2007;7:10.
- Fan ZM, Zeng QY, Huo JW, Bai L, Liu ZS, Luo LF, et al. Macronodular multi-organs tuberculoma: CT and MR appearances. *J Gastroenterol* 1998;33:285-8.
- Lim J, Yu JS, Hong SW, Chung JJ, Kim JH, Kim KW. A case of mass-forming splenic tuberculosis: MRI findings with emphasis of diffusion-weighted imaging characteristics. *J Korean Med Sci* 2011;26:457-60.
- Drevelengas A. The spleen in infectious disorders. In: De Schepper AM, Vanhoenacker F, editors. *Medical Imaging of the Spleen*. Berlin, Heidelberg: Springer; 2000. p. 67-80.
- De Backer AI, Vanhoenacker FM, Mortelé KJ, Vanschoubroeck JJ, De Keulenaer BL, Parizel PM. MRI features of focal splenic lesions in patients with disseminated tuberculosis. *AJR Am J Roentgenol* 2006;186:1097-102.
- Morita S, Higuchi M, Takahata T, Honda H, Saito N, Suzuki K, et al. Magnetic resonance imaging for multiple macronodular localized splenic tuberculosis. *Clin Imaging* 2007;31:134-6.
- Porcel-Martin A, Rendon-Unceta P, Bascañana-Quirell A, Amaya-Vidal A, Rodriguez-Ramos C, Soria de la Cruz MJ, et al. Focal splenic lesions in patients with AIDS: Sonographic findings. *Abdom Imaging* 1998;23:196-200.
- Brooke AM, Monson JP. Addison's disease. *Medicine* 2005;33:20-2.
- Mayo-Smith WW, Boland GW, Noto RB, Lee MJ. State-of-the-art adrenal imaging. *Radiographics* 2001;21:995-1012.
- Guo YK, Yang ZG, Li Y, Ma ES, Deng YP, Min PQ, et al. Addison's disease due to adrenal tuberculosis: Contrast-enhanced CT features and clinical duration correlation. *Eur J Radiol* 2007;62:126-31.
- Yang ZG, Guo YK, Li Y, Min PQ, Yu JQ, Ma ES. Differentiation between tuberculosis and primary tumors in the adrenal gland: Evaluation with contrast-enhanced CT. *Eur Radiol* 2006;16:2031-6.

32. Zhang XC, Yang ZG, Li Y, Min PQ, Guo YK, Deng YP, et al. Addison's disease due to adrenal tuberculosis: MRI features. *Abdom Imaging* 2008;33:689-94.
33. Veerabadran P, Sasnur P, Subramanian S, Marappagounder S. Pancreatic tuberculosis-abdominal tuberculosis presenting as pancreatic abscesses and colonic perforation. *World J Gastroenterol* 2007;13:478-9.
34. Hong SG, Kim JS, Joo MK, Lee KG, Kim KH, Oh CR, et al. Pancreatic tuberculosis masquerading as pancreatic serous cystadenoma. *World J Gastroenterol* 2009;15:1010-3.
35. Evans JD, Hamanaka Y, Olliff SP, Neoptolemos JP. Tuberculosis of the pancreas presenting as metastatic pancreatic carcinoma. *Dig Surg* 2000;17:183-7.
36. McGuinness FE. Tuberculosis of the gastrointestinal tract and peritoneum. *Clinical Imaging in Non-Pulmonary Tuberculosis*. Berlin: Springer; 2000. p. 107-37.
37. Gupta N, Mandal AK, Singh SK. Tuberculosis of the prostate and urethra: A review. *Indian J Urol* 2008;24:388-91.
38. Engin G, Acunaş B, Acunaş G, Tunaci M. Imaging of extrapulmonary tuberculosis1 (CME available in print version and on RSNA Link). *Radiographics* 2000;20:471-88.
39. Chavhan GB, Hira P, Rathod K, Zacharia TT, Chawla A, Badhe P, et al. Female genital tuberculosis: Hysterosalpingographic appearances. *Br J Radiol* 2004;77:164-9.

Source of Support: Nil, **Conflict of Interest:** None declared.