

Transanal Endoscopic Video-Assisted Excision: Application of Single-Port Access

Madhu Ragupathi, MD, Eric M. Haas, MD

ABSTRACT

Background: Transanal endoscopic microsurgery is a safe and efficacious surgical approach for local excision of benign adenomas and early-stage rectal cancer. However, utilization of the technique has been limited due to the unavailability of high-priced specialized instrumentation at many institutions and the technically demanding training required. To avoid these obstacles, we have explored an alternative approach called Transanal Endoscopic Video-Assisted excision, which combines the merits of single-port access and local transanal excision.

Methods: A disposable single-incision port is inserted into the anal canal for transanal access. The port contains 3 cannulae for introducing instrumentation into the rectal lumen, and a supplementary cannula for carbon dioxide insufflation. Pneumorectum results in rectal distention and optimizes the visual field during the procedure. Standard laparoscopic instrumentation is utilized for visualization and transanal excision of rectal pathologies.

Conclusions: Transanal endoscopic video-assisted excision is an innovative approach to local excision of benign and malignant rectal lesions. The approach averts several of the pitfalls commonly experienced with transanal endoscopic microsurgery. Continued investigation and development of this novel modality will be important in establishing its role in minimally invasive surgery.

Key Words: Anal canal, Laparoscopy, Microsurgery, Rectal neoplasms.

INTRODUCTION

Transanal endoscopic microsurgery (TEM) is a safe and feasible minimally invasive surgical (MIS) approach for the treatment of benign adenomas and early-stage carcinomas of the rectum.¹ The modality facilitates removal of lesions not otherwise amenable to standard transanal excision (TAE), thereby extending the utility of MIS technique for polyps of the middle and upper rectum.² TEM provides enhanced visualization and precise excision, resulting in reduced length of hospital stay and low morbidity and mortality compared with low anterior resection (LAR) and abdominoperineal resection (APR).³

Nonetheless, several barriers have limited widespread adaptation of TEM, including the need for specialized instrumentation and the associated costs and steep learning curve of the technique.⁴ Recently, a novel platform combining single-port access with the principles of transanal excision has emerged as a practical approach averting the complexities inherent to TEM.⁵⁻⁷ A disposable SILS Port Multiple Instrument Access Port (Covidien, Mansfield, MA, USA) and standard laparoscopic instrumentation are used to perform local transanal excision in the middle and upper rectum. We present our technique and considerations for this innovative approach, which we call Transanal Endoscopic Video-Assisted (TEVA) excision.

MATERIALS AND METHODS

Transanal endoscopic video-assisted excision is performed using a disposable SILS Port and standard nonarticulating laparoscopic instrumentation. We have developed and refined our approach to facilitate safe excision of rectal pathologies and maintenance of oncologic principles.

Operative Technique

The patient is placed in the lithotomy position with legs elevated in "candy-cane" stirrups. The port is inserted and secured in the anal canal with interrupted 2-0 Vicryl (or silk) sutures. Trocars (two 5-mm and one 12-mm) are placed into the cannulae on the port. Pneumorectum is established and maintained with carbon dioxide (CO₂) insufflation. A laparoscopic 30° camera (5-mm trocar), a

Division of Minimally Invasive Colon and Rectal Surgery, Department of Surgery, University of Texas Medical School at Houston, Houston, Texas, USA (all authors).

The SILS port (Covidien, Mansfield, MA, USA) is presently marketed and distributed for use as an access device for minimally invasive single-incision surgical procedures.

Address correspondence to: Eric M. Haas, MD, Colorectal Surgical Associates Ltd, LLP, 7900 Fannin, Suite 2700, Houston, TX 77054, USA. Telephone: (713) 790-0600, Fax: (713) 790-0616, E-mail: ehaasmd@houstoncolon.com

DOI: 10.4293/108680810X12924466009005

© 2011 by JSLS, *Journal of the Society of Laparoendoscopic Surgeons*. Published by the Society of Laparoendoscopic Surgeons, Inc.

5-mm atraumatic grasper (5-mm trocar), and a pencil hook bovie cautery (12-mm trocar) are introduced into the rectum. The lesion is circumferentially scored at 1 to 2 cm from its edges and gently retracted, followed by full-thickness excision through the muscularis propria into the perirectal fat (mesorectum). The lesion is subsequently removed in a specimen bag through the 12-mm trocar. The wall defect is approximated and primarily closed using interrupted 2-0 Vicryl sutures. Final surveillance ensures proper defect closure, hemostasis, and luminal patency. The instruments and port are removed.

DISCUSSION

Transanal endoscopic video-assisted excision is a safe and feasible approach for the management of middle and upper rectal lesions not amenable to traditional transanal excision. Furthermore, the approach capitalizes on the benefits of local TAE⁸ while avoiding the technical limitations and the steep costs associated with TEM.^{9,10} The procedure utilizes readily available surgical instrumentation, requires minimal setup, and translates well to the experienced laparoscopic surgeon. Our developed approach is intended for safe local excision with maintenance of oncologic principles¹¹ and reduction of the obstacles that have limited broad implementation of TEM. TEVA excision may prove to be a viable alternative to TEM; however, several technical considerations should be taken into account for proper application of this novel platform.

Patient Positioning

Patient positioning is critical for performing TEM and is influenced by the location of the tumor and the nature of the operative equipment.¹² The patient is placed in the position that best centers the target lesion in the lower half of the visual field (6 o'clock position): prone jackknife for anterior wall lesions, lithotomy for posterior wall lesions, and lateral decubitus for sidewall lesions.¹³ This provides proper orientation for the surgeon utilizing specialized TEM instrumentation that remains fixed to the operating table throughout the procedure.

Unlike traditional TAE and TEM, positioning for TEVA excision is independent of the location of the lesion. The ideal position is lithotomy with legs elevated in "candy-cane" stirrups. This position promotes exposure and excision of lesions situated in any quadrant of the rectal lumen. The laparoscopic instrumentation used for TEVA excision is not secured to the operating table as is required for TEM and the setup provides unimpeded deep and

lateral instrument motion. Utilization of the lithotomy position may be associated with decreased risk for position-related nerve injuries^{14–16} and loss of airway control^{17,18} considered most often with the prone position.

Device Setup for Access to the Rectal Lumen

Intra-rectal access for TEM is achieved through a 4-cm (40-mm) beveled operating rectoscope.¹⁹ The scope allows excision of lesions up to 25 cm from the anal verge; however, repeated readjustments may be necessary to center the lesion for excision. A glass face-piece with airtight working ports is used to seal the scope's external end, creating a closed pressurized system. If a leak develops in the system, such as from damaged rubber sleeves and caps on the ports, the rectum will collapse and visualization will be obscured. Troubleshooting can become very time-consuming and arduous, thereby extending operative times, prolonging anal dilation, and possibly leading to anorectal dysfunction.^{20–23}

The SILS port provides access to the rectal lumen for TEVA excision. The device is inserted into the anal canal using steady manual pressure (**Figure 1a**). Anal dilation and lubricant are not required due to the flexible nature of the SILS port. Constructed from a mixture of elastic polymers, the soft pliable material affords insertion through a 2-cm (20-mm) incision routinely used for single-incision laparoscopic surgery. When utilized for TAE, the SILS port's dimensions (approximately 30-mm diameter waist) and malleable design conform to the structure of the anal canal. TEVA excision may be associated with reduced sphincter strain and consequently, a lower incidence of postoperative anorectal dysfunction. However, comprehensive evaluation must be undertaken to verify this potential benefit.

The outer diameter (approximately 50 mm) of the SILS port creates a seal against the perianal skin for prevention of CO₂ leakage. Interrupted silk or 2-0 Vicryl sutures may be used to secure the port, (**Figure 1b and 1c**), especially if presented with a patulous anus. Though once fixed, the port cannot be freely rotated, an important maneuver that may aid in optimizing access to the targeted lesion. One 12-mm and two 5-mm trocars are inserted into the cannulae on the port (**Figure 1d**), and pneumorectum is established with CO₂ insufflation.

Optical and Surgical Instrumentation

A binocular stereoscopic eyepiece is used for visualization during TEM.²⁴ The stereoscope provides a 3-dimensional field of view with 6-fold magnification for precise excision, while an accessory scope offers a 2-dimensional field

of view for the assistants. A wide array of surgical instrumentation has been developed; however, despite these advancements, the technique remains unchanged.^{25,26} TEM is performed with instruments and optics in parallel (collinear) alignment, often resulting in repetitive clashing and loss of the air seal. As a result, the learning curve for TEM remains steep.

Standard laparoscopic instrumentation is utilized for TEVA excision. A laparoscopic 30° camera, a 5-mm atraumatic grasper, and a bovie cautery or comparable thermal energy device are introduced into the rectal lumen through the anterior 5-mm (12-o'clock), left lateral 5-mm (8-

o'clock), and right lateral 12-mm trocars (4-o'clock), respectively (**Figure 2**). A laparoscopic 45° camera may help overcome limited visualization of lesions situated behind the second or third haustral folds. The video systems used for conventional laparoscopy are utilized. A right-angle light cord adaptor (KARL STORZ Endoscopy, El Segundo, CA, USA) should be used to reduce potential external clashing of instruments and camera (**Figure 3**).

Internal crossing of instruments provides ample triangulation and retraction, limiting external clashing during TEVA excision. This allows the procedure to be performed with technical principles similar to those of single-

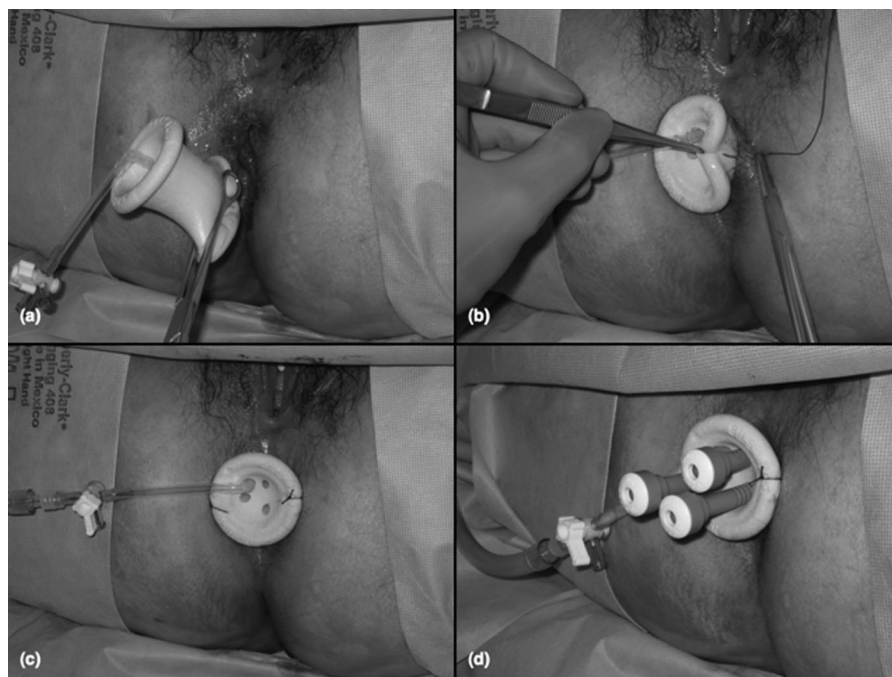


Figure 1. Introduction of the SILS™ port into the anal canal with manual pressure (**a**). Securing the SILS port to the perianal skin with silk sutures (**b, c**). The SILS port with the trocars inserted through the cannulae (**d**).

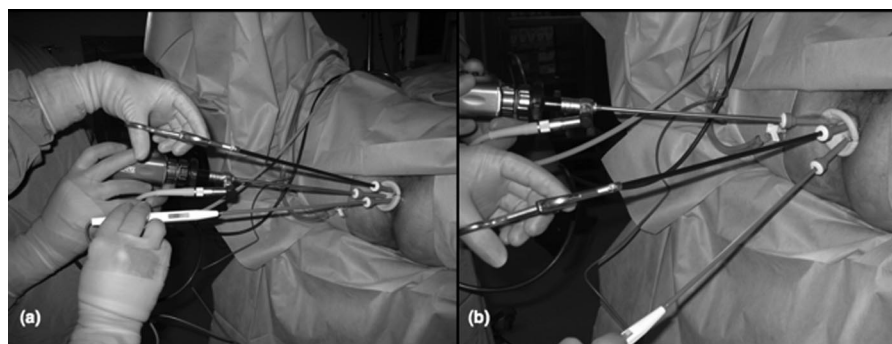


Figure 2. Introduction of laparoscopic camera and instruments into the rectal lumen (**a**). The flexible nature of the port allows increased range of motion with laparoscopic instrumentation (**b**).



Figure 3. Right angle light cord adaptor used for TEVA excision.

incision laparoscopic surgery.²⁷ The location of the lesion may influence instrument insertion; the arrangement that provides the most optimal retraction and thorough excision should be used. In addition, alternating retraction and dissection between hands (instruments) eliminates the need for variable patient positioning. Parallel or colinear dissection may be utilized at the surgeon's discretion; however, this may limit the effective working area during the procedure.

Articulating instrumentation is not required for TEVA excision as these tools may prove to be cumbersome and less intuitive. Ultimately, the complexity of the procedure (learning curve) and the risk for inadvertent trauma may be increased. Similarly, a flexible tip camera may not enhance the procedure because the rectal circumference is too small to effectively capitalize on its visual advantages. The camera may frequently become cloudy or hazy, adding additional time to the procedure as repeated cleaning becomes mandatory for maintaining a proper visual field. In addition, use of specialized instrumentation may result in increased cost for the procedure.

Excision and Maintenance of Oncologic Principles

Similar to the technique used for TEM,²⁸ the lesion is identified and circumferentially scored at 1 to 2cm from its edges, ensuring that adequate oncologic margins are obtained during TEVA excision. We utilize a bovie cautery with an Opti2 Laparoscopic Wire L Hook Tip Electrode (Valleylab, Covidien, Mansfield, MA, USA) for scoring and excision. However, other energy sources or electrodes, such as a monopolar hook or a bovie spat-

ula, may be used for this approach. Excision should be performed at a tangential angle to the elevated lesion to guarantee a full-thickness (cylindrical) specimen. Therefore, a Harmonic scalpel should be avoided as this can result in an inadequate oblique (conical) specimen. A linear stapler may prove particularly advantageous for benign, pedunculated, wide-stalked polyps but should be avoided for malignant lesions for which adequate margins are crucial. Following excision, the lesion is subsequently placed in an Endo Catch specimen pouch (Autosuture, Covidien, Mansfield, MA, USA) and removed.

Closure of Defect

A laparoscopic needle driver is ideal for primary closure of the rectal wall following TEVA excision. If an SH needle is used, a 5-mm trocar will need to be replaced with a 10-mm trocar for introduction and removal of the needle. Alternatively, a 3-mm laparoscopic needle driver and RB-1 needle may be used through a 5-mm trocar, thus avoiding unnecessary trocar exchange. Regardless of needle size, intraluminal knot tying can be readily achieved in any quadrant of the rectal wall. A knot pusher should be avoided as this may result in loss of pneumorectum. If laparoscopic suturing and knot tying prove to be overly challenging or complex, a LaparoClip (Davis and Geck, Danbury, CT, USA) or Lapra-Ty absorbable suture clip (Ethicon Endo-Surgery, Inc., Cincinnati, OH, USA) may be used, although this will likely increase the overall cost of the procedure.

Final Surveillance

Final surveillance is performed to ensure preservation of an intact suture line with proper hemostasis. The camera and instruments are removed, followed by the SILS port.

Cost

Although very early in its utilization, TEVA excision offers several potential benefits over TEM, including a lower learning curve and a reduced cost. The TEM rectoscope and insufflation system alone cost an estimated \$75,000 to \$85,000,²⁹ which is considerably greater than the cost of the SILS port, approximately \$500 to \$600. This difference does not reflect the costs associated with the optical and surgical instrumentation, which will likely further amplify this discrepancy to a greater extent. As such, TEVA excision may emerge as a favorable cost-effective modality for palliative

cases in patients not able to tolerate more invasive procedures, such as LAR or APR.

Limitations

Nevertheless, TEVA excision does have its limitations. The platform does not currently offer an equal level of rectal access (reach) compared with TEM (15 to 18cm versus 20 to 25cm). In addition, there is a tendency for smoke to obscure the surgical field during excision, although use of a smoke evacuator or small pulse suctioning (lasting only a few seconds at a time) may improve the visual field. Excessive or continuous suction will result in immediate collapse of the rectal lumen. Larger comparative studies will be needed to establish the overall efficacy of TEVA excision with regard to complication rate, recurrence rate, and overall survival. Still, this innovative approach represents a step toward the development of efficacious and cost-effective modalities for local management of benign and malignant rectal lesions.

CONCLUSION

Transanal endoscopic video-assisted excision offers an appealing alternative to transanal endoscopic microsurgery. The approach affords a relatively inexpensive platform with excellent exposure and adaptability for local transanal excision of middle and upper rectal tumors. Experienced laparoscopic surgeons will be able to perform the procedure with minimal training by applying principles of both conventional and single-incision laparoscopic surgery. Although many of the pitfalls associated with transanal endoscopic microsurgery may be averted, this new technique is not without its own limitations. Still very early in its infancy, the potential impact of transanal endoscopic video-assisted excision is promising. Ultimately, additional experience with the technique and advancements in instrumentation will be essential at extending its utility.

References:

1. Platell C. Transanal endoscopic microsurgery. *Aust NZ J Surg.* 2009;79:275–280.
2. Buess G, Mentges B, Manncke K, Starlinger M, Becker HD. Minimal invasive surgery in the local treatment of rectal cancer. *Int J Colorectal Dis.* 1991;6:77–81.
3. Dias AR, Nahas CS, Marques CF, Nahas SC, Ceconello I. Transanal endoscopic microsurgery: indications, results and controversies. *Tech Coloproctol.* 2009;13:105–111.
4. Middleton PF, Sutherland LM, Maddern GJ. Transanal endoscopic microsurgery: a systematic review. *Dis Colon Rectum.* 2005;48:270–284.
5. Atallah S, Albert M, Larach S. Transanal minimally invasive surgery: a giant leap forward. *Surg Endosc.* 2010;DOI:10.1007/s00464-010-0927-z.
6. Lorenz C, Nimmesgern T, Back M, Langwieler TE. Transanal single port microsurgery (TSPM) as a modified technique of transanal endoscopic microsurgery (TEM). *Surg Innov.* 2010;17:160–163.
7. Khoo RE. Transanal excision of a rectal adenoma using single-access laparoscopic port. *Dis Colon Rectum.* 2010;53:1078–1079.
8. Bretagnol F, Merrie A, George B, Warren BF, Mortensen NJ. Local excision of rectal tumours by transanal endoscopic microsurgery. *Br J Surg.* 2007;94:627–633.
9. Fucini C, Segre D, Trompetto M. Local excision of rectal polyp: indications and techniques. *Tech Coloproctol.* 2004;8:s300–s304.
10. Demartines N, von Flüe MO, Harder FH. Transanal endoscopic microsurgical excision of rectal tumors: indications and results. *World J Surg.* 2001;25:870–875.
11. Lynch ML, Brand MI. Preoperative evaluation and oncologic principles of colon cancer surgery. *Clin Colon Rectal Surg.* 2005;18:163–173.
12. Buess G, Kipfmüller K, Hack D, Grüssner R, Heintz A, Junginger T. Technique of transanal endoscopic microsurgery. *Surg Endosc.* 1988;2:71–75.
13. Christoforidis D, Cho HM, Dixon MR, Mellgren AF, Madoff RD, Finne CO. Transanal endoscopic microsurgery versus conventional transanal excision for patients with early rectal cancer. *Ann Surg.* 2009;249:776–782.
14. Larach SW, Gallagher JT. Complications of laparoscopic surgery for rectal cancer: avoidance and management. *Semin Surg Oncol.* 2000;18:265–268.
15. Trottier DC, Martel G, Boushey RP. Complications in laparoscopic intestinal surgery: prevention and management. *Minerva Chir.* 2009;64:339–354.
16. Roig-Vila JV, García-Armengol J, Bruna-Esteban M, Redondo-Cano C, Tornero-Ibáñez F, García-Aguado R. Operating position in colorectal surgery. The importance of the basics. *Cir Esp.* 2009;86:204–212.
17. Read TE, Henry SE, Hovis RM, et al. Prospective evaluation of anesthetic technique for anorectal surgery. *Dis Colon Rectum.* 2002;45:1553–1560.
18. McCaul CL, Harney D, Ryan M, Moran C, Kavanagh BP, Boylan JF. Airway management in the lateral position: a randomized controlled trial. *Anesth Analg.* 2005;101:1221–1225.

19. Mentges B, Buess G, Schäfer D, Manncke K, Becker HD. Local therapy of rectal tumors. *Dis Colon Rectum*. 1996;39:886–892.
20. Jin Z, Yin L, Xue L, Lin M, Zheng Q. Anorectal functional results after transanal endoscopic microsurgery in benign and early malignant tumors. *World J Surg*. 2010;34:1128–1132.
21. Gracia Solanas JA, Ramírez Rodríguez JM, Aguilera Diago V, Elía Guedea M, Martínez Díez M. A prospective study about functional and anatomic consequences of transanal endoscopic microsurgery. *Rev Esp Enferm Dig*. 2006;98:234–240.
22. Doornebosch PG, Tollenaar RA, Gosselink MP, et al. Quality of life after transanal endoscopic microsurgery and total mesorectal excision in early rectal cancer. *Colorectal Dis*. 2007;9:553–558.
23. Dafnis G, Pählman L, Raab Y, Gustafsson UM, Graf W. Transanal endoscopic microsurgery: clinical and functional results. *Colorectal Dis*. 2004;6:336–342.
24. Saclarides TJ. TEM/local excision: indications, techniques, outcomes, and the future. *J Surg Oncol*. 2007;96:644–650.
25. Neary P, Makin GB, White TJ, et al. Transanal endoscopic microsurgery: a viable operative alternative in selected patients with rectal lesions. *Ann Surg Oncol*. 2003;10:1106–1111.
26. Guerrieri M, Baldarelli M, de Sanctis A, Campagnacci R, Rimini M, Lezoche E. Treatment of rectal adenomas by transanal endoscopic microsurgery: 15 years' experience. *Surg Endosc*. 2010;24:445–449.
27. Ramos-Valadez DI, Patel CB, Ragupathi M, Bartley Pickron T, Haas EM. Single-incision laparoscopic right hemicolectomy: safety and feasibility in a series of consecutive cases. *Surg Endosc*. 2010. DOI: 10.1007/s00464-010-1017-y, April 03, 2010.
28. Azimuddin K, Riether RD, Stasik JJ, Rosen L, Khubchandani IT, Reed JF 3rd. Transanal endoscopic microsurgery for excision of rectal lesions: technique and initial results. *Surg Laparosc Endosc Percutan Tech*. 2000;10:372–378.
29. Denk PM, Swanström LL, Whiteford MH. Transanal endoscopic microsurgical platform for natural orifice surgery. *Gastrointest Endosc*. 2008;68:954–959.