

Prospective evaluation of wipe-out after glaucoma filtration surgery in eyes with split fixation

Tania Ray Bhadra, Rudra Prosad Ghosh¹, Kumar Saurabh², Ankita Mitra, Asim Kumar Ghosh, Tanmoy Bhadra³

Purpose: To assess the incidence and cause of idiopathic, irreversible loss of vision (“wipe-out”) in the early post-operative period after glaucoma-filtration surgery in advanced glaucoma. **Methods:** It was a prospective, interventional cohort study. Patients with advanced glaucoma and macular split fixation underwent either only trabeculectomy (group A) or combined phaco-emulsification with trabeculectomy (group B). The incidence and cause of visual loss, changes in intra-ocular pressure, visual acuity, and visual field indices during 2 months post surgery were assessed. **Results:** Thirty patients (30 eyes) were divided in two groups. No significant difference was noted between the pre-operative and post-operative mean deviations in both groups ($P = 0.41$, $P = 0.65$). Two eyes in group A and one eye in group B had visual loss of two lines or more at the end of 2 months because of cataract and choroidal detachment. None of the eyes showed “wipe-out”. **Conclusion:** “Wipe-out” is a rare phenomenon after surgery in advanced glaucoma.

Key words: Glaucoma-filtering surgery, split fixation, wipe-out

Access this article online

Website:

www.ijo.in

DOI:

10.4103/ijo.IJO_501_22

Quick Response Code:



The “wipe-out” phenomenon is defined as idiopathic and irreversible loss of central vision in eyes with advanced glaucoma after filtration surgery.^[1-3] Costa *et al.*^[3] have reported a 0.75% incidence, whereas Kolker *et al.*^[2] have reported a 13.6% incidence of wipe-out. A few known causes of vision loss after glaucoma-filtering surgery are hypotony, supra-choroidal hemorrhage, cataract, cystoid macular edema, and retrobulbar anesthesia causing trauma to optic nerve and vascular structures.^[1-6] Macular split fixation is another important risk factor for wipe-out.^[3]

The aim of our study was to assess the incidence of visual loss in the early post-operative period (2 months) in eyes with advanced glaucoma and split fixation undergoing filtration surgery, to identify the causes for the visual loss, and to assess the changes in the central visual field after surgery.

Methods

A prospective, institution-based, interventional cohort study was conducted after approval from the Institutional Review Board and Ethics Committee. All study procedures conformed to the Tenets of the Declaration of Helsinki for research involving human subjects. Informed consent was obtained from all patients participating in the study.

Thirty patients (30 eyes) diagnosed with advanced glaucomatous field loss (stages 3 and 4, Richard Mills

classification^[7]) with macular split fixation were enrolled for the study. Split fixation was defined as retinal sensitivity of “0” dB in all four locations tested, in at least one quadrant of the macular threshold program of the Humphrey field analyzer, size III stimulus (HFAII, Version 750; Carl Zeiss Meditec Inc.) [Fig. 1].^[8] Only patients with good reliability indices, that is, fixation losses of <20% and false positive and false negative responses of <33%, were included. Patients with visual acuity too poor to undergo visual field examination and those with central vision loss because of retinal or neurological pathologies other than glaucoma were excluded. All patients were on more than three anti-glaucoma medications with intra-ocular pressure (IOP) >25 mm of Hg. There was no loss to follow-up. Patients were recruited in this study between March 2020 and March 2021.

The patients were divided into two groups, A and B (15 patients each). Group A patients underwent only trabeculectomy with mitomycin C, and group B patients underwent phaco-emulsification with trabeculectomy and mitomycin C in a single sitting. A detailed pre-operative examination was carried out for all the patients 1 week before the surgery. The history of systemic disorders, previous surgeries and laser procedures performed, and the number of glaucoma medications used were noted. The best corrected visual acuity (BCVA) was measured using the Snellen chart and then converted to logMAR (logarithm of the reciprocal of the minimal

Department of Ophthalmology, Regional Institute of Ophthalmology, Medical College Kolkata, West Bengal, ¹Department of Ophthalmology, Rampurhat Govt Medical College, Birbhum, West Bengal, ²Netralayam Supespeciality Eye Hospital, Mukundpur, Kolkata, ³Department of Anaesthesiology, IPGMER, Kolkata, West Bengal, India

Correspondence to: Dr. Rudra Prosad Ghosh, Department of Ophthalmology, Rampurhat Govt Medical College, Birbhum - 731 224, West Bengal, India. E-mail: docrpg_2000@yahoo.com

Received: 21-Feb-2022

Revision: 14-Apr-2022

Accepted: 21-Jun-2022

Published: 30-Sep-2022

This is an open access journal, and articles are distributed under the terms of the Creative Commons Attribution-NonCommercial-ShareAlike 4.0 License, which allows others to remix, tweak, and build upon the work non-commercially, as long as appropriate credit is given and the new creations are licensed under the identical terms.

For reprints contact: WKHLRPMedknow_reprints@wolterskluwer.com

Cite this article as: Bhadra TR, Ghosh RP, Saurabh K, Mitra A, Ghosh AK, Bhadra T. Prospective evaluation of wipe-out after glaucoma filtration surgery in eyes with split fixation. Indian J Ophthalmol 2022;70:3544-9.

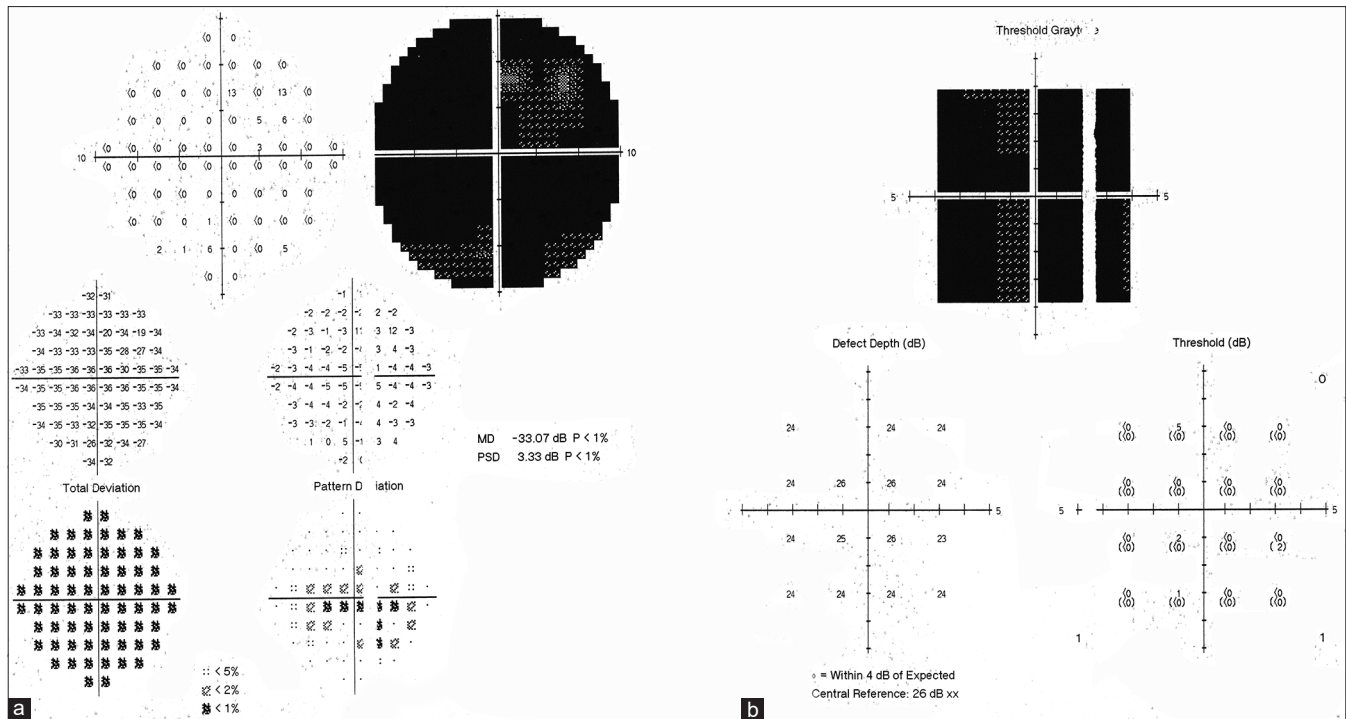


Figure 1: (a) Central 10-2 HFA showing loss of the central visual field; (b) Macular threshold program of HFA showing a retinal sensitivity of “0” dB in all four locations tested in two quadrants, that is, split fixation

angle of resolution). Slit lamp bio-microscopic examination, IOP measurements using Goldmann applanation tonometry, gonioscopy using a Goldmann4-mirrrolens, optic disc evaluation with a Volk 90D lens, and indirect ophthalmoscopy using a Volk 20D lens were performed. The lens status was noted and graded using LOCS III classification (The Lens Opacities Classification System III).^[9] Visual field examination was conducted using a Humphrey field analyzer (HFA), the SITA Standard program with the Central 24-2 strategy, the Central10-2 strategy, and the macular threshold test using the size III stimulus, with the appropriate refractive correction.

Peri-bulbar anesthesia was used in all the patients. Details of the surgical technique performed along with the use, dosage, and duration of application of the anti-metabolite were noted. Trabeculectomy with mitomycin C (0.4mg/mL with a duration of exposure of 1 minute) was performed for 15 patients, and trabeculectomy combined with phaco-emulsification and foldable intra-ocular lens implantation with mitomycin C (0.2/0.4mg/mL) at the surgeon’s discretion (a duration of exposure of 1 minute) was performed for the rest 15 patients in the same sitting. Any intra-operative complication was noted. Patients were examined on the first and 15th post-operative days and then again on day 30, and final examination was on day 60 (2 months post-operative). On each visit, BCVA and IOP measurements were performed. Both anterior and posterior segments of the eye were examined thoroughly, and any post-operative complication was noted. In the event of drop in vision by two lines or more from the pre-operative level, the cause was thoroughly investigated, and they underwent macular scan optical coherence tomography (OCT) (Spectralis SDOCT, Heidelberg) to identify any macular pathology likely to result in a drop in visual acuity. Anterior chamber reaction (cells and flare) was graded as per the SUN

classification (Standardization of Uveitis Nomenclature). The lens status was noted and graded in group A patients using the LOCS III classification system^[9] by a single examiner who was blinded to the pre-operative grade. If the posterior segment could not be examined because of dense cataract, an ultrasound B scan was performed for the patient.

Hypotony was defined as IOP <6 mm of Hg and was considered to be transient if there was improvement by the 60th day visit and persistent if it was present at the last visit. Hypotony maculopathy was defined as the appearance of chorioretinal folds in the macular area visualized using a 90D lens on slit lamp bio-microscopy. In the eyes with hypotony, the presence or absence of a wound leak and/or a choroidal detachment were specifically documented. The visual field examination was repeated on the 60th post-operative day by the SITA standard test strategy with the Central 24-2, Central 10-2, and macular threshold programs. Visual field examinations were to be repeated if any patient developed a “wipe-out” to exclude the effect of fluctuation. Wipe-out was defined as loss of the central visual field with retinal sensitivity measured as “0” dB in the four points abutting fixation on both the Central 10-2 test and the macular threshold program, associated with a decrease in visual acuity of 2 lines or more.

Results

Baseline characteristics of the patients of both groups A and B are given in Table 1. The mean age of group A was 57.93 ± 9.13 years, and that of group B was 59.4 ± 8.89 years. Nine patients (60%) in group A and eight patients (53.3%) in group B had primary open-angle glaucoma, five patients (33.3%) in group A and six patients (40%) in group B had primary angle-closure glaucoma, and the rest had secondary glaucoma.

The baseline visual acuity (LogMAR) in group A was 1.43 ± 0.69 and that in group B was 1.52 ± 0.75 , whereas the baseline IOP in group A was 39.3 ± 7.84 mm of Hg and that in group B was 37.87 ± 7.14 mm of Hg. The average mean deviation (MD) pre-operatively was -24.17 ± 5.44 dB in group A and -24.34 ± 6.07 dB in group B. Three patients (20%) in group A and five patients (33.3%) in group B had a stage III field defect, whereas 12 patients (80%) in group A and ten patients (66.7%) in group B had a stage IV field defect.

The mean visual acuity (LogMAR) on the first post-operative day dropped to 2.28 ± 0.75 from 1.43 ± 0.69 pre-operatively

Table 1: Baseline characteristics of patients

Baseline Characteristics	Group A (n=15)	Group B (n=15)
Age (Years)		
Mean	57.93±9.13	59.4±8.89
Range	45-75	44-72
Gender		
Males : Females	8:7	8:7
Type Of Glaucoma		
Primary Open-Angle Glaucoma (%)	9 (60%)	8 (53.3%)
Primary Angle-Closure Glaucoma (%)	5 (33.3%)	6 (40%)
Secondary Glaucoma (%)	1 (6.7%)	1 (6.7%)
Systemic Disorder		
Diabetes (%)	2 (13.3%)	2 (13.3%)
Hypertension (%)	7 (46.7%)	7 (46.7%)
Both (%)	3 (20%)	3 (20%)
Visual Acuity (LOGMAR)		
Mean	1.43±0.69	1.52±0.75
Range	0.2-3	0.3-3
Baseline IOP (mm Hg)		
Mean	39.3±7.84	37.87±7.14
Range	28-50	28-50
No. of Anti-glaucoma Medications		
Mean	3.4±0.51	3.4±0.51
Range	3-4	3-4
Visual Field Mean Deviation (dB)		
Mean	-24.17±5.44-18.56	-24.34±6.07-17.5
Range	to -33.35	to -33.75
No. of Patients with a Stage 3 Defect	3 (20%)	5 (33.3%)
No. of Patients with a Stage 4 Defect	12 (80%)	10 (66.7%)
Foveal Threshold (dB)		
Mean	11.3±10.32	8.13±7.95
Range	0-28	0-22
Mean Threshold of Four Central Test Points on C-10-2 Test (Db)		
Mean	11.06±5.76	11.02±5.12
Range	4-26.26	5.3-21.5
No. of Quadrants of Split Fixation		
Mean	1.33±0.49	1.53±0.52
Range	1-2	1-2

in group A, whereas in group B, it dropped to 2.25 ± 0.67 from 1.52 ± 0.75 pre-operatively. The causes for the drop in vision by more than two lines could be ascertained in eight eyes (53.33%) in group A and five eyes (33.33%) in group B and included choroidal detachment in two eyes, a persistently shallow anterior chamber in two eyes, post-operative hyphema in two eyes, anterior chamber reaction in three eyes, and corneal edema in four eyes. There was improvement in mean visual acuity by 2 months and was 1.52 ± 0.69 in group A and 1.47 ± 0.78 in group B. Patients in both group A and group B did not show any significant improvement in visual acuity ($p > 0.05$) [Tables 2a and 2b]. Two eyes (13.33%) in group A and one eye in group B (6.67%) had a loss of vision by >2 lines, which improved by 2 months, with the reason identified as a persistent choroidal detachment in two eyes and cataractous lens changes in one eye in group A. None of the patients developed "wipe-out".

The mean IOP on the first post-operative day dropped to 11.13 ± 4.67 mm of Hg from 39.33 ± 7.84 mm of Hg pre-operatively in group A, whereas in group B, it dropped from 37.86 ± 7.14 to 11.27 ± 4.73 mm of Hg. One patient in group A and one patient in group B developed prolonged hypotony with a fall in visual acuity, which improved by 2 months. There was no associated hypotony maculopathy. The mean central retinal thickness using the fast macular scan of the OCT in the eyes with hypotony was $241.5 \pm 7.77\mu$. No evidence of chorioretinal folds was detected with OCT. The mean visual acuity (LogMAR) in the group with hypotony at end of 2 months (1.6 ± 0.42) was not very different from the mean of groups A and B (1.52 ± 0.69 and 1.47 ± 0.78 , respectively). One patient in group A developed a spike in IOP to 25 mm of Hg on the first post-operative day, and the cause was ascertained to hyphema, which gradually resolved within 7 days with a fall in IOP.

There was no significant difference in the mean deviation (MD) after surgery in both the groups ($p > 0.05$) [Tables 2a and 2b, Fig. 2]. A change in the MD by >2 dB was also analyzed. The MD improved by >2 dB in one eye (6.67%) in group A and in one eye (6.67%) in group B and worsened by >2 dB in one eye (6.67%) in group A. There was no worsening of the MD in any eyes in group B. There was also no significant difference in the foveal threshold and mean threshold of the four central

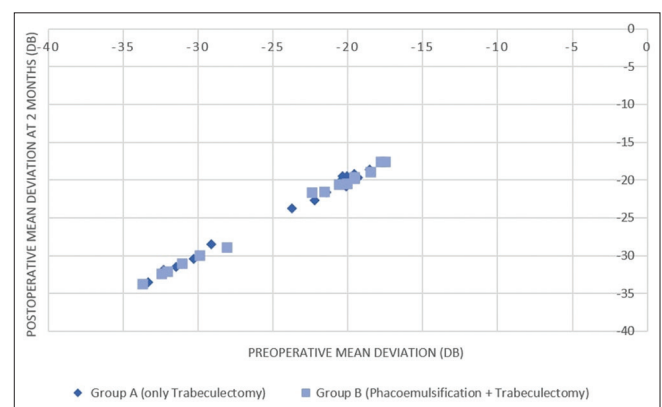


Figure 2: Scatter Plot comparing preoperative mean deviation with postoperative mean deviation measured after 2 months in Group A and Group B

Table 2(a): Post-operative Data of Group A

	Pre-Operative	Post-Operative 2 Months	Mean Difference (95% CI)	P
Mean IOP (mm Hg)	39.33±7.84	13.6±1.72	25.73±8.31 (12,40)	0.0001
Mean BCVA (LogMAR)	1.43±0.69	1.52±0.69	0.02±0.11 (-0.2,0.2)	0.48
Mean deviation (dB)	-24.17±5.45	-24.08±5.46	0.091±0.45 (-0.68,0.9)	0.41
Mean threshold of four central test points on C-10-2 test (dB)	11.06±5.76	11.08±5.83	0.025±0.16 (-0.4,0.44)	0.57
Foveal Threshold (dB)	11.23±10.32	11.97±10.55	-0.7±1.81 (-5,2)	0.15
No. of quadrants of split fixation	1.33±0.49	1.33±0.49	-0.133±0.35 (-1,0)	0.16

Table 2(b): Post-operative data of Group B

	Pre-Operative	Post-Operative 2 Months	Mean Difference (95% CI)	P
Mean IOP (mm Hg)	37.86±7.14	13.33±2.09	24.53±7.77 (14,38)	0.0001
Mean BCVA (LogMAR)	1.52±0.75	1.47±0.78	0.05±0.12 (-0.2,0.3)	0.17
Mean deviation (dB)	-24.37±6.08	-24.37±6.07	-0.04±0.35 (-0.78,0.8)	0.65
Mean threshold of four central test points on C-10-2 test (dB)	11.02±5.12	11.1±5.21	0.084±0.14 (0,0.5)	0.41
Foveal Threshold (dB)	8.13±7.95	9.34±8.76	-1.2±1.59 (-4.87,0)	0.21
No. of quadrants of split fixation	1.53±0.52	1.4±0.50	-0.13±0.35 (-1,0)	0.16

test points on the Central 10-2 test result in both groups A and B ($p > 0.05$). The number of quadrants with split fixation remained the same in all eyes, and there was no statistical difference between pre-operative and post-operative 2-month values in both groups A and B [Tables 2a and 2b].

HypHEMA, anterior chamber reaction, corneal edema, choroidal detachment with a persistently shallow anterior chamber, and cataract were the common post-operative complications in both groups A and B. HypHEMA was seen in two eyes (13.33%) and was more than two thirds of the anterior chamber in one eye. Both were managed conservatively with the head placed in the propped-up position and topical and oral steroids and IOP-lowering agents, and they cleared spontaneously within 7 days. Two eyes (13.33%) in group A and one eye (6.67%) in group B had significant anterior chamber reaction more than ± 2 grade on the first post-operative day, and all three cleared within 7 days after treatment with topical steroids and cycloplegics. Two eyes (13.33%) in group A and two eyes (13.33%) in group B had corneal edema on the first post-operative day, of which one had Descemet's membrane detachment intra-operatively and all four cleared within seven days. Choroidal detachment was seen in two eyes (one each in group A and group B), which was managed conservatively with topical steroids, cycloplegics, and systemic steroids. All the eyes that presented with choroidal detachment with a shallow anterior chamber recovered completely within a period of 3 weeks to 1 month after surgery, and none required surgical intervention. Cataractous change of the lens was seen in one eye in group A at the end of 2 months post-operative period [Table 3].

Discussion

Studies on loss of vision after the glaucoma filtration surgery are mostly retrospective. Also, the majority of these studies are based on findings of Goldmann perimetry. In our study, central visual field findings on automated perimetry were assessed

Table 3: Surgical Complications

	Group A (n=15)	Group B (n=15)
Intra-operative		
HypHEMA	1 (6.67%)	1 (6.67%)
Shallow anterior chamber	1 (6.67%)	1 (6.67%)
Descemet detachment	0	1 (6.67%)
Post-operative		
HypHEMA	1 (6.67%)	1 (6.67%)
Corneal edema	2 (13.33%)	2 (13.33%)
Anterior chamber reaction	2 (13.33%)	1 (6.67%)
Choroidal detachment	1 (6.67%)	1 (6.67%)
Persistently shallow anterior chamber	1 (6.67%)	1 (6.67%)
Cataract	1 (6.67%)	-

prospectively to study the incidence and identify the cause and risk factors for sudden vision loss after filtration surgery in advanced glaucoma.

Varying incidences of "wipe-out" have been reported with different risk factors for its development post filtration surgery. The findings of a few such studies have been summarised in Table 4.

An advanced glaucomatous field defect with macular involvement and split fixation is considered as a risk factor for the "wipe-out" or "snuff" phenomenon.^[1-5] Both Costa *et al.*^[3] and Kolkar *et al.*^[2] suggested macular split fixation as an important risk factor for wipe-out. All 30 patients in our study had an advanced field defect (Stage III and IV) with split fixation. Of these, 21 patients had a drop in vision by more than two lines on the Snellen chart on the first post-operative day, all of whom recovered by the 2 months. The reason for the vision loss could be ascertained in only 13 patients, and of these, two patients (one each in group A and group B) had

Table 4: Summary of the results of studies on the incidence and risk factors of unexplained visual loss after glaucoma-filtration surgery

Reference	Type of study	Sample	Definition of Split fixation	Incidence of unexplained visual loss	Identified risk factors
Costa <i>et al.</i> ^[9]	Retrospective	580	None	4	Old age, split fixation, history of coronary artery disease, post-operative hypotony
Topouzis <i>et al.</i> ^[10]	Prospective	21	None	None	-
Levene <i>et al.</i> ^[11]	Retrospective	96	Sensitivity loss of at least 10 dB from age-corrected normal at 1.4-degree eccentricity with Central 10-2 test of HFA	None	-
Francis <i>et al.</i> ^[12]	Retrospective	301	Sensitivity of <10 dB in any of the cardinal quadrants tested with HFA	6	Split fixation, no. of quadrants with split fixation, post-operative choroidal effusion
Balekudaru <i>et al.</i> ^[8]	Prospective	65	Sensitivity of 0 dB of all locations in at least one quadrant of the macular threshold program, HFA stimulus size III.	None	-

hypotony with choroidal detachment and two patients had a persistently shallow anterior chamber for more than 2 weeks post-operatively. The rest two patients had hyphema, three patients had anterior chamber reaction (more than grade ± 2), and four had corneal edema with one eye having intra-operative Descemet's membrane detachment. In the eight patients where the reason for drop in vision could not be ascertained, cycloplegia with inadequate correction of refractive error could be the likely cause. Also, cystoid macular edema as a possible cause could have been missed on fundoscopic examination. Delayed visual recovery after a period of 6 months post trabeculectomy has also been reported.^[11,12]

Choroidal detachment and post-operative hypotony were considered as important risk factors for "wipe-out".^[3,12] The incidence of choroidal detachment in filtration surgeries varies greatly from as low as 0.6–1.4%^[13] to as high as 16.5%.^[14] Choroidal detachment is managed with topical and oral steroids with cycloplegics. In our study, the patients with choroidal detachment were successfully managed conservatively with improvement of visual acuity by the end of 2 months. Hypotony maculopathy, another risk factor for the wipe-out phenomenon,^[3,12] is identified by the presence of optic disc edema, vascular tortuosity, or chorioretinal folds on fundoscopic examination, whereas sub-clinical hypotony maculopathy can be identified by OCT.^[15] It has been reported that hypotonic maculopathy occurs not only in eyes with conventional ocular hypotony (IOP <6 mm Hg) but also in eyes with IOP between 7 and 10 mm Hg.^[16] In our study, detailed funduscopy was performed in every visit and an OCT was performed in the final visit, that is, at 2 months, to detect any finding which may have been missed in funduscopy. Two of our patients had hypotony, IOP ≤ 6 mm of Hg, with a persistent shallow anterior chamber up to 2 weeks post surgery, which gradually increased by 2 months. However, these two patients did not show any evidence of choroidal folds either in funduscopy or in OCT. The mean central retinal thickness on OCT in the hypotony group was similar to the rest (245.6 μ in the hypotony group versus 246.8 μ in the rest). One of our patients presented with an IOP of 25 mm of Hg on the first

post-operative day. This may be attributed to hyphema in the anterior chamber. However, the hyphema resolved on conservative management alone within 7 days with lowering of the IOP.

Cataract is another cause for drop in vision after filtration surgery.^[17] Several studies have reported the incidence of cataract after filtration surgery to vary between 3.94% to 19%.^[3,12] The observer who performed the examination and classification was blinded to the pre-operative findings of lens examination. Only one patient in group A developed cataract after prolonged hypotony with choroidal detachment at the end of 2 months. A post-operative shallow anterior chamber, choroidal detachment, lens-corneal touch, and intense inflammation are some of the proposed risk factors for cataractous changes in the lens post filtration surgery.^[18,19] A sudden fall of IOP during filtration surgery leading to optic nerve hemorrhage might be another possible cause for wipe-out.^[6]

The risk of reversible visual loss after glaucoma-filtering surgery has been shown to vary from 34% to 56.5%,^[3,12,18] whereas the risk of severe or permanent visual loss after surgery varies from 0.95% to 13.6%.^[2,3] Studies have shown a varying incidence of wipe-out after trabeculectomy, but a few recent studies have also discarded the "wipe-out" phenomenon as a complication of the past with much less chances of occurrence with the present techniques.^[1] We did not have any occurrence of wipe-out in our study, but a possible limitation of our study could be a short follow-up of 2 months, which may be insufficient for stabilization of the ocular parameters assessed after surgery.

Conclusion

"Wipe-out" did not happen in our series of cases, and the reason for drop in visual acuity after surgery could be identified by careful evaluation. Also, most of the times, the loss in vision seems to be transient and recovers with appropriate management. Thus, filtration surgery in advanced glaucoma should not be withheld for fear of wipe-out in cases where medical management cannot sufficiently control the IOP.

Financial support and sponsorship

Nil.

Conflicts of interest

There are no conflicts of interest.

References

1. Moster MR, Moster ML. Wipe-out: A complication of glaucoma surgery or just a blast from the past? *Am J Ophthalmol* 2005;140:705-6.
2. Kolker AE. Visual prognosis in advanced glaucoma: A comparison of medical and surgical therapy for retention of vision in 101 eyes with advanced glaucoma. *Trans Am Ophthalmol Soc* 1977;75:539-55.
3. Costa VP, Smith M, Spaeth GL, Gandham S, Markovitz B. Loss of visual acuity after trabeculectomy. *Ophthalmology* 1993;100:599-612.
4. Song A, Scott IU, Flynn HW Jr, Budenz DL. Delayed-onset bleb-associated endophthalmitis: Clinical features and visual acuity outcomes. *Ophthalmology* 2002;109:985-91.
5. Karadimas P, Papastathopoulos KL, Bouzas EA. Decompression retinopathy following filtration surgery. *Ophthalmic Surg Lasers* 2002;33:175-6.
6. Sullivan KL, Brown GC, Forman AR, Sergott RC, Flanagan JC. Retrobulbar Anesthesia and retinal vascular obstruction. *Ophthalmology* 1983;90:373-7.
7. Mills RP, Budenz DL, Lee PP, Noecker RJ, Walt JG, Siegartel LR, *et al.* Categorizing the stage of glaucoma from pre-diagnosis to end-stage disease. *Am J Ophthalmol* 2006;141:24-30.
8. Balekudaru S, George R, Panday M, Singh M, Neog A, Lingam V. Prospective evaluation of early visual loss following glaucoma-filtering surgery in eyes with split fixation. *J Glaucoma* 2014;23:211-8.
9. Chylack LT Jr, Wolfe JK, Singer DM, Leske MC, Bullimore MA, Bailey IL, *et al.* The lens opacities classification system III. The longitudinal study of cataract study group. *Arch Ophthalmol* 1993;111:831-6.
10. Topouzis F, Tranos P, Koskosas A, Pappas T, Anastasopoulos E, Dimitrakos S, *et al.* Risk of sudden visual loss following filtration surgery in end-stage glaucoma. *Am J Ophthalmol* 2005;140:661-6.
11. Levene RZ. Central visual field, visual acuity, and sudden visual loss after glaucoma surgery. *Ophthalmic Surg* 1992;23:388-94.
12. Francis BA, Hong B, Winarko J, Kawji S, Dustin L, Chopra V. Vision loss and recovery after trabeculectomy: Risk and associated risk factors. *Arch Ophthalmol* 2011;129:1011-7.
13. Vaziri K, Schwartz SG, Kishor KS, Fortun JA, Moshfeghi DM, Moshfeghi AA, *et al.* Incidence of postoperative suprachoroidal hemorrhage after glaucoma filtration surgeries in the United States. *Clin Ophthalmol* 2015;9:579-84.
14. Iwasaki K, Kakimoto H, Arimura S, Takamura Y, Inatani M. Prospective cohort study of risk factors for choroidal detachment after trabeculectomy. *Int Ophthalmol* 2020;40:1077-83.
15. Weyll M, Gilio A, Barbosa A, Nicoli AA, Silveira RC. Detection of subclinical hypotony maculopathy with OCT III after filtration surgery. *Arq Bras Oftalmol* 2006;69:823-5.
16. Azuma K, Saito H, Takao M, Araie M. Frequency of hypotonic maculopathy observed by spectral domain optical coherence tomography in post glaucoma filtration surgery eyes. *Am J Ophthalmol Case Rep* 2020;19:100786.
17. Seah SK, Jap A, Prata JA Jr, Baerveldt G, Lee PP, Heuer DK, *et al.* Cataract surgery after trabeculectomy. *Ophthalmic Surg Lasers* 1996;27:587-94.
18. The AGIS Investigators. The Advanced Glaucoma Intervention Study, 8: Risk of Cataract Formation After Trabeculectomy *Arch Ophthalmol* 2001;119:1771-9.
19. Law SK, Nguyen AM, Coleman AL, Caprioli J. Severe loss of central vision in patients with advanced glaucoma undergoing trabeculectomy. *Arch Ophthalmol* 2007;125:1044-50.