

Is percutaneous pinning needed for the treatment of displaced distal radius metaphyseal fractures in children?

A systematic review

Zhi-Kui Zeng, MD^a, Wei-Dong Liang, MM^a, You-Qiang Sun, MD^b, Ping-Pin Jiang, BS^c, Ding Li, MD^d, Zhen Shen, MD^d, Ling-Mei Yuan, MD^a, Feng Huang, MM^{b,*}

Abstract

Background: Distal radius metaphyseal (DRM) fractures are very frequent childhood fractures. Whether additional percutaneous pinning improves the outcome remains controversial. In this review, we tried to systematically evaluate the effect of percutaneous pinning on re-displacement, secondary reduction, radiographs, function, and complications in children with displaced DRM fractures.

Methods: PubMed, Medline, Embase, Cochrane Library, and Web of Science databases were explored systematically to identify randomized controlled trials (RCTs) and clinical controlled trials (CCTs) comparing cast immobilization alone or following reduction to additional percutaneous pinning in the treatment of pediatric displaced DRM fractures. Two reviewers independently screened eligible articles and extracted relevant information from each article. The methodological quality of eligible articles was evaluated using the Cochrane Collaboration risk assessment tool (RCTs) and modified Jadad scale (CCTs).

Results: A total of 4 RCTs and 3 CCTs met the inclusion criteria, with a total patient count of 1 144 children. The results showed that additional percutaneous pinning significantly reduced the rate of re-placement (Chi-square tests, $P < .001$) and complications (Chi-square tests, $P = .030$). The superior results, both radiographically and functionally seemed to be temporary. No difference was found between the 2 groups after longer-term follow-up.

Conclusions: This systematic review suggested that compared with casting following reduction, percutaneous pinning had a positive effect on maintaining the initial reduction and reducing fracture complication rate of displaced DRM fractures in children, but with no significant improvement in function and radiographic outcome at the long-term follow-up. We suggest clinicians think twice before percutaneous pinning of displaced pediatric DRM fractures.

Abbreviations: CCT = clinical controlled trial, CT = casting therapy, DRM = distal radius metaphyseal, PP = percutaneous pinning, RCT = randomized controlled trial.

Keywords: displacement, distal metaphyseal radius, pediatric fracture, percutaneous pinning

1. Introduction

Distal radius fractures are common pediatric injuries, comprising 20% to 35% of all fractures in childhood.^{1,2} Traditionally,

Editor: Johannes Mayr.

The authors report no conflicts of interest.

^a Department of Orthopedics, The Affiliated Hospital of Jiangxi University of Chinese Medicine (Jiangxi Provincial Hospital of Chinese Medicine), Nanchang,

^b Department of Orthopaedics, The First Affiliated Hospital of Guangzhou University of Chinese Medicine, Guangzhou, ^c Department of Orthopedics, Xinyu Chinese Medicin Hospital Affiliated to Jiangxi University of Chinese Medicine, Xinyu, ^d First School of Clinical Medicine, Guangzhou University of Chinese Medicine, Guangzhou City, China.

* Correspondence: Feng Huang, Guangzhou University of Traditional Chinese Medicine First Affiliated Hospital, Guangzhou, Guangdong, China (e-mail: huangfeng5703@163.com).

Copyright © 2018 the Author(s). Published by Wolters Kluwer Health, Inc. This is an open access article distributed under the terms of the Creative Commons Attribution-Non Commercial License 4.0 (CCBY-NC), where it is permissible to download, share, remix, transform, and buildup the work provided it is properly cited. The work cannot be used commercially without permission from the journal.

Medicine (2018) 97:36(e12142)

Received: 2 December 2017 / Accepted: 7 August 2018

<http://dx.doi.org/10.1097/MD.0000000000012142>

given the great inherent ability of pediatric radius metaphyseal fractures to heal and remodel,^{3,4} these fractures have been treated non-operatively. The most frequent method used was closed reduction and cast or splint immobilization. Unfortunately, with this approach, re-displacement has been reported to occur in 25% to 39% of patients.^{5,6} In an attempt to optimize patient outcome by combining the benefits of operative treatment with a reduced rate of re-displacement, a method of percutaneous reduction and wire fixation has been developed by many authors, particularly for unstable fractures.⁷

The risk factors leading to high risk of displacement remains a pivotal question. Complete initial displacement,^{8,9} initial reduction quality,^{9,12} associated ulnar fracture,¹⁰ lateral translation go beyond half of the bone diameter,¹¹ experience of surgeon,^{6,9,12} volar angulation,¹² and plaster technique^{5,12} have been reported as the most common risk factors in literature.

Recent studies have shown superior results with percutaneous wire fixation, in certain subgroups of patients with angulated or displaced distal radius fractures.¹³ However, Adrian et al¹⁴ suggested that no major reports have proven the superiority of manipulation and pinning over cast immobilization alone in treating angulated fractures of the distal forearm in children, but pinning increased the complications and cost. Therefore, the optimal treatment of displaced pediatric distal radius fractures

remains controversial. Given this uncertainty, relevant evidence is required to evaluate the effectiveness of percutaneous pinning as an alternative management technique to traditional casting, especially for unstable fractures. In this systematic review, we aimed to compare the results and complication rates between these 2 methods.

2. Methods

We performed the present systematic review in accordance with the preferred reporting items for systematic reviews and meta-analyses (PRISMA) guidelines. Ethical approval is not required because this study is conducted based on the existing literature. Our study protocol had been registered on PROSPERO (registration number: 42017082545).

2.1. Selection criteria

An article was considered eligible if it met the following criteria: the study was an randomized controlled trial (RCT) or clinical controlled trial (CCT); population: the patients (<17 years old) had closed displaced distal radius metaphyseal (DRM) fractures (complete fracture of DRM or DRM+ulna fracture, or translation >50% bone diameter, or angulation >15° in patients <10 years, or angulation >10° in patients >10 years); interventions: the intervention method was fixation with additional percutaneous pinning; comparison: casting alone or with manipulation; outcomes: at least 1 key data involved: re-displacement, secondary reduction, radiographic results, function, complication; and there was at least a 6-week clinical follow-up.

2.2. Search strategy

A literature search was carried out to select articles in which casting and additional percutaneous pinning approaches were compared in the treatment of pediatric displaced fractures of DRM. PubMed, Medline, Embase, Cochrane Library, and Web of Science databases were explored for relevant articles published from January 1950 through June 2018. Publications were restricted to the English language. Search keywords were “wrist,” “distal radius,” “distal forearm,” “distal radial,” and “fracture,” “children,” or “pediatric.” Only RCTs and CCTs that compared casting with additional percutaneous pinning methods for displaced pediatric DRM fractures were considered. In addition, all eligible studies were reviewed to find additional articles.

2.3. Data extraction and quality assessment

The effective data were extracted by 2 independent reviewers (ZKZ and YQS) from all identified articles, including data available for systematic review and information on general characteristics of trials and patients. In case of a disagreement, it was resolved by discussion.

To guarantee a systematic, standardized, and logical assessment method, RCTs were evaluated using the risk assessment tool described by the Cochrane Collaboration,^[15] while the modified Jadad scale was adopted for CCTs studies.^[16] The modified Jadad scale has 8 subscales, which evaluate randomization, blinding, withdrawals and dropouts, inclusion and exclusion criteria, adverse effects, and statistical analysis. A score of 4 to 8 denotes good to excellent quality, while a score of 0 to 3 denotes poor to low quality.

2.4. Statistical analysis

The data rates were analyzed with Chi-square test and Fishers' exact test. A *P* value less than .05 was accepted as statistical significant. SPSS statistics software (version 22, IBM Corporation, New York) was employed for statistical analyses.

3. Results

3.1. Literature search results and study characteristics

A total of 1185 relevant articles were identified. After screening the titles and abstracts, 1165 records were excluded; the remaining 20 articles were evaluated with a full-text review. We excluded 6 duplicate publications, as well as 7 studies that did not report on casting versus percutaneous pinning clinical trials. Finally, 4 published RCTs^[14,17–19] and 3 CCTs^[13,20,21] with a total of 1144 patients met the inclusion criteria (Fig. 1). Almost of all the included articles compared casting following reduction to additional percutaneous pinning except 1 study,^[14] in which no reduction was performed in the casting group. The characteristics of eligible articles and participants are summarized in Table 1. The identified 7 trials reported on 1144 children (average 160.6 per study; range 34–742) with displaced metaphyseal fractures of the distal radius or distal forearm. The weighted average age of eligible patients reported in 6 studies was 9.8 (casting) versus 9.7 (pinning) (range 0–17) with a mean follow-up of 38.52 weeks (range 6–102.8).

3.2. Methodological quality assessment

An assessment of the quality of RCTs was seen in Table 2, all the RCTs had a low to medium risk of bias. The total scores of CCTs, based on the modified Jadad scale, are shown in Table 3. Based on the scores, the 3 CCTs were all identified as poor to low quality designs (score of 0–3 on the modified Jadad scale).

3.3. Pediatric displaced fractures of DRM outcomes analysis

Data on the outcomes of the identified studies are presented in Table 4.

3.3.1. Re-displacement. Six of the papers investigated the re-displacement rate.^[13,17–21] In the report of McLauchlan et al,^[17] there was a significant difference between the 2 groups in the rate of loss of reduction, none of the 35 cases had re-displacement in the pinning group compared with 7 of 33 in the casting group (*P* = .013). In the study of Miller et al,^[18] re-displacement occurred in 39% of patients treated with plaster, compared to no cases of re-displacement in the K-wire group (*P* = .011). In the series treated by Van Leemput et al,^[13] 11 of 24 (45.8%) patients in the casting group experienced subsequent loss of position; in contrast no re-displacement was seen in the patients treated with pinning at 6-week follow-up (*P* = .021). Ozcan et al^[20] found that the incidence of re-displacement was 10% in the K-wire group and 50% in the casting group (*P* = .006). In the report of Egmond et al,^[21] none of the 45 cases treated by pinning showed loss of reduction compared with 19 of 48 cases treated by casting (*P* = .023). In the series of Colaris et al,^[19] after an average of 7.1-month follow-up, patients treated with additional K-wire exhibited significantly less re-displacement than the casting group (8% vs 45%) (*P* < .001).

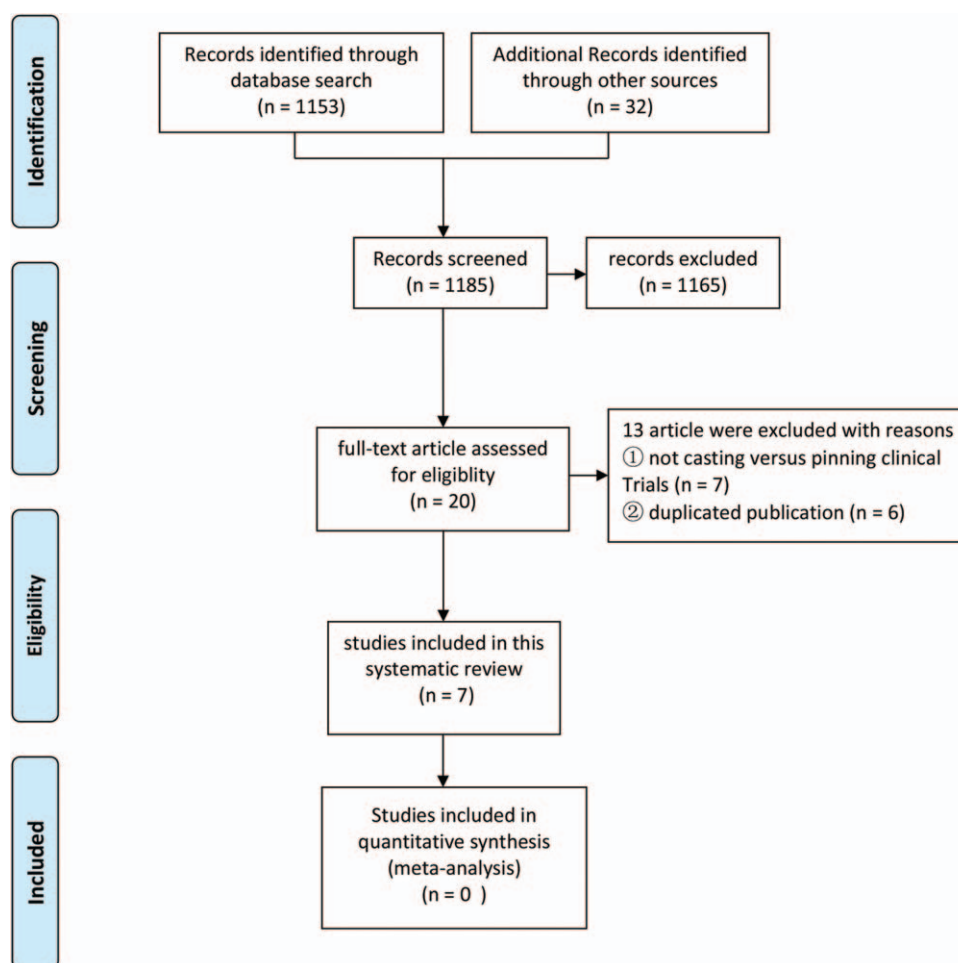


Figure 1. Flowchart of eligibility selection.

3.3.2. Secondary reduction. Re-manipulation was shown in 5 studies.^[13,17–21] In the report of McLauchlan et al,^[17] 7 of 33 patients treated with casting had subsequent re-displacement, and all of them had further intervention including re-manipulation (n=2), wedging of the cast (n=1), or re-manipulation with additional pinning (n=4). In the series treated by Miller et al,^[18] 7 of 18 cases in the casting group showed subsequent loss of reduction; 1 patient's fracture healed by malunion, while 6 patients required a second procedure, including reduction/casting (n=4), pin fixation (n=1), and cast wedging (n=1). In the study of Van Leemput et al,^[13] loss of position occurred in 3 patients after the second week of surgery, and they underwent further closed reduction and K-wire fixation. In the report of Egmond et al,^[21] 19 fractures treated by casting required a secondary manipulation, which was not described in detail. In the series of Colaris et al,^[19] re-displacement was noted in 30 patients treated with casting of which 17 underwent secondary reduction. In the pinning group, re-displacement was noted in 5 patients, and only 1 patient underwent secondary reduction. However, the details of the second procedure were not mentioned.

3.3.3. Radiographic results. Four articles reported the radiographic findings at the final examination.^[17,18,20,21] In the study of McLauchlan et al,^[17] after application of a cast, the quality of reduction on the immediate post-reduction radiograph in the

K-wire group was better than in the casting group. Furthermore, by the time of union, the difference became more obvious: the mean dorsal angulation was $9.1 \pm 11.5^\circ$ in the casting group compared with $2.7 \pm 7.3^\circ$ in the pinning group ($P=.01$), suggesting that pinning prevented further loss of reduction during and after the application of the cast. In the report of Miller et al,^[18] no significant difference was found in final radiographs between the 2 groups, and all fractures healed with acceptable alignment (defined as angulation $<25^\circ$ and the presence of cortical contact). Similarly, in the study of Ozcan et al,^[20] no significant difference was detected between the 2 groups during the final evaluation in terms of radiological parameters at 20-month follow-up. In the series of Egmond et al,^[21] at the time of union, the residual angles of both bone in the anteroposterior and the lateral directions were greater in the casting group than in the pinning group.

3.3.4. Function. Five trials provided functional outcomes during the last follow-up.^[14,17–20] In the study of McLauchlan et al,^[17] no significant difference was detected between the 2 groups in terms of function at 3-month follow-up. In the report of Ozcan et al,^[20] there was also no significant difference in range of motion when compared with the normal side during the follow-up at 20 months; however, the average degree of pronation was 5° smaller in the casting therapy group ($P=.018$). In the series of

Table 1**Characteristics of recruited trails.**

Study (year)	Study type	Cases (CT/PP)	Mean age (years)	Follow-up time (weeks)	Inclusion criteria	Outcome
McLauchlan et al, 2002 ^[17]	RCT	33/35	7.9±2.7	12.5	Completely fracture of DRM±ulna fracture	Re-displacement; secondary reduction; radiographs; function; complication
Miller et al, 2005 ^[18]	RCT	18/16	12.4	10.5	Completely fracture of DRM; DRM fracture with angulation>30°	Re-displacement; secondary reduction; radiographs; function; complication
Van Leemput et al, 2009 ^[13]	CCT	24/15	9.3 (CT) 9.7 (PP)	6	DRM fracture with mean angulation=27° (CT); mean angulation=37° (PP) (completely fracture, 4 vs 6 cases in CT vs PP, respectively)	Re-displacement; secondary reduction
Ozcan et al, 2010 ^[20]	CCT	20/20	11.2 (CT) 10.1 (PP)	85.5	Completely fracture of DRM or DRM+ulna fracture, or translation>50% bone diameter, or angulation>30° (<10 years), or angulation>20° (>10 years)	Re-displacement; radiographs; function; complication
Egmond et al, 2012 ^[21]	CCT	48/45	9.3±3.4 (CT) 9.1±2.9 (PP)	22	Displaced metaphyseal fractures of the distal forearm (AO 23M/2.1, 23M/3.1)	Re-displacement; secondary reduction; radiographs
Colaris et al, 2013 ^[19]	RCT	67/61	8.7±3.2 (CT) 9.0±3.0 (PP)	30.4	Displaced metaphyseal fractures of the distal forearm, or translation>50% bone diameter, or angulation>15° (<10 years), or angulation>10° (>10 years), or any rotation of radius and/or ulna	Re-displacement; secondary reduction; function; complication
Adrian et al, 2015 ^[14]	RCT	371/371	5–11	102.8	AO 23-M/2-3, 23-E/1-2; angulated radius, or completely fracture of distal forearm, or angulated physiolysis±wedge of the metaphysis; angulation 15°–30° (5–7 years), angulation 10°–25° (8–11 years)	Function

CT=casting therapy, DRM=distal radius metaphys, PP=percutaneous pinning, RCT=randomized controlled trial.

Miller et al,^[18] all differences between the pinning and casting groups seemed to be temporary. After 10.5 weeks, no difference was found in the results of treatment between the 2 groups. Using Cooney scores, Adrian et al^[14] found no superiority of reduction and pinning over cast immobilization alone at 2-year follow-up. In the report of Colaris et al,^[19] pronation and supination were less limited in the group initially treated by percutaneous pinning compared with the cast group ($6.9\pm 9.4^\circ$ vs $14.3\pm 13.6^\circ$) at the 7.1-month follow-up ($P=.001$).

3.3.5. Complication. Four trials evaluated complications at the final follow-up.^[17–20] In the study of McLauchlan et al,^[17] complications in the manipulation group included re-displacement ($n=7$); in the K-wire group, complications included pain ($n=1$), prominent scar ($n=2$), and pin migration ($n=1$). In the series treated by Miller et al,^[18] no statistically significant difference in complication rates was observed between groups. The overall complication rates in the casting group was 44%

versus 38% in the pinning group ($P=.738$). In the casting group, the most frequent complication was loss of position and the need for a second reduction subsequently ($n=7$). The authors also reported 1 incident of transient ulnar nerve hypesthesia ($n=1$). In the pinning group, complications included pin migration under the skin ($n=2$), pin-site infection ($n=2$), transient neuropraxia of the radial nerve ($n=1$), and tendon irritation ($n=1$). In the report of Ozcan et al,^[20] loss of reduction was seen in 2 patients, while 4 patients had pin migration in the K-wire group. The complications in the casting group included re-displacement ($n=10$), pressure sore ($n=1$), and median and ulnar nerve dysfunction ($n=1$). In the study of Colaris et al,^[19] 30 fractures showed re-displacement in the above-elbow cast group, and 1 patient developed transient neuropraxia. By comparison, in the group with additional K-wires, 5 fractures showed re-displacement, other complications seen were subcutaneous K-wires ($n=7$), re-fractures ($n=3$), superficial infections ($n=2$), transient neuropraxia ($n=1$), and failed insertion of K-wires ($n=1$).

Table 2**Quality of the RCTs selected in this study using the Cochrane Collaboration risk assessment tool.**

Study	Random sequence generation	Allocation concealment	Blinding of participants and personnel	Blinding of outcome assessment	Incomplete outcome data	Selective reporting	Other bias
McLauchlan et al, 2002 ^[17]	Low risk	Low risk	High risk	Unclear risk	Low risk	Low risk	Low risk
Miller et al, 2005 ^[18]	Low risk	Low risk	High risk	Unclear risk	Low risk	Low risk	Low risk
Colaris et al, 2013 ^[19]	Low risk	Low risk	High risk	Unclear risk	Low risk	Low risk	Low risk
Adrian et al, 2015 ^[14]	Low risk	Low risk	High risk	Low risk	Unclear risk	Low risk	Unclear risk

RCTs=randomized controlled trials.

Table 3**Quality of the CCTs selected in this study using the modified Jadad scale.**

Item assessed	Response	Score	Van Leemput et al, 2009 ^[13]	Ozcan et al, 2010 ^[19]	Egmond et al, 2012 ^[20]
Was the study described as randomized?	Yes	+1			
	No	0	0	0	0
Was the method of randomization appropriate?	Yes	+1			
	No	-1			
	Not described	0	0	0	0
Was the study described as blinded*?	Yes	+1			
	No	0	0	0	0
Was the method of blinding appropriate?	Yes	+1			
	No	-1			
	Not described	0	0	0	0
Was there a description of withdrawals and dropouts?	Yes	+1			1
	No	0	0	0	
Was there a clear description of the inclusion/exclusion criteria?	Yes	+1	1	1	1
	No	0			
Was the method used to assess adverse effects described?	Yes	+1		1	
	No	0	0		0
Was the method of statistical analysis described?	Yes	+1		1	1
	No	0	0		
Total score (maximum 8)			1	3	3

CCTs=clinical controlled trials.

* Double-blind trials, score 1; single-blind trials, score 0.5.

4. Discussion

The present review analyzed the results of 7 trials involving 1144 children with displaced DRM fractures. To the best of our knowledge, this study is the first systematic review aimed at comparing percutaneous pinning with casting therapy for the treatment of displaced DRM fractures in children. Our analysis indicated that additional percutaneous pinning reduced fracture

complication rate but was not superior to casting in terms of function and radiographic outcome after follow-up for more than 10 weeks. Therefore, this study may help identify the differences between the 2 treatments, suggest therapeutic courses of action, and highlight areas for further research.

Overall, the quality of the evidence is limited. An adequately randomized sequence was generated by sealed envelopes in 3

Table 4**Data on the outcomes of the identified trails.**

Study (year)	Re-displacement (CT/PP)	Secondary reduction (CT/PP)	Radiographs	Function	Complication (CT/PP)
McLauchlan et al, 2002 ^[17]	7/33,0/35	7/33,0/35	Dorsal angulation CT > PP	NSD	Re-displacement (n=7)/pain (n=1), prominent scar (n=2) and pin migration (n=1)
Miller et al, 2005 ^[18]	7/18,0/16	6/18,0/16	NSD	NSD	Re-displacement (n=7), transient ulnar nerve hypesthesia (n=1)/ pin migration under the skin (n=2), pin-site infection (n=2), transient neuropraxia of the radial nerve (n=1) and tendon irritation (n=1)
Van Leemput et al, 2009 ^[13]	11/24,0/15	3/24,0/15	NA	NA	NA
Ozcan et al, 2010 ^[20]	10/20,2/20	NA	NSD	NSD	Re-displacement (n=10), pressure sore (n=1) and median and ulnar nerve dysfunction (n=1)/ re-displacement (n=2), pin migration (n=4)
Egmond et al, 2012 ^[21]	19/48,0/45	19/48,0/45	residual angles CT > PP	NA	NA
Colaris et al, 2013 ^[19]	30/67,5/61	17/67,1/61	NA	Limitation of forearm rotation CT > PP	Re-displacement (n=30), transient neuropraxia (n=1)/re-displacement (n=5), subcutaneous K-wires (n=7), re-fractures (n=3), superficial infections (n=2), transient neuropraxia (n=1) and failed insertion of K-wires (n=1)
Adrian et al, 2015 ^[14]	NA	NA	NA	NSD	NA

CT = casting therapy, NA = not available, NSD = no significant difference, PP = percutaneous pinning.

RCT studies,^[16–18] except the study of Adrian et al^[14] which adopted the method of online-based randomization. The methods of randomization and allocation concealment were not employed in all CCTs papers.^[13,19,20] Unavoidably, a significant problem was that nearly all studies failed to employ any blinding methods, except 1 study^[14] used observer blinding, which might cause a certain detection bias in the outcomes. In addition, the difference of duration in the follow-up might also cause a potential source of bias to the final result.

4.1. Re-displacement

Re-displacement is the most common complication after closed reduction and cast immobilization in the treatment of displaced DRM fractures.^[22,23] Therefore, a number of surgeons recommend pinning to augment the reduction to prevent re-displacement.^[24,25] In all 6 papers, our review found significantly higher re-displacement rates in the casting therapy group.^[13,17–21] Overall, the mean re-displacement rate found in this systematic review was 40.0% in the casting group compared with 3.6% in the pinning group (Chi-square tests, $P < .001$). Among those patients, some required a secondary procedure. Consistent with a previously published study,^[26] our results also indicate that K-wire pinning has a positive effect in reducing fracture re-displacement. This may be because the majority of the participants included in our review had unstable fractures. However, the lack of a standard definition of re-displacement might affect the reliability of our results.

4.2. Secondary reduction

If loss of reduction occurs, secondary intervention might be required. Five of the 7 included studies reported that further intervention was adopted,^[13,17–20] including re-manipulation, pin fixation, and cast wedging. In the report of Ozcan et al,^[20] none of the fractures with re-displacement in the casting group ($n = 10$) underwent further interventions. Nevertheless, it did not affect the final radiographic and functional results after a follow-up of 20 months.

Whether to re-manipulate or to accept re-displacement remains controversial. Do et al^[27] suggested that skeletally immature patients with open physes, isolated injuries, radioulnar, and dorsovolar angulations $< 15^\circ$ and < 1 cm of shortening will heal, with cast removal in an average of 6 weeks, and with re-modeling completed after a mean of 7.5 months. Similarly, Roth et al^[28] retrospectively evaluated 66 children with distal forearm fractures for a mean of 4.0-year follow-up and found that a second reduction of re-angulated fractures in children less than 12 years old did not show superior results; second reductions were deemed unnecessary. In the re-modeling group, satisfactory clinical results were achieved in children more than 12 years old despite re-angulations surpassing current guidelines. They concluded that clinicians should think twice before performing secondary reduction.

4.3. Radiographic results

With regard to the results of radiographs, no significant difference was found between the 2 groups in 2 studies.^[18,20] Nevertheless, in the study of McLauchlan et al,^[17] superior results were found in patients treated with additional K-wire fixation. Interestingly, at the 3-month follow-up, the different radiographic findings did not affect function, which may be due

to the greater ability of growing long bones to remodel and compensate. Similarly, in the series of Egmond,^[21] the plaster group had a greater residual angle, while functional comparison results were not reported. One possible explanation of the greater residual angle is that the time to perform angulation assessment in the next 2 articles was not long enough (the time of union). Colaris et al^[29] prospectively investigated 410 children (< 16 years) who suffered a forearm fracture. After 3 months of follow-up, it was concluded that children with a metaphyseal forearm fracture of the distal forearm with an angular malalignment of $\leq 15^\circ$ only had a 9% to 13% chance of developing a clinically relevant limitation. Additionally, Howe et al^[30] reported 88 distal radius fractures (7–15 years old) that healed with angular deformity, including 8 cases with an angulation $> 15^\circ$, and found complete re-modeling with no limitation of function at the 7-year follow-up.

4.4. Function

Function is the most important assessment standard of these clinical results, because it may change the quality of life of children. Three papers^[14,17,18] found no significant difference between percutaneous pinning and casting with respect to the range of motion. Furthermore, in the study of Adrian et al,^[14] no initial manipulation was performed in the casting group. However, Ozcan et al^[20] reported that the loss of pronation was significantly higher in the casting therapy group ($P = .018$). Fortunately, the difference disappeared between the 2 groups during the final follow-up, which could be explained by a re-modeling period of 20 months. Significantly, at the last follow-up, Colaris et al^[19] reported less limitation in pronation and supination in the group initially treated by percutaneous pinning ($P = .001$). The authors concluded that it could be explained by the inclusion of only children with forearm fractures, the relatively short time of follow-up (7.1 months) and the prospective nature of their study. Because forearm fractures were more likely to cause narrowing of the interosseous space.^[31] Therefore, based on the current evidences, alternative casting following reduction does not appear to significantly worsen functional outcomes, and any theoretical loss of rotation appears small and of short duration when compared with percutaneous pinning.

4.5. Complications

In the casting group, the commonly reported complications were re-displacement, nerve hypesthesia, and pressure sores.^[32] In contrast, in the pinning group, the main complications included loss of reduction, prominent scar, infection, pin migration, tendon irritation, re-fractures, transient neuropraxia, and failed insertion.^[33,34] Of the 4 studies that reported complications,^[17–20] only 1 included re-displacement.^[18] In our review, we included the re-displacement into the complications in all the trials. Overall, the average complication rates found in this systematic review were 40.5% for the casting group versus 28.0% for the pinning group (Chi-square tests, $P = .030$). Compared with casting, pinning decreases the rate of complications.

Three of the selected studies involved a cost-related analysis.^[17,18,20] In the report of McLauchlan et al,^[17] fewer radiographs were required in the K-wire group at 3 months of follow-up. However, specific data and details were not available in this paper. In the study of Ozcan et al,^[20] the average number of radiographs was 13 for the casting group and 9 for the K-wire

group after follow-up of 20 months; the difference was not statistically significant. Based on cost analysis, in series of Miller et al,^[18] no significant difference was observed in terms of cost between groups at the 10.5-week follow-up. The average cost was \$3831.00 for the casting group and \$3347.20 for the pinning group. However, there was a trend toward higher costs for K-wire fixation compared to casting in patients with no complications.

5. Limitations

Inevitably, there are some limitations of this systematic review. Although a comprehensive Medline search was performed, the number of RCTs was very limited; because of this, CCTs related to the topic were also searched. Even with CCTs included, only 7 articles met our inclusion criteria, with few papers achieving a sufficient reliability in terms of the number of cases and follow-up. In the eligible trials, only 4 RCTs were included; the other 3 were CCTs.

Another limitation was a lack of consistency in inclusion criteria and definition of re-displacement between studies, although similar fracture characteristics were included across different studies. The general characteristics of most eligible cases were complete fractures, angulation, and translation, with or without ulnar fracture. The lack of standardization and the variability in inclusion criteria and outcome measures resulted in an inability to pool data for meta-analysis. Fortunately, the casting group applied the above-elbow cast consistently in all of the included studies. The recruitment of CCTs might lower the level of evidence, as they may lead to a certain degree of selection bias in the outcomes.

6. Conclusions

The present systematic review showed that compared with casting following reduction, additional percutaneous pinning reduced the rate of re-displacement and complications in displaced pediatric DRM fractures. However, the superior results of function and radiographs seem to be short-lived, as all differences disappeared after complete re-modeling. Furthermore, no cost advantages have been found in the additional percutaneous pinning group compared with the casting group. In our opinion, clinicians should use careful consideration before performing percutaneous pinning in these fractures.

Acknowledgments

We thank Chuan-Wei Mo for help with the statistical analysis.

Author contributions

Conceptualization: Feng Huang.

Methodology: Ding Li, Ling Mei Yuan.

Project administration: Zhi Kui Zeng.

Supervision: Wei Dong Liang, Ping Pin Jiang.

Writing – original draft: Zhi Kui Zeng.

Writing – review & editing: You Qiang Sun, Zhen Shen.

References

- [1] Cooper C, Dennison EM, Leufkens HG, et al. Epidemiology of childhood fractures in Britain: a study using the general practice research database. *J Bone Miner Res* 2004;19:1976–81.
- [2] Bae DS, Howard AW. Distal radius fractures: what is the evidence? *J Pediatr Orthop* 2012;32(suppl 2):S128–30.
- [3] Jerose K, America T, Witbreuk M, et al. Malunion of distal radius fractures in children remodeling speed in 33 children with angular malunions of ≥ 15 degrees. *Acta Orthop* 2015;86:233–7.
- [4] Plánka L, Chalupová P, Skvaril J, et al. Remodelling ability of the distal radius in fracture healing in childhood. *Rozhl Chir* 2006;85:508–10.
- [5] Devalia KL, Asaad SS, Kakkar R. Risk of redisplacement after first successful reduction in paediatric distal radius fractures: sensitivity assessment of casting indices. *J Pediatr Orthop B* 2011;20:376–81.
- [6] Fenton P, Nightingale P, Hodson J, et al. Factors in redisplacement of paediatric distal radius fractures. *J Pediatr Orthop B* 2012;21:127–30.
- [7] Huang W, Zhang X, Zhu H, et al. A percutaneous reduction technique for irreducible and difficult variant of paediatric distal radius and ulna fractures. *Injury* 2016;47:1229–35.
- [8] McQuinn AG, Jaarsma RL. Risk factors for redisplacement of pediatric distal forearm and distal radius fractures. *J Pediatr Orthop* 2012;32:687–92.
- [9] Asadollahi S, Ooi KS, Hau RC. Distal radial fractures in children: risk factors for redisplacement following closed reduction. *J Pediatr Orthop* 2015;35:224–8.
- [10] Hang JR, Hutchinson AF, Hau RC. Risk factors associated with loss of position after closed reduction of distal radial fractures in children. *J Pediatr Orthop* 2011;31:501–6.
- [11] Mani GV, Hui PW, Cheng JC. Translation of the radius as a predictor of outcome in distal radial fractures of children. *J Bone Joint Surg Br* 1993;75:808–11.
- [12] Asadollahi S, Pourali M, Heidari K. Predictive factors for re-displacement in diaphyseal forearm fractures in children—role of radiographic indices. *Acta Orthop* 2017;88:101–8.
- [13] Van Leemput W, De Ridder K. Distal metaphyseal radius fractures in children: reduction with or without pinning. *Acta Orthop Belg* 2009;75:306–9.
- [14] Adrian M, Wachtlin D, Kronfeld K, et al. A comparison of intervention and conservative treatment for angulated fractures of the distal forearm in children (AFIC): study protocol for a randomized controlled trial. *Trials* 2015;16:437.
- [15] Higgins J. *Cochrane handbook for systematic reviews of interventions* Version 5.1.0. Cochrane Collaboration 2011.
- [16] Oremus M, Wolfson C, Perrault A, et al. Interrater reliability of the modified Jadad quality scale for systematic reviews of Alzheimer's disease drug trials. *Dement Geriatr Cogn Disord* 2001;12:232–6.
- [17] McLauchlan GJ, Cowan B, Annan IH, et al. Management of completely displaced metaphyseal fractures of the distal radius in children. A prospective, randomised controlled trial. *J Bone Joint Surg Br* 2002;84:413–7.
- [18] Miller BS, Taylor B, Widmann RF, et al. Cast immobilization versus percutaneous pin fixation of displaced distal radius fractures in children: a prospective, randomized study. *J Pediatr Orthop* 2005;25:490–4.
- [19] Colaris JW, Allema JH, Biter LU, et al. Re-displacement of stable distal both-bone forearm fractures in children: a randomised controlled multicentre trial. *Injury* 2013;44:498–503.
- [20] Ozcan M, Memisoglu S, Copuroglu C, et al. Percutaneous Kirschner wire fixation in distal radius metaphyseal fractures in children: does it change the overall outcome? *Hippokratia* 2010;14:265–70.
- [21] van Egmond PW, Schipper IB, van Luijt PA. Displaced distal forearm fractures in children with an indication for reduction under general anesthesia should be percutaneously fixated. *Eur J Orthop Surg Traumatol* 2012;22:201–7.
- [22] Bae DS. Pediatric distal radius and forearm fractures. *J Hand Surg Am* 2008;33:1911–23.
- [23] Proctor MT, Moore DJ, Paterson JM. Redisplacement after manipulation of distal radial fractures in children. *J Bone Joint Surg Br* 1993;75:453–4.
- [24] Zamzam MM, Khoshhal KI. Displaced fracture of the distal radius in children: factors responsible for redisplacement after closed reduction. *J Bone Joint Surg Br* 2005;87:841–3.
- [25] Luscombe KL, Chaudhry S, Dwyer JS, et al. Selective Kirschner wiring for displaced distal radial fractures in children. *Acta Orthop Traumatol Turc* 2010;44:117–23.
- [26] Muratli HH, Yağmurlu MF, Yüksel HY, et al. Treatment of childhood unstable radius distal metaphysis fractures with closed reduction and percutaneous Kirschner wires. *Acta Orthop Traumatol Turc* 2002;36:52–7.
- [27] Do TT, Strub WM, Foad SL, et al. Reduction versus remodeling in pediatric distal forearm fractures: a preliminary cost analysis. *J Pediatr Orthop B* 2003;12:109–15.

- [28] Roth KC, Denk K, Colaris JW, et al. Think twice before re-manipulating distal metaphyseal forearm fractures in children. *Arch Orthop Trauma Surg* 2014;134:1699–707.
- [29] Colaris J, Reijman M, Allema JH, et al. Angular malalignment as cause of limitation of forearm rotation: an analysis of prospectively collected data of both-bone forearm fractures in children. *Injury* 2014;45:955–9.
- [30] Hove LM, Brudvik C. Displaced paediatric fractures of the distal radius. *Arch Orthop Trauma Surg* 2008;128:55–60.
- [31] Yasutomi T, Nakatsuchi Y, Koike H, et al. Mechanism of limitation of pronation/supination of the forearm in geometric models of deformities of the forearm bones. *Clin Biomech* 2002;17:456–63.
- [32] Paneru SR, Rijal R, Shrestha BP, et al. Randomized controlled trial comparing above- and below-elbow plaster casts for distal forearm fractures in children. *J Child Orthop* 2010;4:233–7.
- [33] Ramoutar DN, Shivji FS, Rodrigues JN, et al. The outcomes of displaced paediatric distal radius fractures treated with percutaneous Kirschner wire fixation: a review of 248 cases. *Eur J Orthop Surg Traumatol* 2015;25:471–6.
- [34] Jordan R, Westacott D. Displaced paediatric distal radius fractures—when should we use percutaneous wires? *Injury* 2012;43:908–11.