

Spectrum of Magnetic Resonance Imaging Findings in Acute Pediatric Traumatic Brain Injury - A Pictorial Essay

Cristina-Mihaela Popescu ¹, Virginia Marina ², Georgiana Avram³, Carmen Laura Cristescu Budala³

¹Dental-Medicine Department, Faculty of Medicine and Pharmacy, “dunărea de Jos” University, Galați, 800201, Romania; ²Medical Department of Occupational Health, Faculty of Medicine and Pharmacy, “Dunărea de Jos” University, Galați, 800201, Romania; ³“sf. Ioan” Clinical Emergency Children’s Hospital, Galați, 800487, Romania

Correspondence: Virginia Marina, Tel +40-770-89-82-74, Email virginia.marina@ugal.ro

Abstract: Head trauma (HT) in pediatric patients is the number one cause of mortality and morbidity in children. Although computer tomography (CT) imaging provides ample information in assessing acute traumatic brain injuries (TBIs), there are instances when magnetic resonance imaging (MRI) is needed. Due to its high sensitivity in diagnosing small bleeds, MRI offers a well-documented evaluation of primary acute TBIs. Our pictorial essay aims to present some of the latest imaging protocols employed in head trauma and review some practical considerations. Injury mechanisms in accidental HT, lesions’ topography, and hematoma signal variability over time are also discussed. Acute primary intra- and extra-axial lesions and their MRI aspect are showcased using images from patients in our hospital. This pictorial essay has an educational purpose. It is intended to guide young emergency and intensive care unit doctors, neurologists, and neurosurgeons in diagnosing acute primary TBIs on MRI while waiting for the official radiologist’s report. The presentation focuses on the most frequent traumatic lesions encountered in acute pediatric head trauma.

Keywords: paediatric head trauma, traumatic brain injury, diffuse axonal injury, haemorrhagic cortical contusions, epidural haematoma

Introduction

Children are susceptible to sustaining diverse types of traumas. If major traumas (as defined by Thompson et al¹) are rare in children - accounting for only 6% of all major traumas in both children and adults,² pediatric HT is the leading cause of Emergency Department visits worldwide.³ Whether accidental or not, its effects can be devastating,⁴ making it the leading cause of mortality and morbidity in children.^{5,6} The best imaging tools must be used to evaluate the HT and take suitable measures for each patient. Algorithms such as the Paediatric Emergency Care Applied Research Network (PECARN), Children’s Head Injury Algorithm for the Prediction of Important Clinical Events (CHALICE), and Canadian Assessment of Tomography for Childhood Head Injury (CATCH) are of critical importance to both clinicians and patients. They guide the former to rule out or ask for CT imaging. CT is still the gold standard for the initial evaluation of HT.⁷⁻⁹

In cases where neurological deficits persist or new ones develop, and the initial head CT is normal, MRI is the next step in current practice,^{10,11} particularly after moderate to severe HT. MRI is also useful to assess further the lesions previously described on the initial CT.¹² According to Yue et al, biomarkers, such as plasma concentrations of glial fibrillary acidic protein levels twenty-four hours post-trauma in patients with no CT traumatic lesions, might indicate those who need subsequent MRI.¹³ Further research¹⁴ confirms the correlation between plasma concentrations of glial fibrillary acidic protein levels, intracranial lesions absent on CT, and the need for further MRI neuroimaging. However, in pediatric patients, a meta-analysis¹⁵ shows that S100 calcium-binding protein B (S100B) has the highest sensitivity in predicting TBIs, especially when associated with CT and clinical decision algorithms. CT-negative mTBIs lead to long-term non-specific symptoms, eg,

dizziness, anxiety, loss of concentration, and irritability.¹⁶ In children, MRI-detectable lesions one year after mild head trauma are encountered in almost 50% of the cases.^{17,18} Although The ACR Appropriateness Criteria® Head Trauma-Child¹⁰ does not recommend MRI for acute mild trauma, targeted sub-populations should be considered for additional MRI and TBI specialist follow-up.

According to the Centers for Disease Control and Prevention, TBI is an injury to the brain that may be caused by a bump, blow, jolt, or penetrating injury to the head.¹⁹ Although CT confers a complete and quick imaging evaluation in TBI, the risk of exposing young patients to ionizing radiation is high. Rapid MRI protocols have become more popular in pediatric TBI evaluation as an alternative to CT or an additional workup.²⁰ According to Lindberg DM and Shope C, rapid sequence MRI without anesthesia has also been implemented.^{9,21} MRI is being utilized more in the USA than in other parts of the world to investigate severe TBIs in children.⁸

Brain MR images were first obtained in the 1970s, and MR neuroimaging has come a long way since. The recent standard conventional MRI protocol for HT should include volumetric 3D T1-WI sequences, coronal T2-weighted fast spin echo (T2-FSE) sequences, axial 2D T2-fluid attenuation inversion recovery (T2-FLAIR), susceptibility-weighted imaging (SWI), and diffusion-weighted imaging (DWI).²² T1-WI is employed for mapping the brain's anatomy. T2-WI is used to visualize areas of more significant water content (edema). T2-FLAIR suppresses the high signal from cerebral-spinal fluid and allows the areas of edema in the subarachnoid space or close to the ventricles to be better evaluated. Both SWI and T2*-weighted gradient recall echo (T2*GRE) sequences capitalize on the magnetic susceptibility of paramagnetic iron and thus diagnose small bleeds. SWI can underline existing diffuse axonal injuries associated with microhemorrhages, but some centers use T2*GRE to detect small bleeds.⁸ Even though there is an overlapping between these two sequences, some centers employ them both in trauma MRI.⁸ DWI helps to identify potential ischemic regions and shearing injuries not visible on T2-FLAIR or T2*GRE sequences.²³ Nonetheless, whether obtained on day zero of the HT or a few days later, MRI brings enough details to improve prognostication of long-term neurological outcomes.^{4,8,24} Small hemorrhagic lesions are detected with T2*GRE or SWI sequences. FLAIR sequences have greater sensitivity for non-hemorrhagic lesions, contusions, and vasogenic edema that develop in brainstem and deep brain structures.²⁴ The number of lesions, the volume, and the anatomical location correlate with neurological disability; the child will also experience deficits in cognitive domains such as overall intelligence, memory, and attention. We need to consider that although MRI can bring further light to the case, it is a lengthy investigation, and the patient needs to be clinically stable. Hence, quick brain MRI protocols have been developed to shorten the acquisition time and get as much information as possible. A recent study emphasized the fast brain MRI role in acute pediatric head trauma.²⁵

This pictorial essay aims to review the most common MRI findings of primary acute intracranial lesions encountered in pediatric TBI.

Imaging Protocols and Practical Considerations

The severity of the HT is traditionally evaluated and classified according to the patient's Glasgow Coma Score (GCS) after the initial exam.²⁶ Established in 1974, the Glasgow Coma Scale evaluates the depth and duration of impaired consciousness and coma, attributing a total score for opening the eyes and best motor and verbal response.²⁷ The effect of the traumatic event is a traumatic brain injury (TBI), defined as a traumatically induced structural injury and/or physiologic disruption of brain function as a result of an external force.²⁸ The GCS is correlated with the intensity of the TBI, dividing it into mild (GCS 13–15), moderate (GCS 9–12), and severe (GCS 3–8).²⁹

In pediatric acute blunt HT, non-enhanced CT remains the go-to method to assess the patient initially from an imaging point of view. The ACR Appropriateness Criteria® Head Trauma-Child¹⁰ states that head MRI is usually appropriate in subacute HT. Subacute TBIs occur between day eight and one month after the traumatic event. As stated in the previously mentioned criteria, MRI may bring more diagnostic information in children with acute moderate-severe HT. In such cases, HT is the result of a high-impact force. The patient will most likely develop shear injuries or ischemic lesions that are better delineated using MRI. However, it is not recommended as the first step in diagnosing the latter category of HT. One reason is that MRI is a lengthy process, and in children, it is even more time-consuming since they need patience, reassurance, and easing their anxiety.³⁰ Besides the time aspect, the need for anesthesia³¹ sometimes

accounts for unnecessary delays that should be avoided. As mentioned, the acute mild TBI is a heterogeneous group in which some patients develop long-term consequences. Such children would benefit from MR neuroimaging.

Small cortical contusions (CC), subdural hematomas (SDH), and traumatic axonal injuries (TAI) previously not detected on initial CT scans were diagnosed when using MRI.^{12,32} MRI has a higher specificity and sensitivity in diagnosing small bleeds.^{33–35} It is also better at delineating small bleeds in the posterior fossa and the brainstem.^{36–38} The most commonly used sequences are T2- and T2*-weighted combined with the hem-sensitive ones (susceptibility-weighted) and diffusion-weighted imaging.^{10,11,34,39,40} Recent studies have shown that fast brain MRI protocols can be used on pediatric patients without anesthesia and can have similar results when evaluating TBIs.^{9,21,41} Such protocols include T2-weighted half-Fourier acquisition single-shot turbo spin echo (HASTE) imaging in axial, coronal, and sagittal planes^{9,41} along DWI, ADC, T2-FLAIR, and GRE in the axial plane.⁹ Although different rapid brain MRI protocols have been explored, they vary from hospital to hospital, and no protocol that has been used unanimously in such instances has been implemented.

Our hospital's routine MRI protocol for HT includes the following sequences: T2 AX, T2 COR, SAG 3D T1, COR 3D CUBE T2 FLAIR, 3D SWAN, DWI. We do not use contrast media in the routine protocol. The device used is a General Electric Signa Explorer 1.5 T.

Injury Mechanisms in Accidental HT

There are different causes for accidental HT in children, depending on their age. The most frequent are falls and motor vehicle accidents.⁴²

Two mechanisms have been described to cause the injuries - impulsive and impact loading.⁴³ Impulsive head loading results from a force applied on another part of the body that causes the head to move in a different direction. Impact loading appears when the force is applied directly to the head, either because of a blunt object hitting the head or the head hitting a stationary object. These two different mechanisms will result in two distinct types of lesions. In the case of direct contact, the most frequent injuries are scalp lesions, fractures, coup, and contrecoup brain injuries. Impulsive loading results more frequently in subdural hematomas and traumatic axonal injuries.

Anatomical Characteristics of the Pediatric Head; Lesions' Topography; Hematoma Signal Variability Over Time

The pediatric head has anatomical particularities that entail different intracranial lesions than in adults. Firstly, the head/body ratio changes with age, decreasing over time. Newborns and infants have a large head/body ratio; it decreases as the child grows. In addition to this, weak neck muscles and lax ligaments make them susceptible to sustaining cranio-cervical junction and upper cervical spine injuries.⁴⁴ After age nine, the cervical spine resembles the adult spine more, making the lesions comparable to those found in patients over eighteen.⁴⁴ The pediatric skull has bones with more plasticity and deformity, allowing forces to be better absorbed. This results in fewer skull fractures than in adults. The brain structure also changes over time, accounting for different types of lesions. Newborns and infants have a high-water content brain and small myelin percentage, allowing shear injuries to occur easily. Myelination progresses following known anatomical patterns, turning the brain into a structure with more densely packed fibers and a smaller percentage of water.

Accidental HT may result in different traumatic injuries, and all anatomical structures can be involved. Based on the time they appear, they are either acute or chronic. Also, they can be primary - developed at the time of the trauma, or secondary - as an effect of the first. Based on their topography, the lesions are intra-axial (cortical contusions, traumatic axonal injuries, parenchymal hematoma, vascular injuries) or extra-axial (epidural hematoma, subdural hematoma, traumatic subarachnoid hemorrhage, intraventricular hemorrhage)⁴⁵ (Table 1).

Traumatic lesions can be focal (such as epidural hematoma, subdural hematoma, traumatic subarachnoid hemorrhage, or intraventricular hemorrhage) or diffuse (like traumatic axonal injuries), and they can also coexist within the same patient.⁴⁶ The presence of epidural hematoma, subdural hematoma, and traumatic subarachnoid hemorrhage predicts the progression of cortical contusions.⁴⁷

Table 1 Acute Lesions

| Acute intra-axial lesions | Acute extra-axial lesions |
|---------------------------|-----------------------------------|
| Cortical contusions | Epidural hematoma |
| Traumatic axonal injuries | Subdural hematoma |
| Parenchymal hematoma | Traumatic subarachnoid hemorrhage |
| Vascular injuries | Intraventricular hemorrhage |

After the traumatic injury, extravasation of blood, whether extra- or intra-axial, hem compounds change over time. Chemical changes within the hematoma will affect the MRI signal that we get from it. The age of the bleed is responsible for different signal intensities on different sequences. When the hematoma first appears, ie, in the hyperacute stage (within the first hours of the bleeding), it is a heterogeneous area where some parts have more serum components and fibrin, and others have more erythrocytes. Oxyhemoglobin is inside the erythrocytes and has a higher intensity or isointense signal on T2-weighted images. The oxyhemoglobin decreasing its oxygen content and becoming deoxyhemoglobin starts at the periphery of the hematoma and progresses toward the center. Deoxyhemoglobin has a hypointense T2 signal. The initial clot appears as an area of isointense to slightly hypointense signal in T1-weighted images. Suppose SWI sequences are done in this phase. In that case, the periphery of the hematoma will not have as low a signal as in later cases because there will be no hemosiderin but deoxyhemoglobin. In the acute phase, the center of the hematoma starts to develop more deoxyhemoglobin, which explains the drop in signal in T2 sequences; the signal in T1-weighted sequences remains iso- to hypointense. The acute phase is the first 24–48 hours after bleeding. The early subacute phase lasts from day 2 to 7 after the hemorrhage; methemoglobin replaces deoxyhemoglobin. Although this occurs, the compound is intracellular within the erythrocytes and is mainly concentrated in the center of the hematoma. Methemoglobin is stronger paramagnetic than deoxy methemoglobin, which translates to a higher T1 signal; the T2 signal remains low. A week after the bleed takes place, the late subacute phase begins, and it lasts for two weeks. The red blood cells’ membrane disintegrates during this period, and the intracellular methemoglobin becomes extracellular. This decreases the areas where methemoglobin is concentrated, and more water is bound to the free molecules. The hematoma becomes hyperintense in T1-weighted sequences and hypointense in T2. In the chronic phase of the hematoma, over 28 days after the bleeding, hemosiderin and ferritin are at the border, inside macrophages. Both compounds are superparamagnetic, making the hematoma’s rim hypointense on T2-weighted imaging and SWI. The center of the hematoma has water, protein, and hemoglobin breakdown products, so it will appear hypointense on T1 and hyperintense on T2-weighted imaging (Table 2).

MRI in HT thoroughly assesses brain injuries, especially those inconspicuous on initial non-enhanced CT. The main indication for an MRI on a head trauma patient is when a “clear” CT scan does not explain the neurological status. The lesions that cause the discrepancy between the clinical status and the CT scan results are diffuse axonal injuries, ie, a type of intra-axial traumatic brain injury. We first describe the intra-axial lesions and the corresponding MRI findings.

Acute Primary Intracranial Lesions in TBIs

Cortical Contusions (CC)

CCs are focal hemorrhagic lesions that develop either in the cortex and progress towards the white subcortical matter or in the white-grey matter junction and gradually involve the cortex.⁴⁸ Located on the brain’s surface, they display relative

Table 2 Hematoma Signal Variability Over Time

| The phase of the hematoma | Hem compounds | T1 -WI signal | T2WI signal |
|---------------------------|-----------------------------|-----------------------|-----------------------|
| Hyperacute | Oxyhemoglobin | Isointense/slightly ↓ | Isointense/slightly ↑ |
| Acute | Deoxyhemoglobin | Isointense/slightly ↓ | ↓ |
| Early subacute | Intracellular methemoglobin | ↑ | ↓ |
| Late subacute | Extracellular methemoglobin | ↑ | ↑ |
| Chronic | Ferritin/hemosiderin | ↓ | ↑ |

sparing of the underlying white matter and are surrounded by edema. CCs result from the brain parenchyma hitting the inner table of the skull or being hit by a bony fragment from a comminuted skull fracture. The most frequent sites where CCs appear are the frontal lobe-The orbitofrontal area (overlying the cribriform plate and planum sphenoidale), and the temporal lobe (near the petrous pyramid and posterior to the great wing of the sphenoid bone). The areas prone to sustaining such lesions are those in direct contact with bony ridges or irregular bone surfaces. On the other hand, the cerebellar hemispheres are in contact with the smooth occipital bone surface and rarely are the site of CCs. They can be found under the place where the blunt object hit the head - and are known as coup lesions - or on the opposite side of the brain, known as contrecoup lesions (Figure 1).

When MRI is performed, CCs have a variable signal intensity in both T1- and T2-weighted sequences, according to the age of the bleed. The small cortical spots are usually limited to the brain's outer surface and have a gyral topography. In the acute phase, the hemorrhagic spots display a hypointense signal on T2-weighted sequences and a hypo-/isointense signal on T1-weighted sequences. After hemosiderin is formed, ie, in chronic hemorrhagic contusions, it appears as a low signal spot on T2-weighted sequences and even more so on T2* - weighted sequences. These low signal spots persist indefinitely as an important clue for a previous hemorrhagic event in the area. Fluid attenuation inversion recovery sequence (FLAIR) will best depict the edema, which appears as hyperintense cortical areas surrounding the hemorrhagic contusions (Figure 2). Also, susceptibility-weighted imaging (SWI) shows areas of low-intensity signal corresponding to bleeding in acute, subacute, and chronic hemorrhages.⁴⁹

Diffuse Axonal Injury (DAI)

Traumatic axonal injuries are microscopic axonal damages^{50,51} that appear when acceleration-deceleration and rotational deceleration forces are exerted on the brain during impulsive loading. When widespread, traumatic axonal injuries are referred to as diffuse axonal injuries (DAI).⁵² They are represented by the shearing of the brain parenchyma, making them deeper set lesions than CCs. Whether referred to as traumatic or diffuse axonal injuries, they are the number one lesion for which MRI is performed. Most frequently, they occur at the interface between the cortex and the subcortical white matter and in the corpus callosum. DAIs are non-hemorrhagic or hemorrhagic. In the first case, when performing an MRI, foci will be hyperintense on T2, T2SE, FLAIR, and DWI sequences; on T1-weighted sequences, they appear as hypointense spots. When investigating hemorrhagic DAIs (Figure 3), they show up as small areas of hypointense signal on T2-weighted and hyperintense on T1-weighted protocols (in the subacute phase when there is intracellular methemoglobin). It is essential to mention that in the first 48 hours after the DAI has occurred, DWI sequences are more helpful in detecting small shearing areas than T2*GRE or T2FSE sequences.⁵³ Combining information from the DWI and the corresponding ADC map helps differentiate between DAI with increased or decreased diffusion.⁵⁴ As time passes, the edema subsides, and the axons degenerate, resulting in gliosis or hemosiderin impregnation; the latter will appear indefinitely on T2* sequences. Of all the intra-axial injuries better diagnosed by MRI, DAIs are the most common and have a worse prognosis. The extent of the DAIs is proportional to the severity of the trauma. Grade I- DAI is located at the white matter-cortex junction. In this case, the most frequent locations are in the parasagittal regions of the frontal lobes and periventricular in the temporal lobes. Grade II- DAI is located at the white matter-cortex junction and the corpus callosum - especially the splenium and the posterior part. Grade III- DAI is situated as in grade II and the brainstem (Figure 4). Although grade I DAI has the fastest recovery, neurological exams at discharge time seem comparable between the three grades.^{55,56}

Parenchymal Hematoma (PH)

Unlike CCs, which result from the brain parenchyma hitting a rough area of the inner side of the skull, PH arises after small blood vessels inside the brain are torn because of shearing forces. Since the area of the brain where they appear is not under direct impact of forces, the hematoma will not have as much surrounding edema as the CCs. In most cases, traumatic parenchymal hematomas' typical location is in the white matter of the front-temporal lobes. They are seldom a unique finding, most of them being associated with DIAs, CCs, and skull fractures. MRI will show different areas of bleeding inside the brain parenchyma, and the signal intensity will depend on the age of the bleeding, as previously mentioned.

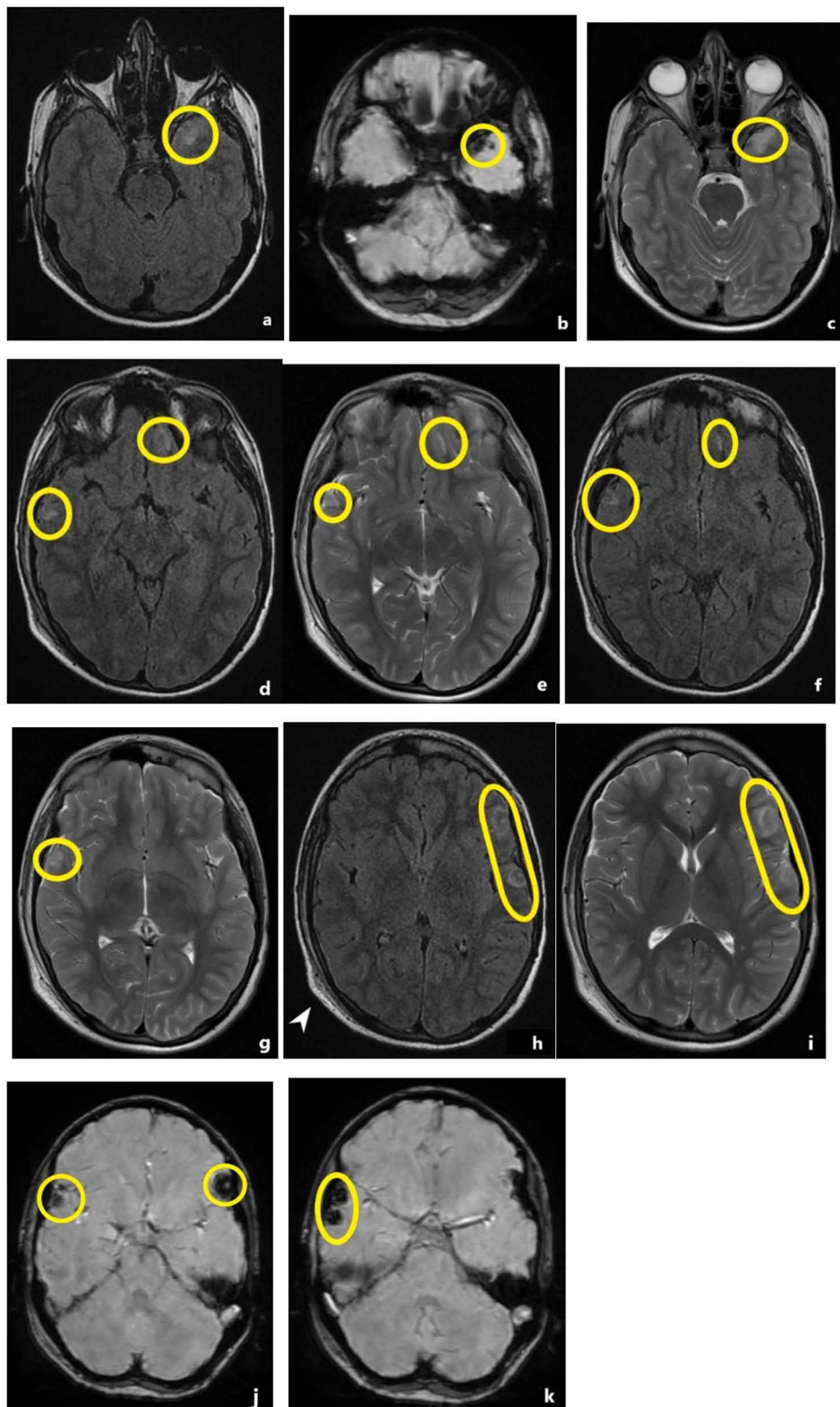


Figure 1 Right occipital epicranial hematoma (white pointed arrow h). All images show case bilateral cortical contusions on different MR sequences. (a, d, f, h) FLAIR sequences depicting hyperintense signal areas consistent with CCs (yellow circles and capsule). (b, j, k) SWI sequences display the same lesions with hypointense signal (yellow circles and capsule). (c, e, g, i) CCs with hyperintense T2 signal (yellow circles and capsule). (d, e, f) Left frontal non-hemorrhagic traumatic axonal injury (yellow circles and capsule). (d, e) FLAIR sequences; (f) T2-weighted sequences. (h-i) The epicranial hematoma located in the right occipital area pinpoints the force impact; high-signal FLAIR and T2 lesions support the “contrecoup lesions” diagnosis (yellow capsule).

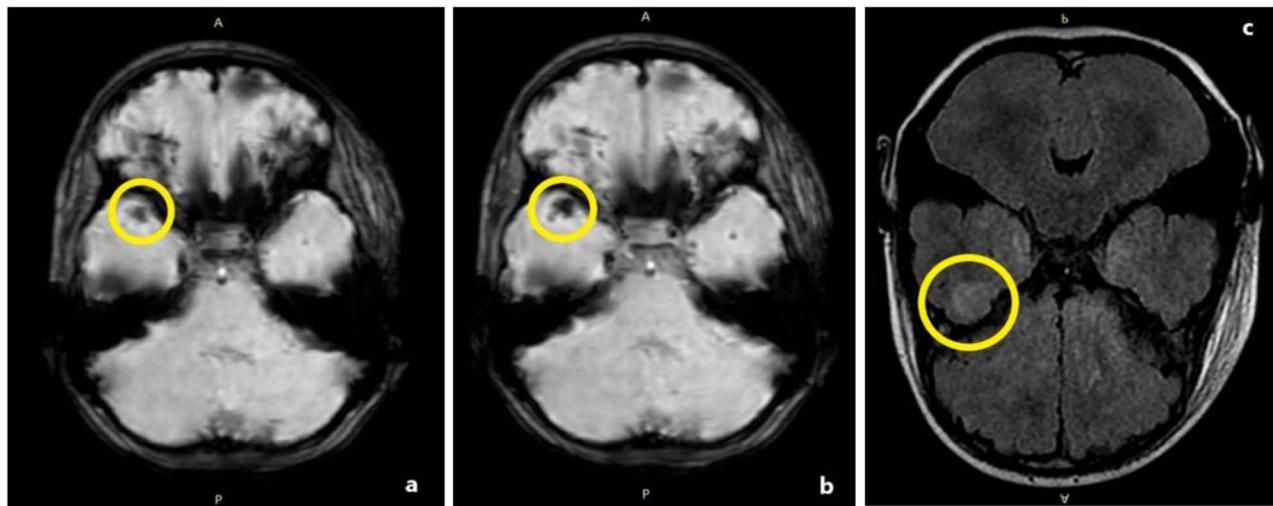


Figure 2 An 8-year-old pedestrian girl was involved in a motor vehicle accident. (a and b) Eighteen hours after admission, an MRI was performed. Hemorrhagic CC in the anterior part of the right temporal lobe appears as an area of hypointense SWI signal (yellow circle). (c) corresponding FLAIR signal imaging at the same level, showcasing hyperintense cortical (yellow circle).

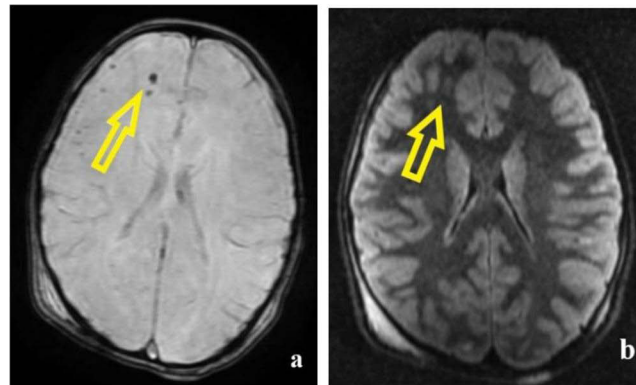


Figure 3 8-year-old girl, pedestrian involved in a motor vehicle accident. (a) In the white matter of the right frontal lobe- SWI and FLAIR imaging show small areas of low SWI signal (yellow arrow). (b) high FLAIR signal, consistent with frontal haemorrhagic DAIs (yellow arrow).

Epidural Hematoma (EDH)

This is an extra-axial accumulation of blood between the inner table of the skull and the dura mater, with a biconvex shape and mass effect on the underlying brain. If it is large enough, it can exert a mass effect on the underlying brain, shift the midline, cause herniation, and then coma and death.⁵⁷ In children, EDHs can occur in case of head trauma without any fracture if there is a tear or an elongation of the meningeal arteries.^{58,59} The MRI aspect depends on the age of the bleed. In acute EDHs, the lenticular shape collection has an isointense T1 signal, and the initial hyperintense T2 signal in the hyperacute phase drops. The EDH is in contact with the dura, which appears as a hypointense linear structure on T1 and T2 sequences³¹ (Figure 5).

Subdural Hematoma (SDH)

This is a crescent-shaped collection located under the dura mater. It can extend from the anterior part of the falx cerebri to the posterior one or over the tentorium. It is usually the result of tearing in the subdural veins that cross that space after an abrupt deceleration and is more frequently found in abuse head trauma injuries than in accidental head trauma.⁶⁰ The subdural space is larger than the extradural one, so if there is a bleed in the subdural space, it will occupy a larger area. The width of an SDH is smaller than that of an EDH.

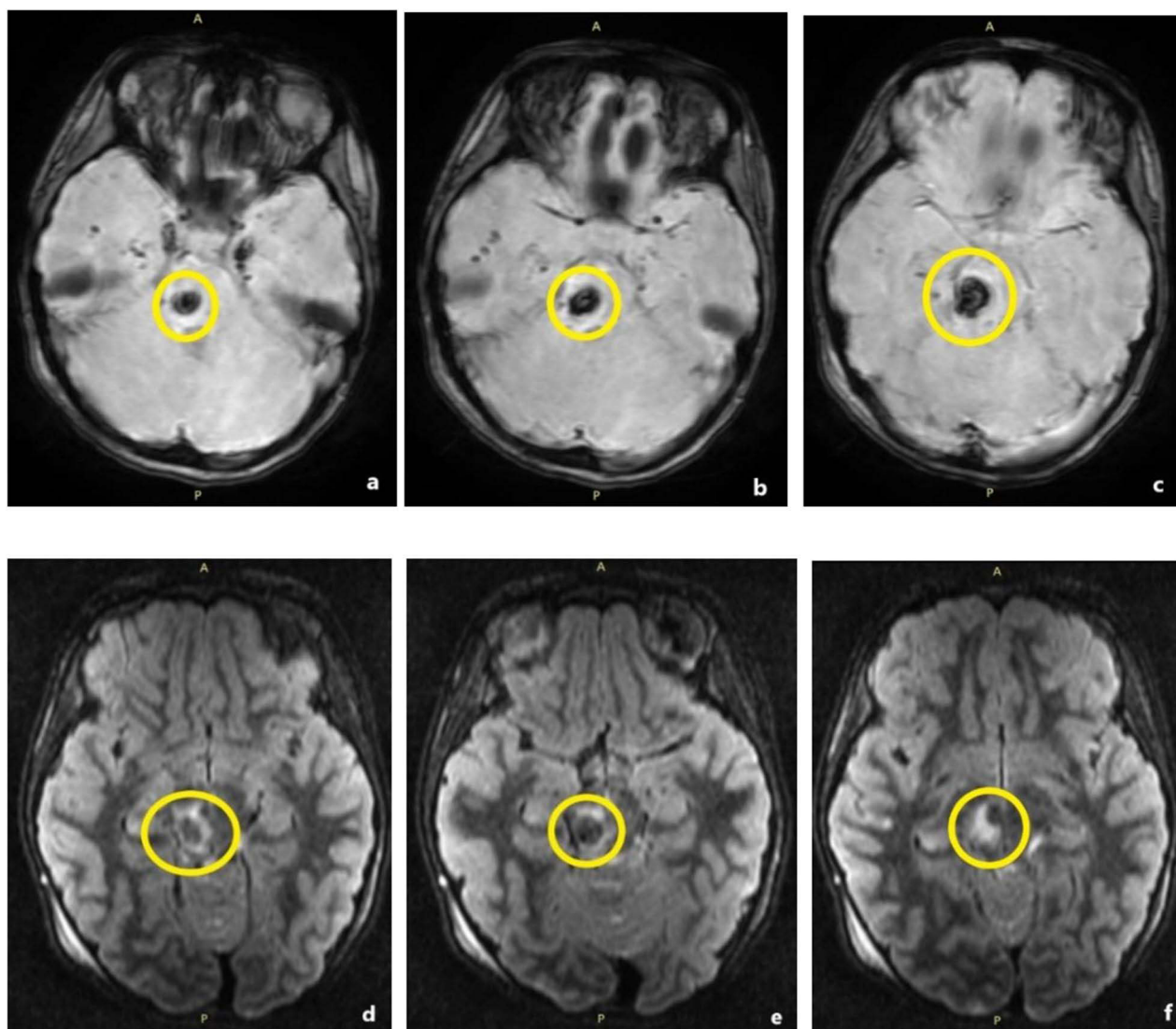


Figure 4 8-year-old girl, motor vehicle accident. 18 hours after the initial non enhanced CT scan, MRI is performed. (a-c) Grade III DAI involving the pons and mesencephalon (yellow circle) - SWI hypo signal (d-f) FLAIR hypo signal. (c-f) The haemorrhagic lesion is surrounded by oedema (FLAIR high signal).

In the acute stage of the hematoma, an MRI will show a crescent-shaped collection with an isointense T1 signal and a decreasing signal on T2 (from hyperintense in the hyperacute phase to isointense in a few days) (Figure 6).

Traumatic Subarachnoid Hemorrhage (tSAH)

It is frequently caused by tearing in small pial vessels or extension of a hemorrhagic contusion, hematoma, and intraventricular bleeding into the subarachnoid space. They appear as fine lines over the gyri or in the cisterns and are hard to diagnose on T1 or T2. The best imaging tool for this lesion is the FLAIR sequence, where the tSAH appears as fine lines with intense hypersignal (Figure 7).⁶¹

Intraventricular Hemorrhage (IVH)

It can be caused by torn veins from the subependymal space (due to rotational forces) or a bleed in the choroid plexus, rupture of a PH in the ventricles, or because of retrograde flow of tSAH through the fourth ventricle. There will be an intraventricular blood-CSF level. FLAIR sequence is the best to diagnose IVH (Figure 8).

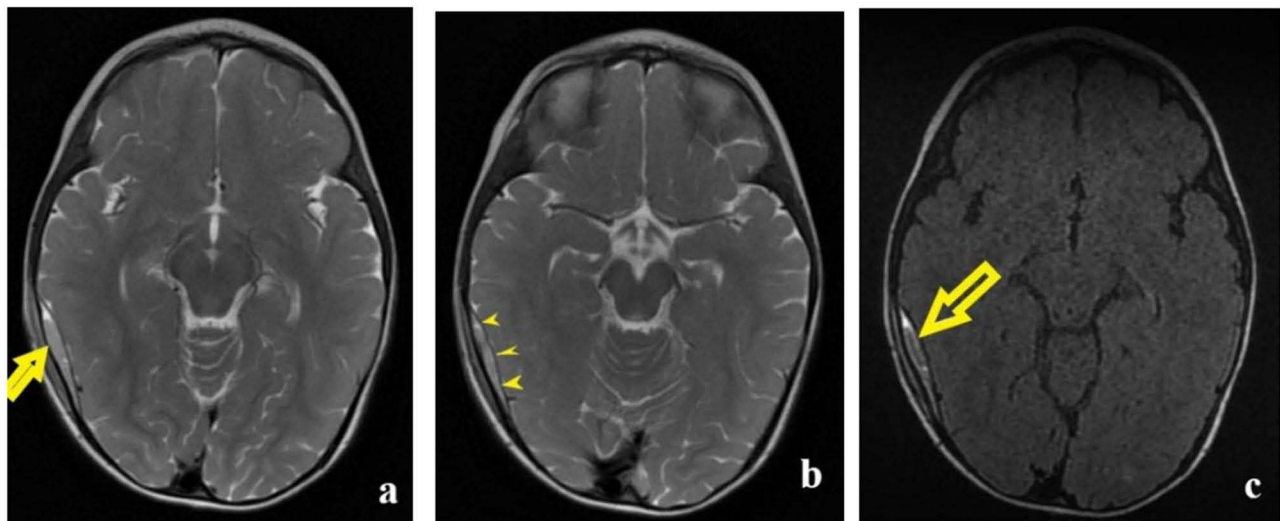


Figure 5 (a) The T2-WI axial section depicts a right temporoparietal lenticular collection (yellow arrow) with a small mass effect on the underlying brain parenchyma. (b) T2-WI axial section: yellow arrowheads point to the dura mater that appears as a fine black line between the hematoma and the brain parenchyma. (c) FLAIR axial imaging shows the same collection with a hyperintense signal (yellow arrow).

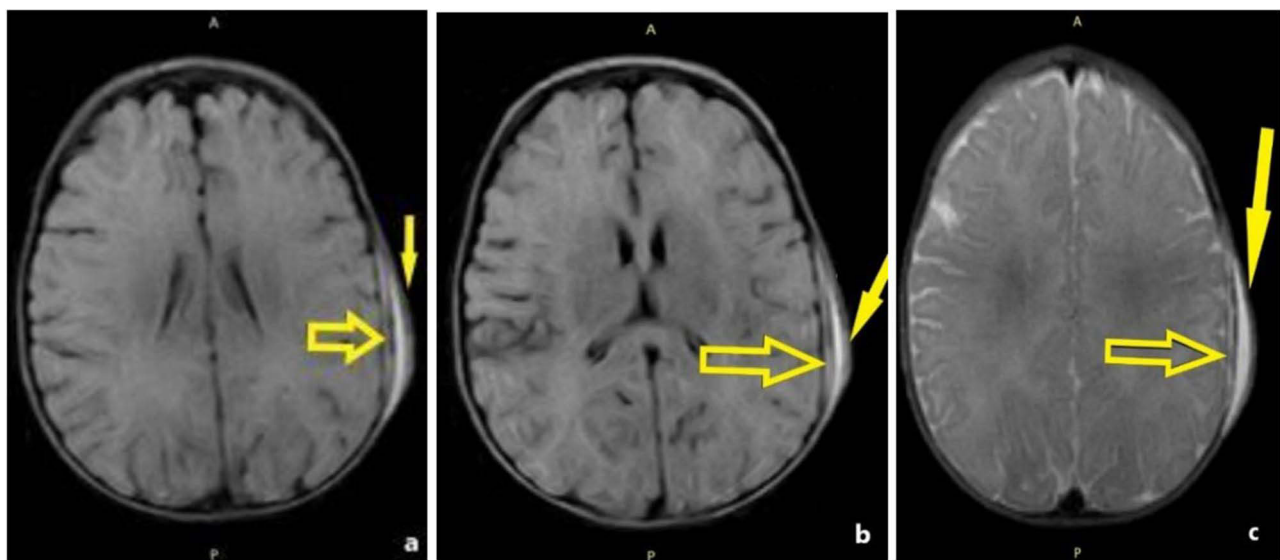


Figure 6 5-month-old baby fell from 2 feet. (a and b) Left-sided parietal subdural hematoma (yellow arrow)- A crescent-shaped collection with high-intensity FLAIR signal; hyperintense epicranial left parietal hematoma (yellow arrow) on FLAIR. (c) isointense T2 signal; T2-weighted imaging epicranial left parietal hematoma (yellow arrow).

Vascular Injuries (VI)

They can cause both intra- and extra-axial traumatic bleeds. Both the arteries and veins can sustain traumatic injuries. There have been cases of vascular injuries reported after minor HT in children, but in most of the situations, they remain an uncommon result of the trauma.⁶² Case reports and retrospective studies presented a reduced prevalence of such lesions.^{62–64} Arterial acute vascular traumatic lesions include dissection and pseudoaneurysms. The most vulnerable vessel is the internal carotid artery, especially where it comes in contact with bony ridges (entering the carotid canal and exiting from the cavernous sinus). Skull base fractures are associated with these types of lesions. Such bone lesions should alert the radiologist to look carefully at the vessel. MRI can detect intramural hematoma on T1-weighted with fat suppression, intimal flap in case of dissection, and absent flow-void. When the arterial injury involves the cavernous segment of the internal carotid artery,

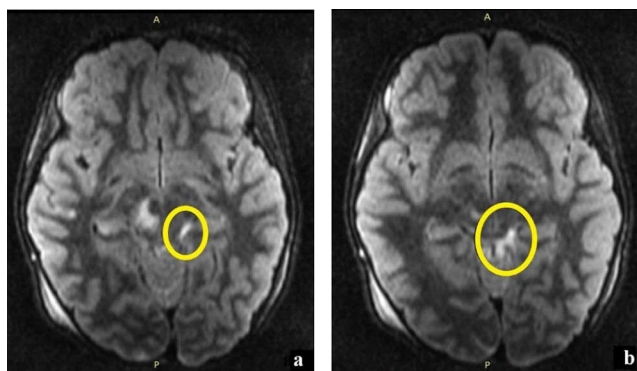


Figure 7 An 8-year-old patient, motor vehicle accident. (a and b) The left ambient cistern has a high-intensity FLAIR signal (yellow circle) suggestive of traumatic subarachnoid hemorrhage.

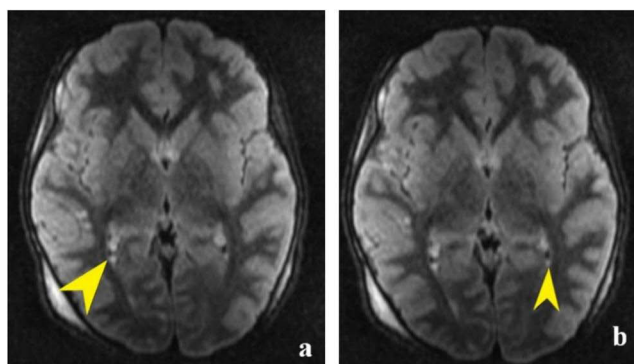


Figure 8 An 8-year-old girl was in a motor vehicle accident. (a and b) Small FLAIR hyperintense signal areas (yellow arrowheads) suggest intraventricular hemorrhage in the occipital horns of the lateral ventricles.

and if there is a complete tear in all the arterial wall layers, high-pressure blood will pass into the cavernous plexus. The patient develops an arterio-venous fistula. In this case, an MRI will show an enlarged cavernous sinus and its tributaries (superior ophthalmic vein and petrosinus sinuses). Flow void anomalies will also be present. Another cause of carotid-cavernous fistula is an aneurysm rupturing in the cavernous portion of the internal carotid artery. Dural fistulas are also a possible complication, and they occur when a torn meningeal artery communicates with a meningeal vein.

Venous injuries can also occur after HT. When skull fractures cross the sagittal or transverse sinuses, tears in the venous wall may occur, and bleeding begins. The hematoma occupies the extradural space, but its size differs from that of arterial origin. Because of the epidural hematoma's mass effect on the venous sinus, venous thrombosis can develop. In addition, thrombosis can also have a direct traumatic cause and develop after a tear in the vessel wall.

Discussion

Specialist literature covers all primary intracranial lesions in pediatric patients, ie, cortical contusions, traumatic axonal injuries, epidural hematoma, subdural hematoma, traumatic subarachnoid hemorrhage, intraventricular hemorrhage, parenchymal hematoma, and vascular injuries.⁴⁵ DAIs and CCs were the most frequent findings in patients who had an MRI done a few days after the trauma occurred. Parenchymal hematomas and vascular injuries have not been encountered in our department. Most HT patients we have had over the years have sustained mild and moderate TBIs. The patients who sustained severe TBIs were transferred to other hospitals after the initial CT scan was performed.

Conclusion

Clinicians rely on algorithms to adequately select patients undergoing CT scanning in HT. It is true that CT scanning provides essential details when investigating acute TBIs and remains the gold standard for acute HT imaging. Nevertheless, ionizing radiation should be limited because of its possible long-term impact. MRI not only avoids radiation but also reveals lesions inconspicuous on CT, making it a valuable tool for thoroughly assessing mortality- and morbidity-inducing TBIs. Further, MRI may provide valuable additional insights when the clinical status is not on par with the CT scans, which show no apparent lesions, or when new, persistent, or worsening neurological symptoms appear.

MRI protocols in HT have evolved over the years, allowing for a larger group of patients to be evaluated. If decades ago, MRI for HT only used T1-WI and T2-WI, things have changed. Nowadays, fast brain MRI protocols take less time, allowing young patients to undergo such investigations without anesthesia. To resume, such protocols include T2-weighted half-Fourier acquisition single-shot turbo spin echo (HASTE) imaging in axial, coronal, and sagittal planes along with DWI, ADC, T2-FLAIR, and GRE in the axial plane.

Recently used sequences aimed at better delineating intracranial lesions associated with TBIs facilitate a faster and better-targeted diagnosis. The purpose of this pictorial review was educational, seeking to familiarize young professionals with the most common primary acute TBIs that occur in HT. The presentation was not comprehensive, but it provided essential information.

Declarations

This is a pictorial review.

Abbreviations

CC, Cortical contusions; CCs, focal hemorrhagic; CT, computer tomography; DAI- Diffuse axonal injury; DWI, diffusion weighted imaging; EDH, Epidural hematomas; FLAIR, Fluid attenuation inversion recovery; HCC, Hemorrhagic cortical contusions; HT, Head trauma; ICH, Intracerebral hemorrhage; IVH, Intraventricular hematomas; MRI, Magnetic resonance imaging; t SAH, Traumatic subarachnoid hemorrhage; SDH, Subdural hematoma; SWI, Susceptibility weighted imaging; T2* GRE, T2* gradient-recalled echo; TBI, Traumatic brain injury; VI, Vascular injuries.

Ethics Approval and Consent to Participate

The study was conducted in accordance with the Declaration of Helsinki, and the protocol was approved by the Ethics Committee of Clinical Emergency Hospital, Galati, Romania. (Project identification code: 4579/14.11.2023).

Author Contributions

All authors made a significant contribution to the work reported, whether that is in the conception, study design, execution, acquisition of data, analysis and interpretation, or in all these areas; took part in drafting, revising or critically reviewing the article; gave final approval of the version to be published; have agreed on the journal to which the article has been submitted; and agree to be accountable for all aspects of the work.

Funding

This review received no external funding.

Disclosure

The authors declare that they have non-financial competing interests.

References

1. Thompson L, Hill M, Shaw G. Defining major trauma: a literature review. *British Paramedic Journal*. 2019;4(1):22–30. PMID: 33328825; PMCID: PMC7706773. doi:10.29045/14784726.2019.06.4.1.22
2. Dodd C, Halliday K, Somers J. Paediatric trauma: experience from the UK's busiest trauma centre. *Clin Radiol*. 2021;76(8):559–570. Epub 2021 Apr 2. PMID: 33820638. doi:10.1016/j.crad.2021.03.006

3. Dibera GB, Yizengaw MA, Yadeta GL, Iticha DD, Gamachu B, Legesse BT. Clinical characteristics and outcomes of traumatic brain injury in patients admitted to surgical ward of Jimma Medical Center, Southwest Ethiopia: a prospective observational follow-up study. *BMJ Open*. 2024;14(2):e080598. doi:10.1136/bmjopen-2023-080598
4. Figaji A. An update on pediatric traumatic brain injury. *Childs Nerv Syst*. 2023;39(11):3071–3081. Epub 2023 Oct 6. PMID: 37801113; PMCID: PMC10643295. doi:10.1007/s00381-023-06173-y
5. Paneitz DC, Ahmad S. Pediatric trauma update. *Mo Med*. 2018;115(5):438–442. PMID: 30385992; PMCID: PMC6205270.
6. Dennis EL, Caeyenberghs K, Asarnow RF, et al. Challenges and opportunities for neuroimaging in young patients with traumatic brain injury: a coordinated effort towards advancing discovery from the ENIGMA pediatric moderate/severe TBI group. *Brain Imaging Behav*. 2021;15(2):555–575. doi:10.1007/s11682-020-00363-x
7. Rossi A, Argyropoulou M, Zlatareva D, et al. ESNR pediatric neuroradiology subspecialty committee; ESPR neuroradiology taskforce. European recommendations on practices in pediatric neuroradiology: consensus document from the European society of neuroradiology (ESNR), European society of paediatric radiology (ESPR) and European Union of Medical specialists division of neuroradiology (UEMS). *Pediatr Radiol*. 2023;53(1):159–168. Epub 2022 Sep 5. PMID: 36063184; PMCID: PMC9816178. doi:10.1007/s00247-022-05479-4
8. Ferrazzano PA, Rosario BL, Wisniewski SR, et al. Use of magnetic resonance imaging in severe pediatric traumatic brain injury: assessment of current practice. *J Neurosurg Pediatr*. 2019;23(4):471–479. doi:10.3171/2018.10.PEDS18374
9. Shope C, Alshareef M, Larrew T, et al. Utility of a pediatric fast magnetic resonance imaging protocol as surveillance scanning for traumatic brain injury. *J Neurosurg Pediatr*. 2021;27(4):475–481. PMID: 33545669. doi:10.3171/2020.8.PEDS20496.PEDS20496
10. Ryan ME, Pruthi S, Desai NK, et al.; Expert Panel on Pediatric Imaging. ACR appropriateness criteria[®] head trauma-child. *J Am Coll Radiol*. 2020;17(5S):S125–S137. PMID: 32370957. doi:10.1016/j.jacr.2020.01.026
11. Wintermark M, Sanelli PC, Anzai Y, Tsiouris AJ, Whitlow CT. ACR head injury institute; ACR head injury institute. imaging evidence and recommendations for traumatic brain injury: conventional neuroimaging techniques. *J Am Coll Radiol*. 2015;12(2):e1–14. Epub 2014 Nov 25. PMID: 25456317.
12. Provenzale JM. Imaging of traumatic brain injury: a review of the recent medical literature. *AJR Am J Roentgenol*. 2010;194(1):16–19. PMID: 20028899. doi:10.2214/AJR.09.3687
13. Yue JK, Yuh EL, Korley FK, et al. TRACK-TBI Investigators. Association between plasma GFAP concentrations and MRI abnormalities in patients with CT-negative traumatic brain injury in the TRACK-TBI cohort: a prospective multicentre study. *Lancet Neurol*. 2019;18(10):953–961. doi:10.1016/S1474-4422(19)30282-0.
14. Yue JK, Upadhyayula PS, Avalos LN, Deng H, Wang KKW. The role of blood biomarkers for magnetic resonance imaging diagnosis of traumatic brain injury. *Medicina*. 2020;56(2):87. PMID: 32098419; PMCID: PMC7074393. doi:10.3390/medicina56020087
15. Marzano LAS, Batista JPT, de Abreu Arruda M, et al. Traumatic brain injury biomarkers in pediatric patients: a systematic review. *Neurosurg Rev*. 2022;45(1):167–197. Epub 2021 Jun 25. PMID: 34170424. doi:10.1007/s10143-021-01588-0
16. Trifan G, Gattu R, Haacke EM, Kou Z, Benson RR. MR imaging findings in mild traumatic brain injury with persistent neurological impairment. *Magn Reson Imaging*. 2017;37:243–251. Epub 2016 Dec 7. PMID: 27939436. doi:10.1016/j.mri.2016.12.009
17. Datta SG, Pillai SV, Rao SL, Kovoov JM, Chandramouli BA. Post-concussion syndrome: correlation of neuropsychological deficits, structural lesions on magnetic resonance imaging and symptoms. *Neurol India*. 2009;57(5):594–598. PMID: 19934558. doi:10.4103/0028-3886.57810
18. Riedy G, Senseney JS, Liu W, et al. Findings from structural MR imaging in military traumatic brain injury. *Radiology*. 2016;279(1):207–215. Epub 2015 Dec 15. PMID: 26669604. doi:10.1148/radiol.2015150438
19. Centers for Disease Control and Prevention-Traumatic Brain Injury & Concussion. Available from: https://www.cdc.gov/traumaticbraininjury/get_the_facts.html. Accessed 24 April 2024.
20. Franklin D, Barr C, Nguyen D, O’Shaughnessy D, Gilbert OE, Quinsey C. Clinical indications for rapid sequence MRI in pediatric neurosurgical patients and the limitations and barriers to implementation. *J Vis Exp*. 2024;203. PMID: 38284552. doi:10.3791/65797
21. Lindberg DM, Stence NV, Grubenhoff JA, et al. Feasibility and accuracy of fast MRI versus CT for traumatic brain injury in young children. *Pediatrics*. 2019;144(4):e20190419. PMID: 31533974. doi:10.1542/peds.2019-0419
22. Branson HM, Martinez-Rios C. Conventional MR imaging in trauma management in pediatrics. *Neuroimaging Clin N Am*. 2023;33(2):251–260. Epub 2023 Feb 18. PMID: 36965943. doi:10.1016/j.nic.2023.01.001
23. Huisman TA, Sorensen AG, Hergan K, Gonzalez RG, Schaefer PW. Diffusion-weighted imaging for the evaluation of diffuse axonal injury in closed head injury. *J Comput Assist Tomogr*. 2003;27(1):5–11. PMID: 12544235. doi:10.1097/00004728-200301000-00002
24. Smitherman E, Hernandez A, Stavinoha PL, et al. Predicting outcome after pediatric traumatic brain injury by early magnetic resonance imaging lesion location and volume. *J Neurotrauma*. 2016;33(1):35–48. Epub 2015 Jun 19. PMID: 25808802. doi:10.1089/neu.2014.3801
25. National Library of Medicine.Clinical Trials.gov. Rapid RMI for Acute Pediatric Head Trauma. Available from: <https://clinicaltrials.gov/study/NCT03291964>. Accessed 25 April 2024.
26. Alberts A, Lucke-Wold B. Updates on improving imaging modalities for traumatic brain injury. *J Integr Neurosci*. 2023;22(6):142. PMID: 38176928. doi:10.31083/j.jin2206142
27. Teasdale G, Jennett B. Assessment of coma and impaired consciousness. A practical scale. *Lancet*. 1974;2(7872):81–84. PMID: 4136544. doi:10.1016/s0140-6736(74)91639-0
28. Mckee AC, Daneshvar DH. The neuropathology of traumatic brain injury. *Handb Clin Neurol*. 2015;127:45–66. PMID: 25702209. doi:10.1016/B978-0-444-52892-6.00004-0
29. Wilson JT, Pettigrew LE, Teasdale GM. Structured interviews for the Glasgow outcome scale and the extended Glasgow outcome scale: guidelines for their use. *J Neurotrauma*. 1998;15(8):573–585. doi:10.1089/neu.1998.15.573 PMID: 9726257.
30. Sirén A, Nyman M, Syvänen J, Mattila K, Hirvonen J. Utility of brain imaging in pediatric patients with a suspected accidental spinal injury but no brain injury-related symptoms. *Childs Nerv Syst*. 2024;40(5):1435–1441. Epub ahead of print. PMID: 38279986. doi:10.1007/s00381-024-06298-8
31. Mutch CA, Talbott JF, Gean A. Imaging evaluation of acute traumatic brain injury. *Neurosurg Clin N Am*. 2016;27(4):409–439. Epub 2016 Aug 10. PMID: 27637393; PMCID: PMC5027071. doi:10.1016/j.nec.2016.05.011
32. Linsenmaier U, Wirth S, Kanz KG, Geyer LL. Imaging minor head injury (MHI) in emergency radiology: MRI highlights additional intracranial findings after measurement of trauma biomarker S-100B in patients with normal CCT. *Br J Radiol*. 2016;89(1061):20150827. Epub 2015 Dec 23. PMID: 26607648; PMCID: PMC4985459. doi:10.1259/bjr.20150827

33. Datta S, Stoodley N, Jayawant S, Renowden S, Kemp A. Neuroradiological aspects of subdural haemorrhages. *Arch Dis Child.* 2005;90(9):947–951. PMID: 16113131; PMCID: PMC1720557. doi:10.1136/adc.2002.021154
34. Bertsimas D, Dunn J, Steele DW, Trikalinos TA, Wang Y. Comparison of machine learning optimal classification trees with the pediatric emergency care applied research network head trauma decision rules. *JAMA Pediatr.* 2019;173(7):648–656. PMID: 31081856; PMCID: PMC6515573. doi:10.1001/jamapediatrics.2019.1068
35. Kemp AM, Rajaram S, Mann M, et al.; Welsh Child Protection Systematic Review Group. What neuroimaging should be performed in children in whom inflicted brain injury (iBI) is suspected? A systematic review. *Clin Radiol.* 2009;64(5):473–483. Epub 2009 Feb 20. PMID: 19348842. doi:10.1016/j.crad.2008.11.011
36. Hunter JV, Wilde EA, Tong KA, Holshouser BA. Emerging imaging tools for use with traumatic brain injury research. *J Neurotrauma.* 2012;29(4):654–671. Epub 2011 Oct 17. PMID: 21787167; PMCID: PMC3289847. doi:10.1089/neu.2011.1906
37. Skandsen T, Kvistad KA, Solheim O, Strand IH, Folvik M, Vik A. Prevalence and impact of diffuse axonal injury in patients with moderate and severe head injury: a cohort study of early magnetic resonance imaging findings and 1-year outcome. *J Neurosurg.* 2010;113(3):556–563. JNS09626. PMID: 19852541. doi:10.3171/2009.9
38. Tong KA, Ashwal S, Holshouser BA, et al. Hemorrhagic shearing lesions in children and adolescents with posttraumatic diffuse axonal injury: improved detection and initial results. *Radiology.* 2003;227(2):332–339. PMID: 12732694. doi:10.1148/radiol.2272020176
39. Amyot F, Arciniegas DB, Brazaitis MP, et al. A review of the effectiveness of neuroimaging modalities for the detection of traumatic brain injury. *J Neurotrauma.* 2015;32(22):1693–1721. Epub 2015 Sep 30. PMID: 26176603; PMCID: PMC4651019. doi:10.1089/neu.2013.3306
40. Bazarian JJ, Biberthaler P, Welch RD, et al. Serum GFAP and UCH-L1 for prediction of absence of intracranial injuries on head CT (ALERT-TBI): a multicentre observational study. *Lancet Neurol.* 2018;17(9):782–789. Epub 2018 Jul 24. PMID: 30054151. doi:10.1016/S1474-4422(18)30231-X
41. Kabakus IM, Spampinato MV, Knipfing M, et al. Fast brain magnetic resonance imaging with half-Fourier acquisition with single-shot turbo spin echo sequence in detection of intracranial hemorrhage and skull fracture in general pediatric patients: preliminary results. *Pediatr Emerg Care.* 2021;37(12):e1168–e1172. PMID: 31804431. doi:10.1097/PEC.0000000000001949
42. Dewan MC, Mummareddy N, Wellons JC, Bonfield CM. Epidemiology of global pediatric traumatic brain injury: qualitative review. *World Neurosurg.* 2016;91:497–509. Epub 2016 Mar 25. PMID: 27018009. doi:10.1016/j.wneu.2016.03.045
43. Keating CE, Cullen DK. Mechanosensation in traumatic brain injury. *Neurobiol Dis.* 2021;148:105210. Epub 2020 Nov 28. PMID: 33259894; PMCID: PMC7847277. doi:10.1016/j.nbd.2020.105210
44. Sirén A, Nyman M, Syvänen J, Mattila K, Hirvonen J. Emergency MRI in spine trauma of children and adolescents—a pictorial review. *Children.* 2023;10(7):1094. PMID: 37508591. doi:10.3390/children10071094
45. Brant WE, Clyde AH. *Fundamentals of Diagnostic Radiology.* Lippincott Williams & Wilkins; (2007) Google Scholar.
46. Capizzi A, Woo J, Verduzco-Gutierrez M. Traumatic brain injury: an overview of epidemiology, pathophysiology, and medical management. *Med Clin North Am.* 2020;104(2):213–238. doi:10.1016/j.mcna.2019.11.001 PMID: 32035565.
47. Shafiei M, Sabouri M, Veshnavei HA, Tehrani DS. Predictors of radiological contusion progression in traumatic brain injury. *Int J Burns Trauma.* 2023;13(2):58–64. PMID: 37215509; PMCID: PMC10195219.
48. Pellot JE. De Jesus o. cerebral contusion. 2023 Aug 28. *StatPearls [Internet].* Treasure Island (FL). StatPearls Publishing. 2024. Jan. PMID: 32965818. <https://www.ncbi.nlm.nih.gov/books/NBK562147/>.
49. Durak MA, Ş G, Derya S, et al. A comparison of computerized tomography and flair-SWI MRI results of patients with head injury attending the emergency department. *Eur Rev Med Pharmacol Sci.* 2022;26(24):9157–9161. PMID: 36591827. doi:10.26355/eurrev_202212_30665
50. Adams JH, Graham DI, Murray LS, Scott G. Diffuse axonal injury due to nonmissile head injury in humans: an analysis of 45 cases. *Ann Neurol.* 1982;12(6):557–563. PMID: 7159059. doi:10.1002/ana.410120610
51. Adams JH, Doyle D, Ford I, Gennarelli TA, Graham DI, McLellan DR. Diffuse axonal injury in head injury: definition, diagnosis and grading. *Histopathology.* 1989;15(1):49–59. PMID: 2767623. doi:10.1111/j.1365-2559.1989.tb03040.x
52. Krieg JL, Leonard AV, Turner RJ, Corrigan F. Identifying the phenotypes of diffuse axonal injury following traumatic brain injury. *Brain Sci.* 2023;13(11):1607. PMID: 38002566; PMCID: PMC10670443. doi:10.3390/brainsci13111607
53. Le TH, Gean AD. Neuroimaging of traumatic brain injury. *Mt Sinai J Med.* 2009;76(2):145–162. PMID: 19306377. doi:10.1002/msj.20102
54. Hergan K, Schaefer PW, Sorensen AG, Gonzalez RG, Huisman TA. Diffusion-weighted MRI in diffuse axonal injury of the brain. *Eur Radiol.* 2002;12(10):2536–2541. Epub 2002 Apr 30. PMID: 12271396. doi:10.1007/s00330-002-1333-2
55. El-Abtah ME, Kashkoush A, Pettitt JC, et al. Diffuse axonal injury pattern predicts timing of in-hospital neurologic recovery: a retrospective case series. *World Neurosurg.* 2023;24(S1878–8750(23)):00845–00848. Epub ahead of print. PMID: 37356490. doi:10.1016/j.wneu.2023.06.076
56. Janas AM, Qin F, Hamilton S, et al. Diffuse axonal injury grade on early MRI is associated with worse outcome in children with moderate-severe traumatic brain injury. *Neurocrit Care.* 2022;36(2):492–503. Epub 2021 Aug 30. PMID: 34462880; PMCID: PMC8405042. doi:10.1007/s12028-021-01336-8
57. De Stefano F, Fiani B, Mayo T. A foundational “survival guide” overview of sports-related head injuries. *Cureus.* 2020;12(11):e11636. PMID: 33376648; PMCID: PMC7755598. doi:10.7759/cureus.11636
58. Echara M, Das AK, Agrawal M, Gupta A, Sharma A, Singh SK. Prognostic factors and outcome of surgically treated supratentorial versus infratentorial epidural hematoma in pediatrics: a comparative study of 350 patients at a tertiary center of a developing country. *World Neurosurg.* 2023;171:e447–e455. Epub 2022 Dec 14. PMID: 36528317. doi:10.1016/j.wneu.2022.12.040
59. Umerani MS, Abbas A, Aziz F, Shahid R, Ali F, Rizvi RK. Pediatric extradural hematoma: clinical assessment using king’s outcome scale for childhood head injury. *Asian J Neurosurg.* 2018;13(3):681–684. PMID: 30283526. doi:10.4103/ajns.AJNS_164_16
60. Caré MM. Parenchymal Insults in abuse—a potential key to diagnosis. *Diagnostics.* 2022;12(4):955. PMID: 35454003; PMCID: PMC9029348. doi:10.3390/diagnostics12040955
61. Noguchi K, Ogawa T, Seto H, et al. Subacute and chronic subarachnoid hemorrhage: diagnosis with fluid-attenuated inversion-recovery MR imaging. *Radiology.* 1997;203(1):257–262. PMID: 9122404. doi:10.1148/radiology.203.1.9122404
62. Jones TS, Burlew CC, Kornblith LZ, et al. Blunt cerebrovascular injuries in the child. *Am J Surg.* 2012;204(1):7–10. Epub 2011 Dec 15. PMID: 22172317. doi:10.1016/j.amjsurg.2011.07.015

63. McGuire D, Mielke N, Bahl A. Atypical presentation of traumatic pediatric carotid artery dissection: a case report. *Clin Pract Cases Emerg Med.* 2022;6(3):229–231. PMID: 36049190; PMCID: PMC9436487. doi:10.5811/cpcem.2022.4.56488
64. Mortazavi MM, Verma K, Tubbs RS, Harrigan M. Pediatric traumatic carotid, vertebral and cerebral artery dissections: a review. *Childs Nerv Syst.* 2011;27(12):2045–2056. doi:10.1007/s00381-011-1409-x

Journal of Multidisciplinary Healthcare

Dovepress

Publish your work in this journal

The Journal of Multidisciplinary Healthcare is an international, peer-reviewed open-access journal that aims to represent and publish research in healthcare areas delivered by practitioners of different disciplines. This includes studies and reviews conducted by multidisciplinary teams as well as research which evaluates the results or conduct of such teams or healthcare processes in general. The journal covers a very wide range of areas and welcomes submissions from practitioners at all levels, from all over the world. The manuscript management system is completely online and includes a very quick and fair peer-review system. Visit <http://www.dovepress.com/testimonials.php> to read real quotes from published authors.

Submit your manuscript here: <https://www.dovepress.com/journal-of-multidisciplinary-healthcare-journal>