

Dabigatran Toxicity in Acute Kidney Injury: Hemodialysis and Idarucizumab Required



Lucy McBride¹, Julie Wang², Prahlad Ho^{2,3,4} and David Langsford^{1,3}

¹Department of Nephrology, Northern Health, Epping, Melbourne, Victoria, Australia; ²Department of Hematology, Northern Health, Epping, Melbourne, Victoria, Australia; ³Faculty of Medicine, Dentistry and Health Sciences, University of Melbourne, Parkville, Melbourne, Victoria, Australia; and ⁴Australian Centre of Blood Disease, Faculty of Medicine, Nursing and Health Sciences, Monash University, Melbourne, Victoria, Australia

Correspondence: David Langsford, Department of Nephrology, Northern Health, 185 Cooper Street, Epping 3076, Victoria, Australia. E-mail: David.Langsford@nh.org.au

Kidney Int Rep (2019) **4**, 500–504; <https://doi.org/10.1016/j.ekir.2018.11.015>

© 2018 International Society of Nephrology. Published by Elsevier Inc. This is an open access article under the CC BY-NC-ND license (<http://creativecommons.org/licenses/by-nc-nd/4.0/>).

INTRODUCTION

Dabigatran is a direct thrombin inhibitor, the sole agent of its class. It is an effective anticoagulant¹ with a specific antidote, idarucizumab.² It is, however, renally cleared such that should patients prescribed dabigatran develop an acute kidney injury (AKI), a coagulopathic state can be anticipated. We describe a multimodal approach involving the use of hemodialysis and 3 doses of idarucizumab to manage coagulopathy and major hemorrhage in a patient prescribed dabigatran with severe AKI. We also illustrate that dabigatran can be implicated as a cause of acute interstitial nephritis.

CASE PRESENTATION

A 71-year-old man presented to the emergency department with lethargy, anorexia, acute abdominal pain, and melena on the background of having commenced dabigatran for stroke prophylaxis 6 weeks prior. On presentation, his blood pressure was 100/65 mm Hg and heart rate 104 beats per minute with atrial fibrillation. His urine output was 30 ml per hour. His examination revealed mild diffuse abdominal tenderness and melena. Laboratory investigations on presentation demonstrated severe AKI (creatinine 16 mg/dl, urea 434.5 mg/dl), anemia (hemoglobin 7.8 g/dl) and coagulopathy (international normalized ratio 8.7, full coagulation profile not available). Autoimmune and vasculitis screens detected no abnormalities (Table 1).

His comorbidities were significant for atrial fibrillation, hypertension, and ischemic cerebrovascular accident 6 weeks prior, which had occurred in the context of warfarin nonadherence (international normalized ratio 1.3 at time of the cerebrovascular accident). At that time, dabigatran 150 mg twice a day and

metoprolol 12.5 mg twice a day had been commenced in addition to preexisting telmisartan 40 mg daily and atorvastatin 80 mg daily. Before commencing dabigatran, his renal function was normal (creatinine 0.7 mg/dl, see Table 1).

On re-presentation with anemia and melena, a decision was taken to reverse the dabigatran. Dabigatran was ceased and 2 doses of idarucizumab 2.5 g 15 minutes apart were administered in conjunction with 2 units of packed red blood cells. However, by 18 hours post idarucizumab, rebound coagulopathy was evident (activated partial thromboplastin time 89.7 seconds, thrombin time >60 seconds, see Figure 1) and hemoglobin had fallen (7.3 g/dl). At 24 hours after the first administration of idarucizumab, a further 2 doses of idarucizumab i.v. 2.5 g 15 minutes apart were administered, resulting in correction of coagulopathy (activated partial thromboplastin time 30.1 seconds, thrombin time 17.5 seconds 1 hour after idarucizumab administration). At this time, a right jugular temporary dialysis line was inserted.

The dual need to manage the patient's AKI and the recognition of the requirement to facilitate dabigatran clearance prompted the initiation of daily hemodialysis. Initially, because of a high risk of disequilibrium syndrome, hemodialysis was performed for 2 hours with a blood flow rate of 160 ml per hour with a high flux and medium surface area dialysis membrane. Within 30 minutes of commencement of hemodialysis, hypotension, tachycardia, and an acute decline in hemoglobin to 6.4 g/dl occurred. In response, i.v. fluid, packed red blood cells, and a further 2 doses of idarucizumab 2.5 g were administered (Figure 1). Coagulation profile and dabigatran levels were not taken immediately before or after the third idarucizumab administration; however, tests taken 12 hours later

Table 1. Initial investigations, at time of commencement of dabigatran (week 0), at time of re-presentation (week 6)

Parameter (normal range, units)	Week 0	Week 6
Sodium (135–145 mmol/l)	134	131
Potassium (3.5–5.2 mmol/l)	4.3	5.8
Bicarbonate (22–32 mmol/l)	26	13
Urea (3.0 – 10.0 mmol/l) (mg/dl)	5.4 (32.5)	72.2 (434.9)
Creatinine (60 – 110 µmol/l) (mg/dl)	61 (0.7)	1414 (16)
Phosphate (0.75–1.50 mmol/l)	0.91	1.66
Albumin (35–50 g/l)	28	21
Hemoglobin (130–180 g/l) (g/dl)	140 (14)	78 (7.8)
Platelets (150–450 × 10 ⁹ /l)	278	264
International normalized ratio	1.3	8.7
aPTT (seconds)	25.1	Not available
CK (<201 U/l)		658
Troponin I (<0.05 µg/l)		0.04
Serum protein electrophoresis		Polyclonal increase in IgA Mild increase in alpha 1 globulins
Kappa/Lambda ratio (0.26–1.65)		1.58
ANA (<160)		1:160 speckled
C-ANCA		Negative
P-ANCA		Negative
Ds-DNA (<10)		<10
Extractable nuclear antigen		Negative
Anti-Sjogren syndrome A (Ro) Ab		
Anti-Sjogren syndrome B (La) Ab		
Anti-ribonucleoprotein Ab		
Anti-Smith Ab		
Anti-scleroderma Ab		
Anti-Jo-1 Ab		
Anti-PCNA Ab		
Anti-ribosomal P Ab		
Anti-polymyositis/scleroderma Ab		
RhF (<14 IU/ml)		33
Anti-GBM Ab		Negative
HBV sAg, sAb, cAb		Not detected
HCV Ab		Not detected
HIV Ag/Ab		Not detected
Urine PCR (<21 mg/mmol)		216
Renal tract CT		No evidence of renal tract obstruction

Ab, antibodies; Ag, antigen; ANA, antinuclear antibodies; aPTT, activated partial thromboplastin time; C-ANCA, cytoplasmic antineutrophil cytoplasmic antibodies; CT, computed tomography; Ds-DNA, double-stranded DNA; GBM, glomerular basement membrane; HBV, hepatitis B virus; HCV, hepatitis C virus; P-ANCA, perinuclear antineutrophil cytoplasmic antibodies; PCR, protein:creatinine ratio.

(activated partial thromboplastin time 32.2 seconds, thrombin time >60 seconds, dabigatran level 110 ng/ml) were lower than those taken 5 hours before the third idarucizumab dose (activated partial thromboplastin time 45.7 seconds, thrombin time >60 seconds, dabigatran level 191.5 ng/ml), strongly suggesting that such tests were considerably higher at the time of commencement of hemodialysis.

Further rebound elevations in dabigatran levels were observed (Figure 1) even after the third dose of idarucizumab. Despite this, further idarucizumab was not given, as there was an absence of evidence of bleeding.

Instead, clearance of dabigatran was achieved by rapidly increasing the efficiency of hemodialysis (increasing blood flow and large surface area dialysis membrane), as well as the institution of daily hemodialysis, which continued for 14 days until dabigatran had been successfully cleared. During this time, the patient became oligo-anuric and subsequently required ongoing thrice-weekly hemodialysis for his AKI.

A renal biopsy was performed on day 14 that demonstrated an acute interstitial inflammatory infiltrate containing eosinophils and diffuse tubular injury consistent with severe tubulo-interstitial nephritis secondary to a drug reaction (Figure 2). A comprehensive review of the patient's drug exposures did not reveal any previously recognized cause of acute interstitial nephritis (AIN). He was treated with prednisolone and warfarin was reinstated. Six weeks later, estimated glomerular filtration rate was 20 ml/min per 1.73 m² (creatinine 252 µmol/l, 2.9 mg/dl), and hemodialysis was withdrawn.

DISCUSSION

We present the first detailed report of a patient with dabigatran toxicity and severe AKI with major bleeding who received 3 doses of idarucizumab within 48 hours in combination with daily hemodialysis to reverse dabigatran-induced coagulopathy. To our knowledge, this is also the first report of biopsy-proven dabigatran-induced AIN.

The use of dabigatran is generally avoided in those with significant renal impairment. However, AKI is common, and with increasing prescription of dabigatran, the clinical situation of dabigatran toxicity secondary to AKI (of any etiology) will be increasingly encountered.

Recommended idarucizumab dosing has been based on the dose required to reverse the 99th centile drug concentration of dabigatran measured in the Randomized Evaluation of Long-Term Anticoagulant Therapy with Dabigatran Etxilate (RE-LY trial).¹ This was observed to be 745 ng/ml for those taking 110 mg and 1000 ng/ml for 150 mg.³ Importantly, RE-LY excluded those with creatinine clearance less than 30 ml/min. As dabigatran is primarily renally cleared, impaired elimination of dabigatran is predictable in severe AKI. This will likely result in dabigatran levels that exceed those encountered in the RE-LY trial and thus the recommended dose of idarucizumab will be insufficient. Evidence of this is seen in the rebound elevations of dabigatran levels that have been observed after idarucizumab administration in case reports,^{4–8} which led to recurrent bleeding and/or death in these patients. Rebound in dabigatran levels was also recognized in

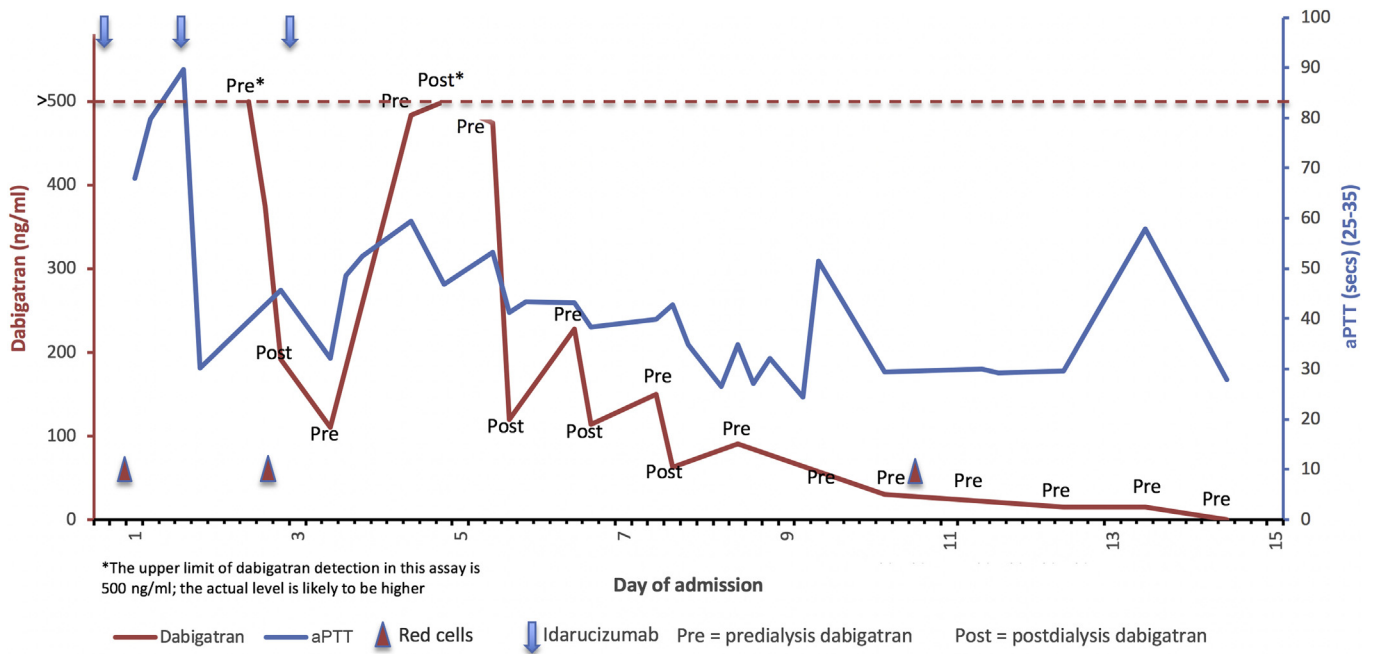


Figure 1. Graph demonstrating dabigatran levels and activated partial thromboplastin time over the course of our patient’s admission, in relation to key events, including idarucizumab doses, hemodialysis (pre- and postlevels) and red blood cell transfusion. sec, seconds.

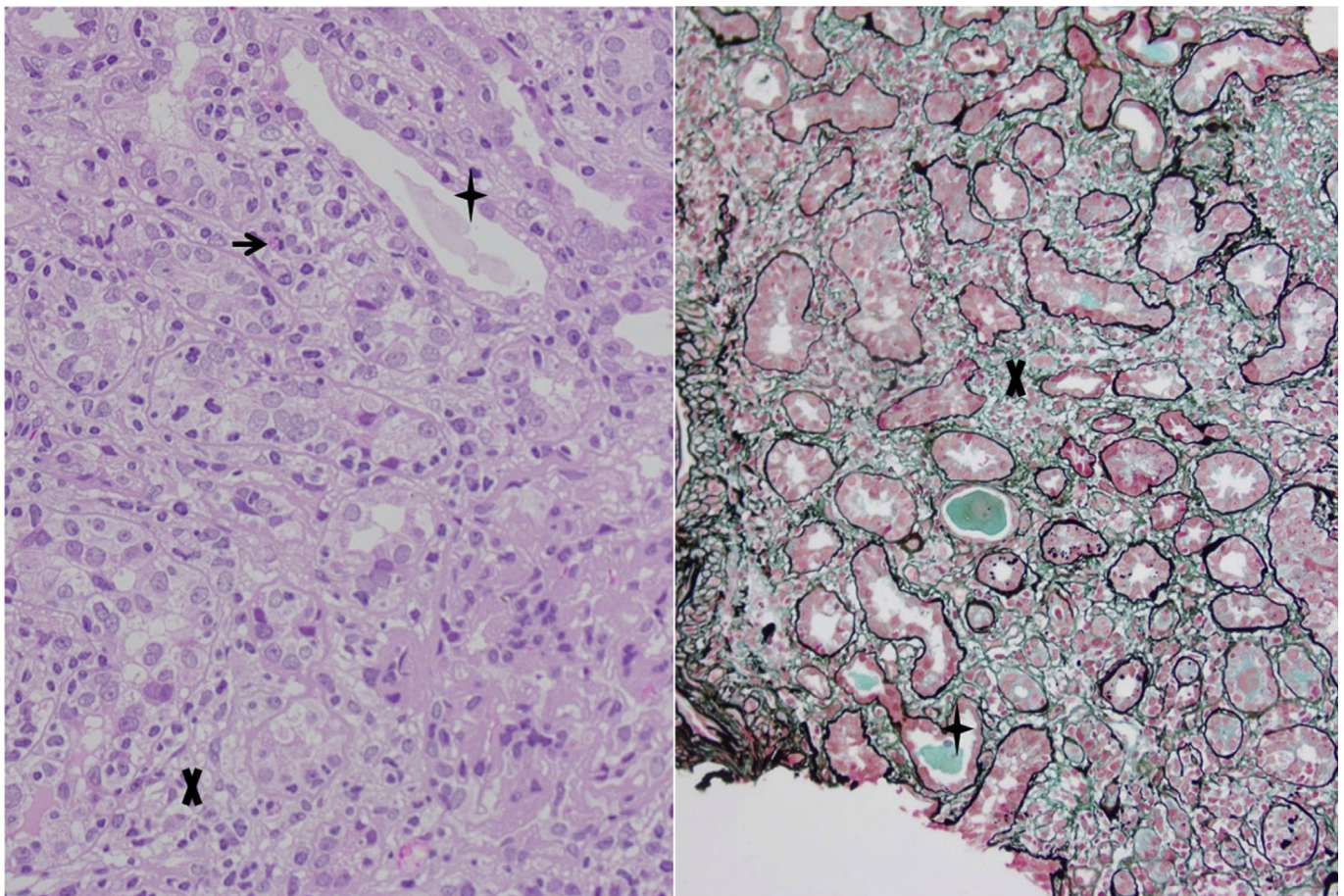


Figure 2. Renal biopsy. Hematoxylin-eosin stain (original magnification $\times 400$) and Silver Masson stain (original magnification $\times 200$) demonstrating interstitial infiltration of mononuclear cells and eosinophils (example at arrowhead) interstitial edema (example at X) and tubular epithelial injury (example at star).

Table 2. Key teaching points

Dabigatran is primarily renally cleared and impaired elimination of dabigatran is predictable in severe acute kidney injury (AKI).
The recommended dose of idarucizumab will likely be insufficient in this setting.
When dabigatran reversal is required in the context of severe AKI, rebound coagulopathy should be anticipated, and clinicians ought to be prepared to administer further doses of idarucizumab.
If severe AKI does not promptly resolve and need to improve coagulation persists, clinicians should consider the early initiation of frequent hemodialysis to facilitate dabigatran clearance.
Acute interstitial nephritis is a potential complication of dabigatran therapy.

the Idarucizumab for Dabigatran Reversal (REVERSE-AD) cohort²; however, levels remained relatively low (90% of patients less than 75 ng/ml at 24 hours), and only 3 patients were administered a second dose of idarucizumab.

Rebound in dabigatran levels occurs due to redistribution of dabigatran from the extravascular space, as occurs with agents with a volume of distribution of greater than 1 l/kg. The volume of distribution of dabigatran is 0.7–1.0 l/kg; however, in the terminal phase, its volume of distribution is 2.4 to 26.6 l/kg.⁹ Idarucizumab, as an antibody fragment, is restricted to the vascular space. It irreversibly binds serum dabigatran, reversing coagulopathy, but cannot bind dabigatran beyond the vasculature. Serum dabigatran levels rebound as it diffuses from extravascular to vascular space. As the time taken for dabigatran to redistribute can exceed the half-life of idarucizumab or simply overwhelm idarucizumab due to inadequate dosing, rebound coagulopathy occurs. Others^{8,10} have described this phenomenon in the setting of AKI, and it has been suggested that repeat coagulation assays should be obtained within 6 to 8 hours, anticipating that further idarucizumab will be required. Currently, an additional 5 g of idarucizumab is recommended by the manufacturer if there is reappearance of clinically relevant bleeding and elevated coagulation parameters or need for an urgent procedure/surgery.¹¹

As in our case and others,⁷ 2 idarucizumab doses may still be inadequate in the setting of severe AKI, and further doses may be considered. It is not known if adverse events, such as tachyphylaxis or production of negating antibodies, occur following repeated doses of idarucizumab. Low levels of antibodies have been detected in the REVERSE-AD cohort, although these were not associated with reduced function or hypersensitivity reactions.² In our patient, we demonstrated that the third dose of idarucizumab was effective in reducing dabigatran level and no adverse events were noted.

Even in the era of idarucizumab, the early institution of hemodialysis also should be considered to facilitate dabigatran clearance in the setting of severe AKI. This is particularly the case in patients in whom

prompt resolution of AKI is not anticipated, and thus more than a single dose of idarucizumab may be required if a high bleeding risk persists. Dabigatran is a small dialyzable molecule with a molecular weight of 471.5 Daltons. Pre- and post-hemodialysis levels in our patient (see Figure 1) demonstrate the efficiency of hemodialysis clearance, as has been documented by others in the pre-idarucizumab era.^{9,12,13}

To our knowledge, this is the first description of biopsy-proven AIN secondary to dabigatran, which is the only agent of its class of direct thrombin inhibitor. Although causal links cannot be absolutely proven in AIN, biopsy findings were strongly correlative with a drug reaction. Dabigatran and metoprolol were the only medications commenced before the onset of AKI, and, despite their extensive use, beta-blocker agents have not been associated with AIN.¹⁴ One other report exists of dabigatran-associated AKI; however, renal biopsy was not performed in this case.¹⁵ With regard to other novel anticoagulants, 2 factor Xa inhibitors, apixaban^{16,17} and rivaroxaban,¹⁸ have been associated with biopsy-proven AIN. Dabigatran-induced interstitial nephritis should be considered as a potential rare, serious but treatable complication in patients taking dabigatran who present with AKI.

The key learning points from this case are outlined in Table 2. This case was managed in real time, and as such some tests (including dabigatran levels) were not performed in a timely manner. Within these limitations, we describe the safe administration of 3 doses of idarucizumab combined with early institution of daily hemodialysis to clear total body dabigatran and restore hemostasis in a patient with major bleeding and severe AKI secondary to AIN from dabigatran exposure.

DISCLOSURE

All the authors declared no competing interests.

ACKNOWLEDGMENTS

We thank Dr. Anthony Landgren, Pathologist, Director of Anatomical Pathology, Royal Melbourne Hospital, for supplying photographs of histology slides.

AUTHORSHIP

All authors were directly involved with patient care, paper concept, and design of paper. L McBride and J Wang (joint first authors) wrote the paper. All authors were involved in drafting of paper and approval of final draft.

REFERENCES

1. Connolly SJ, Ezekowitz MD, Yusuf S, et al. Dabigatran versus warfarin in patients with atrial fibrillation. *N Engl J Med.* 2009;361:1139–1151.

2. Pollack CV Jr, Reilly PA, van Ryn J, et al. Idarucizumab for dabigatran reversal—full cohort analysis. *N Engl J Med*. 2017;377:431–441.
3. Reilly PA, Lehr T, Haertter S, et al. The effect of dabigatran plasma concentrations and patient characteristics on the frequency of ischemic stroke and major bleeding in atrial fibrillation patients: the RE-LY Trial (Randomized Evaluation of Long-Term Anticoagulation Therapy). *J Am Coll Cardiol*. 2014;63:321–328.
4. Thorborg C, Horn EP, Mofid H, Langer F. Reversal by the specific antidote, idarucizumab, of elevated dabigatran exposure in a patient with rectal perforation and paralytic ileus. *Br J Anaesth*. 2016;117:407–409.
5. Simon A, Domanovits H, Ay C, et al. The recommended dose of idarucizumab may not always be sufficient for sustained reversal of dabigatran. *J Thromb Haemost*. 2017;15:1317–1321.
6. Rottenstreich A, Jahshan N, Avraham L, Kalish Y. Idarucizumab for dabigatran reversal—Does one dose fit all? *Thromb Res*. 2016;146:103–104.
7. Steele AP, Lee JA, Dager WE. Incomplete dabigatran reversal with idarucizumab. *Clin Toxicol (Phila)*. 2018;56:216–218.
8. Novak JE, Alamiri K, Yee J. Dabigatran reversal in a patient with end-stage liver disease and acute kidney injury. *Am J Kidney Dis*. 2018;71:137–141.
9. Awad NI, Brunetti L, Juurlink DN. Enhanced elimination of dabigatran through extracorporeal methods. *J Med Toxicol*. 2015;11:85–95.
10. Yip L, Deng JF. Idarucizumab dosing in kidney failure. *Am J Kidney Dis*. 2018;71:146.
11. Praxbind [product monograph]. Burlington, Ontario, Canada: Boehringer Ingelheim Pharmaceuticals, Inc.; 2015 (Dec).
12. Getta B, Muller N, Motum P, et al. Intermittent haemodialysis and continuous veno-venous dialysis are effective in mitigating major bleeding due to dabigatran. *Br J Haematol*. 2015;169:603–604.
13. Chang D, Dager WE, Chin AI. Removal of dabigatran by hemodialysis. *Am J Kidney Dis*. 2013;61:487–489.
14. Nast CC. Medication-induced interstitial nephritis in the 21st century. *Adv Chronic Kidney Dis*. 2017;24:72–79.
15. Basetty P, Bellovitch K. A cautionary tale: dabigatran toxicity associated with allergic interstitial nephritis. *Am J Kidney Dis*. 2013;61:B24.
16. Brodsky SV, Mhaskar NS, Thiruveedi S, et al. Acute kidney injury aggravated by treatment initiation with apixaban: another twist of anticoagulant-related nephropathy. *Kidney Res Clin Pract*. 2017;36:387–392.
17. Abdulhadi B, Mulki R, Goyal A, Rangaswami J. Novel oral anticoagulant and kidney injury: apixaban-related acute interstitial nephritis. *BMJ Case Rep*. 2017;2017:bcr-2017-bcr-221641.
18. Monahan RC, Suttorp MM, Gabreels B. A case of rivaroxaban-associated acute tubulointerstitial nephritis. *Neth J Med*. 2017;75:169–171.