

CASE REPORT

Primary rectal diffuse large B-cell lymphoma associated with ulcerative colitis: a case report

Kazuhiro Hiyama¹, Hideo Terashima², Yoritaka Nakano¹, Masahiro Kamiga¹, Kyoichi Harada³, Hisashi Horiguchi⁴ & Takashi Mamiya²

¹Department of Surgery, Hitachi Ltd. Hitachinaka General Hospital, Hitachinaka, Ibaraki, Japan

²Hitachinaka Medical Education and Research Center, University of Tsukuba Hospital, Hitachinaka, Ibaraki, Japan

³Department of Hematology, Hitachi Ltd. Hitachinaka General Hospital, Hitachinaka, Ibaraki, Japan

⁴Department of Pathology, Hitachi Ltd. Hitachinaka General Hospital, Hitachinaka, Ibaraki, Japan

Correspondence

Hideo Terashima, 20-1 Ishikawa-cho, Hitachinaka, Ibaraki, Japan.

Tel: +81-29-354-5111;

Fax: +81-29-354-6842;

E-mail: h-tera@md.tsukuba.ac.jp

Funding Information

No funding information provided.

Received: 19 August 2014; Revised: 19 October 2014; Accepted: 25 October 2014

Clinical Case Reports 2015; 3(3): 150–155

doi: 10.1002/ccr3.185

Key Clinical Message

We need to be aware of primary intestinal lymphoproliferative disease (PILD) associated with ulcerative colitis (UC). We should carefully monitor UC patients, particularly patients who meet the following conditions; a previous Epstein-Barr virus infection, treatment duration ≥ 4 years, male, and age ≥ 50 years.

Keywords

Azathioprine, Epstein-Barr virus, lymphoproliferative disease, ulcerative colitis.

Introduction

There are three main types of drugs that are commonly used to treat ulcerative colitis (UC): aminosalicylates, corticosteroids, and immunosuppressants [1, 2]. All drugs can have unwanted side effects, but some adverse effects gain little attention in spite of their severity. One such complication is primary intestinal lymphoproliferative disease (PILD), which can develop during the treatment of UC, especially in cases in which the patients are treated with immunosuppressants [1]. Although UC itself is not considered to be a risk factor for PILD, UC patients that are treated with thiopurines are considered to be at a significantly high risk of PILD [1, 3–5]. This case raises issues concerning what we should deal with the risk for UC treatment-associated PILD.

Case History/Examination

A 69-year-old male had suffered from progressively worsening pain and swelling in his right buttock for 1 month. The patient had been diagnosed with distal (left-sided)

UC three and a half years ago (Fig. 1). Since then, his UC had become more extensive over time, resulting in total colitis requiring triple-drug combination therapy involving prednisolone (PSL), mesalazine (5-ASA), and azathioprine (AZA). At this visit, he had been taking 7.5 mg PSL, 2 g 5-ASA, and 50 mg AZA daily. The cumulative dose of PSL and AZA had reached 11,693.5 and 37,250 mg respectively. On inspection, the swelling and redness affecting his right buttock indicated the presence of strong inflammation.

Other than the abovementioned conditions, there was nothing in the patient's medical, social, or family history that deserves special mention.

Blood tests revealed a total white blood cell count of 9100/ μL and a mildly elevated C-reactive protein level of 10.24 mg/dL.

A contrast-enhanced computed tomography scan detected partial defects in the rectal wall and a mixture of gas bubbles and liquid that had spread from the tissues surrounding the rectum to the subcutaneous tissue, which were suggestive of necrotizing proctitis and the presence of a severe perirectal abscess (Fig. 2).

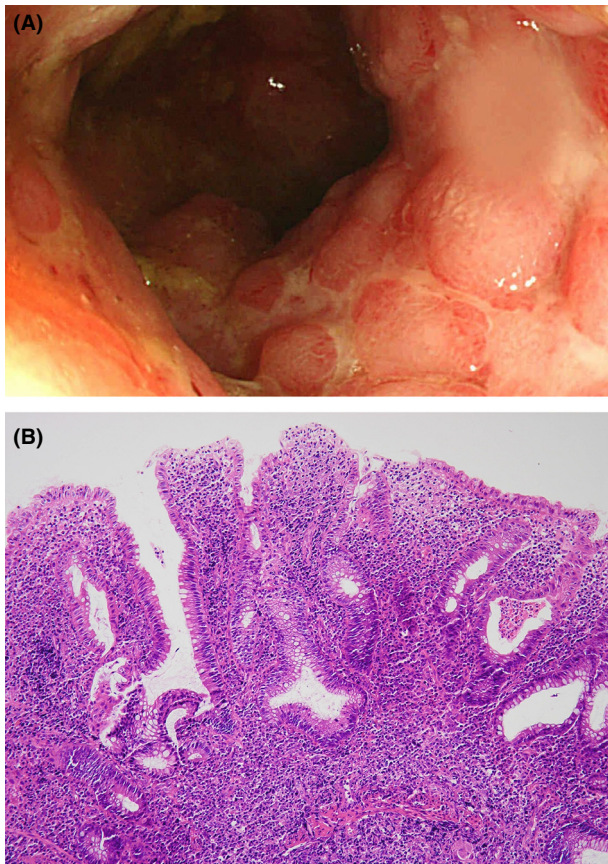


Figure 1. (A) Colonoscopy performed before admission showed the mucosal destruction (pseudopolyps) mainly in the sigmoid colon. (B) The biopsy specimen obtained from the sigmoid colon as the onset of ulcerative colitis (UC) shows cryptic distortion and branching, and dense lymphoplasmacytic with basal plasmacytosis (hematoxylin-eosin staining).

Differential Diagnosis, Investigations, and Treatment

It comes down to whether UC had a causal role in the development of necrotizing proctitis with severe perirectal abscess; for example, fistula formation or perforated rectal cancer secondary to UC. Other causes included a variety of infectious proctitis with a more fulminant course, perforation of the rectal cancer unrelated to UC, and so on.

Immediately, the patient underwent emergency surgery including removal of abscess with necrotic tissue, drainage, and ileostomy. In addition to systemic administration of doripenem hydrate, the wound left open was managed by wound cleansing with the use of normal saline squeeze bottles two times daily.

Outcome and Follow-Up

Daily wound cleansing and the systemic administration of antibiotics based on antimicrobial susceptibility testing

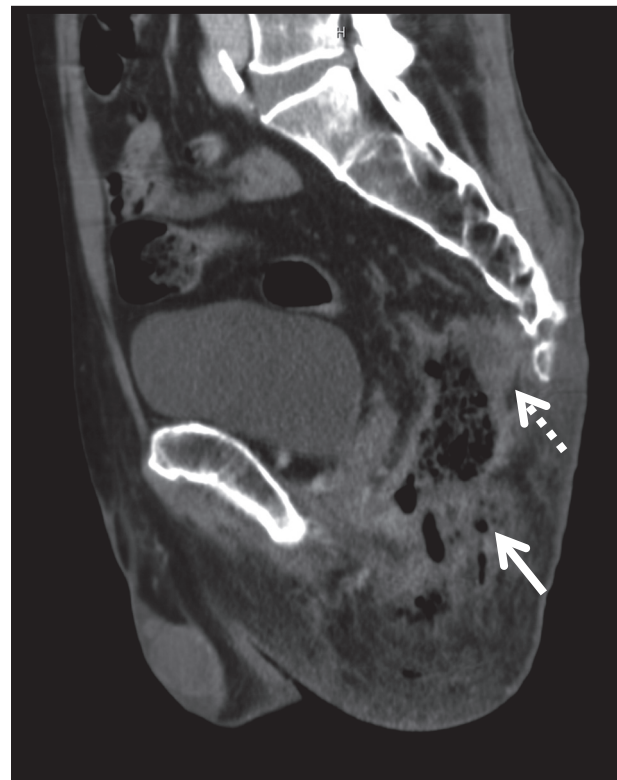


Figure 2. A contrast-enhanced computed tomography scan performed on admission detected partial defects in the rectal wall and a mixture of gas bubbles (white arrow) and liquid, which had spread from the tissue surrounding the rectum to the subcutaneous tissue, which were suggestive of necrotizing proctitis and the presence of a severe perirectal abscess (dotted white arrow).

was continued for about 1 month, but the pelvic infection remained poorly controlled. We considered that the underlying cause of the infection was the long-term administration of corticosteroids and immunosuppressants and that the residual necrotic tissue had become a breeding ground for bacteria. On day 42 after the emergent surgery, the patient underwent laparoscopy-assisted total colectomy and the removal of the necrotic tissue followed by omentopexy with the aim of controlling the infection and promoting wound healing in the pelvic cavity.

A routine histopathological examination of the surgical specimen (Fig. 3A) confirmed that the UC extended to the entire colon (Fig. 3B), and surprisingly revealed the existence of malignant lymphoma in the rectal ulcer. A further detailed examination identified Epstein-Barr virus-positive diffuse large B-cell lymphoma (EBV-positive DLBCL) in the rectum (Fig. 3C). Imaging studies and a bone marrow biopsy were performed, which did not find any evidence of pathological lymphadenopathy or bone marrow infiltration. Therefore, we clinically diagnosed the

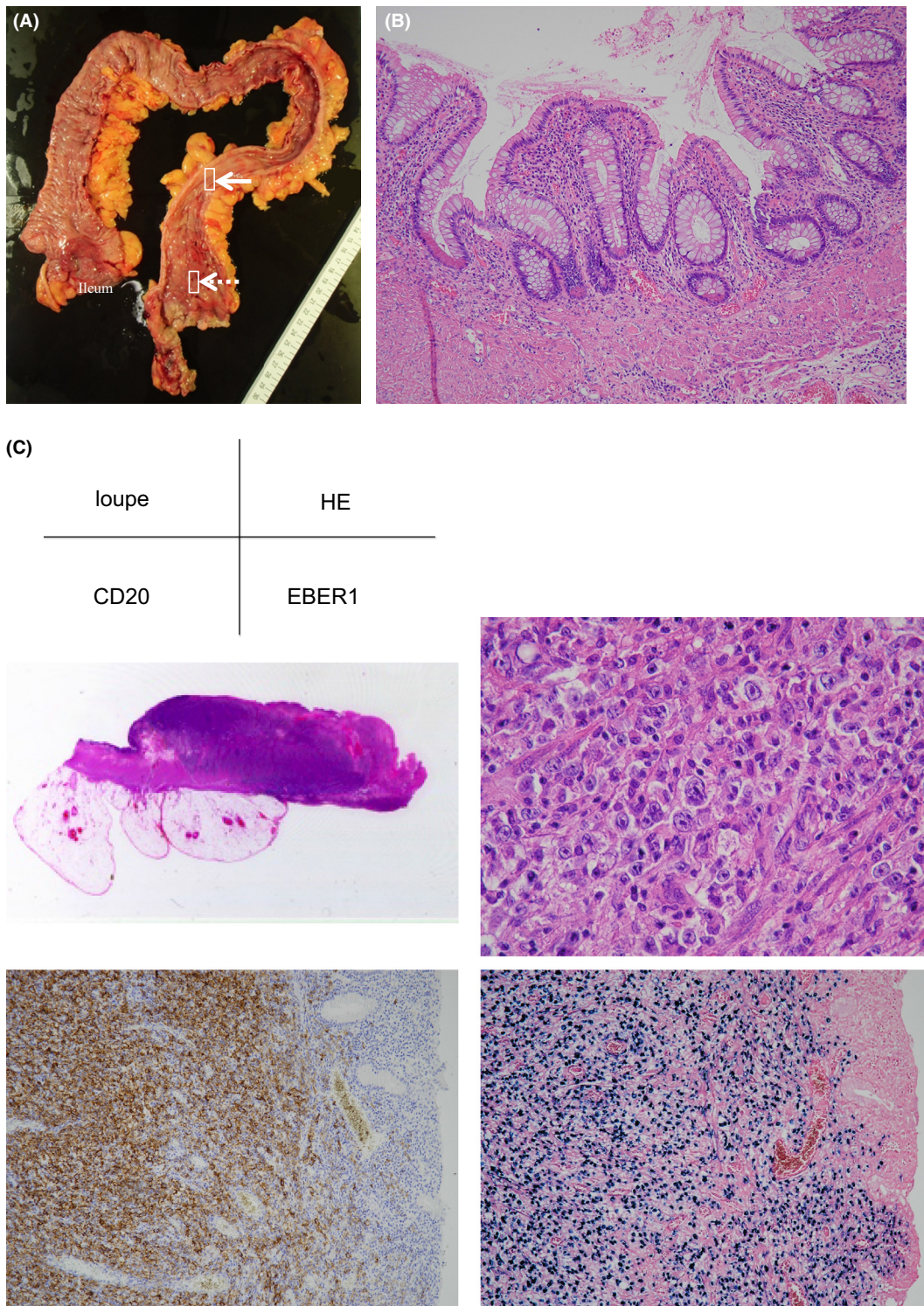


Figure 3. (A) Total colectectomy specimen. The white arrow indicates the site from where the colonic tissue slices that were subjected to the histopathological examination shown in (B) were obtained. The dotted white arrow indicates the site from where the rectal tissue slices that were subjected to the histopathological examination shown in (C) were obtained. (B) The sigmoid colon mucosa apart from the ulcer shows marked cryptic distortion with Paneth cell metaplasia, thickening of lamina muscularis mucosae, and relatively mild lymphocytic infiltration (compared to Fig. 1B); findings are consistent with ulcerative colitis in chronic phase. (C) Histologic section of the rectal ulcer demonstrates that there is dense cellular aggregation in the ulcer edge. High-power view shows that large tumor cells possess irregular-shaped nuclei and scant cytoplasm. Some nuclei are very large and contain prominent nucleoli, mimicking Hodgkin cells. Immunohistochemically, the tumor cells express CD20, and in situ hybridization analysis reveals their expression of Epstein-Barr virus encoded RNAs (EBERs).

patient with EBV-positive DLBCL arising from the rectum and considered that this condition represented a form of UC associated PILD.

As the infected wound failed to improve despite the withdrawal of PSL and AZA, a second attempt to remove the abscess and necrotic tissue followed by drainage was conducted on day 81 after admission. A histopathological examination of the granulation tissue surrounding the necrotic tissue demonstrated proliferating and infiltrating EBV-positive DLBCL cells (Fig. 4), indicating that the malignant lymphoma had relapsed locally and that it might have played a role in prolonging the patient's infection.

As the DLBCL had to be treated in order to treat the infected wound, we started chemotherapy with the R-THP-CVP regimen (rituximab, theraurubicin, cyclophosphamide, vindesine, and prednisolone) on day 96 after admission [6, 7]. However, the first course of chemotherapy had no effect. The patient became increasingly ill; in

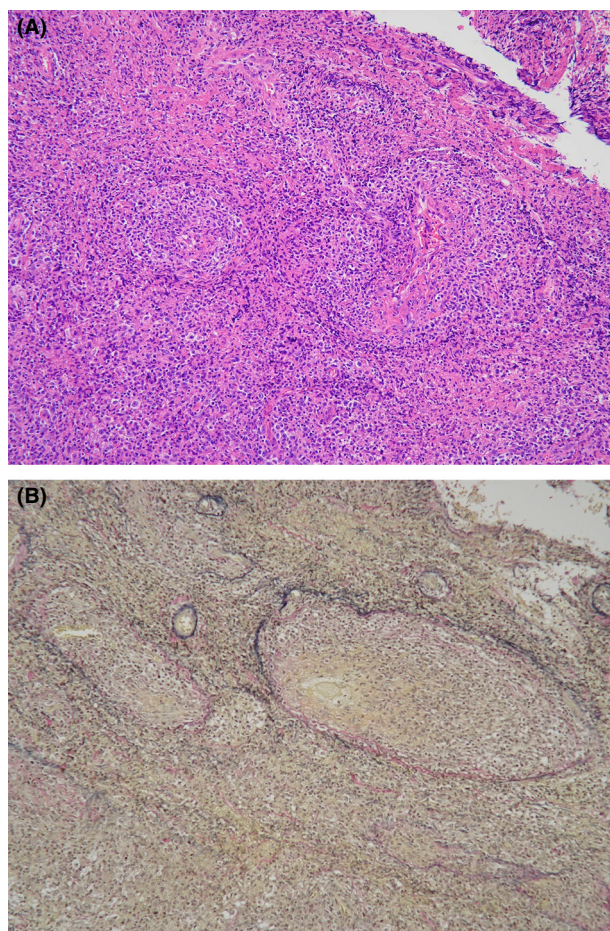


Figure 4. (A) Lymphoma cells diffusely infiltrate the granulation tissue obtained during the second debridement. (B) Elastic van Gieson staining reveals their angiocentric feature.

particular, urinary incontinence and lower limb dysesthesia developed and eventually a mixture of urine and digestive juices drained through the original wound, which was suggestive of extended tissue destruction due to the progression of both the malignant lymphoma and wound infection. The patient died of disseminated intravascular coagulation syndrome secondary to sepsis on day 144 after admission.

Discussion

We experienced a case of primary rectal DLBCL associated with UC, which had a unique clinical course that was unlike that of common malignant lymphoma. Generally, primary gastrointestinal lymphoma decreases the mechanical strength of the gastrointestinal wall by replacing intestinal tissues as it proliferates, which is considered to be causally related to perforation [8–10]. In the present case, the use of steroids (PSL) masked the inflammatory response that would have been induced when the patient suffered a rectal perforation, which led to a delay in the patient seeking medical care and the development of necrotizing proctitis by the time of his visit. Therefore, there was no choice but to treat the infected wounds as a large open wound, which made wound management difficult throughout the patient's clinical course. A histopathological examination of the specimen obtained during the second debridement of the open wound showed that lymphoma cells had spread to the region around the granulation tissue and had also infiltrated and occluded some blood vessels. Thus, the locally recurrent lymphoma not only had a substantially detrimental effect on wound healing, but also caused further tissue destruction in the bladder and small intestine, resulting in the leakage of urine and stool from the open wound.

In this case, three factors, persistent chronic inflammation due to UC, a previous EBV infection, and the administration of AZA might have all contributed to the pathogenesis of the patient's PILD; that is, primary rectal DLBCL. Persistent chronic inflammation might play a role in the promotion of the precursor cells of malignant lymphoma because it leads to an overstimulated immune system and the continuous proliferation of immune cells [11]. In addition, in the presence of over-activated B cells T cell dysfunction would allow the reactivation of EBV, which mostly infects B cells [11]. The newly infected and differentiating B cells would not be controlled by cytotoxic T cell responses because of the T cell dysfunction, which could lead to uncontrolled lymphoproliferation and the subsequent development of malignant lymphoma [12, 13]. However, the incidence of PILD among UC patients is relatively low; that is, less than one in 1500 patients per year, indicating that UC itself is not a signifi-

cant risk factor for PILD [14–16]. In previous reports on the causal relationship between inflammatory bowel disease and PILD, the relative risk of PILD associated with irritable bowel disease (IBD) ranged from 0.4 to 17.51, suggesting that several reports found no link between the conditions [3, 4, 16]. On the other hand, UC patients receiving thiopurines were found to exhibit markedly increased relative risks of PILD, ranging between 2.97 and 49.52. This indicates that the use of thiopurines in UC causes an increased risk of PILD [3, 5]. In addition, it has been reported that in cases of PILD occurring in UC patients receiving thiopurines more than 90% of them are EBV-positive on histopathological examination [5, 15]. From the standpoint of lymphomas, there have been growing evidence indicating a significant causal relationship between use of thiopurines and development of lymphoma [17, 18]. Especially, Khan et al. presented definite results based on a retrospective, nationwide cohort study including 4734 UC patients treated with thiopurines for a median of 1 year [17]. The age-, gender-, and race-adjusted hazard ratios of developing lymphoma were 4.2 (95% confidence interval, 2.5–6.8; $P < 0.0001$) while being treated with thiopurines, and 0.5 (95% confidence interval, 0.2–1.3; $P = 0.17$) after discontinuing treatment with thiopurines compared with unexposed patients. So, it is extremely important that discontinuing thiopurine therapy allows for reduction in the risk of lymphoma.

This case report highlights the side effects of drug therapy for UC. Once the cumulative dose of PSL exceeds 10,000 mg, serious side effects, which might be irreversible, are likely to develop [19]. Therefore, clinicians should consider surgery before the cumulative dose of oral corticosteroids reaches this threshold. In the case of thiopurines, previous studies have produced conflicting results regarding whether the cumulative dose and/or duration of AZA are associated with the development of PILD [3, 20, 21]. However, it should be noted that the magnitude of overall risk for lymphomas is significantly associated with therapy duration of 4 years as a threshold for achieving statistical significance [17, 18]. At this time, we should not overreact to the risk of PILD development and stop using thiopurines because they benefit a lot of UC patients [2], and the incidence of PILD among UC patients receiving thiopurines is quite low (less than one in 1000 patients per year) [1]. Since over 90% of adults have been infected with EBV [22], it is not feasible to decide whether the use of thiopurines is safe after testing for the presence or absence of EBV. Instead, the most practical approach is to monitor UC patients who are taking thiopurines whilst paying careful attention to the risk of PILD. In terms of overall risk for lymphomas, the characteristics of patients requiring special care are as follows; treatment duration for more than 4 years, male

gender, and age older than 50 or 65 years [17, 18]. On the other hand, a trial of withdrawal of thiopurine therapy after 3 years may be another option, considering the results reported by Khan et al. [17].

The outcome of and optimal treatment for UC-associated PILD are disputed [15, 20, 21, 23, 24] because insufficient information is available about the condition due to the limited number of case reports [20]. Therefore, further collection and follow-up of reported cases are needed to clarify the characteristics of PILD secondary to UC.

Conflict of Interest

None declared.

References

- Danese, S., and C. Fiocchi. 2011. Ulcerative colitis. *N. Engl. J. Med.* 365:1713–1725.
- Ford, A. C., P. Moayyedi, and S. B. Hanauer. 2013. Ulcerative colitis. *BMJ* 346:f432–2.
- Beaugerie, L., N. Brousse, A. M. Bouvier, J. F. Colombel, M. Lémann, J. Cosnes, et al. 2009. Lymphoproliferative disorders in patients receiving thiopurines for inflammatory bowel disease: a prospective observational cohort study. *Lancet* 374:1617–1625.
- Sokol, H., L. Beaugerie, M. Maynadié, D. Laharie, J.-L. Dupas, B. Flourié, et al. 2012. Excess primary intestinal lymphoproliferative disorders in patients with inflammatory bowel disease. *Inflamm. Bowel Dis.* 18:2063–2071.
- Vos, A. C. W., N. Bakkal, R. C. Minnee, M. K. Casparie, D. J. de Jong, G. Dijkstra, et al. 2011. Risk of malignant lymphoma in patients with inflammatory bowel diseases: a Dutch nationwide study. *Inflamm. Bowel Dis.* 17:1837–1845.
- Kitamura, K., and F. Takaku. 1990. Pirarubicin, a novel derivative of doxorubicin. THP-COP therapy for non-Hodgkin's lymphoma in the elderly. *Am. J. Clin. Oncol.* 13 (Suppl. 1):S15–S19.
- Mitsuhashi, S., H. Ninomiya, A. Shibuya, H. Kojima, T. Nagasawa, A. Ohsaka, et al. 1993. Effect of THP-CVP regimen for elderly patients with malignant lymphoma. *Rinsho Ketsueki* 34:1532–1539.
- Vaidya, R., T. M. Habermann, J. H. Donohue, K. M. Ristow, M. J. Maurer, W. R. Macon, et al. 2013. Bowel perforation in intestinal lymphoma: incidence and clinical features. *Ann. Oncol.* 24:2439–2443.
- Lagoutte, N., A. Doussot, U. Leung, O. Facy, J. N. Bastie, P. Rat, et al. 2014. Perforation of bowel lymphoma: beware of atypical presentations. *J. Gastrointest. Cancer* 5:1–5.
- Richards, M. A. 1986. Lymphoma of the colon and rectum. *Postgrad. Med. J.* 62:615–620.
- Copie-Bergman, C., G. Niedobitek, D. C. Mangham, J. Selves, K. Baloch, T. C. Diss, et al. 1997. Epstein-Barr

- virus in B-cell lymphomas associated with chronic suppurative inflammation. *J. Pathol.* 183:287–292.
12. Saha, A., and E. S. Robertson. 2011. Epstein-Barr virus-associated B-cell lymphomas: pathogenesis and clinical outcomes. *Clin. Cancer Res.* 17:3056–3063.
 13. Grywalska, E., J. Markowicz, P. Grabarczyk, M. Pasiarski, and J. Roliński. 2013. Epstein-Barr virus-associated lymphoproliferative disorders. *Postepy Hig. Med. Dosw. (Online)* 67:481–490.
 14. Watanabe, N., N. Sugimoto, A. Matsushita, A. Maeda, K. Nagai, K. Hanioka, et al. 2003. Association of intestinal malignant lymphoma and ulcerative colitis. *Intern. Med.* 42:1183–1187.
 15. Allen, P. B., G. Laing, A. Connolly, and C. O'Neill. 2013. EBV-associated colonic B-cell lymphoma following treatment with infliximab for IBD: a new problem? *BMJ Case Rep.* 2013:bcr2013200423–3.
 16. Collins, P. D. 2013. Strategies for detecting colon cancer and dysplasia in patients with inflammatory bowel disease. *Inflamm. Bowel Dis.* 19:860–863.
 17. Khan, N., A. M. Abbas, G. R. Lichtenstein, E. V. Loftus Jr., and L. A. Bazzano. 2013. Risk of lymphoma in patients with ulcerative colitis treated with thiopurines: a nationwide retrospective cohort study. *Gastroenterology* 145:1007–1015.e3.
 18. Beigel, F., A. Steinborn, F. Schnitzler, C. Tillack, S. Breitenicher, J. M. John, et al. 2014. Risk of malignancies in patients with inflammatory bowel disease treated with thiopurines or anti-TNF alpha antibodies. *Pharmacoepidemiol. Drug Saf.* 23:735–744.
 19. Turner, E. J. H., and S. A. Raza. 2012. Long-term steroids and an extensive diverticular abscess. *BMJ Case Rep.* 2012:bcr1020114926–6.
 20. Sultan, K., B. I. Korelitz, D. Present, S. Katz, S. Sunday, and I. Shapira. 2012. Prognosis of lymphoma in patients following treatment with 6-mercaptopurine/azathioprine for inflammatory bowel disease. *Inflamm. Bowel Dis.* 18:1855–1858.
 21. Tan, C. W., G. E. Wilson, J. M. Howat, and D. R. Shreeve. 2001. Rectal lymphoma in ulcerative colitis treated with azathioprine. *Eur. J. Gastroenterol. Hepatol.* 13:989–992.
 22. Allen, U., C. Alfieri, J. Preiksaitis, A. Humar, D. Moore, B. Tapiero, et al. 2002. Epstein-Barr virus infection in transplant recipients: summary of a workshop on surveillance, prevention and treatment. *Can. J. Infect. Dis.* 13:89–99.
 23. Shibahara, T., K. Miyazaki, D. Sato, H. Matsui, A. Yanaka, A. Nakahara, et al. 2006. Rectal malignant lymphoma complicating ulcerative colitis treated with long-term cyclosporine A. *J. Gastroenterol. Hepatol.* 21(1 Pt 2):336–338.
 24. She, W.-H., W. Day, P. Y.-Y. Lau, K.-L. Mak, and A. W.-C. Yip. 2011. Primary colorectal lymphoma: case series and literature review. *Asian J. Surg.* 34:111–114.