

Thoracic stent graft placement for repair of iatrogenic aortic injury secondary to sheath placement during pacemaker insertion

SAGE Open Medical Case Reports
Volume 6: 1–3
© The Author(s) 2018
Reprints and permissions:
sagepub.co.uk/journalsPermissions.nav
DOI: 10.1177/2050313X17753779
journals.sagepub.com/home/sco



Jared T Feyko¹, Kelsey Musgrove², Cara Lyle²
and Alexandre d'Audiffret¹

Abstract

We describe the inadvertent cannulation of the proximal descending thoracic aortic stent with a five French sheath during attempted pacemaker placement in an 88-year-old male. The injury was managed successfully by the percutaneous placement of a thoracic aortic stent graft with good outcome. Our case highlights the feasibility of managing this uncommon injury with this technique.

Keywords

Aortic, stent graft, iatrogenic injury

Date received: 17 August 2017; accepted: 19 December 2017

Introduction

Multiple randomized, controlled trials from the late 1990s to early 2000s showed safety and efficacy of endovascular repair of descending thoracic aortic aneurysms, leading to Food and Drug Administration (FDA) approval in March 2005.¹ Since that time, its use has expanded to include the treatment of traumatic and iatrogenic thoracic aortic injuries. Attempted pacemaker insertion resulting in iatrogenic aortic injury is rarely reported and challenging to manage. We describe a case of inadvertent cannulation of the thoracic aorta with a five French sheath during attempted pacemaker insertion managed by placement of a thoracic aortic stent graft.

Case details

An 88-year-old man was transferred from a referring hospital for descending thoracic aortic injury after attempted pacemaker placement; 3 days prior he was admitted with a transient ischemic attack. He had new onset atrial fibrillation and sinus bradycardia that prompted pacemaker placement. Left subclavian access was attempted after a pocket was created. After placement of a five French sheath, arterial blood return was noted. The sheath was left in place and the procedure was aborted. The patient was hemodynamically stable

and taken to computed tomography (CT) scanner for evaluation of arterial injury. The CT scan revealed direct cannulation of the aortic knob with the sheath. The patient was directly transferred by helicopter to our institution for higher level of vascular surgery care. The patient arrived intubated and sedated with the sheath in place in the left chest covered with a dressing and a left chest tube in place with 100cc of sanguinous output.

The patient was taken to the hybrid operating room in our facility. Bilateral percutaneous femoral access was obtained and a five French sheath was placed in the right common femoral artery, and initially, a seven French sheath was placed in the left common femoral artery. We placed two proglide devices in the left access in standard preclose technique as

¹Division of Vascular Surgery, West Virginia University Heart and Vascular Institute, Morgantown, WV, USA

²Department of Surgery, West Virginia University, Morgantown, WV, USA

Corresponding Author:

Jared T Feyko, Division of Vascular Surgery, West Virginia University Heart and Vascular Institute, 1 Medical Center Drive, PO Box 8500, Morgantown, WV 26506, USA.

Email: jfeyko@hsc.wvu.edu



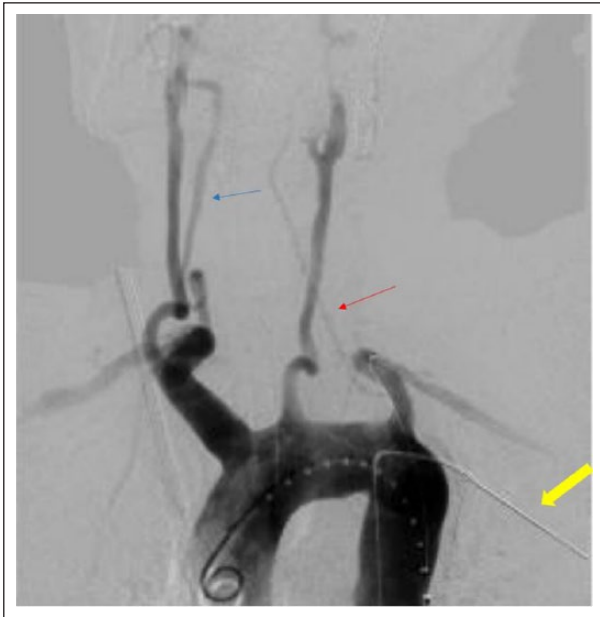

Figure 1. Pre-deployment aortogram (blue arrow: dominant right vertebral artery; red arrow: atretic left vertebral artery; yellow arrow: sheath).

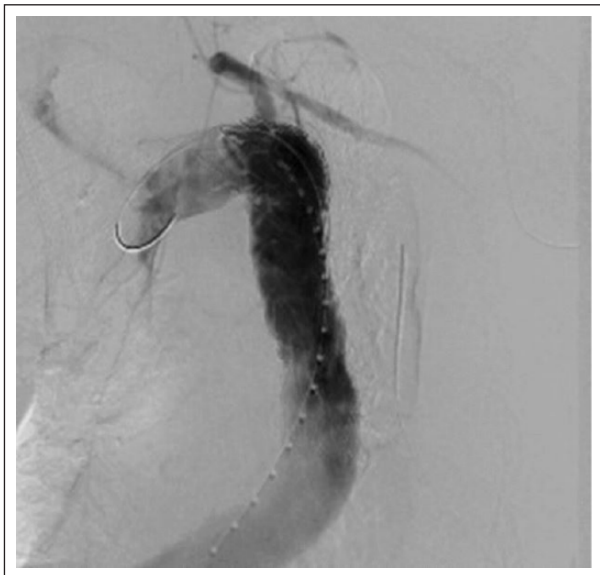


Figure 2. Post-deployment aortogram.

this was our anticipated side of device deployment. At this point, a pigtail catheter was advanced into the ascending aorta and an arch aortogram was performed which demonstrated a direct cannulation of the aortic knob (Figure 1). We elected to proceed to with stent graft placement to manage this injury as the patient's comorbidities and advanced age were prohibitive risks for open repair. Prior to the placement of an endoprosthesis, a cerebral angiogram was performed to identify cerebrovascular dominance. This demonstrated a dominant right vertebral artery and left vertebral atresia. There was

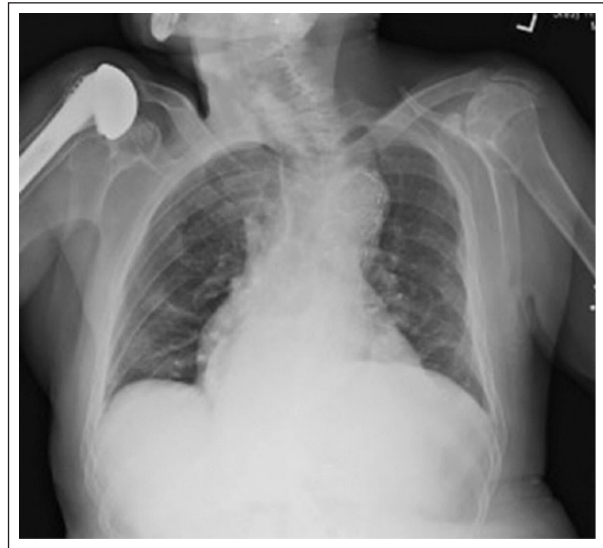


Figure 3. Post-deployment chest X-ray.

adequate distance from the site of sheath insertion to the left subclavian artery, such that we felt we could achieve a seal without covering the left subclavian artery. Based on our pre-operative measurement of our anticipated proximal and distal seal zones, the aortic diameter was 32 mm. Therefore, we selected a 36 mm × 160 mm Valiant thoracic aortic stent graft (Medtronic, Santa Rosa, CA) and advanced and deployed the device distal to the origin of the left subclavian artery. The sheath was removed from the aorta and the device was deployed simultaneously. Angioplasty was then performed with a Coda compliant balloon. Repeat arch and thoracic angiography revealed successful sealing of the injury site and no evidence of extravasation. Additionally, the left subclavian remained patent (Figure 2). We removed the 24 French sheath from the left femoral access and successfully closed the arteriotomy with the proglide devices. The right groin access was managed with direct pressure. The patient had an uneventful post-operative course. The chest tube output was minimal and serous the remainder of his hospitalization and was removed on post-operative day 4. He was discharged to home on post-operative day 5 (Figure 3).

Discussion

Thoracic endovascular aortic repair has been approved for the treatment of atherosclerotic aneurysmal disease of the thoracic aorta since 2005. Additionally, indications now include aortic transection and complicated type B aortic dissection.² Less common applications of this technology include intramural hematoma, penetrating ulcers, and embolizing “shaggy” aortas.

Iatrogenic thoracic aorta injury is a rarely reported event. Upon reviewing the literature, two case reports were found reporting thoracic aorta injury secondary to pericardiocentesis and pacemaker placement. Overall acute complications from

pacemaker placement are about 4%–5% mainly due to malpositioning of leads causing atrial or ventricular perforation resulting in cardiac tamponade. Additionally, venous access complications including hemothorax and pneumothorax have been reported.³ A similar case report by Vagefi et al. showed successful endovascular management of an iatrogenic distal descending thoracic aortic injury secondary to six French sheath placement during attempted pericardiocentesis. An AneuRx aortic cuff stent graft (Medtronic, Santa Rosa, CA) was used successfully in this instance, and the patient remained complication free for 8 years of follow-up care as of 2014.⁴

Conclusion

This case highlights the extension of a commonly used thoracic stent graft device to manage an uncommon aortic injury. Elderly and frail patients are often poor open aortic surgical candidates. We describe the successful application of a minimally invasive technique in a patient who is not a suitable candidate for open repair with an excellent clinical outcome.

Declaration of conflicting interests

The author(s) declared no potential conflicts of interest with respect to the research, authorship, and/or publication of this article.

Ethical approval

Our institution does not require ethical approval for reporting individual cases or case series.

Funding

The author(s) received no financial support for the research, authorship, and/or publication of this article.

Informed consent

Written informed consent was obtained from the patient(s) for their anonymized information to be published in this article.

References

1. Cho JS, Haider SE and Makaroun MS. Endovascular therapy of thoracic aneurysms: Gore TAG trial results. *Semin Vasc Surg* 2006; 19(1): 18–24.
2. Wang GJ and Fairman RM. Endovascular repair of the thoracic aorta. *Semin Intervent Radiol* 2009; 26(1): 17–24.
3. Tommaso LD, Monaco M, Piscione F, et al. TEVAR for iatrogenic aortic injury of the distal aortic arch after pacemaker implantation. *EJVES Extra* 2007; 26(2): e17–e19.
4. Vagefi P, Patel M and LaMuraglia G. Endovascular stent for iatrogenic penetrating injury of the thoracic aorta. *Vasc Endovasc Surg* 2014; 48(4): 333–336.