

# Fluoroscopy-guided shaped endobiliary biopsy at endoscopic retrograde cholangiography can accurately diagnose biliary neoplasia: Results from a large cohort ▶

OPEN  
ACCESS



## Authors

Bao-can Wang<sup>1,2</sup>, Kelly K. Wang<sup>1</sup>, Navin Paul<sup>3</sup>, Vijay Jayaraman<sup>4</sup>, Qiang Wang<sup>1</sup>, Yazan Abboud<sup>1</sup>, Laith H. Jamil<sup>1</sup>, Srinivas Gaddam<sup>1</sup>, Simon K. Lo<sup>1</sup>

## Institutions

- 1 Karsh Division of Gastroenterology and Hepatology, Department of Medicine, Cedars-Sinai Medical Center, Los Angeles, California, United States
- 2 Department of Gastroenterology, Xin Hua Hospital affiliated to Shanghai Jiao Tong University School of Medicine, Shanghai, China
- 3 Kaiser Permanente Fresno Medical Center, Fresno, California, United States
- 4 Comprehensive Digestive Institute of Nevada, Las Vegas, Nevada, United States

Fax: +1-310-423-1826  
Simon.Lo@cshs.org

submitted 26.7.2020

accepted after revision 15.2.2021

## Bibliography

Endosc Int Open 2021; 09: E1039–E1048

DOI 10.1055/a-1399-8031

ISSN 2364-3722

© 2021. The Author(s).

This is an open access article published by Thieme under the terms of the Creative Commons Attribution-NonDerivative-NonCommercial License, permitting copying and reproduction so long as the original work is given appropriate credit. Contents may not be used for commercial purposes, or adapted, remixed, transformed or built upon. (<https://creativecommons.org/licenses/by-nc-nd/4.0/>)

Georg Thieme Verlag KG, Rüdigerstraße 14,  
70469 Stuttgart, Germany

## Corresponding author

Simon K. Lo, MD, Karsh Division of Gastroenterology and Hepatology, Cedars-Sinai Medical Center, 8700 Beverly Blvd., Room 7707, Los Angeles, CA 90048, United States

## ABSTRACT

**Background and study aims** The sensitivity of using standard endobiliary forceps biopsy to diagnose neoplastic biliary lesions remains low. We have developed a unique biopsy approach, termed fluoroscopy-guided, shaped endobiliary biopsy (FSEB), in which the biopsy forceps are modified to improve diagnostic yield. In this study, we evaluate the diagnostic characteristics of FSEB for endobiliary lesions at endoscopic retrograde cholangiography (ERC).

**Patients and methods** Consecutive patients undergoing FSEB between 1/2001 and 12/2014 were retrospectively enrolled. The identification of neoplastic lesions with FSEB, was the primary endpoint. The gold standard of neoplasia was histopathology, cytology or surgical histopathology. The benign cases were followed up for one year.

**Results** A total of 204 patients undergoing 250 biopsy sessions by FSEB were analyzed. Per-patient analysis was performed and FSEB showed 81.1% sensitivity and 88.2% accuracy. FSEB detection of proximal biliary lesions was more sensitive (91.1% vs 73.2%,  $P < 0.01$ ) and accurate (94.9% vs 82.2%,  $P < 0.01$ ) compared to distal lesions. No complications from FSEB were reported.

**Conclusions** FSEB shows high accuracy for diagnosis of neoplasia in biliary strictures, especially for proximal lesions. Future prospective randomized controlled studies are merited to further validate the role of FSEB as the first-line sampling tool for evaluation of biliary neoplasm.

## Introduction

Biliary stricture is an abnormal narrowing of the bile duct that can result from a wide spectrum of benign causes, such as choledocholithiasis, primary sclerosing cholangitis, abdominal radiation treatment, chronic pancreatitis, traumatic or ischemic injury, and postsurgical strictures. Yet, approximately 70% of biliary strictures are neoplastic in origin, such as resulting from

cholangiocarcinoma, pancreatic cancer, gallbladder cancer, hepatocellular cancer and metastatic carcinomas [1,2]. It is important to accurately characterize the pathology of the biliary stricture because it is the basis for choosing the appropriate treatment: while endoscopic procedures may be sufficient for benign diseases, surgery is generally required for treatment of malignant diseases. However, biliary strictures frequently present a diagnostic challenge in the clinics.

To date, tissue or cytology acquisition by endoscopic retrograde cholangiography (ERC) or by endoscopic ultrasonography (EUS) remains the gold standard for diagnosis of malignant strictures [3]. These endoscopy-based methods include biopsy or brush cytology with ERC, biopsy with choledochoscopy [4] and endoscopic ultrasound-guided fine-needle aspiration (EUS-FNA) [5]. In particular, ERC is the primary and the most widely used endoscopic procedure for evaluating bile duct strictures, because it provides the opportunities to identify the biliary stricture, obtain specimens for cytological or histological evaluation, and perform biliary drainage. Fluoroscopic biopsy and biliary brush cytology are two major ERC techniques used in transpapillary biliary sampling for the evaluation of patients with biliary obstruction. For both methods, the specificity for diagnosis of neoplastic biliary strictures is high but the sensitivity remains unsatisfactory [1]. In recent years, a variety of new biopsy forceps and new methods of forceps biopsy have been developed to improve sensitivity, such as biopsies under the guidance of pusher [6], "ropeway-type forceps" with a side slit for a guidewire [7], and 90° adjustable biopsy forceps [8]. However, these efforts have not led to significant improvement in the yield of neoplasia.

We have developed fluoroscopy-guided, shaped endobiliary biopsy (FSEB), a unique biopsy approach in which the biopsy forceps are modified by the physician to mimic the shape of the bile duct involved. Using the "shaped" biopsy forceps has the benefit of improving access to the targeted tissue and, thereby, increasing the yield and accuracy of diagnosis. Here, we demonstrate the diagnostic characteristics of FSEB for neoplastic biliary lesions in a large cohort of consecutive patients with biliary stricture undergoing ERC. Our results indicate that FSEB has high sensitivity and accuracy and can serve as a first-line sampling tool for the evaluation of biliary strictures.

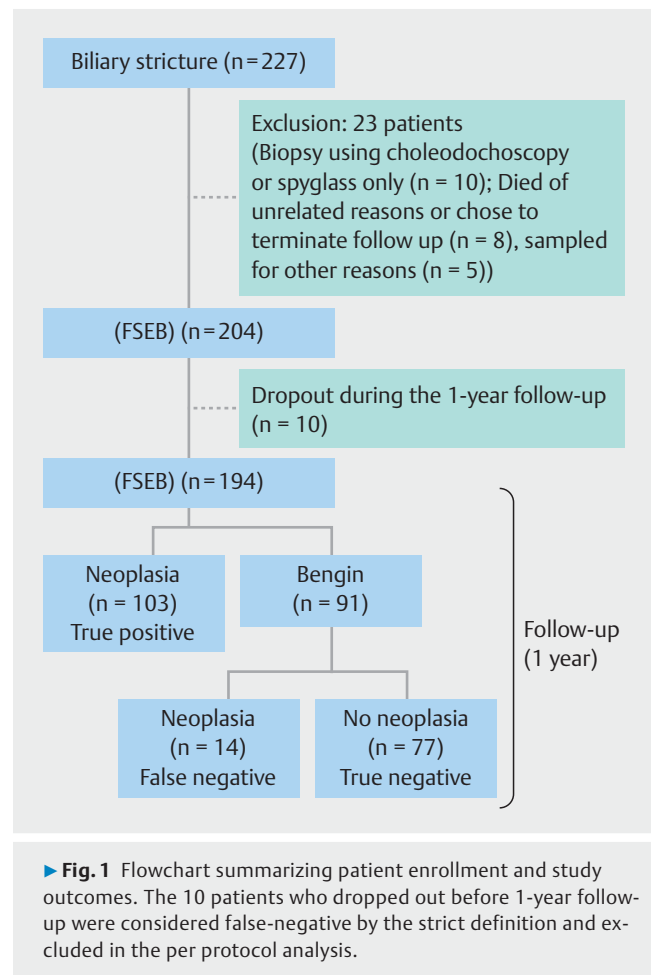
## Patients and methods

### Patients

The study included consecutive patients who had biliary stricture on the first endoscopic retrograde cholangiography (ERC), with endobiliary biopsies obtained using FSEB by the senior author (S.K. Lo) at the Cedars-Sinai Medical Center between January 2001 and December 2014. Patients that underwent choledochoscopic biopsies only and patients with incomplete medical records were excluded from this study (► Fig. 1). For intention-to-treat analysis, patients were included as false negative if they dropped out in the follow-up. Patients were excluded if death occurred from unrelated reasons or if patients chose to terminate follow-up due to advanced age or severe co-morbidities. The study was approved by the Cedars-Sinai Institutional Review Board (IRB protocol #23115). The data in this study are reported in accordance with the STARD guidelines [9].

### Location of bile duct stricture and classification of malignant bile duct stricture

Proximal bile duct is confined to the area between intrahepatic bile duct and the level of the cystic duct. Distal extrahepatic bile duct refers to the area between the origin of the cystic



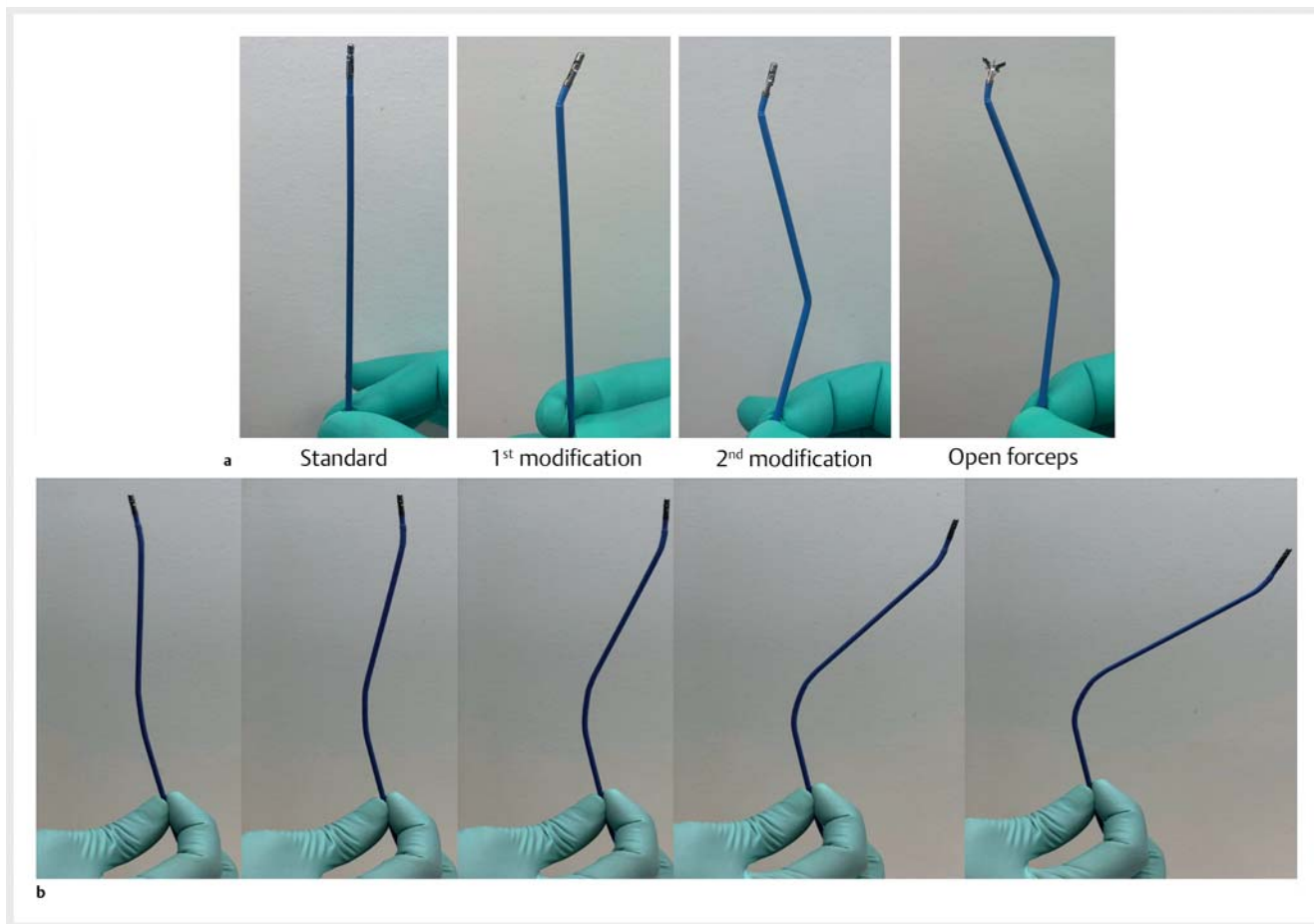
duct and the ampulla of Vater. The primary malignant bile duct stricture refers to the biliary stricture induced by the ingrowth of cholangiocarcinoma, secondary malignant bile duct stricture refers to the biliary stricture caused by the ingrowth or external compression by pancreatic, gallbladder, liver, duodenal, or metastatic cancer, lymphomas, or the lymph node.

### Endoscopic procedure

The biliary stricture was evaluated by ERC using a standard duodenoscope available at the time of endoscopy (JF-260V; Olympus Optical, Tokyo, Japan). The instruments used for deep cannulation of the biliary tree were based on the endoscopist's choice based on the clinical and anatomical considerations, such as the angle of entry and the general direction of the bile duct. A biliary sphincterotomy of native papilla was generally performed to facilitate further therapy. The stricture was dilated with a balloon dilator up to either 6 or 8 mm, depending on the location of the stricture and overall caliber of the bile ducts. Subsequently, FSEB was performed on all patients in this study.

### Creation of FSEB

FSEB is achieved by manually bending ("shaping") a standard upper endoscopy forceps (FB-220U; with cup capacity of 6.1 mm<sup>3</sup> and jaw opening width of 7.1 mm, Olympus Medical Sys-



► **Fig. 2** Modification of biopsy forceps. **a** Images of standard and shaped biopsy forceps. **b** The orientation of biopsy forceps can be controlled by manually changing wire tension (selected frames from ► **Video 1**; tension decreased from the left to right panels).

tems, Tokyo, Japan) to facilitate negotiation through a duodenoscope elevator and to achieve the angulation needed to obtain a biopsy (► **Fig. 2**). The endoscope used in this study has a 4.2-mm working channel and can accommodate both a guide-wire and a biopsy forceps alongside the wire.

For cases that required proximal biopsies, additional angles were created. The first angle is made by manually grooming the tip of the biopsy forceps and this angle can be altered based on the relative position of the duodenoscope to the papilla. The length of the bile duct is estimated by visual inspection or standard measurement technique using a cannula. Based on the distance between the tumor and the ampulla, a second shape/bend is created proximally (away from the forceps) as illustrated in ► **Fig. 2**. Please see ► **Video 1** for further explanation of creation and use of FSEB.

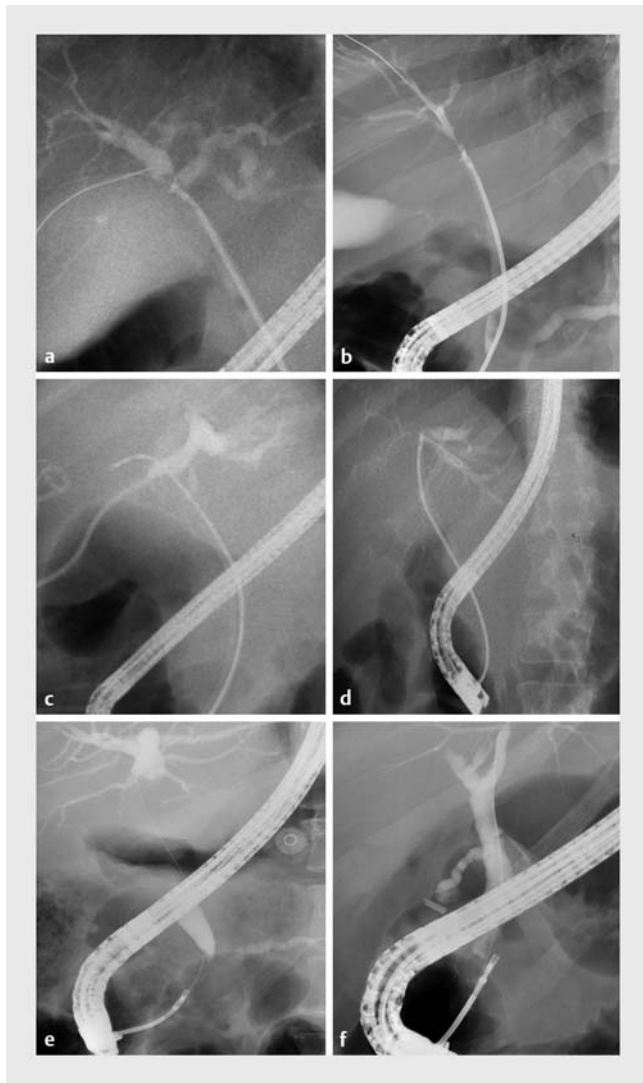
### Biopsy technique

Endoscopic sphincterotomy was performed in all patients prior to FSEB. We have not attempted passage of these forceps without sphincterotomy for perceived high risk of ERCP-related pancreatitis. The shaped forceps were introduced into the biliary duct under endoscopic and fluoroscopic guidance. After introduction into the bile duct, changing the angle of the tip of the

► **VIDEO**

► **Video 1** Demonstration of orientation of the biopsy forceps by manually changing wire tension.

biopsy instrument can be achieved by altering the pressure of closure (► **Fig. 2**, ► **Fig. 3**, and ► **Video 1**). At normal pressure of closure of the forceps, the tip of the shaped forceps may contain one or two angulations based on the desired “shaping” that was performed by the endoscopist. Pressure of closure of



► **Fig. 3** Images of FSEB for biliary stricture at various sites. **a, b** Biopsy of hilar stricture. **c, d** Right and left intrahepatic stricture. **e, f** Distal bile duct stricture.

the forceps handle is increased in order to straighten the forceps. Occasionally, the forceps can move in a different direction than desired. In that instance, the biopsy forceps may need to be reshaped based on the length and direction of the bile duct. Rarely, a new biopsy forceps may be needed if reshaping the existing forceps is not adequate. Our routine standard practice was to obtain at least three pieces of tissue for histopathology. If adequate tissue was obtained, brushing was not performed.

Thus, by using this dynamic alteration in pressure of closure of the forceps, the distal tip of the forceps is carefully negotiated to the desired location for a successful endobiliary biopsy (► **Fig. 2**, ► **Fig. 3** and ► **Video 1**). Generally, at least three specimens were obtained from different areas of the stricture, under fluoroscopic observation to guarantee the adequacy of tissue for histopathological evaluation. The biopsy specimens were fixed in 10% formalin for histopathological evaluation. After biopsies were performed, one or more biliary plastic or metal

stents were introduced beyond the stricture to relieve biliary obstruction. Clinical characteristics of the stricture were considered when making a decision on the type of stent.

The cups of the biopsy forceps can be easily opened despite creating the bends. Rarely, it may appear to open sluggishly but that may have more to do with the stricture than the bends. However, the creations of the bends make it difficult to rotate. This cannot be consistently achieved and therefore not routinely attempted. Rarely, flipping maybe attempted to angulate the forceps into one of the intrahepatic ducts with limited success.

### Follow-up

Malignant cases were referred to oncological evaluation and/or surgery for further treatment depending on the stage. If the biopsies were negative, FSEB was repeated in 1 to 2 months if there was a clinical concern for malignancy. Rarely, if the suspicion of malignancy was very high, patients were referred to be evaluated for surgery despite negative endobiliary biopsies. If the suspicion for malignancy was low or moderate, multiple endobiliary biopsies were performed at the time of stent change.

### Final diagnosis

Biliary biopsy samples were routinely classified into one of the following categories: (1) benign lesion, (2) adenoma, (3) dysplasia, (4) malignant lesion, (5) suspected malignant lesion, or (6) insufficient material. The samples that were labeled as “insufficient material” were then considered a technical failure. The biopsy samples interpreted by the pathologist as “adenoma”, “dysplasia”, “malignant” or “suspected malignant” were considered to be neoplastic by our definition. All biopsies with atypical pathologic results were considered benign. A benign biopsy was corroborated with a compatible clinical course and follow-up for at least 1-year.

The final diagnosis of these samples was made either on the basis of surgical pathology, subsequent EUS-FNA or ERC sampling with definite evidence for malignancy or a benign long-term radiological follow-up for 1-year. The neoplastic samples identified by FSEB were considered true positives. Likewise, the benign samples with a benign clinical course of 1-year with a stable or improved radiological imaging were deduced to be true negatives. These patients were further reviewed until their most recent clinical encounter including all interval radiographic imaging, procedures/surgeries, pathologic data, and deaths (verified through obituaries and medical records). The benign samples that were subsequently found to be malignant, either by surgical pathology, EUS-FNA, repeated FSEB, or clinical evidence of metastasis in the areas of the stricture were considered to be false negative. Patients who dropped out within one year of follow-up were considered false negative by our strict definition. For the per protocol analysis, the drop-out patients were excluded.

### Data collection

Data was collected by reviewing electronic medical records, including the medical history, details of the procedure, location of the stricture, complications, histopathological reports, surgical procedure reports and follow-up information. The data

were then compiled using Microsoft Excel (Microsoft Corporation, Redmond, Washington, United States).

## Statistical evaluation

The primary endpoint was the diagnostic accuracy of FSEB based on per patient analysis. Secondary outcomes were subgroup analysis of diagnostic accuracy of FSEB based on the site of stricture and type of malignancy. Statistical analysis was performed using SPSS software (IBM, Chicago, Illinois, United States). Continuous variables are expressed as mean  $\pm$  standard deviation (SD), or as median with range, if data are non-parametric. The diagnostic characteristics were calculated as a proportion and presented as accuracy, sensitivity, specificity, and negative predictive values (NPV). Fisher's exact test was used to compare the differences in demographics between patients with false-negative FSEB and all other patients. Multivariate logistic regression analysis was performed to evaluate for independent predictors of false-negative results.  $P < 0.05$  was considered to be statistically significant.

## Per-biopsy session analysis

A secondary analysis was performed to evaluate the diagnostic characteristics of FSEB based on per biopsy session analysis. This analysis is performed such that the denominator for the calculations was the total number of sessions of biopsy rather than the total number patients. The goal of this analysis is to show the diagnostic characteristics of FSEB per ERCP biopsies. Sensitivity, specificity, accuracy, and negative predictive value were calculated. Comparative analysis of the yield of FSEB was made based on the location of the biliary stricture.

## Results

### Demographics

A total of 227 patients undergoing endoscopic biliary biopsies for evaluation of biliary stricture were initially enrolled in this study. Twenty-three patients met the exclusion criteria and were excluded from the analysis (10 underwent choledochoscopic biopsy only; 8 patients died of unrelated reasons or chose to terminate follow-up due to advanced age or severe co-morbidities; 5 were sampled for other reasons) (► Fig. 1). Final analysis was performed on 204 patients. Of these, six patients (2.9%) received post Roux-en-Y surgical procedures (4 for pancreaticobiliary cancers, 1 for autoimmune cholangiopathy, 1 for bariatric surgery), eight patients (3.9%) underwent choledochoscopy in the same session. All of them underwent FSEB. The flow chart of patient enrollment with inclusion and exclusion criteria is shown in ► Fig. 1. Neoplasia was identified in 117 patients (57.4%), and 77 patients (37.7%) had no evidence of dysplasia over  $\geq 1$  years of follow-up (► Table 1). Overall, 10 patients (4.9%) were lost in follow-up.

### Diagnostic characteristics of FSEB

All tissue specimens obtained by FSEB were adequate for histopathological diagnosis. Among these, a total of 103 patients were diagnosed with neoplasia (95 with cancer, 8 with adenoma/dysplasia) and were considered to be true-positive findings.

► **Table 1** Demographic and final diagnoses of the patients included in the study (N = 204).

Characteristics	Value
Age in years, mean (range)	65 (31–100)
Sex, male (%)	113 (55.4%)
Location of stricture	
▪ Proximal	97
▪ Distal	107
Biopsy session	
▪ One session	166
▪ > 1 session	38
Post Roux-en-Y surgery	6
Choledochoscopy or spyglass in the same session	8
Final diagnosis	
▪ Non-neoplasia	77
▪ Primary sclerosing cholangitis	19
▪ Biliary stone	13
▪ Chronic pancreatitis	9
▪ sphincters stenosis	9
▪ postoperative stricture	6
▪ other	21
Neoplasia	
▪ Adenoma/dysplasia	8
▪ Cholangiocarcinoma	46
▪ Pancreatic cancer	44
▪ hepatocellular carcinoma	4
▪ Other malignancies	15
Dropout before 1-year follow-up	10

Ninety-one patients had non-neoplastic index FSEB histology: 77 (5 confirmed on surgery) had no evidence of dysplasia upon follow-up of one year (true negative). Fourteen patients were found to have neoplastic disease subsequent to their negative tissue sampling and the index histology in these patients was considered to be false negative. Of these, eight were found to have neoplasia on repeat EUS-FNA, five on surgical histopathology, and one had an obvious source of malignancy with a cervical cancer history and multiple liver metastasis on imaging. Ten patients dropped out before the 1-year follow-up period and were categorized as false negative by our strict definition (► Table 1).

The diagnostic characteristics of FSEB are summarized in ► Table 2. The overall sensitivity, specificity, accuracy, and NPV were 81.1%, 100%, 88.2%, and 76.2%, respectively. When the dropout patients were excluded from the analysis (per protocol), the sensitivity and accuracy improved to 88.0%

► **Table 2** Diagnostic characteristics of FSEB for diagnosis of biliary neoplasia.

	Total numbers	True positive	False positive	True negative	False negative <sup>1</sup>	Sensitivity (95% ci)	Accuracy (95% ci)	Negative predictive value (95% CI)
Per-patient analysis (N = 204)								
All locations	204	103	0	77	24	81.10% (73.20%–87.50%)	88.24% (83.00%–92.31%)	76.24% (66.74%–84.14%)
Proximal	97	51	0	41	5	91.07% (80.38%–97.04%)	94.85% <sup>2</sup> (88.38%–98.31%)	89.13% (76.43%–96.38%)
Distal	107	52	0	36	19	73.24% (61.41%–83.06%)	82.24% <sup>2</sup> (73.67%–88.96%)	65.45% (51.42%–77.76%)
Per-biopsy session analysis (N = 250)								
All locations	250	114	0	104	32	78.08% (70.49%–84.50%)	87.20% (82.41%–91.08%)	76.47% (68.44%–83.32%)
Proximal	122	59	0	55	8	88.06% (77.82%–94.70%)	93.44% <sup>2</sup> (87.49%–97.13%)	87.30% (76.50%–94.35%)
Distal	128	55	0	49	24	69.62% (58.25%–79.47%)	81.25% <sup>2</sup> (73.40%–87.60%)	67.12% (55.13%–77.67%)

FSEB, fluoroscopy-guided, shaped endobiliary biopsy.

<sup>1</sup> Including patients dropped out in follow-up (N = 10).

<sup>2</sup> Accuracy rates between proximal and distal bile duct biopsies are statistically different ( $P < 0.01$ ).

► **Table 3** Diagnostic performance of FSEB according location or type of malignancy.

	Patients (n)	Sensitivity (95% CI)	NPV (95% CI)	Accuracy (95% CI)
Site of Stricture				
Intrahepatic duct	24	88.89% (51.75%–99.72%)	93.75% (69.77%–99.84%)	95.83% (78.88%–99.89%)
Common hepatic duct	73	91.49% <sup>1</sup> (79.62%–97.63%)	86.67% (69.28%–96.24%)	94.52% <sup>1</sup> (86.56%–98.49%)
Common bile duct	107	73.24% <sup>1</sup> (61.41%–83.06%)	65.45% (47.26%–80.90%)	82.24% <sup>1</sup> (73.67%–88.96%)
Malignancy				
Cholangiocarcinoma	46	91.3% (79.21%–97.58%)	95.06% (87.84%–98.64%)	96.75% (91.88–99.11%)
Pancreatic Cancer	44	84.09% (69.93–93.36%)	91.67% (83.58%–96.58%)	94.21% (88.44%–97.64%)

FSEB, fluoroscopy-guided, shaped endobiliary biopsy.

<sup>1</sup> Sensitivity and accuracy rates between common hepatic duct strictures and common bile duct strictures are statistically different ( $P < 0.01$  and  $P < 0.02$ , respectively).

and 92.7%, respectively. Potential complications of FSEB include biliary duct perforation, bile peritonitis, bile leaks, bleeding, infection, and pancreatitis. No significant complications were noted on review of these patients.

### Differences in diagnostic characteristics of FSEB based on malignancy and location

Because the diagnostic accuracy of endobiliary biopsies can be affected by the location of the stricture [10], we compared the diagnostic performance characteristics of FSEB between proximal and distal strictures. As shown in ► **Table 2**, if the dropout subjects were included, FSEB detection for proximal biliary lesions was significantly more sensitive (91.1% vs 73.2%,  $P < 0.01$ ) and more accurate (94.9% vs 82.2%,  $P < 0.01$ ) than for

distal biliary lesions. When further dividing the stricture site into intrahepatic duct (IHD), common hepatic duct (CHD), and common bile duct (CBD), the sensitivity was 88.9%, 91.5%, and 73.2% respectively (► **Table 3**). FSEB had a significantly higher accuracy for lesions in the CHD compared to CBD (94.5% vs 82.2%,  $P < 0.01$ ).

The diagnostic performance of FSEB was also evaluated based upon type of malignancy. The sensitivity for detecting cholangiocarcinoma was 91.3% in comparison to pancreatic cancer, which was 84.1% (► **Table 4**). Moreover, the accuracy was high in both groups, with cholangiocarcinoma having a 96.8% accuracy and pancreatic cancer with 94.2% accuracy. As expected, the specificity and positive predictive value was 100% in both groups.

► **Table 4** Characteristics of confirmed false-negative results of FSEB (N = 14).

Characteristics	Value	Multivariate analysis results		
		Standardized $\beta$	% explained variance	P value
Age in year, mean (range)	60 (40–78)	0.0026	0.4	0.8263
Gender, male (%)	11 (78.6%)	0.0843	1.2	0.2573
Location of stricture				
▪ Proximal	5/51	0.0435	1.3	0.7601
▪ Distal	9/52			

FSEB, fluoroscopy-guided, shaped endobiliary biopsy.

### Per-biopsy session analysis

Next, we analyzed the diagnostic characteristics of FSEB per biopsy session. A total of 250 biopsy sessions were performed in the group of 204 patients. The overall sensitivity, specificity, accuracy, and NPV were 78.1%, 100%, 87.2%, and 76.5%, respectively (► **Table 2**). Similarly, compared to distal biliary lesions, FSEB was significantly more sensitive (88.1% vs 69.6%,  $P < 0.01$ ) and more accurate (93.4% vs 81.3%,  $P < 0.01$ ) in diagnosing proximal neoplastic biliary lesions, by the strict definition (► **Table 2**).

### Independent predictors of False-negative FSEB

The demographics, clinical indication, location of FSEB, and final diagnosis for the patients who were false negative on index FSEB are presented in ► **Table 4**. False-negative results were identified in 11.1% (14/117) of the patients with confirmed neoplasia. Of the 14 false-negative cases, four primary biliary malignancies (cholangiocarcinoma) and 10 secondary biliary malignancies were subsequently diagnosed. The secondary biliary malignancies included seven pancreatic cancers, two lymphomas, and one metastatic cervical cancer. According to multivariate analysis, none of the variables we tested, such as age, gender, location of lesion, or tumor type, were significant independent predictors of false negative by FSEB. It should be noted that, under the strict definition where the ten patients dropped out in the follow-up were included for analysis, the false-negative rate is higher for lesions in the distal bile duct than the ones in the proximal region (Fisher's exact test;  $P = 0.01$ ).

We also reviewed the records of the 77 negative patients beyond the 1-year follow-up period to identify potential misdiagnosis. Eleven patients (11/77; 14.3%) did not return to our institution for care beyond one year, one of whom was found to have died of unknown cause on extensive review of death and obituary records. The remaining 66 patients (66/77; 85.7%) were reviewed with a mean follow-up of 89.7 months (range, 24–223 months). At 2 years following FSEB, all 66 patients continued to have a benign course and none were reclassified to false negative. One patient developed periampullary adenocarcinoma after 30 months, which could possibly be interpreted as a false negative. Death records and obituary data were reviewed on all 66 patients and 10 individuals had passed after a

mean of 69.3 months (range, 25–154) from date of their procedure.

### Discussion

In this long-term, retrospective study of a large cohort of patients, we show very high overall sensitivity and accuracy of FSEB for the diagnosis of biliary neoplasm (81.1% and 88.2%, respectively). In comparison, the sensitivity of conventional fluoroscopic forceps biopsies ranges from approximately 36% to 81% with the pooled sensitivity of 48% [11]. The sensitivity of biliary brush cytology varies from 6%–64% with the overall sensitivity of 42% [12]. The combination of brush cytology and forceps biopsy has been shown to enhance the yield of biliary malignancy to about 70% to 74% [13, 14]. Repeated brush cytology and biopsies can moderately increase the sensitivity [15, 16]. An ERC-based method of obtaining pathologic diagnosis using a smashed cytologic preparation of forceps biopsy sampling (Smash protocol) showed an overall sensitivity of 76% [17]. Thus, our results show that the sensitivity of FSEB is among the highest of what has been reported.

Our data show that the sensitivity and accuracy of FSEB for detecting proximal biliary neoplasm were significantly higher than that for distal biliary neoplasm, which is consistent with a previous study [18]. The disparity is conceivably due to the intrinsic difficulty to access and target a lesion located proximally in bile ducts.

Modifying the design of biopsy tools represents an important strategy to improve diagnostic yield. The development of novel biopsy forceps or biopsy methods, such as the use of double balloon enteroscopy forceps, the “ropeway-type forceps” with a side slit for a guidewire, and the 90° adjustable biopsy forceps, has been reported and shown to improve the sensitivity up to 69% to 71% [6–8]. However, these studies only involve small groups of subjects (12–43 patients) [6–8]. Thus, up until this study, high quality studies that establish the usefulness of a specific biopsy forceps or technique have been limited. To the best of our knowledge, our study has included one the largest cohorts for evaluation of the diagnostic characteristics of ERC-based biopsy in biliary neoplasms.

A unique feature of FSEB is the use of biopsy forceps that have been precurved at the tip and bent further back to mimic

► **Table 5** Characteristics of studies evaluating the sensitivity of endobiliary forceps biopsies and techniques.

Study	Year	Sample size (n)	Technique	Sensitivity %
Sugiyama et al. [24]	1996	52	Forceps biopsy	81 %
Kitajima et al. [25]	2007	51	Forceps biopsy	65 %
Weber et al. [26]	2008	58	Forceps biopsy	53 %
Wright et al. [17]	2011	133	Endobiliary forceps biopsy + Smash Protocol	72 %
Hartman et al. [27]	2012	81	Forceps biopsy	76 %
Draganov et al. [28]	2012	26	Endobiliary forceps biopsy	29 %
Weilert et al. [29]	2014	51	Brush cytology + forceps biopsy	50 %
Chen et al. [30]	2016	79	Endobiliary forceps biopsy	54 %
Yamamoto et al. [31]	2017	360	Endobiliary slim forceps biopsy	70 %
Inoue et al. [32]	2018	110	Controllable biopsy-forceps	60 %
Our study	2021	204	Endobiliary shaped forceps biopsy	81 %

the shape of the bile duct in question (► **Fig. 2**, ► **Fig. 3** and ► **Video 1**). The “shaped” forceps provide four distinct advantages. First, the angulated tip allows smooth exit from the duodenoscope elevator. Second, it improves the ease of passage through the papilla. Third, the shaped forceps enhance targeting of the lesion, regardless of the shape and distance above the papilla. Fourth, by altering the degree of tightness of forceps closure, the instrument can negotiate through a tortuous bile duct to reach the stricture. It should also be noted that our approach features the standard forceps with a cup opening size of 7.1 mm (the model, producer had been shown in methods), which have been shown to be superior to the pediatric or the SpyBite forceps that have smaller cup opening sizes (4.9 mm and 4.1 mm, respectively) [19,20]. The ability to exert moderate pressure during closure is an integral part of the FSEB technique, which can only be carried out with a strong, standard forceps. For this reason, forceps with a thinner or softer shaft are less optimal in acquiring the desired tissue. With the modification, we have been able to insert the biopsy forceps to the papilla in all patients intended (i.e. post-sphincterotomy patients). Overall, we believe that the ability to create bends in the forceps and the use of the tension to help with angulation allows for easier access of the bile duct and better targeting of the tumor, which contributes to higher sensitivity.

The routine usage of a guidewire across the stricture to guide forceps advancement and tissue targeting is another essential element of our biopsy technique, as fluoroscopic guidance based on the contrast retained above the stricture is unreliable with regards to safety and accuracy of forceps passage. The shaped biopsy forceps and the guidewire can be simultaneously inserted in one channel. No false-positives or complications have been found with FSEB. Based on our experience, we believe that FSEB may have a lower risk of complications compared to standard biopsy forceps as the shaped forceps better align with the bile duct. We did not conduct any analysis on the safety and accuracy of FSEB before or after balloon dilation

of the stricture, although anecdotally we have not observed any difference between the two approaches.

The high diagnostic yield of FSEB can, in part, be attributed to the increased amount of tissue sampled from the stricture. A previous study showed that the tissue sampling number is associated with lower false-negative rate and recommended at least 4–6 samples per case [21]. In the FSEB study, we generally obtain the equivalence of three adequately sampled biopsies, with an additional sampling performed if one of the samples was substantially smaller than expected. The pathological tissue samples collected by FSEB range from 1 mm to 7 mm and were sufficient for histopathological diagnosis in all the patients.

We were not able to identify any statistically significant independent predictors of false-negative results by FSEB. The sensitivity for all sampling methods can be influenced by the characteristics of the tumor underlying the stricture [10,22,23]. In our study, the false negative rate for the secondary malignant biliary stricture was moderately higher than that of cholangiocarcinoma.

The ropeway technique from multiple vendors, as well as several other kinds of “modified” biliary forceps, has been attempted by our senior author over the years. Despite the senior author’s experience in ERCP for more than four decades, it is unclear why our biopsy technique works better than the others. It is possible that the cups of the biopsy forceps have better ability to obtain adequate tissue. Other factors, such as the stiffness of the forceps, the size of forceps, and the smoothness of the edges, may also play a role.

We recognize several limitations of the study. First, this was a retrospective, single-centered study and future prospective studies are needed to confirm the advantage of FSEB. Second, we have compared the accuracy of FSEB with that of previously reported ERC-based methods (► **Table 5**). The results remain to be confirmed by further studies that include a control group using a conventional biopsy forceps. Third, operator-dependent bias may exist, as all FSEB were performed by a single



endoscopist. There may be a learning curve with this method, but performance may improve with more procedures. This study did not evaluate the role of skill or learning curve on the accuracy of biopsy. It would be of importance to determine whether the results can be reproduced by other endoscopist in future studies. Fourth, although we employed a scheme of 1-year follow-up to determine the final diagnosis of non-neoplastic cases, we recognize that biliary adenoma without dysplasia or with low grade dysplasia can be slow-growing and may evade definite diagnosis in the one-year period, leading to an underestimate of the false-negative rate. For this reason, we continued to review the patients beyond the standard 1-year follow up corroborating death records to obviate the need for potential reclassification.

## Conclusions

In summary, our results indicate that FSEB exhibits high levels of sensitivity and accuracy in evaluating biliary strictures and is safe and inexpensive. FSEB can potentially be used solely as the tissue sampling method. Future, prospective, randomized, multicenter studies are needed to validate the definitive role of FSEB in accurate diagnosis of malignant biliary neoplasm. Further studies are also needed to compare FSEB with other sampling techniques, such as biliary brush cytology, cholangioscopy, and EUS-FNA/biopsy, in order to establish a highly sensitive and specific diagnostic modality for biliary stricture that is also safe and cost-effective.

## Competing interests

The authors declare that they have no conflict of interest.

## References

- [1] Bowlus CL, Olson KA, Gershwin ME. Evaluation of indeterminate biliary strictures. *Nat Rev Gastroenterol Hepatol* 2016; 13: 28–37
- [2] Tummala P, Munigala S, Eloubeidi MA et al. Patients with obstructive jaundice and biliary stricture±mass lesion on imaging: prevalence of malignancy and potential role of EUS-FNA. *J Clin Gastroenterol* 2013; 47: 532–537
- [3] Xu M-M, Sethi A. Diagnosing biliary malignancy. *Gastrointest Endosc Clin North Am* 2015; 25: 677–690
- [4] Bhat YM, Kochman ML. Novel management of complex hilar biliary strictures with the Spyglass Direct Visualization System (with video). *Gastrointest Endosc* 2009; 69: 1182–1184
- [5] Sadeghi A, Mohamadnejad M, Islami F et al. Diagnostic yield of EUS-guided FNA for malignant biliary stricture: a systematic review and meta-analysis. *Gastrointest Endosc* 2016; 83: 290–298.e1
- [6] Kulaksiz H, Strnad P, Römpf A et al. A novel method of forceps biopsy improves the diagnosis of proximal biliary malignancies. *Digest Dis Sci* 2011; 56: 596–601
- [7] Tamada K, Higashizawa T, Tomiyama T et al. Ropeway-type bile duct biopsy forceps with a side slit for a guidewire. *Gastrointest Endosc* 2001; 53: 89–92
- [8] Ishii K, Itoi T, Sofuni A et al. Novel biopsy forceps for diagnosis of biliary tract diseases during endoscopic retrograde cholangiopancreatography: a prospective comparative study with 90° adjustable and conventional biopsy forceps. *Hepato-gastroenterology* 2011; 59: 1350–1353
- [9] Meyer GJ. Guidelines for reporting information in studies of diagnostic test accuracy: the STARD initiative. *Journal of personality assessment* 2003; 81: 191–193
- [10] Korc P, Sherman S. ERCP tissue sampling. *Gastrointest Endosc* 2016; 84: 557–571
- [11] Navaneethan U, Njei B, Lourdasamy V et al. Comparative effectiveness of biliary brush cytology and intraductal biopsy for detection of malignant biliary strictures: a systematic review and meta-analysis. *Gastrointest Endosc* 2015; 81: 168–176
- [12] Burnett AS, Calvert TJ, Chokshi RJ. Sensitivity of endoscopic retrograde cholangiopancreatography standard cytology: 10-y review of the literature. *J Surg Res* 2013; 184: 304–311
- [13] Kitajima Y, Ohara H, Nakazawa T et al. Usefulness of transpapillary bile duct brushing cytology and forceps biopsy for improved diagnosis in patients with biliary strictures. *J Gastroenterol Hepatol* 2007; 22: 1615–1620
- [14] Schoeffl R, Haefner M, Wrba F et al. Forceps biopsy and brush cytology during endoscopic retrograde cholangiopancreatography for the diagnosis of biliary stenoses. *Scand J Gastroenterol* 1997; 32: 363–368
- [15] de Bellis M, Fogel EL, Sherman S et al. Influence of stricture dilation and repeat brushing on the cancer detection rate of brush cytology in the evaluation of malignant biliary obstruction. *Gastrointest Endosc* 2003; 58: 176–182
- [16] Caturelli E, Biasini E, Bartolucci F et al. Diagnosis of hepatocellular carcinoma complicating liver cirrhosis: utility of repeat ultrasound-guided biopsy after unsuccessful first sampling. *Cardiovasc Intervent Radiol* 2002; 25: 295–299
- [17] Wright ER, Bakis G, Srinivasan R et al. Intra-procedural tissue diagnosis during ERCP employing a new cytology preparation of forceps biopsy (Smash protocol). *Am J Gastroenterol* 2011; 106: 294–299
- [18] Ponchon T, Gagnon P, Berger F et al. Value of endobiliary brush cytology and biopsies for the diagnosis of malignant bile duct stenosis: results of a prospective study. *Gastrointest Endosc* 1995; 42: 565–572
- [19] Ikeda M, Maetani I, Terada K et al. Usefulness of endoscopic retrograde biliary biopsy using large-capacity forceps for extrahepatic biliary strictures: a prospective randomized study. *Endoscopy* 2010; 42: 837–841
- [20] Hartman DJ, Slivka A, Giusto DA et al. Tissue yield and diagnostic efficacy of fluoroscopic and cholangioscopic techniques to assess indeterminate biliary strictures. *Clin Gastroenterol Hepatol* 2012; 10: 1042–1046
- [21] Kawashima H, Itoh A, Ohno E et al. Transpapillary biliary forceps biopsy to distinguish benign biliary stricture from malignancy: how many tissue samples should be obtained? *Digest Endosc* 2012; 24: 22–27
- [22] Razumilava N, Gores GJ. Cholangiocarcinoma. *Lancet* 2014; 383: 2168–2179
- [23] Tamada K, Ushio J, Sugano K. Endoscopic diagnosis of extrahepatic bile duct carcinoma: advances and current limitations. *World J Clin Oncology* 2011; 2: 203
- [24] Sugiyama M, Atomi Y, Wada N et al. Endoscopic transpapillary bile duct biopsy without sphincterotomy for diagnosing biliary strictures: a prospective comparative study with bile and brush cytology. *Am J Gastroenterol* 1996; 91: 465–467
- [25] Kitajima Y, Ohara H, Nakazawa T et al. Usefulness of transpapillary bile duct brushing cytology and forceps biopsy for improved diagnosis in patients with biliary strictures. *J Gastroenterol Hepatol* 2007; 22: 1615–1620

- [26] Weber A, von Weyhern C, Fend F et al. Endoscopic transpapillary brush cytology and forceps biopsy in patients with hilar cholangiocarcinoma. *World J Gastroenterol* 2008; 14: 1097–1101
- [27] Hartman DJ, Slivka A, Giusto DA et al. Tissue yield and diagnostic efficacy of fluoroscopic and cholangioscopic techniques to assess indeterminate biliary strictures. *Clin Gastroenterol Hepatol* 2012; 10: 1042–1046
- [28] DraganovV PV, Chauhan S, Wagh MS et al. Diagnostic accuracy of conventional and cholangioscopy-guided sampling of indeterminate biliary lesions at the time of ERCP: a prospective, long-term follow-up study. *Gastrointest Endosc* 2012; 75: 347–353
- [29] Weilert F, Bhat YM, Binmoeller KF et al. EUS-FNA is superior to ERCP-based tissue sampling in suspected malignant biliary obstruction: results of a prospective, single-blind, comparative study. *Gastrointest Endosc* 2014; 80: 97–104
- [30] Chen WM, Wei KL, Chen YS et al. Transpapillary biliary biopsy for malignant biliary strictures: comparison between cholangiocarcinoma and pancreatic cancer. *World J Surg Oncol* 2016; 14: 140
- [31] Yamamoto K, Tsuchiya T, Itoi T et al. Evaluation of novel slim biopsy forceps for diagnosis of biliary strictures: Single-institutional study of consecutive 360 cases (with video). *World J Gastroenterol* 2017; 23: 6429–6436
- [32] Inoue T, Kitano R, Kobayashi Y et al. Assessing the diagnostic yield of controllable biopsy-forceps for biliary strictures. *Scand J Gastroenterol* 2018; 53: 598–603