

Access this article online
Quick Response Code:

Website: www.e-tjo.org
DOI: 10.4103/tjo.tjo_40_17

Autoimmune retinopathy associated with systemic lupus erythematosus: A diagnostic dilemma

Wadakarn Wuthisiri^{1,2}, Yu-Hung Lai^{1,3,4}, Jenina Capasso¹, Martin Blidner⁵, David Salz¹, Erik Kruger⁶, Alex V. Levin^{1,7}

Abstract:

Visual loss in systemic lupus erythematosus (SLE) due to autoimmune retinopathy (AIR) is rare and easily misdiagnosed as hydroxychloroquine retinopathy. We report the rare clinical presentation of severe visual loss in a patient with SLE due to nonparaneoplastic AIR as differentiated from hydroxychloroquine toxicity. A 70-year-old female diagnosed and treated for lupus for 17 years and had been taking hydroxychloroquine for 15 years. Over the past 2 years, she developed progressive peripheral visual loss oculus uterque which rapidly advanced in the latter 6 months. Hydroxychloroquine toxicity was initially suspected, but diagnostic testing revealed a retinal degeneration. Antiretinal autoantibody testing using Western blot analysis revealed autoantibodies against 44-kDa, 46-kDa (anti-enolase), and 68-kDa proteins. Visual acuity improved in the first 6 months of treatment with mycophenolate mofetil. Our case suggests that AIR should be considered in the differential diagnosis of rapid, severe visual loss in patients with hydroxychloroquine treatment.

Keywords:

Hydroxychloroquine retinopathy, nonparaneoplastic autoimmune retinopathy, systemic lupus erythematosus

¹Pediatric Ophthalmology and Ocular Genetics, Wills Eye Hospital, ⁷Thomas Jefferson Medical College, Thomas Jefferson University, Philadelphia, ⁵The Arthritis Center of NEPA, Wilkes-Barre, ⁶Eye Care Specialists, Kingston, PA, USA, ²Department of Ophthalmology, Faculty of Medicine, Ramathibodi Hospital, Mahidol University, Bangkok, Thailand, ³Department of Ophthalmology, Kaohsiung Medical University Hospital, ⁴Department of Ophthalmology, School of Medicine, College of Medicine, Kaohsiung Medical University, Kaohsiung, Taiwan

Address for correspondence:

Dr. Alex V. Levin,
Wills Eye Hospital,
840 Walnut Street,
Philadelphia,
PA 19107-5109, USA.
E-mail: alevin@willseye.org

Submission: 16-04-2016
Accepted: 20-03-2017

Introduction

Autoimmune retinopathies (AIRs) are a group of autoantibody-mediated retinal degenerations. Three subtypes have been identified: cancer-associated retinopathy (CAR), melanoma-associated retinopathy (MAR), and nonparaneoplastic AIR (npAIR).^[1,2] AIR is characterized by acute or subacute progressive visual deterioration, visual field loss, abnormal electroretinography (ERG), the presence of circulating antiretinal autoantibodies (ARAs), and often a normal appearing retina.^[2]

Systemic lupus erythematosus (SLE) is a chronic autoimmune disorder, characterized by the production of autoantibodies against cell surfaces and abnormal deposition of

circulating immune complexes in various tissues, both of which result in end-organ damage.^[3] The ocular manifestations are highly variable and can lead to severe visual loss. Previously reported posterior segment manifestations include retinal vasculitis or vascular occlusion, choroidopathy, optic neuritis, and toxic retinopathy related to the use of hydroxychloroquine in SLE treatment.^[1,3] Reports of SLE-associated AIR are rare and may be incorrectly ascribed to hydroxychloroquine toxicity.^[1]

Case Report

A 70-year-old Caucasian female, with no family history of retinal degeneration, was first diagnosed with SLE in 1995 in another center. Her prior manifestations of the disease included synovitis, pleuropericarditis, hemolytic anemia,

This is an open access article distributed under the terms of the Creative Commons Attribution-NonCommercial-ShareAlike 3.0 License, which allows others to remix, tweak, and build upon the work non-commercially, as long as the author is credited and the new creations are licensed under the identical terms.

For reprints contact: reprints@medknow.com

How to cite this article: Wuthisiri W, Lai YH, Capasso J, Blidner M, Salz D, Kruger E, *et al.* Autoimmune retinopathy associated with systemic lupus erythematosus: A diagnostic dilemma. Taiwan J Ophthalmol 2017;7:172-6.

immune thrombocytopenia, positive antinuclear antibody (ANA), positive double-stranded DNA (dsDNA) antibody, positive anti-SSA antibody, positive anti-SSB antibody, and hypocomplementemia. She experienced decreasing vision, nyctalopia, and constricted peripheral vision beginning in 2010 and hydroxychloroquine was stopped. Her SLE had been stable on hydroxychloroquine 400 mg daily for 15 years (total dose 2190 g) and low-dose prednisone for 17 years. She was 59 inches (149.9 cm) in height and weighed 53.5 kg (ideal body weight 44.6 kg).^[4] Over the past 2 years, zoledronic acid, metoprolol, hydrochlorothiazide, allopurinol, and potassium supplements were used for the treatment of her osteoporosis, hypertension, and gout, respectively. Although her SLE was stable and well controlled, with negative anti-dsDNA and 1:640 ANA, over the past 2 years, she had a progressive decline of her peripheral vision making it difficult for her to use her vision. Hydroxychloroquine was stopped. Her vision rapidly declined in the first 6 months and then slowly thereafter. Cataract surgery performed after the first 6 months did not result in visual improvement.

At her first visit with us in 2012, best-corrected visual acuity in her current spectacles (plano +0.75 axis 55 right eye, +0.50 +0.5 axis 94 left eye) was 20/40 in each eye with difficulty finding the letters on the Snellen chart in each eye. She was unable to identify any Ishihara color plates in either eye other than the control plates. Pupils were reactive and equal, without relative afferent pupillary defect or paradoxical pupils. Ocular motility was full, and there was no strabismus. Anterior segment examination was normal with posterior chamber intraocular lenses in both eyes. Dilated retinal examination was remarkable in both eyes for optic nerve pallor, retinal arterial attenuation, blunted foveal reflex, and mid-peripheral pigmentary mottling [Figure 1].

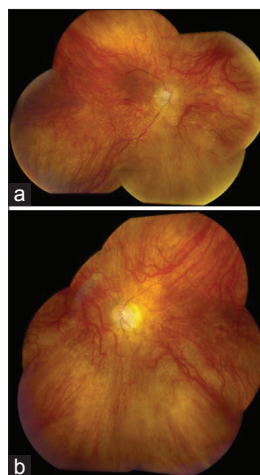


Figure 1: Fundus photographs: Right eye (a); left eye (b). Note bilateral optic nerve pallor, retinal arterial attenuation, blunted foveal reflex, and mid-peripheral pigmentary mottling

Goldmann visual field showed constriction to $<10^\circ$ in each eye without peripheral islands. Full-field ERG and multifocal ERG (ffERG and mfERG) performed in accordance with the International Society for Clinical Electrophysiology of vision protocol were isoelectric to all stimuli. Intravenous fluorescein angiography showed attenuation of the retinal vessels with some transmission defects in the retinal pigment epithelium. Optical coherence tomography (OCT) showed the absence of the macular photoreceptors, loss of normal retinal lamination, and gliosis on the retinal surface of both eyes [Figure 2]. Fundus autofluorescence (FAF) showed diffuse punctate hyperautofluorescence throughout the posterior pole with the suggestion of more intense flecks concentrated in the macula around the fovea [Figure 3]. Peripheral FAF images were not obtained.

Western blot analysis to detect antiretinal autoantibodies (Ocular Immunology Laboratory, Casey Eye Institute, Oregon, USA) revealed autoantibodies against 44-kDa, 46-kDa (anti-enolase), and 68-kDa proteins. CT scan of the brain, whole body magnetic resonance imaging, and mammography were all normal. There were no skin lesions suggestive of melanoma. No genetic testing for retinal dystrophy was performed.

Mycophenolate mofetil 500 mg twice a day was started in January 2013. Her vision improved to 20/30–40 both eyes 2.5 months thereafter and 20/25–30 oculus uterque at 6 months. At last follow-up in June 2014, her best-corrected visual acuity was 20/40 OD but decreased to 20/100 OS. She had sustained fractures from a fall in her left tibia and right wrist in 2014 requiring surgery. Hence, the treatment for her AIR was interrupted. She was unable to perform visual field testing. There was new foveal hyperautofluorescence in the left eye more than the right that had worsened since her presentation [Figure 3].

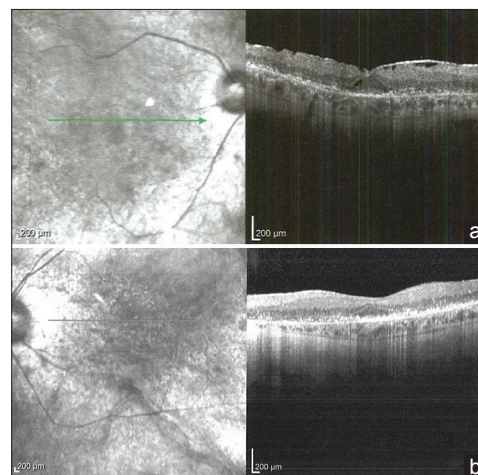


Figure 2: Optical coherence tomography in 2012: Right eye (a); left eye (b). Optical coherence tomography showed the absence of the macular photoreceptors, loss of normal retinal lamination, and gliosis on the retinal surface of both eyes

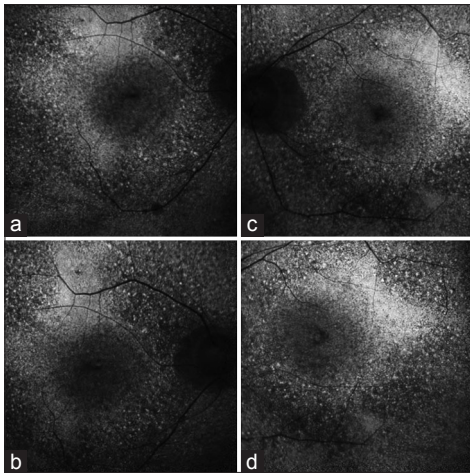


Figure 3: Fundus autofluorescence in October 4, 2013 (a and b) diffuse punctate hyperautofluorescence throughout the posterior pole without the more characteristic easily discernible perfoveal ring of hydroxychloroquine toxicity. October 6, 2014 (c and d) There is new foveal hyperautofluorescence in the left eye more than the right

OCT was unchanged. ffERG and mfERG showed no recovery of response and remain isoelectric.

Discussion

AIR is a retinopathy resulting from an immunological attack on the retina by ARAs directed against retinal antigens such as rod, cone, and Muller cells.^[1,2] AIR is characterized by cone and rod dysfunction associated with photoaversion, subacute progressive loss of vision, nyctalopia, abnormalities of color perception, central or paracentral scotoma, and decreased photopic and scotopic responses on ERG.^[2] npAIR shares the same features as CAR/MAR but occurs in the absence of malignant tumor.^[5-8] The clinical spectrum of AIR is heterogeneous and diverse. The fundus can appear normal or show signs of retinal degeneration including attenuated retinal vessels, disc pallor, and RPE mottling or atrophy.^[9]

Numerous antiretinal antibodies have been described in AIR. Among them, antibodies against recoverin (23-kDa) and enolase (46-kDa) are the most common.^[2,6] Both anti-recoverin and anti-enolase antibodies can be found in patients with CAR and npAIR.^[2] It had been suggested that the anti-recoverin antibody is more specific to paraneoplastic retinopathy and the anti-enolase antibody is more sensitive^[6] although a significant portion of normal people have been reported to carry anti-recoverin antibody.^[10] Hence, the interpretation of these antiretinal antibodies should be cautious.^[11]

There are several causes of visual dysfunction in SLE. Pigmentary retinopathy is uncommon. Hydroxychloroquine retinopathy must be considered.

A cumulative dose of more than 1000 g has been considered as a risk factor.^[12] Our patient had been treated with a potentially toxic cumulative dose of 2190 g,^[12] but her fundus, diagnostic testing and clinical features are not consistent with hydroxychloroquine retinopathy. She did not demonstrate many of the common signs of hydroxychloroquine retinopathy: “bull’s eye” maculopathy, spared central vision, paracentral visual field defect, FAF findings of perimacular hyperautofluorescent and hypoautofluorescent rings with or without hyperautofluorescent specks surrounding the fovea, typical OCT findings, and normal ffERG.^[12-14] One report of retinal toxicity from hydroxychloroquine with a similar cumulative dose to our patient did not show similar clinical features.^[13] The patient first saw us in 2012 with a history of progressive visual loss within 2 years even though the hydroxychloroquine had been stopped. She did not have bull’s eye maculopathy. She demonstrated severely constricted visual fields without peripheral islands, diffuse retinal structure disruption on OCT without “flying saucer” sign, diffuse hyper- and hypoautofluorescence on FAF, and isoelectric ffERG and mfERG, all of which are not typical of hydroxychloroquine retinopathy.^[13,15-17] Although late deterioration can rarely occur despite stopping hydroxychloroquine, our patient’s features do not unequivocally suggest this possibility.^[13] Yet, there is no way to prove she did not have very severe end-stage hydroxychloroquine retinopathy.

We also considered the possibility of coincidental late-onset primary retinitis pigmentosa. In later onset retinal degeneration (LORD), retinal findings including yellow subretinal deposits, chorioretinal atrophy, and choroidal neovascularization, all are very different from those seen in our patient.^[18] Diffuse hyperautofluorescence has been reported in patients with PRPH 2 mutation;^[19] our patient’s rapid progression of visual dysfunction would be atypical for a mutation in this gene as well as LORD or autosomal dominant retinitis pigmentosa. Therefore, molecular genetic testing was not pursued. The presence of ARAs is supportive evidence for a diagnosis of AIR.^[2] Anti-enolase antibody is reported to be associated with central visual loss, and in some cases, both cone and rod functions were similarly affected as in our patient.^[20] Without evidence of neoplasia, we believe our patient has npAIR. Periodic screening for malignancy will still be conducted every year. Late onset of detectable malignancy has previously been reported.^[5]

Our patient had painless subacute visual field loss, pigmentary retinopathy, isoelectric ERG responses, and OCT findings, which show loss of the outer retinal segment and thinning of the retina, consistent with previous reports of AIR.^[21,22] The OCT of both eyes

is severe. The image quality of our patient's OCT is only fair and we believe only some healthy-surviving photoreceptors would be able to give patient-compatible visions, which OCT may fail to show. FAF in our patient initially showed diffuse intense hyperautofluorescent flecks throughout the posterior pole without the more characteristic easily discernible perifoveal ring of hydroxychloroquine toxicity. Follow-up FAF showed new foveal hyperautofluorescence and RPE mottling. To our knowledge, there are only three prior reports regarding FAF in AIR which both of which showed a hyperautofluorescent ring in the parafoveal region.^[21,23,24] Although this pattern is similar to that seen in retinitis pigmentosa, the authors suggest that the hyperautofluorescent ring is less intense than seen in patients with retinitis pigmentosa because of the shorter duration in course of their patients' disease.^[23] Our patient's FAF findings are different from the prior studies perhaps because our patient had more severe retinal damage compared to those patients. Areas of fundus hyperautofluorescence were reported to correspond to the destruction of the outer retinal structure.^[21] In addition, we recently found an interesting report by Polascik *et al.*^[24] They reported a case of AIR in a patient not taking hydroxychloroquine who shares many common features with our patient (good central vision, attenuated retinal vessels, parafoveal hyperautofluorescence, and loss of outer retinal layers). This also supports AIR although we acknowledge this could share similar features with very late-staged hydroxychloroquine retinopathy. The visual field test in our patient is much more severe than patients in the prior studies. Advanced field loss in this patient may be secondary to delayed detection of AIR by a misattribution of her symptoms to hydroxychloroquine. The high cumulative dose of hydroxychloroquine might also compound the damage to the retinal photoreceptors. Perhaps the most convincing factor that supports an autoimmune role for her visual loss is the worsening of her vision when her mycophenolate mofetil was discontinued because of fractures and associated surgery.

Hydrochlorothiazide, her antihypertensive medication, has been reported to be associated with retinopathy.^[25] The reported symptoms are central scotoma and metamorphopsia. The fundus photograph in that report shows a subfoveal yellowish-gray lesion in the acute phase and a flat partially pigmented retinal pigment epithelial scar 6 months later. Our patients did not share any characteristics with hydrochlorothiazide retinopathy.

There are many causes of severe visual loss in SLE including lupus retinopathy, vascular complications, and hydroxychloroquine toxicity. npAIR is a rare cause of visual loss in SLE. Our case suggests that AIR should be

considered in the differential diagnosis of rapid, severe visual loss in patients rather than the complications of hydroxychloroquine treatment. In the future, perhaps immunohistochemistry studies may be helpful to elucidate the roles of retinal antibodies in similar patients and help differentiate AIR from hydroxychloroquine toxicity.

Financial support and sponsorship

This study was funded in part by the Foerderer Fund (AVL) and the Robison D. Harley, MD Endowed Chair in Pediatric Ophthalmology and Ocular Genetics (AVL).

Conflicts of interest

There are no conflicts of interest.

References

1. Cao X, Bishop RJ, Forooghian F, Cho Y, Fariss RN, Chan CC. Autoimmune retinopathy in systemic lupus erythematosus: Histopathologic features. *Open Ophthalmol J* 2009;3:20-5.
2. Grange L, Dalal M, Nussenblatt RB, Sen HN. Autoimmune retinopathy. *Am J Ophthalmol* 2014;157:266-272.e1.
3. Read RW. Clinical mini-review: Systemic lupus erythematosus and the eye. *Ocul Immunol Inflamm* 2004;12:87-99.
4. Melles RB, Marmor MF. The risk of toxic retinopathy in patients on long-term hydroxychloroquine therapy. *JAMA Ophthalmol* 2014;132:1453-60.
5. Braithwaite T, Vugler A, Tufail A. Autoimmune retinopathy. *Ophthalmologica* 2012;228:131-42.
6. Adamus G, Ren G, Weleber RG. Autoantibodies against retinal proteins in paraneoplastic and autoimmune retinopathy. *BMC Ophthalmol* 2004;4:5.
7. Heckenlively JR, Fawzi AA, Oversier J, Jordan BL, Aptsiauri N. Autoimmune retinopathy: Patients with antirecoverin immunoreactivity and panretinal degeneration. *Arch Ophthalmol* 2000;118:1525-33.
8. Adamus G. Autoantibody targets and their cancer relationship in the pathogenicity of paraneoplastic retinopathy. *Autoimmun Rev* 2009;8:410-4.
9. Heckenlively JR, Ferreyra HA. Autoimmune retinopathy: A review and summary. *Semin Immunopathol* 2008;30:127-34.
10. Shimazaki K, Jirawuthiworavong GV, Heckenlively JR, Gordon LK. Frequency of anti-retinal antibodies in normal human serum. *J Neuroophthalmol* 2008;28:5-11.
11. Forooghian F. The uncertainty regarding antiretinal antibodies. *JAMA Ophthalmol* 2015;133:744-5.
12. Marmor MF, Kellner U, Lai TY, Lyons JS, Mieler WF; American Academy of Ophthalmology. Revised recommendations on screening for chloroquine and hydroxychloroquine retinopathy. *Ophthalmology* 2011;118:415-22.
13. Marmor MF. Comparison of screening procedures in hydroxychloroquine toxicity. *Arch Ophthalmol* 2012;130:461-9.
14. Rodriguez-Padilla JA, Hedges TR 3rd, Monson B, Srinivasan V, Wojtkowski M, Reichel E, *et al.* High-speed ultra-high-resolution optical coherence tomography findings in hydroxychloroquine retinopathy. *Arch Ophthalmol* 2007;125:775-80.
15. Melles RB, Marmor MF. Pericentral retinopathy and racial differences in hydroxychloroquine toxicity. *Ophthalmology* 2015;122:110-6.
16. Michaelides M, Stover NB, Francis PJ, Weleber RG. Retinal toxicity associated with hydroxychloroquine and chloroquine: Risk

- factors, screening, and progression despite cessation of therapy. *Arch Ophthalmol* 2011;129:30-9.
17. Taylor R, Elaraoud I, Good P, Hope-Ross M, Scott RA. A case of severe hydroxychloroquine-induced retinal toxicity in a patient with recent onset of renal impairment: A review of the literature on the use of hydroxychloroquine in renal impairment. *Case Rep Ophthalmol Med* 2012;2012:182747.
 18. Jacobson SG, Cideciyan AV, Wright E, Wright AF. Phenotypic marker for early disease detection in dominant late-onset retinal degeneration. *Invest Ophthalmol Vis Sci* 2001;42:1882-90.
 19. Manes G, Guillaumie T, Vos WL, Devos A, Audo I, Zeitz C, *et al.* High prevalence of PRPH2 in autosomal dominant retinitis pigmentosa in France and characterization of biochemical and clinical features. *Am J Ophthalmol* 2015;159:302-14.
 20. Weleber RG, Watzke RC, Shults WT, Trzupek KM, Heckenlively JR, Egan RA, *et al.* Clinical and electrophysiologic characterization of paraneoplastic and autoimmune retinopathies associated with anti-nuclear antibodies. *Am J Ophthalmol* 2005;139:780-94.
 21. Pepple KL, Cusick M, Jaffe GJ, Mruthyunjaya P. SD-OCT and autofluorescence characteristics of autoimmune retinopathy. *Br J Ophthalmol* 2013;97:139-44.
 22. Abazari A, Allam SS, Adamus G, Ghazi NG. Optical coherence tomography findings in autoimmune retinopathy. *Am J Ophthalmol* 2012;153:750-6, 756.e1.
 23. Lima LH, Greenberg JP, Greenstein VC, Smith RT, Sallum JM, Thirkill C, *et al.* Hyperautofluorescent ring in autoimmune retinopathy. *Retina* 2012;32:1385-94.
 24. Polascik BA, Grewal DS, Jiramongkolchai K, Fekrat S. Choroidal thickness and en face optical coherence tomography imaging in autoimmune retinopathy. *Ophthalmic Surg Lasers Imaging Retina* 2016;47:362-5.
 25. Mauget-Fayssse M, Quaranta M, Francoz N, BenEzra D. Incidental retinal phototoxicity associated with ingestion of photosensitizing drugs. *Graefes Arch Clin Exp Ophthalmol* 2001;239:501-8.