


# Two Consecutive Ruptured Tubal Ectopic Pregnancies after Interval Bilateral Tubal Ligation

Moses Owiny <sup>1</sup>, Monica Okwir Acen<sup>1</sup>, Joram Okeng<sup>2</sup>, Oliver Anyeko Akello<sup>3</sup>

<sup>1</sup>Department of Obstetrics and Gynaecology, Lira University, Lira City, Uganda; <sup>2</sup>Department of Surgery, Lira University, Lira City, Uganda;

<sup>3</sup>Department of Nursing, Lira University, Lira City, Uganda

Correspondence: Moses Owiny, Department of Obstetrics and Gynaecology, Lira University, Lira City, Uganda, Tel +256 773 579 387, Email moswin90@gmail.com

**Background:** Bilateral tubal ligation (BTL) is an effective permanent method of birth control that is surgically performed to block the woman's fallopian tube and prevent the egg from meeting the sperm. It is preferred by women or couples who have achieved their reproductive potential and do not desire pregnancy. BTL carries a low risk of method failure with a subsequent pregnancy which is likely to be ectopic. We present a case of two consecutive ruptured tubal ectopic pregnancies following an interval BTL.

**Case Presentation:** A 40-year-old female, with 7 living children, who previously underwent an interval BTL, presented with acute abdominal pain for 2 days and amenorrhea for 6 weeks. She was stable but had generalized abdominal tenderness, guarding and rebound tenderness, and cervical motion tenderness. Her urine HCG was positive, and a trans-abdominal ultrasound scan revealed a tender echo-complex right adnexal mass, free fluid in the Cul-de-sac, and an empty uterine cavity, consistent with a ruptured right ectopic pregnancy. An emergency exploratory laparotomy was done with findings of a ruptured right distal tube containing products of conception, hemoperitoneum, and previous tubal ligation and left salpingectomy. A right total salpingectomy was done, and the excised right tube containing the mass was sent for histological examination, which revealed chorionic villi and hemorrhagic vascular decidual tissue in the fallopian tube, features suggestive of tubal ectopic pregnancy.

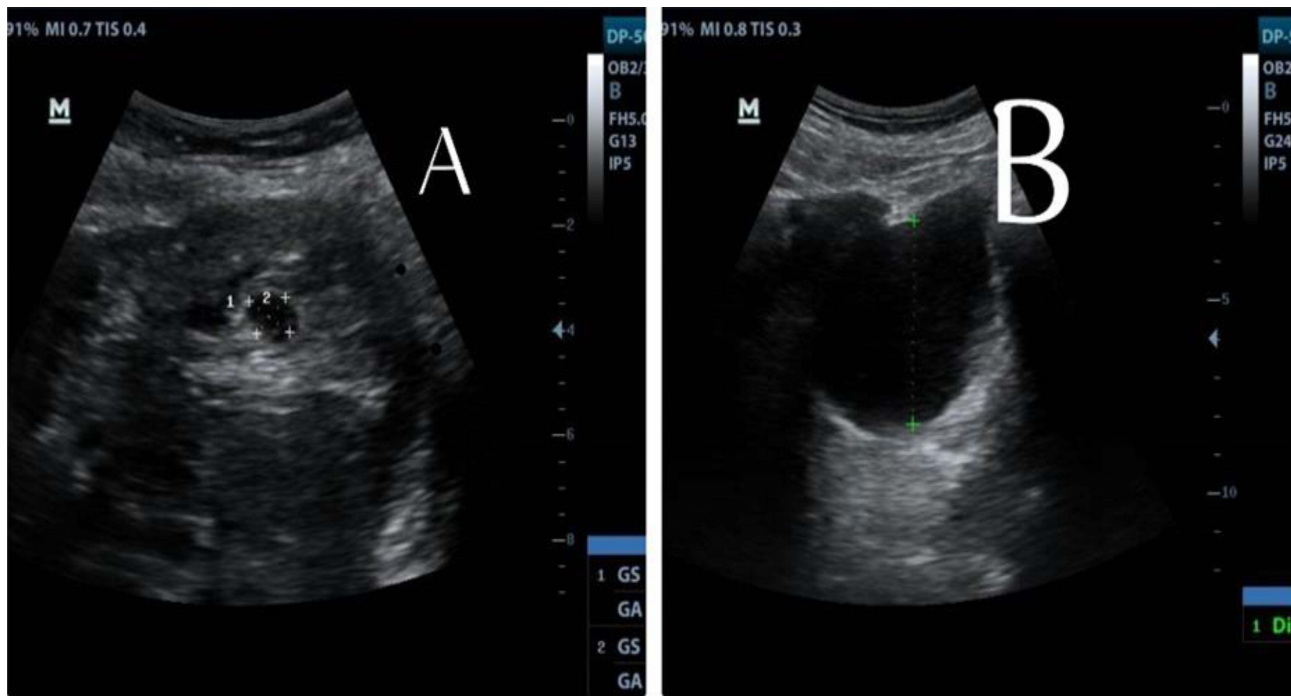
**Keywords:** ruptured, tubal, ectopic, pregnancy, interval, bilateral tubal ligation

## Background

Bilateral tubal ligation (BTL) is an effective permanent method of birth control preferred by women or couples who have achieved their reproductive potential and do not desire pregnancy.<sup>1</sup> It has a very low failure rate of less than 1%. However, failure is associated with a risk of ectopic pregnancy.<sup>2</sup> An ectopic pregnancy is a condition where the fertilized ovum implants outside the uterine cavity. Ectopic pregnancy is life threatening if not diagnosed and managed promptly.<sup>3</sup> The purpose of this case report therefore is to present a rare case of two consecutive ruptured tubal ectopic pregnancies following an interval BTL.

## Case Presentation

We present a 40-year-old female, a gravida-9 para-7+1, who previously underwent an interval bilateral tubal ligation (BTL) in December 2016 during a community outreach program, through a mini laparotomy. She had seven previous successful pregnancies and an ectopic pregnancy in October 2019, for which she had an exploratory laparotomy and salpingectomy done for a left-ruptured tubal ectopic pregnancy in November 2018. She presented at a university teaching hospital in northern Uganda on October 20, 2021, with acute abdominal pain for 2 days and amenorrhea for 6 weeks, with no vaginal bleeding. She was fully conscious, in pain, anxious, afebrile, and hemodynamically stable, with a pulse rate of 98 beats per minute and a blood pressure of 121/78 mmHg. She had generalized abdominal tenderness, guarding and rebound tenderness, and cervical motion tenderness. Laboratory investigations revealed a positive urine pregnancy (HCG) test and a hemoglobin level of 12.9 g/dL with normal platelet count. A trans-abdominal ultrasound scan revealed a tender echo-complex right adnexal mass, free fluid in the Cul-de-sac measuring 5.2 centimeters deep, and an empty uterine cavity (Figure 1). A diagnosis of ruptured right tubal ectopic pregnancy was made, and the patient was counseled



**Figure 1** Showing a trans abdominal ultrasound scan showing right adnexal mass (A) and free fluid in the Cul-de-sac (B).

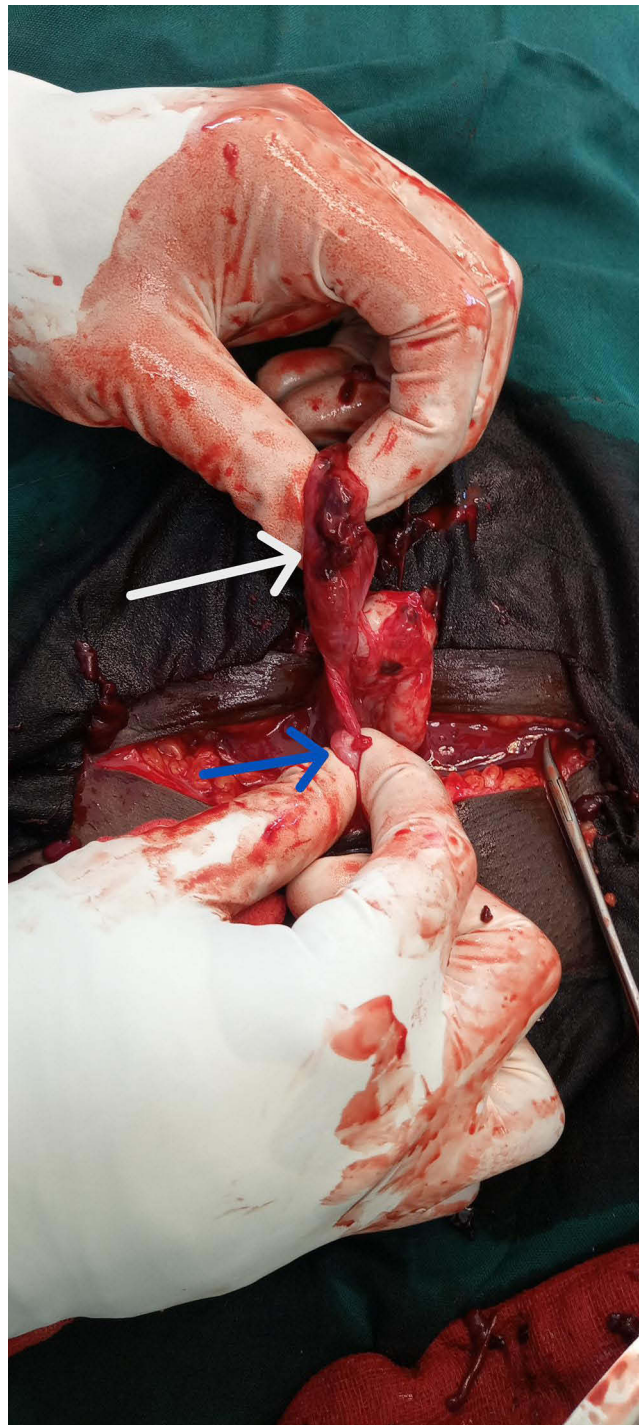and consented to an emergent exploratory laparotomy. On exploratory laparotomy, approximately 300 mL of blood were found in the peritoneal cavity. A ruptured right distal tube containing a well-circumscribed mass was also found. There was also evidence of a previous right tubal ligation and left salpingectomy with a normal uterus and ovaries (Figure 2). The blood was evacuated, and a right total salpingectomy was done. The excised right tube containing the mass (gestational product) was sent for histological examination. Histopathology revealed chorionic villi and hemorrhagic vascular decidual tissue in the fallopian tube, features suggestive of tubal ectopic pregnancy (Figure 3). Post-operative patient management was uneventful. However, the couple expressed their dismay about the two ectopic pregnancies and dissatisfaction with the previous BTL, as well as concerns about having sex in the future in fear of subsequent ectopic pregnancies. They were counseled to relieve their fears about sex and future ectopic pregnancies.

## Discussions

A previous pelvic surgery and a history of an ectopic pregnancy (EP) are well-known significant risk factors for subsequent EP. Clinical features of EP include pelvic pain and tubal rupture with hemoperitoneum.<sup>4,5</sup> These features are consistent with the clinical presentation of our case. Our case had a consecutive tubal ectopic contralateral to the previous ectopic following an interval BTL in a grand multiparous woman. An ipsilateral recurrent tubal ectopic following partial salpingectomy has been reported.<sup>6–8</sup> Ke et al reported an ampullary ectopic that followed a tubal ligation.<sup>9</sup> Three consecutive tubal pregnancies following partial salpingectomies have been documented.<sup>10,11</sup> Contralateral fertilization of ovum with migration across the peritoneum, tubal recanalization and transperitoneal migration of ovum or spermatozoon have been documented as possible explanations of pregnancies.<sup>12–15</sup> The latter possibly explains the mechanism of pregnancy in our case.

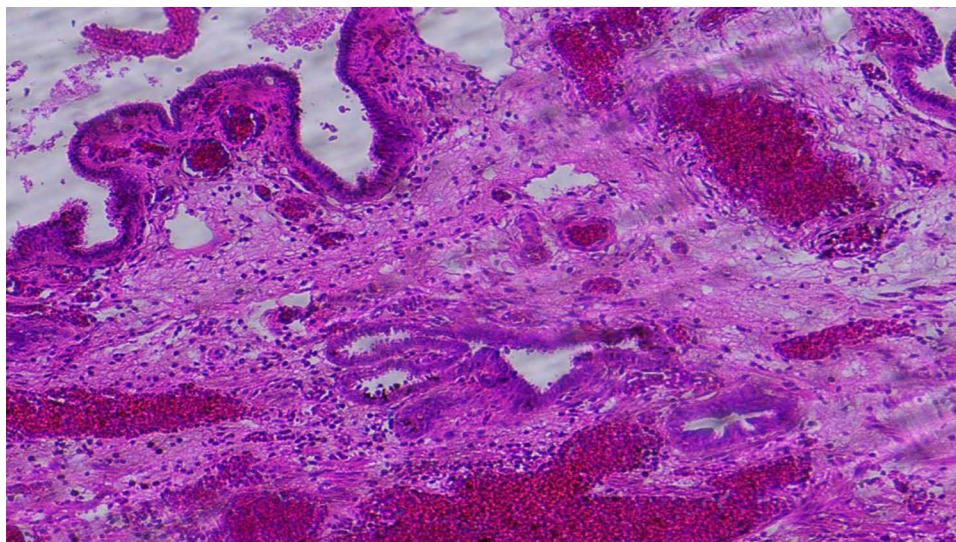
Majority of BTL failures seem to occur if done through a mini laparotomy and in primary health care settings.<sup>16</sup> Our case had the BTL done at a community outreach setting through a mini laparotomy which could have increased the chances of failure.

Other methods of female sterilization like salpingectomy and hysteroscopic occlusion do have comparable surgical outcomes to BTL.<sup>17</sup>



**Figure 2** Showing laparotomy findings of ruptured distal tube containing products of gestation (white arrow) and stump from previous tubal ligation (blue arrow).

Laparoscopic approach to management of ectopic pregnancy in an hemodynamically stable patient like our case has been proven to be effective.<sup>18</sup> In our case, we did total salpingectomy through a laparotomy since the facility did not have laparoscopic equipment. Salpingectomy has been shown to reduce the risk of ovarian cancer.<sup>19,20</sup> This would be further beneficial in cases who have achieved their reproductive needs, like in our case.



**Figure 3** Histopathology showing chorionic villi and hemorrhagic vascular decidual tissue in the fallopian tube.

## Conclusion

Two consecutive ruptured tubal ectopic pregnancies may follow interval BTL, which is associated with maternal morbidity and client dissatisfaction in the BTL service. A complete salpingectomy of both tubes should be done in case a tubal ectopic pregnancy occurs after a BTL to prevent the occurrence of a tubal ectopic for a second time and to help reduce the risk of ovarian cancer.

## Data Sharing Statement

The information used and/or analyzed during the case are available from the corresponding author on reasonable request.

## Ethics Approval and Consent to Participate

No institutional approval was required to publish this case, as this case was identified during routine clinical care. The patient provided an informed written consent.

## Consent for Publication

The patient provided an informed written consent for this case and images to be published in a peer-reviewed journal.

## Acknowledgments

We acknowledge the emergency care staff and theater staff. The abstract of this paper was presented at the “Sexual and Reproductive Health: Informing Policy and Practice through Research and Preservice Training” The Centre for International Reproductive Health Training at the University of Michigan conference in Kigali 2022, as a poster presentation/conference talk with interim findings. The abstract of this paper (074 – Two consecutive ruptured tubal ectopic pregnancies after interval bilateral tubal ligation: a case report) was published in “Poster Abstracts” in CIRHT The Centre for International Reproductive Health Training at the University of Michigan: <https://cirht.med.umich.edu/abstracts-2/>

## Author Contributions

Moses Owiny contributed to the work reported, in the conception, study design, execution, acquisition of data, analysis and interpretation as well as drafting, revising or critically reviewing the article. Oliver Akello Anyeko, Monica Acen Okwir and Joram Okeng contributed to data acquisition, execution, analysis and interpretation, manuscript writing and reviewing the article. All the authors gave final approval of the version to be published; have agreed on the journal to which the article has been submitted; and agree to be accountable for the work.

## Funding

There was no funding for this work.

## Disclosure

The authors do not have any conflicting interests to declare for this work.

## References

1. Marino S, Canela CD, Nama N. Tubal Sterilization. *StatPearls*. StatPearls Publishing; 2024. Available from. <http://www.ncbi.nlm.nih.gov/books/NBK470377/>. Accessed February 3, 2024.
2. Peterson HB, Xia Z, Hughes JM, Wilcox LS, Tylor LR, Trussell J. The risk of pregnancy after tubal sterilization: findings from the U.S. collaborative review of sterilization. *Am J Obstet Gynecol*. 1996;174(4):1161–1168. doi:10.1016/s0002-9378(96)70658-0
3. Creanga AA, Syverson C, Seed K, Callaghan WM. Pregnancy-related mortality in the United States, 2011–2013. *Obstet Gynecol*. 2017;130(2):366–373. doi:10.1097/AOG.0000000000002114
4. Escobar-Padilla B, Perez-López CA, Martínez-Puon H. Factores de riesgo y características clínicas del embarazo ectópico [Risk factors and clinical features of ectopic pregnancy]. *Rev Medica Inst Mex Seguro Soc*. 2017;55(3):278–285. Spanish.
5. Gaskins AJ, Missmer SA, Rich-Edwards JW, Williams PL, Souter I, Chavarro JE. Demographic, lifestyle, and reproductive risk factors for ectopic pregnancy. *Fertil Steril*. 2018;110(7):1328–1337. doi:10.1016/j.fertnstert.2018.08.022
6. Tan TL, Elashry A, Tischner I, Jolaoso A. Lightning does strike twice: recurrent ipsilateral tubal pregnancy following partial salpingectomy for ectopic pregnancy. *J Obstet Gynaecol*. 2007;27(5):534–535. doi:10.1080/01443610701467606
7. Samiei-Sarir B, Diehm C. Recurrent ectopic pregnancy in the tubal remnant after salpingectomy. *Case Rep Obstet Gynecol*. 2013;2013:753269. doi:10.1155/2013/753269
8. Fischer S, Keirse MJ. When salpingectomy is not salpingectomy-ipsilateral recurrence of tubal pregnancy. *Obstet Gynecol Int*. 2009;2009:524864. doi:10.1155/2009/524864
9. K X, H L, Jf Z, Yh L, W F. Rare occurrence of left ampullary ectopic pregnancy after ligation of the left fallopian tube: a case report. *Int J Womens Health*. 2023;15. doi:10.2147/IJWH.S417186
10. Mathew M, Kumari R, Gowri V. Three consecutive ipsilateral tubal pregnancies. *Int J Gynaecol Obstet off Organ Int Fed Gynaecol Obstet*. 2002;78(2):163–164. doi:10.1016/s0020-7292(02)00134-0
11. Iwahashi N, Deguchi Y, Horiuchi Y, Ino K, Furukawa K. A third surgically managed ectopic pregnancy after two salpingectomies involving the opposite tube. *Case Rep Obstet Gynecol*. 2017;2017:1653529. doi:10.1155/2017/1653529
12. Abraham C, Seethappan V. Spontaneous live recurrent ectopic pregnancy after ipsilateral partial salpingectomy leading to tubal rupture. *Int J Surg Case Rep*. 2015;7C:75–78. doi:10.1016/j.ijscr.2014.12.028
13. Liang C, Li X, Zhao B, Du Y, Xu S. Demonstration of the route of embryo migration in retroperitoneal ectopic pregnancy using contrast-enhanced computed tomography. *J Obstet Gynaecol Res*. 2014;40(3):849–852. doi:10.1111/jog.12233
14. Rimdusit P. Ectopic pregnancy after tubal sterilization. Mechanism of recanalization. A case report. *J Med Assoc Thail Chotmaiht Thangphaet*. 1982;65(2):101–105.
15. First A. Transperitoneal migration of ovum or spermatozoon. *Obstet Gynecol*. 1954;4(4):431–434.
16. Date SV, Rokade J, Mule V, Dandapanavar S. Female sterilization failure: review over a decade and its clinicopathological correlation. *Int J Appl Basic Med Res*. 2014;4(2):81–85. doi:10.4103/2229-516X.136781
17. Marchand GJ, Masoud AT, King AK, et al. Salpingectomy, tubal ligation and hysteroscopic occlusion for sterilization. *Minerva Obstet Gynecol*. 2022;74(5):452–461. doi:10.23736/S2724-606X.22.05134-X
18. Di Lorenzo G, Romano F, Mirenda G, et al. “Nerve-sparing” laparoscopic treatment of parametrial ectopic pregnancy. *Fertil Steril*. 2021;116(4):1197–1199. doi:10.1016/j.fertnstert.2021.05.106
19. Daly MB, Drescher CW, Yates MS, et al. Salpingectomy as a means to reduce ovarian cancer risk. *Cancer Prev Res Phila Pa*. 2015;8(5):342–348. doi:10.1158/1940-6207.CAPR-14-0293
20. Stone R, Sakran JV, Long Roche K. Salpingectomy in Ovarian Cancer Prevention. *JAMA*. 2023;329(23):2015–2016. doi:10.1001/jama.2023.6979

International Medical Case Reports Journal

Dovepress

Publish your work in this journal

The International Medical Case Reports Journal is an international, peer-reviewed open-access journal publishing original case reports from all medical specialties. Previously unpublished medical posters are also accepted relating to any area of clinical or preclinical science. Submissions should not normally exceed 2,000 words or 4 published pages including figures, diagrams and references. The manuscript management system is completely online and includes a very quick and fair peer-review system, which is all easy to use. Visit <http://www.dovepress.com/testimonials.php> to read real quotes from published authors.

Submit your manuscript here: <https://www.dovepress.com/international-medical-case-reports-journal-journal>