

Scientific Article

Prostatic Artery Embolization Is Safe and Effective for Medically Recalcitrant Radiation-Induced Prostatitis



Nainesh Parikh, MD, MBA,^a Edward Keshishian, MD,^a
Ayushman Sharma, MD,^a Monica Roca, MD,^a Brandon Manley, MD,^b
Michael Poch, MD,^b G. Daniel Grass, MD, PhD,^c
Javier Torres-Roca, MD,^c David Boulware, MS, MBA,^d
Peter Johnstone, MD,^c Michael Montejo, MD,^c Johnna Smith, ARNP,^a
Julio Pow-Sang, MD,^b and Kosj Yamoah, MD, PhD^{c,*}

Departments of ^aDiagnostic Imaging and Interventional Radiology, ^bGenitourinary Oncology, ^cRadiation Oncology, and ^dBiostatistics, H. Lee Moffitt Cancer Center & Research Institute, Tampa, Florida

Received 6 March 2020; accepted 12 March 2020

Abstract

Purpose: Chronic prostatitis/chronic pelvic pain syndrome (CP/CPPS) represents 90% of all chronic prostatitis cases and may occur after radiation therapy (RT) for localized prostate cancer. Medical therapy is effective in approximately 50% of cases, with no therapy demonstrating consistent efficacy in refractory cases. Prostatic artery embolization (PAE) is effective in men with lower urinary tract symptoms and benign prostatic hyperplasia. We report clinical improvement after PAE in a case series of men with CP/CPPS after RT.

Methods and Materials: Nine men (median age 72 years; range, 61-83 years) with CP/CPPS after RT for prostate cancer underwent PAE. Baseline International Prostate Symptom Score was recorded in 5 patients (median 23; range, 4-26), Chronic Prostatitis Symptom Index score in 6 patients (median 22.5; range, 6-34), and quality of life (QoL) score in 8 patients (median 5; range, 2-6). Median baseline prostate volume was 49 cm³ (range, 22-123 cm³). Patients were followed up at 6 and 12 weeks with QoL, International Prostate Symptom Score, and/or Chronic Prostatitis Symptom Index score and magnetic resonance imaging.

Results: Technical success (ie, bilateral embolization) was achieved in 78% (n = 7) of patients with the other 2 patients having undergone unilateral embolization with no major complications. Clinical success was seen in 89% (n = 8) of patients and QoL improved in 78% (n = 7) during the follow-up period.

Conclusion: CP/CPPS after RT for localized prostate cancer is a highly morbid condition, with medical therapy successful in only 50% of cases. PAE may be a successful therapy for medically recalcitrant CP/CPPS, and further studies are necessary to understand the best patient selection and scenario for PAE in the setting of CP/CPPS.

© 2020 The Author(s). Published by Elsevier Inc. on behalf of American Society for Radiation Oncology. This is an open access article under the CC BY-NC-ND license (<http://creativecommons.org/licenses/by-nc-nd/4.0/>).

Disclosures: none.

Research data are stored in an institutional repository and will be shared upon request to the corresponding author.

* Corresponding author: Kosj Yamoah, MD, PhD; E-mail: kosj.yamoah@moffitt.org

<https://doi.org/10.1016/j.adro.2020.03.015>

2452-1094/© 2020 The Author(s). Published by Elsevier Inc. on behalf of American Society for Radiation Oncology. This is an open access article under the CC BY-NC-ND license (<http://creativecommons.org/licenses/by-nc-nd/4.0/>).

Introduction

The National Institutes of Health categorizes prostatitis into 4 entities based on acuity and etiology.¹ Types I and II

are acute and chronic bacterial prostatitis, respectively. Types III and IV are nonbacterial with the presence or absence of symptoms, respectively. Prevalence of chronic prostatitis is 1.8% to 8.2%¹ with a range of urinary and sexual symptoms.² Type III, Chronic prostatitis/chronic pelvic pain syndrome (CP/CPPS), represents 90% of all prostatitis cases^{1,3} and results from an inciting agent causing prostatic damage and pelvic floor pain. Lower urinary tract symptoms (LUTS) are a predisposing factor.⁴

Radiation therapy (RT) remains a mainstay of definitive therapy for localized prostate cancer (PCa). Management of chronic genitourinary (GU) toxicity from RT is challenging, with \geq grade 3 GU toxicities reaching 33%.⁵ Men with larger prostates have higher rates of chronic GU toxicity, with CP/CPPS occurring in patients receiving a high central urethral dose.⁶ Treatment is challenging and focused on clearance of underlying infection, pain control, and alleviating LUTS.⁷ However, clinical efficacy of medical management is variable,^{4,8} and effectiveness of emerging therapies like prostate artery embolization (PAE) for CP/CPPS should be investigated.

PAE has been used successfully to significantly reduce symptoms from benign prostatic hyperplasia.⁹ We report a case series of patients who had PAE for refractory CP/CPPS after RT.

Methods and Materials

Study design

This retrospective review was approved by the institutional review board, and requirement for informed consent was waived. Consecutive patients who underwent PAE for medically refractory CP/CPPS after definitive RT for localized PCa between April 2017 and September 2019 were included. Medical records were reviewed to collect data on technical and clinical success and complications. Technical success was defined as bilateral prostatic artery embolization. Complications were classified as either major or minor according to the guidelines of the Society of Interventional Radiology Standards of Practice Committee.¹⁰ Clinical success was defined as any improvement in quality of life (QoL) score, or at least 1 category improvement on Chronic Prostatitis Symptom Index (CPSI) score or International Prostate Symptom Score (IPSS) at either 6 or 12 weeks. Volume reduction on cross-sectional imaging at the same time points was recorded. The endpoint of the study was to assess clinical efficacy of PAE at 6 and 12 weeks.

Patient population

Nine men (median age 72 years; range, 61–83 years) with localized PCa (median Gleason score 7; range, 6–9;

median pretherapy prostate-specific antigen 6.4; range, 2.2–25.1) who had undergone definitive RT (Table 1) underwent PAE for refractory CP/CPPS. Baseline IPSS score was recorded in 5 patients (median 23; range, 4–26), CPSI score in 6 patients (median 22.5; range, 6–34), and QoL score in 8 patients (median 5; range, 2–6); 1 patient was excluded from all 3 scores due to indwelling Foley catheter. One patient was doing intermittent self-catheterization at baseline. Baseline median prostate volume was 49 cm³, with a range of 22 to 123 cm³.

Embolization technique and follow-up

All patients had Foley catheter placement, were given ciprofloxacin 400 mg intravenously, were admitted for overnight observation, and were continued for 4 days on an antibiotic, muscarinic antagonist and urinary tract analgesic.

Via right transfemoral (n = 7) or left transradial (n = 2) approach, a guide catheter was placed into the anterior division of an internal iliac artery, the prostatic artery was selectively catheterized, and 4-dimensional computed tomography confirmed appropriate position. Embolization was performed using dilute 300 to 500 micron Embospheres (Merit Medical Systems; South Jordan, UT) until stasis was achieved (Fig 1). This was repeated on the contralateral side if possible. Patients were followed up at 6 and 12 weeks, with QoL, IPSS, and/or CPSI and magnetic resonance imaging (Fig 2).

Statistical analysis

Statistical analyses were performed using SAS version 9.4 (Cary, NC). Descriptive characteristics for the patient cohort were presented and the Wilcoxon signed rank test for paired differences was used. A *P* value < .05 was considered statistically significant. We did not correct for multiple testing.

Results

Technical success was achieved in 78.8% (n = 7) of patients. The other 2 patients underwent unilateral embolization due to severe atherosclerotic disease; however, they were not excluded from the analysis because unilateral embolization has demonstrated positive clinical outcome.¹¹ Median PAE fluoroscopy time was 29.7 minutes (range, 9.4–50.6 minutes) and dose was 3658.81 mGy (range, 207.12–5601.58). No major complications were encountered. Two (22%) patients experienced bladder spasms, which were relieved with medication and resolved at 1 week.

Clinical success at 6 and at 12 weeks was seen in 88.8% (n = 8) of patients. One patient demonstrating

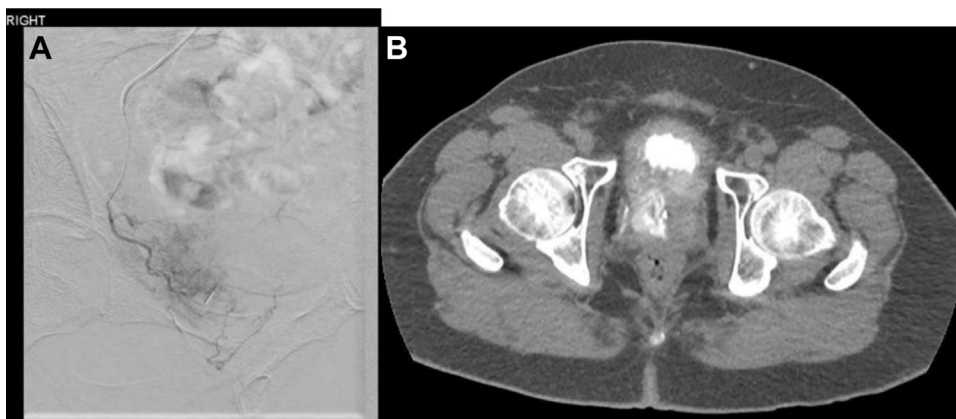


Figure 1 Prostatic artery embolization. (A) Digital subtraction angiogram image shows hypertrophied right prostatic artery (RPA) arising from the anterior division internal iliac artery via common vesicoprostatic trunk. (B) Limited contrast enhanced computed tomography (CT) confirms RPA catheterization and no collateral flow.

clinical failure underwent unilateral embolization and has only been followed up at 6 weeks at the time of this analysis. The other patient who underwent unilateral embolization achieved modest clinical success. Two (22%) of the bilateral embolization patients were successfully weaned off of catheter dependence after the procedure; 1 was Foley catheter dependent (off at 12 weeks) and the other was straight catheter dependent (off at 6 weeks).

Median IPSS improvement at 6 weeks ($n = 4$) was 5.50 points ($P = .125$) and 5.00 points ($P = .0625$) at 12 weeks ($n = 5$). Median CPSI improvement at 6 weeks ($n = 6$) was 10.50 points ($P = .0313$) and 9.00 points ($P = .0313$) at 12 weeks ($n = 6$). QoL improvement at 6 weeks ($n = 8$) was 1.00 ($P = .125$) and 1.50 ($P = .0156$) at 12 weeks ($n = 8$). Prostate volume reduction was 8.00 cm^3 ($P = .0156$) at 6 weeks ($n = 8$) and 11.85 cm^3 ($P = .0313$) at 12 weeks ($n = 6$) (Table 2).

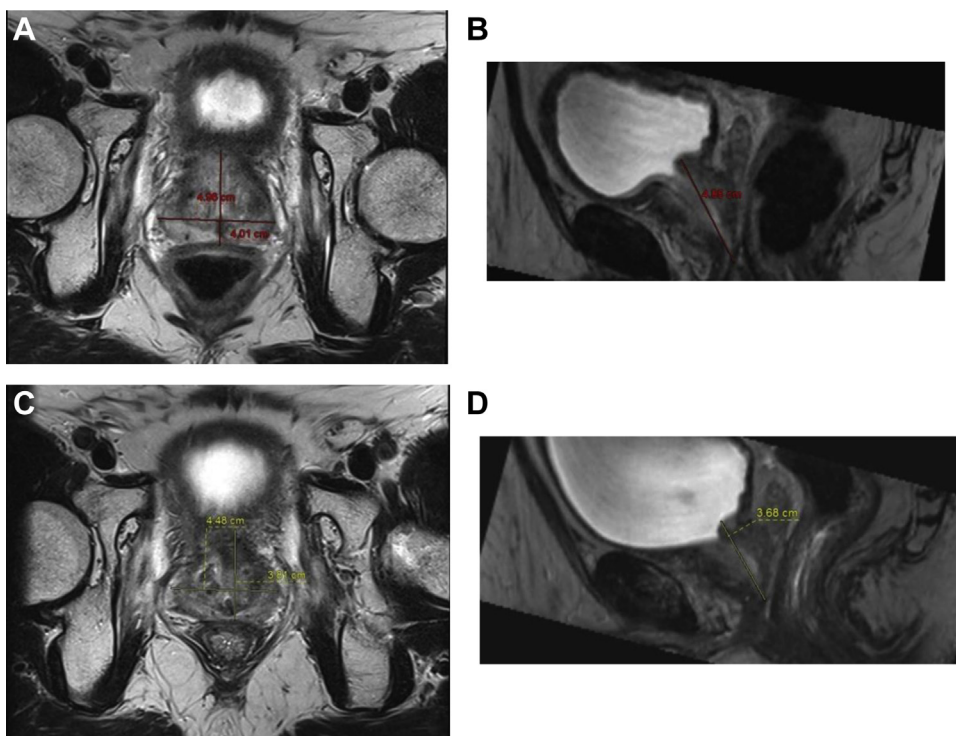


Figure 2 Postprostatic artery embolization (PAE) prostate volume (PV) reduction. (A, B) Patient number 2 axial and sagittal T2 images before PAE. PV = 51 cm^3 . (C, D) Patient number 2 axial and sagittal T2 images 12 weeks post-PAE. PV = 33 cm^3 (35% decrease).

Table 1 Baseline patient characteristics

Patient	Age	Gleason score	Pretherapy PSA	Risk category	RT dose	RT target	Foley (F) or straight cath (SC) dependent	Baseline IPSS	Baseline CPSI	Baseline QoL	Baseline prostate volume (cm ³)
PN 1	83	4 + 4 = 8	25.1	High	8100 cGy/45 fx	Prostate and SV	F	N/A*	N/A*	N/A*	31.6
PN 2	69	3 + 4 = 7	6.35	Intermediate	7020 cGy/26 fx	Prostate and SV	N	26	N/A	5	52
PN 3	75	4 + 3 = 7	2.2	Intermediate	N/A [†]	Prostate and SV	N	7	6	2	74
PN 4	66	3 + 4 = 7	20.8	High	7800 cGy/39 fx	Prostate and SV	N	4	N/A	6	65
PN 5	69	3 + 3 = 6	3.9	Low	8100 cGy/45 fx	Prostate and SV	N	23	19	5	22
PN 6	85	4 + 4 = 8	9.7	High	HDR [‡] + 4500 cGy/25 fx	Prostate and SV	N	23	20	3	44
PN 7	61	4 + 5 = 9	6.4	High	4500 cGy/25 fx (prostate) 3600 cGy/20 fx (pelvis and SV)	Prostate, SV, and sacrum	N	N/A	34	6	46
PN 8	72	3 + 4 = 7	5.7	Low-intermediate	7020 cGy/26 fx	Prostate and SV	SC	N/A	25	4	122.9
PN 9	77	4 + 5 = 9	6.86	High	7920 cGy/44 fx	Prostate and SV	N	N/A	30	5	25

Abbreviations: CPSI = Chronic Prostatitis Symptom Index; IPSS = International Prostate Symptom Score; N = no catheterization; PSA = prostate-specific antigen; QoL = quality of life; RT = radiation therapy; SV = seminal vesicles.

* On Foley catheter.

[†] Retention after 3 treatments of RT, so patient stopped.

[‡] Referred from outside institution, high dose rate dose unknown.

Table 2 Change from baseline after prostatic artery embolization

Variable	n	Median change (range)	P value
IPSS			
6 wk	4	−5.50 (−9.00 to −4.00)	0.125
12 wk	4	−5.00 (−13.00 to −3.00)	0.0625
CPSI			
6 wk	6	−10.50 (−24.00 to −1.00)	0.0313
12 wk	6	−9.00 (−27.00 to −5.00)	0.0313
QoL			
6 wk	8	1.00 (0-6.00)	0.125
12 wk	8	1.50 (0-6.00)	0.0156
Prostate volume (cm ³)			
6 wk	8	−8.00 (−24.7 to 0.40)	0.0156
12 wk	6	−11.85 (−51.40 to −3.60)	0.0313

Abbreviations: CPSI = Chronic Prostatitis Symptom Index; IPSS = International Prostate Symptom Score; QoL = quality of life

Discussion

We demonstrate that PAE is safe and successful (up to 90%) in improving clinical symptoms and QoL (80%) in men who have CP/CPPS after RT for PCa.

Late grade 2 or higher GU toxicity from definitive RT for localized PCa can reach 33%.⁵ Medical therapy is beneficial in up to 50% of patients¹² and is targeted at the 3 “A”s of CP/CPPS management: anti-inflammatories, antibiotics, and alpha-blockers. Although other therapies for these patients have been reported (eg, transurethral prostatic injection of onabotulinumtoxin A), none have demonstrated large-scale clinical benefit.¹³

PAE is effective for men with LUTS from benign prostatic hyperplasia¹⁴ and is being studied in the setting of localized PCa.^{15,16} No study has studied PAE for CP/CPPS. The current study provides baseline clinical evidence that PAE is an effective treatment option for men with medically refractory CP/CPPS after definitive RT for localized PCa. Clinical success was seen in 88% of patients; both patients who were catheter dependent were successfully taken off by 12 weeks. Most importantly, QoL for these men improved significantly at 12 weeks (71% of patients).

The present study has inherent limitations, including small sample size and retrospective assessments. Further analysis of these patients is necessary to understand (1) symptom severity before RT, (2) symptom severity after RT, and (3) efficacy of PAE on LUTS and CP/CPPS. Therefore, large scale studies are necessary to understand the efficacy of PAE for management of medically refractory CP/CPPS.

Conclusions

PAE may be a safe and effective treatment for medically refractory CP/CPPS following definitive RT for localized PCa. Further studies are necessary to understand the best patient selection and scenario for the PAE in the setting of CP/CPPS.

References

- Krieger JN, Nyberg L Jr, Nickel JC. NIH consensus definition and classification of prostatitis. *JAMA*. 1999;282:236-237.
- Holt JD, Garrett WA, McCurry TK, Teichman JMH. Common questions about chronic prostatitis. *Am Fam Physician*. 2016;93:290-296.
- de la Rosette JJ, Hubregtse MR, Meuleman EJ, et al. Diagnosis and treatment of 409 patients with prostatitis syndromes. *Urology*. 1993;41:301-307.
- Anothaisintawee T, Attia J, Nickel JC, et al. Management of chronic prostatitis/chronic pelvic pain syndrome: A systematic review and network meta-analysis. *JAMA*. 2011;305:78-86.
- Ohri N, Dicker AP, Showalter TN. Late toxicity rates following definitive radiotherapy for prostate cancer. *Can J Urol*. 2012;19:6373-6380.
- Hsu IC, Hunt D, Straube W, et al. Dosimetric analysis of radiation therapy oncology group 0321: The importance of urethral dose. *Pract Radiat Oncol*. 2014;4:27-34.
- Nickel JC. Prostatitis. *Can Urol Assoc J*. 2011;5:306-315.
- Cohen JM, Fagin AP, Hariton E, et al. Therapeutic intervention for chronic prostatitis/chronic pelvic pain syndrome (CP/CPPS): A systematic review and meta-analysis. *PLoS One*. 2012;7, e41941.
- Gao YA, Huang Y, Zhang R, et al. Benign prostatic hyperplasia: Prostatic arterial embolization versus transurethral resection of the prostate—a prospective, randomized, and controlled clinical trial. *Radiology*. 2013;270:920-928.
- Khalilzadeh O, Baerlocher MO, Shyn PB, et al. Proposal of a new adverse event classification by the Society of Interventional Radiology Standards of Practice Committee. *J Vasc Interv Radiol*. 2017;28:1432-1437.
- Bilhim T, Pisco J, Rio Tinto H, et al. Unilateral versus bilateral prostatic arterial embolization for lower urinary tract symptoms in patients with prostate enlargement. *Cardiovasc Intervent Radiol*. 2013;36:403-411.
- Thakkinstian A, Attia J, Anothaisintawee T, Nickel JC. α -blockers, antibiotics and anti-inflammatories have a role in the management of chronic prostatitis/chronic pelvic pain syndrome. *BJU Int*. 2012;110:1014-1022.
- Smith CP. Male chronic pelvic pain: An update. *Indian J Urol*. 2016;32:34-39.
- Bagla S, Martin CP, van Breda A, et al. Early results from a United States trial of prostatic artery embolization in the treatment of benign prostatic hyperplasia. *J Vasc Interv Radiol*. 2014;25:47-52.
- Malling B, Roder MA, Lindh M, Frevert S, Brasso K, Lonn L. Palliative prostate artery embolization for prostate cancer: A case series. *Cardiovasc Intervent Radiol*. 2019;42:1405-1412.
- Mordasini L, Hechelhammer L, Diener PA, et al. Prostatic artery embolization in the treatment of localized prostate cancer: A bicentric prospective proof-of-concept study of 12 patients. *J Vasc Interv Radiol*. 2018;29:589-597.