

# Cardiac Injuries: A Review of Multidetector Computed Tomography Findings

Ameya Jagdish Baxi,<sup>1,\*</sup> Carlos Restrepo,<sup>1</sup> Amy Mumbower,<sup>1</sup> Michael McCarthy,<sup>1</sup> and Katre Rashmi<sup>1</sup>

<sup>1</sup>Department of Radiology, University of Texas Health Science Center, San Antonio, USA

\*Corresponding author: Ameya Jagdish Baxi, Department of Radiology, University of Texas Health Science Center, San Antonio, USA. Tel: +1-2105675535, E-mail: baxi@uthscsa.edu

Received 2014 April 5; Revised 2014 June 12; Accepted 2014 July 12

## Abstract

Trauma is the leading cause of death in United States in the younger population. Cardiac trauma is common following blunt chest injuries and is associated with high morbidity and mortality. This study discusses various multidetector computed tomography (MDCT) findings of cardiac trauma. Cardiac injuries are broadly categorized into the most commonly occurring blunt cardiac injury and the less commonly occurring penetrating injury. Signs and symptoms of cardiac injury can be masked by the associated injuries. Each imaging modality including chest radiographs, echocardiography, magnetic resonance imaging and MDCT has role in evaluating these patients. However, MDCT is noninvasive; universally available and has a high spatial, contrast, and temporal resolution. It is a one stop shop to diagnose and evaluate complications of cardiac injury. MDCT is an imaging modality of choice to evaluate patients with cardiac injuries especially the injuries capable of causing hemodynamic instability.

**Keywords:** Cardiac Rupture, Traumatic; CT Scan, Spiral; Blunt Injuries; Contusions; Hemopericardium

## 1. Context

Trauma is the leading cause of death in United States in the younger population. Cardiac trauma is common following blunt chest injuries and is associated with high morbidity and mortality (1). Signs and symptoms of cardiac injury depend on the severity of injury (2). In general they range from being asymptomatic to non-specific mild chest pain or chest discomfort, shortness of breath, anxiety, and cyanosis, to life threatening arrhythmias and hemodynamic instability secondary to cardiac tamponade and myocardial wall rupture (3). Due to wide symptomatology, the diagnosis of cardiac injury can be challenging. The problem is further compounded as signs and symptoms can be masked by the associated other injuries. Nevertheless, morbidity and mortality can be reduced if an accurate and timely diagnosis and treatment of cardiac injury its complications can be made (4). Therefore it is essential to evaluate and screen patients with suspected cardiac injury.

## 2. Evidence Acquisition

In this article, we discuss the pathophysiology of cardiac trauma and review important multidetector computed tomography (MDCT) findings.

### 2.1. Classification of Cardiac Injuries

In general, there are two broad categories of cardiac in-

juries depending upon the underlying mechanism. Penetrating and the more common non-penetrating (blunt injury). Compared with penetrating chest injuries, cardiac injury may be overlooked in blunt trauma, especially when associated with head or abdominal injury (5, 6).

#### 2.1.1. Blunt Cardiac Injury (BCI)

Blunt thoracic injuries are the spectrum of injuries most commonly caused by motor vehicle collisions resulting in either direct blow to the chest or by deceleration compression of the heart between sternum and spine (7). The other common causes include crush injuries, sport injuries and assault injuries (8). The heart can also be injured indirectly from upward displacement of abdominal viscera in abdominal injuries or from hydraulic effect of increased venous return (9).

BCI is the most common form of cardiac injury and may range from minimal concussion to cardiac rupture and death (10-12). In concussion, there is no cellular, morphological, or chemical abnormality. It may manifest as arrhythmia or segmental regional wall motion abnormalities (13).

Cardiac rupture is the most serious form of BCI (14). It may cause sudden death due to cardiac tamponade and or associated hemodynamic alterations from hemorrhage (15-17). Commotio cordis (disruption of heart

rhythm that occurs as a result of a blow in precordial region and can be lethal), traumatic cardiac herniations and valvular ruptures can also be seen with BCI, but are much less common (18-20).

### 2.1.2. Penetrating Injuries (PI)

Though less common than BCI, mortality after penetrating cardiac injuries is significantly higher. One study reported a mortality rate of up to 40% when the left ventricle and the coronary arteries were injured (21-23). Patients can be asymptomatic or may present with signs and symptoms of hemopericardium, pneumopericardium, cardiac rupture or pericardial tamponade (24, 25). In the setting of PI, the presence of cardiac tamponade, right ventricular injury, and single chamber injury have been found to be associated with improved survival (26, 27).

## 2.2. Imaging of Cardiac Injury

Evaluation of cardiac injury requires a multidisciplinary approach (28) and includes a thorough physical examination, chest radiographs, screening with cardiac biomarkers like creatine kinase (CK-MB), troponin I or T, transthoracic and transesophageal echocardiography, Focused assessment with sonography, radionuclide imaging studies, contrast enhanced multidetector computed tomography and cardiac magnetic resonance imaging (29-31).

### 2.2.1. Chest Radiographs

Chest radiograph is usually the first imaging test accomplished in patients with cardiac injury. It can reveal rib/sternal fractures and pericardial effusion. They can diagnose an enlarged heart, pericardial fluid, and pneumopericardium. However, chest radiographs are insensitive to demonstrate important anatomical details and altered hemodynamics of cardiac injury for which usually cross-sectional imaging is required.

### 2.2.2. Transthoracic Echocardiography (TTE) and Transesophageal Echocardiography (TEE)

TTE and TEE can detect wall motion abnormalities, myocardial contusions, valvular disruptions, pericardial effusions and traumatic ventricular septal defect (VSD) (32-35). Though TTE is a noninvasive bedside procedure, it is not recommended for stable patients with normal blood pressure and electrocardiogram (36, 37). Also its use is limited in patients with spine injury, chest tubes, mechanical ventilators and for evaluating the mediastinum and chest wall (34, 38). TEE has better sensitivity and specificity than TTE in diagnosing cardiac injuries, but its use is also limited in patients with hypotension and associated other serious spine injuries (12).

### 2.2.3. Focused Assessment With Sonography (FAST)

FAST is a rapid real time bedside imaging method with

very high sensitivity (more than 97%) in detection of pericardial fluid noninvasively; however it is operator dependent and suboptimal in presence of pneumopericardium, subcutaneous emphysema and large body habitus (39).

### 2.2.4. Radionuclide Imaging

With the advent of echocardiography and MDCT, nuclear scans are not routinely performed for evaluation of patients with acute cardiac injury. They play a role in evaluating patients with cardiac contusion in chronic stage (40). One study reported that radionuclide scanning is not useful in the evaluation of patients with blunt cardiac trauma (35). Though FDG-PET is useful to assess myocardial viability, its role in evaluating myocardial injury is yet to be determined (41). Also this examination is expensive, not readily available and not established to evaluate acute traumatic cardiac injury.

### 2.2.5. Cardiac Magnetic Resonance Imaging (C-MRI)

MRI offers excellent myocardial tissue characterization. However, it plays no role in acute cardiac trauma due to long scanning time and cumbersome challenges related to in patients with polytrauma and on life support devices (42, 43). Delayed enhanced cardiac MR imaging detects extent of post traumatic myocardial infarction and pericardial tears (44, 45).

## 3. Results

### 3.1. MDCT Imaging of Cardiac Injury

MDCT is increasingly utilized in the evaluation of chest trauma and is currently the best standard imaging modality. MDCT has excellent spatial, contrast, and temporal resolution and offers detailed analysis of the heart, pericardium, and great vessels. The entire thorax can be quickly and accurately imaged, and life threatening injuries can be diagnosed and treated efficiently. Using ECG gating, pulsation artifacts can be eliminated and subtle small injuries of the coronary arteries and pericardium can be diagnosed. With dose modulation technique and strategies, radiation dose is now significantly decreased (46).

**Myocardial Contusion:** Cardiac contusion is usually caused by blunt chest trauma and therefore is frequently suspected in patients involved in car or motorcycle accidents. The exact incidence of cardiac contusion in patients with blunt chest trauma is unknown (47). The reported incidence ranges between 3 - 56% of patients, depending on the criteria used for establishing the diagnosis.

Cardiac contusion clinically presents as a spectrum of injuries of varying severity. The diagnosis of a myocardial contusion is difficult because of non-specific symptoms and the lack of an ideal test to detect myocardial damage. Myocardial contusion should be suspected in patients with trauma having elevated troponin, abnormal ECG and hypotension not responding to fluid resuscitation. Though con-

tusion has nonspecific appearance on MDCT, a high index of suspicion with associated injury to great vessels, pulmonary and skeletal structures may aid in diagnosis (48)

**Myocardial Rupture:** Though myocardial rupture is not very common, it carries high morbidity and mortality (49). A non-penetrating cardiac trauma can cause free-wall rupture of the heart as well as the interventricular septum, and cardiac valves (50). Brathwaite et al. (14) reported right sided chambers were more frequently involved in trauma than left sided chambers. Survival is more likely with atrial than ventricle rupture, and more likely with right-sided than left-sided injuries (51). These patients usually present with signs of cardiac tamponade if pericardial integrity is preserved. Patients with a concomitant tear in the pericardium usually manifest with hemothorax and hemorrhagic shock (52).

In MDCT, cardiac rupture is seen as myocardial discontinuity with contrast accumulation in pericardial cavity (Figure 1) (53). Cardiac tamponade secondary to ventricular rupture carries higher mortality than that caused by atrial rupture since in ventricular rupture, blood accumulates more rapidly in the pericardial cavity (Figure 2) (54).

**Pericardial Injury:** Though a rare injury, pericardial rupture has a high mortality and is often associated with other injuries of chest and other organs (18). The diagnosis of a pericardial injury relies on a high degree of clinical suspicion especially in haemodynamically stable patients with subtle imaging findings. Because these patients can deteriorate rapidly, an early diagnosis is crucial. Left pleuropericardial surface is the most commonly involved in trauma; however injuries to right pleuropericardium, diaphragmatic, and mediastinal surfaces of pericardium have also been reported (Figure 3) (55). Pericardial trauma can manifest as pneumopericardium, hemopericardium, and also can lead to cardiac herniation (56).

Pneumopericardium is accurately depicted with MDCT as air typically positioned at the root of great vessels. The presence of pneumopericardium should prompt a search for pericardial tear in patients with blunt chest trauma (57). Accurate diagnosis of pneumopericardium is crucial because it may also lead to tamponade physiology and tension pneumopericardium, typically depicted by MDCT as the 'small heart' sign (58).

Pericardial rupture is seen on MDCT as a focal area of discontinuity, dimpling and irregularity with interposition of lung in the pericardial deficient area.

**Cardiac Herniation:** Cardiac herniation is a serious complication of pericardial rupture, with high a mortality rate. In cardiac herniation, a deformed cardiac contour is manifested as a waist around the compressed portion of the heart herniating through a pericardial defect, known as "collar sign" (59). Another sign of cardiac herniation is the "Empty pericardial sac" sign which is seen as air outlining the empty pleuropericardium as a result of cardiac luxation into the hemithorax (39).

**Hemopericardium:** MDCT has a very high sensitivity and specificity in identifying hemopericardium in stable

patients with trauma (60). In patients with BCI, MDCT reveals hemopericardium with the triad of high-attenuation pericardial effusion with distention of the inferior vena cava, renal veins, and periportal edema (54).

The pericardial blood under tension may compress right sided chambers and cause flattening of the anterior surface of the heart with a diminished anterior-posterior cardiac diameter, which has been described as the "flattened heart sign". This sign has a bad prognosis and can lead to cardiac tamponade if not immediately treated (61).

**Coronary Artery Injury:** Injury to the coronary arteries is rare and occurs in less than 2% of blunt chest trauma cases (62). It can lead to immediate or delayed myocardial infarction either due to dissection or spasm (63). The left anterior descending artery is most commonly involved followed by right coronary artery and circumflex artery (Figure 4) (64). Small tears, dissection or thrombosis of the coronary arteries can be identified on ECG gated MDCT. Such patients should be further evaluated by conventional angiography and treated to limit the extent of infarction (65).

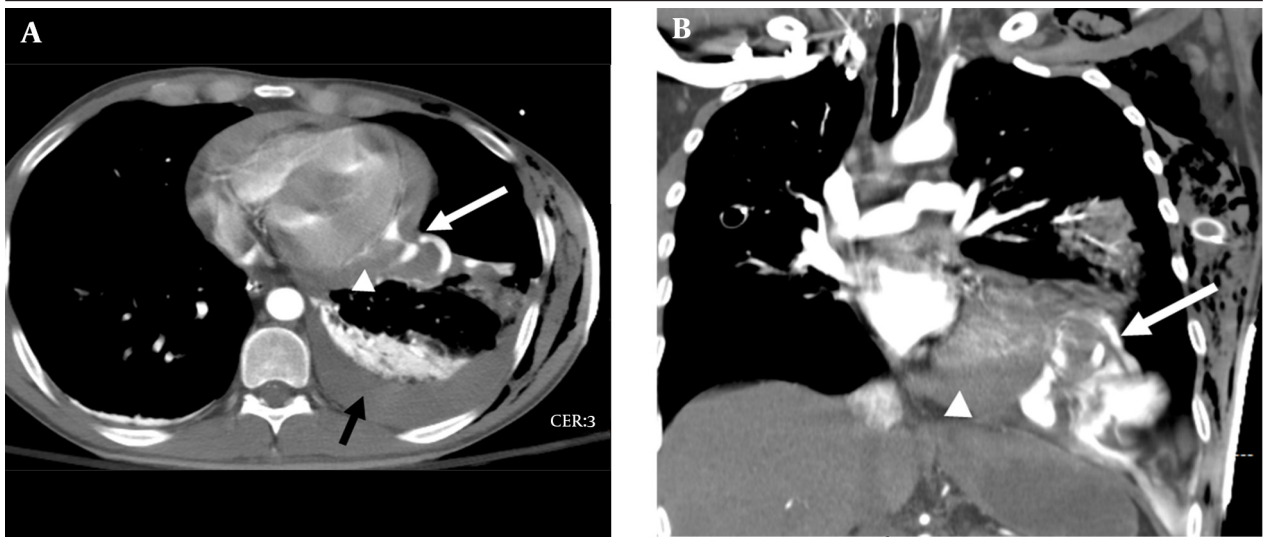
**Post-traumatic coronary artery pseudoaneurysms:** They are rare, but can develop as an immediate or delayed complication of cardiac injury (66). The left anterior descending artery is most commonly involved. MDCT can accurately identify and characterize the pseudoaneurysm.

**Traumatic coronary artery fistula:** They are rare and carry high morbidity and mortality and if not promptly diagnosed and treated (67). In their literature review, Lowe et al. reported that the right coronary artery and right sided cardiac chambers are more frequently involved than the left coronary artery and left sided chambers (68). MDCT can not only evaluate exact anatomy and course of post traumatic fistula but may also facilitate treatment planning (69).

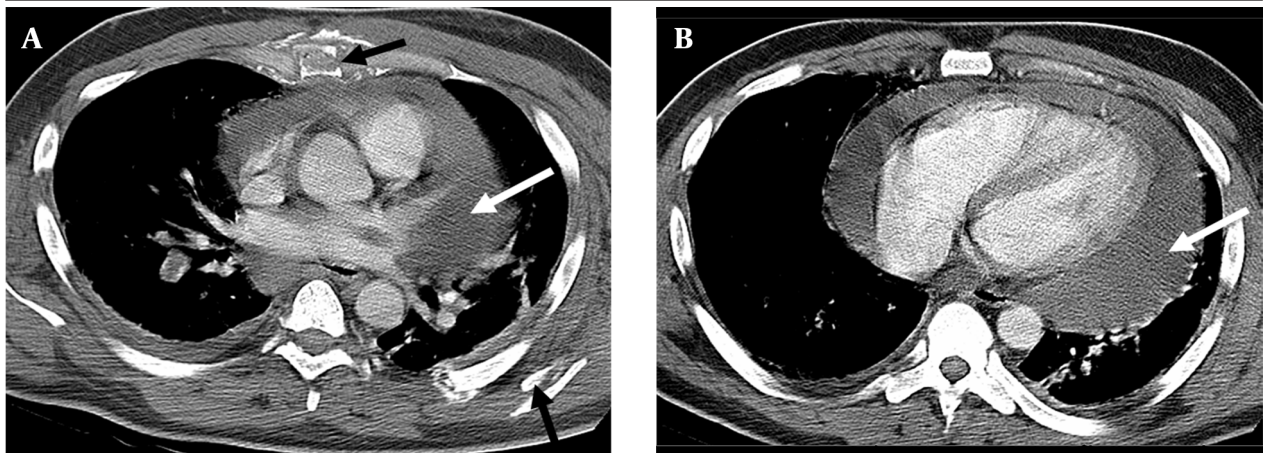
**Post-traumatic VSD:** It can occur immediately as a post-traumatic compression or deceleration injury and is seen on MDCT as disruption of interventricular septum. It can also occur after penetrating cardiac injury. Alternatively, it can occur due to necrotic perforation of interventricular septum secondary to posttraumatic infarction or contusion (70). Post traumatic VSD usually occur in the muscular septum close to apex (Figure 5). Rarely, it can occur in infundibulum (71).

While MDCT can identify posttraumatic VSD, serial echocardiography is recommended in patients with cardiac trauma to evaluate for delayed development of post traumatic VSD (72).

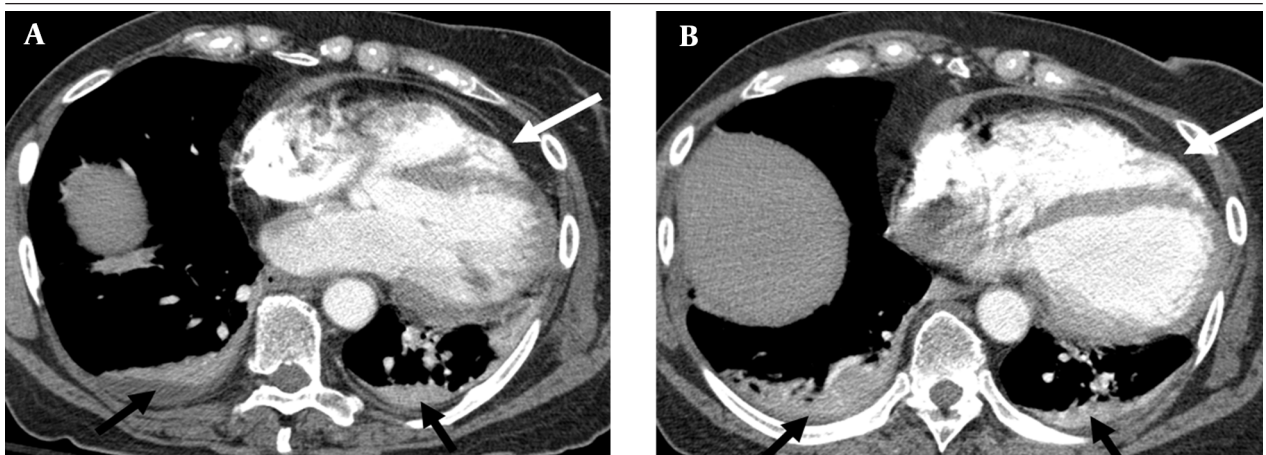
**Traumatic Valvular Dysfunction:** Valvular trauma is exceedingly rare following chest trauma. Its identification requires high clinical suspicion. In a literature review, Kan et al. (73) reported that the aortic valve and in particular the non-coronary cusp is most commonly involved followed by mitral and tricuspid valves. Though echocardiography is the imaging modality of choice for evaluating valvular trauma, MDCT can diagnose trauma to papillary muscles or chordae tendineae (74).



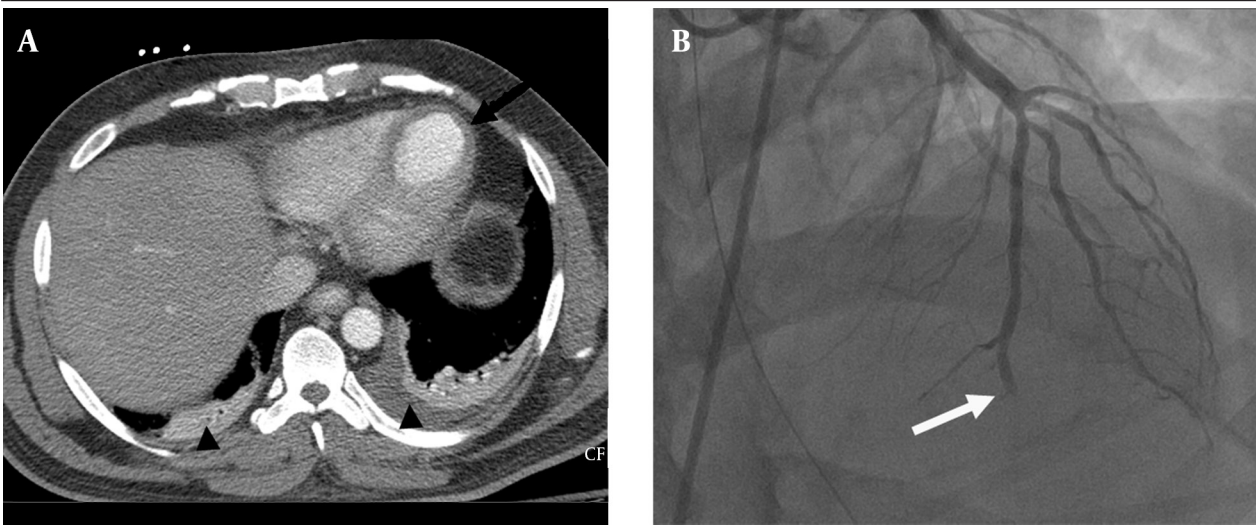
**Figure 1.** Contrast enhanced chest CT axial (A) and coronal (B) planes in a patient with penetrating injury. There is rupture of the lateral wall of the left ventricle (white arrow) with contrast extravasation causing tamponade (arrowhead). Left pleural effusion is also demonstrated (black arrow).



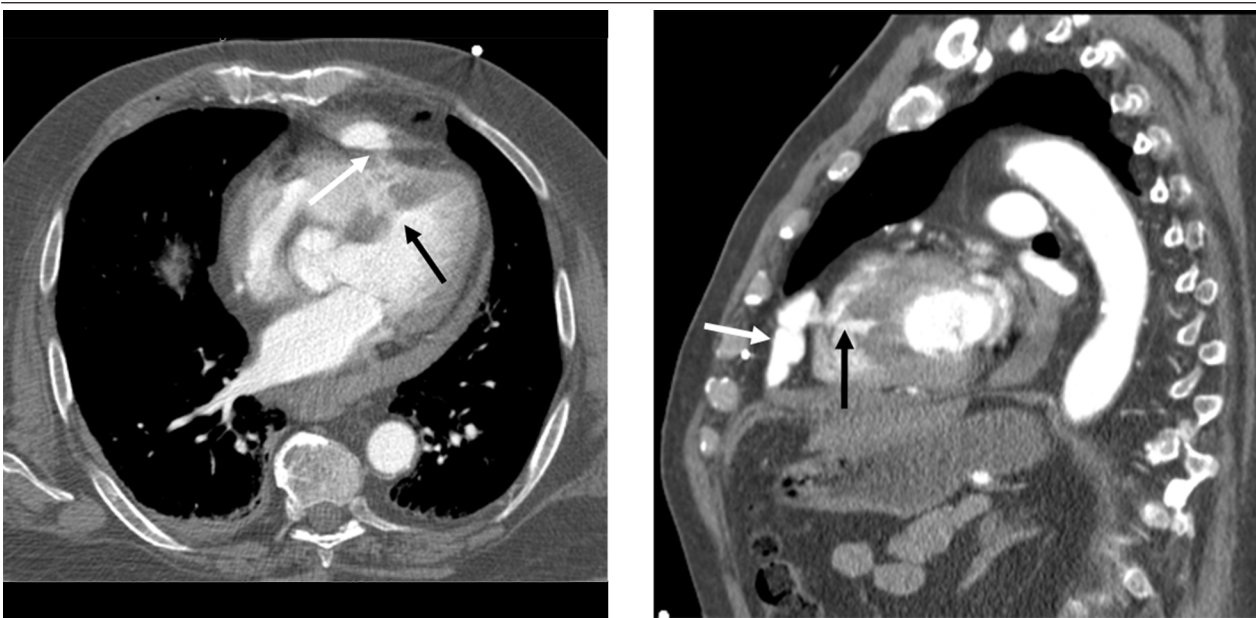
**Figure 2.** Contrast enhanced CT chest in a patient who had a motor vehicle accident one week earlier. Original CT depicted sternal and rib fractures with no hemopericardium. Follow up contrast enhanced chest CT at the level of the aortic root (A) and interventricular septum (B) demonstrates a large delayed hemopericardium (white arrows). Sternal and rib fractures are also seen (black arrows).



**Figure 3.** Contrast enhanced chest CT in a patient with blunt cardiac injury in the axial plane at the level of descending thoracic aorta; images (A) and (B) demonstrate rupture of the left lateral pericardium (white arrows) with altered axis of the heart. Bilateral small pleural effusions are also demonstrated (black arrows).



**Figure 4.** Contrast enhanced CT chest axial plane at the level of descending thoracic aorta (A) in a patient with motor vehicle accident presenting with acute chest pain, elevated troponins and ST elevation shows LV aneurysm (black arrow). Catheter angiography (B) shows dissection/occlusion of the left anterior descending artery (white arrow).



**Figure 5.** Contrast enhanced CT of the chest in axial (A) and sagittal (B) planes in a patient with penetrating injury. There is rupture of the right ventricle (white arrow) with contained pseudoaneurysm and traumatic ventricular septal defect (black arrow).

#### 4. Conclusions

Cardiac trauma is common and can cause a wide spectrum of conditions with clinical presentations ranging from asymptomatic to life threatening cardiac arrhythmias, tamponade and/or cardiac rupture. Thus, it is of paramount importance to recognize the injuries capable of causing hemodynamic instability so that early and specific intervention can be undertaken to reduce the morbidity and mortality. In a patient with suspected cardiac injury, physical examination, chest radiograph, echocardiography, and cardiac enzymes are usually performed as

an initial assessment. In this regard, MDCT is a very helpful diagnostic tool and is a one stop shop for evaluation of cardiac integrity in patients with chest trauma.

#### Footnotes

**Authors' Contribution:** All the authors have made substantial contributions to the conception and design of the study, interpretation, and drafting of the article and its revision.

## References

1. Talving P, Demetriades D. Cardiac trauma during teenage years. *Pediatr Clin North Am*. 2014;**61**(1):111-30.
2. Malangoni MA, McHenry CR, Jacobs DG. Outcome of serious blunt cardiac injury. *Surgery*. 1994;**116**(4):628-32.
3. Agarwal D, Chandra S. Challenges in the diagnosis of blunt cardiac injuries. *Indian J Surg*. 2009;**71**(5):245-53.
4. Sybrandy KC, Cramer MJ, Burgersdijk C. Diagnosing cardiac contusion: old wisdom and new insights. *Heart*. 2003;**89**(5):485-9.
5. Huang YK, Lu MS, Liu KS, Liu EH, Chu JJ, Tsai FC, et al. Traumatic pericardial effusion: impact of diagnostic and surgical approaches. *Resuscitation*. 2010;**81**(12):1682-6.
6. Degiannis E, Loogna P, Doll D, Bonanno F, Bowley DM, Smith MD. Penetrating cardiac injuries: recent experience in South Africa. *World J Surg*. 2006;**30**(7):1258-64.
7. Frazee RC, Mucha PJ, Farnell MB, Miller FJ. Objective evaluation of blunt cardiac trauma. *J Trauma*. 1986;**26**(6):510-20.
8. van Wijngaarden MH, Karmy-Jones R, Talwar MK, Simonetti V. Blunt cardiac injury: a 10 year institutional review. *Injury*. 1997;**28**(1):51-5.
9. Tenzer ML. The spectrum of myocardial contusion: a review. *J Trauma*. 1985;**25**(7):620-7.
10. El-Menyar A, Al Thani H, Zarour A, Latifi R. Understanding traumatic blunt cardiac injury. *Ann Card Anaesth*. 2012;**15**(4):287-95.
11. Kang N, Hsee L, Rizoli S, Alison P. Penetrating cardiac injury: overcoming the limits set by Nature. *Injury*. 2009;**40**(9):919-27.
12. Elie MC. Blunt cardiac injury. *Mt Sinai J Med*. 2006;**73**(2):542-52.
13. El-Chami MF, Nicholson W, Helmy T. Blunt cardiac trauma. *J Emerg Med*. 2008;**35**(2):127-33.
14. Brathwaite CE, Rodriguez A, Turney SZ, Dunham CM, Cowley R. Blunt traumatic cardiac rupture. A 5-year experience. *Ann Surg*. 1990;**212**(6):701-4.
15. Santavirta S, Arajärvi E. Ruptures of the heart in seatbelt wearers. *J Trauma*. 1992;**32**(3):275-9.
16. Calhoun JH, Hoffmann TH, Trinkle JK, Harman PK, Grover FL. Management of blunt rupture of the heart. *J Trauma*. 1986;**26**(6):495-502.
17. Dalvi AN, Gondhalekar RA, Shirhatti RG, Joshi SV, Sukthankar RU, Mathur SK. Atrial rupture following blunt chest trauma (a case report). *J Postgrad Med*. 1987;**33**(3):152-4.
18. Fulda G, Brathwaite CE, Rodriguez A, Turney SZ, Dunham CM, Cowley RA. Blunt traumatic rupture of the heart and pericardium: a ten-year experience (1979-1989). *J Trauma*. 1991;**31**(2):167-72.
19. Khurana S, Puri R, Wong D, Dundon BK, Brown MA, Worthley MI, et al. Latent tricuspid valve rupture after motor vehicle accident and routine echocardiography in all chest-wall traumas. *Tex Heart Inst J*. 2009;**36**(6):615-7.
20. Marshall DT, Gilbert JD, Byard RW. The spectrum of findings in cases of sudden death due to blunt cardiac trauma-'commotio cordis'. *Am J Forensic Med Pathol*. 2008;**29**(1):1-4.
21. Rhee PM, Foy H, Kaufmann C, Areola C, Boyle E, Maier RV, et al. Penetrating cardiac injuries: a population-based study. *J Trauma*. 1998;**45**(2):366-70.
22. Asensio JA, Murray J, Demetriades D, Berne J, Cornwell E, Velmahos G, et al. Penetrating cardiac injuries: a prospective study of variables predicting outcomes. *J Am Coll Surg*. 1998;**186**(1):24-34.
23. Johnson SB, Nielsen JL, Sako EY, Calhoun JH, Trinkle JK, Miller OL. Penetrating intrapericardial wounds: clinical experience with a surgical protocol. *Ann Thorac Surg*. 1995;**60**(1):117-20.
24. Nagy KK, Lohmann C, Kim DO, Barrett J. Role of echocardiography in the diagnosis of occult penetrating cardiac injury. *J Trauma*. 1995;**38**(6):859-62.
25. Killeen KL, Poletti PA, Shanmuganathan K, Mirvis SE. CT diagnosis of cardiac and pericardial injuries. *Emerg Radiol*. 1999;**6**(6):339-44.
26. Antoniadis L, Petrou PM, Eftychiou C, Nicolaides E. A penetrating heart injury resulting in ventricular septal defect. *Hellenic J Cardiol*. 2011;**52**(1):71-4.
27. Campbell NC, Thomson SR, Muckart DJ, Meumann CM, Van Middekoop I, Botha JB. Review of 1198 cases of penetrating cardiac trauma. *Br J Surg*. 1997;**84**(12):1737-40.
28. Helling TS, Duke P, Beggs CW, Crouse LJ. A prospective evaluation of 68 patients suffering blunt chest trauma for evidence of cardiac injury. *J Trauma*. 1989;**29**(7):961-5.
29. Hiatt JR, Yeatman LJ, Child JS. The value of echocardiography in blunt chest trauma. *J Trauma*. 1988;**28**(7):914-22.
30. Salim A, Velmahos GC, Jindal A, Chan L, Vassiliu P, Belzberg H, et al. Clinically significant blunt cardiac trauma: role of serum troponin levels combined with electrocardiographic findings. *J Trauma*. 2001;**50**(2):237-43.
31. Karalis DG, Victor MF, Davis GA, McAllister MP, Covalesky VA, Ross JJ, et al. The role of echocardiography in blunt chest trauma: a transthoracic and transesophageal echocardiographic study. *J Trauma*. 1994;**36**(1):53-8.
32. Garcia-Fernandez MA, Lopez-Perez JM, Perez-Castellano N, Quero LF, Virgos-Lamela A, Otero-Ferreiro A, et al. Role of transesophageal echocardiography in the assessment of patients with blunt chest trauma: correlation of echocardiographic findings with the electrocardiogram and creatine kinase monoclonal antibody measurements. *Am Heart J*. 1998;**135**(3):476-81.
33. Rozycki GS, Feliciano DV, Schmidt JA, Cushman JG, Sisley AC, Ingram W, et al. The role of surgeon-performed ultrasound in patients with possible cardiac wounds. *Ann Surg*. 1996;**223**(6):737-44.
34. Chirillo F, Totis O, Cavarzerani A, Bruni A, Farnia A, Sarpellon M, et al. Usefulness of transthoracic and transoesophageal echocardiography in recognition and management of cardiovascular injuries after blunt chest trauma. *Heart*. 1996;**75**(3):301-6.
35. Maenza RL, Seaberg D, D'Amico F. A meta-analysis of blunt cardiac trauma: ending myocardial confusion. *Am J Emerg Med*. 1996;**14**(3):237-41.
36. Rozycki GS, Feliciano DV, Ochsner MG, Knudson MM, Hoyt DB, Davis F, et al. The role of ultrasound in patients with possible penetrating cardiac wounds: a prospective multicenter study. *J Trauma*. 1999;**46**(4):543-51.
37. Parmley LF, Manion WC, Mattingly TW. Nonpenetrating traumatic injury of the heart. *Circulation*. 1958;**18**(3):371-96.
38. Reid CL, Kawanishi DT, Rahimtoola SH, Chandraratna PA. Chest trauma: evaluation by two-dimensional echocardiography. *Am Heart J*. 1987;**113**(4):971-6.
39. Adams A, Fotiadis N, Chin JY, Sapsford W, Brohi K. A pictorial review of traumatic pericardial injuries. *Insights Imaging*. 2012;**3**(4):307-11.
40. Amino M, Yoshioka K, Morita S, Iizuka S, Otsuka H, Yamamoto R, et al. One-year follow-up and convalescence evaluated by nuclear medicine studies and 24-hour holter electrocardiogram in 11 patients with myocardial injury due to a blunt chest trauma. *J Trauma*. 2009;**66**(5):308-10.
41. Pai M. Diagnosis of myocardial contusion after blunt chest trauma using 18F-FDG positron emission tomography. *Br J Radiol*. 2006;**79**(939):264-5.
42. Lyne J, Fox K, Mohiaddin RH. Follow up in a case of cardiac contusion using cardiovascular magnetic resonance. *J Cardiovasc Magn Reson*. 2007;**9**(3):589.
43. Wicky S, Wintermark M, Schnyder P, Capasso P, Denys A. Imaging of blunt chest trauma. *Eur Radiol*. 2000;**10**(10):1524-38.
44. Sohn JH, Song JW, Seo JB, Do KH, Lee JS, Kim DK, et al. Case report: pericardial rupture and cardiac herniation after blunt trauma: a case diagnosed using cardiac MRI. *Br J Radiol*. 2005;**78**(929):447-9.
45. Southam S, Jutla C, Ketai L. Contrast-enhanced cardiac MRI in blunt chest trauma: differentiating cardiac contusion from acute peri-traumatic myocardial infarction. *J Thorac Imaging*. 2006;**21**(2):176-8.
46. Sabarudin A, Sun Z, Ng KH. A systematic review of radiation dose associated with different generations of multidetector CT coronary angiography. *J Med Imaging Radiat Oncol*. 2012;**56**(1):5-17.
47. Fildes JJ, Betlej TM, Mangano R, Martin M, Rogers F, Barrett JA. Limiting cardiac evaluation in patients with suspected myocardial contusion. *Am Surg*. 1995;**61**(9):832-5.
48. Zinck SE, Primack SL. Radiographic and CT findings in blunt chest trauma. *J Thorac Imaging*. 2000;**15**(2):87-96.
49. Kato S, Nagata Y, Ota T, Sahara T, Kato R, Tsuchioka H. [Successful repair of right atrial rupture due to nonpenetrating trauma of the chest]. *Kyobu Geka*. 1988;**41**(11):913-5.

50. Permanyer E, Ginel A, Munoz-Guijosa C, Padro JM. Right atrium traumatic rupture presenting as chronic tamponade. *Interact Cardiovasc Thorac Surg*. 2009;**9**(4):748-9.
51. Pevec WC, Udekwu AO, Peitzman AB. Blunt rupture of the myocardium. *Ann Thorac Surg*. 1989;**48**(1):139-42.
52. Symbas NP, Bongiorno PF, Symbas PN. Blunt cardiac rupture: the utility of emergency department ultrasound. *Ann Thorac Surg*. 1999;**67**(5):1274-6.
53. Mirvis SE. Imaging of acute thoracic injury: the advent of MDCT screening. *Semin Ultrasound CTMR*. 2005;**26**(5):305-31.
54. Goldstein L, Mirvis SE, Kostrubiak IS, Turney SZ. CT diagnosis of acute pericardial tamponade after blunt chest trauma. *AJR Am J Roentgenol*. 1989;**152**(4):739-41.
55. Clark DE, Wiles C3, Lim MK, Dunham CM, Rodriguez A. Traumatic rupture of the pericardium. *Surgery*. 1983;**93**(4):495-503.
56. Wright MP, Nelson C, Johnson AM, McMillan IK. Herniation of the heart. *Thorax*. 1970;**25**(6):656-64.
57. Farhataziz N, Landay MJ. Pericardial rupture after blunt chest trauma. *J Thorac Imaging*. 2005;**20**(1):50-2.
58. Westaby S. Penumopericardium and tension pneumopericardium after closed-chest injury. *Thorax*. 1977;**32**(1):91-7.
59. Sherren PB, Galloway R, Healy M. Blunt traumatic pericardial rupture and cardiac herniation with a penetrating twist: two case reports. *Scand J Trauma Resusc Emerg Med*. 2009;**17**:64.
60. Nagy KK, Gilkey SH, Roberts RR, Fildes JJ, Barrett J. Computed tomography screens stable patients at risk for penetrating cardiac injury. *Acad Emerg Med*. 1996;**3**(11):1024-7.
61. Hernandez-Luyando L, Calvo J, Gonzalez de las Heras E, de la Puente H, Lopez C. Tension pericardial collections: sign of 'flattened heart' in CT. *Eur J Radiol*. 1996;**23**(3):250-2.
62. Pretre R, Chilcott M. Blunt trauma to the heart and great vessels. *N Engl J Med*. 1997;**336**(9):626-32.
63. Neiman J, Hui WK. Posteromedial papillary muscle rupture as a result of right coronary artery occlusion after blunt chest injury. *Am Heart J*. 1992;**123**(6):1694-9.
64. Ginzburg E, Dygert J, Parra-Davila E, Lynn M, Almeida J, Mayor M. Coronary artery stenting for occlusive dissection after blunt chest trauma. *J Trauma*. 1998;**45**(1):157-61.
65. Thorban S, Ungeheuer A, Blasini R, Siewert JR. Emergent interventional transcatheter revascularization in acute right coronary artery dissection after blunt chest trauma. *J Trauma*. 1997;**43**(2):365-7.
66. Wang SP, Shyong WC, Tsai JH, Chang MS, Chiang BN. Development of posttraumatic coronary aneurysm: clinical implications. *Am Heart J*. 1988;**115**(6):1306-7.
67. Jeganathan R, Irwin G, Johnston PW, Jones JM. Traumatic left anterior descending artery-to-pulmonary artery fistula with delayed pericardial tamponade. *Ann Thorac Surg*. 2007;**84**(1):276-8.
68. Lowe JE, Adams DH, Cummings RG, Wesly RL, Phillips HR. The natural history and recommended management of patients with traumatic coronary artery fistulas. *Ann Thorac Surg*. 1983;**36**(3):295-305.
69. Chang DS, Lee MH, Lee HY, Barack BM. MDCT of left anterior descending coronary artery to main pulmonary artery fistula. *AJR Am J Roentgenol*. 2005;**185**(5):1258-60.
70. Genoni M, Jenni R, Turina M. Traumatic ventricular septal defect. *Heart*. 1997;**78**(3):316-8.
71. Pierli C, Iadanza A, Del Pasqua A, Sinicropi G. Unusual localisation of a ventricular septal defect following blunt chest trauma. *Heart*. 2001;**86**(1):E6.
72. Pirzada FA, McDowell JW, Cohen EM, Saini VK, Berger RL. Traumatic ventricular septal defect. Sequential hemodynamic observations. *N Engl J Med*. 1974;**291**(17):892-5.
73. Kan CD, Yang YJ. Traumatic aortic and mitral valve injury following blunt chest injury with a variable clinical course. *Heart*. 2005;**91**(5):568-70.
74. Lee H, Ruzsics B, Schoepf UJ, Stewart EA, Costello P, Glenn JL, et al. New-onset heart failure caused by spontaneous papillary muscle rupture: diagnosis with dual-source computed tomographic coronary angiography. *J Thorac Cardiovasc Surg*. 2009;**137**(1):e19-21.