

# Knotless Primary Anterior Cruciate Ligament Repair with Adjustable Loop Device and Internal Brace Augmentation



Patrick A. Smith, M.D., and Corey S. Cook, M.A.

**Abstract:** With the recent resurgence of primary anterior cruciate ligament repair, it is important to strive for optimal patient outcomes. This knotless primary repair procedure takes advantage of the use of an adjustable loop device, which allows for intraoperative retensioning by the surgeon. This technical advancement combined with augmentation with an internal brace could potentially minimize gap formation at the repair site, thereby increasing repair stability and ultimate outcome.

Recently, primary anterior cruciate ligament (ACL) repair has seen a resurgence in popularity.<sup>1-3</sup> Historically, clinicians moved away from ACL repair due to the reports of high retear rates and the belief that the ACL was incapable of healing.<sup>4</sup> However, recent research suggests that primary repair can be successful with proper patient selection and updated surgical techniques.<sup>3,5</sup>

An important factor for a successful primary ACL repair is proper patient selection, with proximal tears showing the best results.<sup>2,6,7</sup> In addition to patient selection, augmentation of the repair potentially improves outcomes. Methods being researched for augmenting the repair itself include dynamic intra-ligamentary stabilization (DIS)<sup>8,9</sup> and suture tape

reinforcement as an internal brace (IB).<sup>10,11</sup> Another promising option to enhance the outcome with primary ACL repair is biologic augmentation. The use of bone marrow aspirate concentrate (BMAC) and scaffolding both have shown promise in improving patient and surgical outcomes.<sup>12,13</sup>

A final key to success of ACL primary repair is optimal reattachment of the native ACL tissue back to the femoral insertion site for suitable proximal tears. Previously described techniques vary from use of a simple suture of the native ACL tissue to advance torn proximal ACL tissue to the femur—either tied over drill holes on the femur<sup>14</sup>, or to a button<sup>11</sup>, or to use of suture anchors.<sup>1</sup> A promising technique not previously clinically described is a knotless technique that employs adjustable loop fixation, which was recently shown in a biomechanical study to be superior to both suture tying and anchor fixation for primary repair.<sup>15</sup> This is the focus of this technique paper for primary ACL repair, along with IB augmentation.

From the Department of Orthopaedic Surgery, University of Missouri, Columbia, Missouri, U.S.A. (P.A.S., C.S.C.); and Columbia Orthopaedic Group, Columbia, Missouri, U.S.A. (C.S.C.).

The authors report the following potential conflicts of interest or sources of funding: P.A.S. receives consulting fees, research support, and personal fees for a product unrelated to this research project from Arthrex, outside the submitted work; and owns stock options in Spinal Simplicity. Full ICMJE author disclosure forms are available for this article online, as [supplementary material](#).

Received May 6, 2020; accepted August 28, 2020.

Address correspondence to Patrick A. Smith, M.D., Columbia Orthopaedic Group, Department of Orthopaedic Surgery, Sports Medicine, University of Missouri, 1 S Keene Street, Columbia, MO 65201, U.S.A. E-mail: [psmithmudoc@aol.com](mailto:psmithmudoc@aol.com)

© 2020 Published by Elsevier on behalf of the Arthroscopy Association of North America. This is an open access article under the CC BY-NC-ND license (<http://creativecommons.org/licenses/by-nc-nd/4.0/>).

2212-6287/20791

<https://doi.org/10.1016/j.eats.2020.08.041>

## Surgical Technique

### Indications

The literature supports that proximal ACL tears have the best outcomes.<sup>2,6,7</sup> The most common classification system by Sherman<sup>16</sup> grades ACL tears 1 to 4, as follows:

- Type I: minimal tissue remains on femur (avulsion tear)
- Type II: 20% tissue remains on femur (proximal 1/4<sup>th</sup> tear)

- Type III: 33% tissue remains on femur (proximal 1/3<sup>rd</sup> tear)
- Type IV: 50% tissue remains on femur (midsubstance tear)

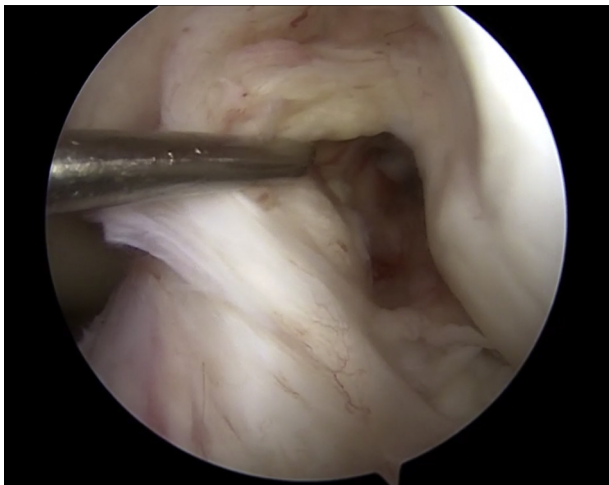
So, based on tissue assessment at the time of arthroscopy, either a Sherman 1 or 2 would be suitable for a primary ACL repair.

### Femoral Preparation

After arthroscopic confirmation of a proximal Sherman type 1 or 2 ACL tear<sup>16</sup> (Fig 1), microfracture of the femoral notch is done to enhance mesenchymal stem cell release from the bone marrow, consistent with the “healing response” technique described by Steadman (Video 1).<sup>17</sup> A PowerPick (Arthrex, Naples, FL) is used to make the first hole at the midpoint of the anatomic attachment of the ACL on the femur to advance the torn proximal ACL tissue. Then, coming through the anteromedial portal, a 3.5 mm diameter spade tip pin (Arthrex, Naples, FL) is drilled at the PowerPick hole made at the anatomic ACL attachment site on the femur with the knee flexed to 120 degrees. This pin is used to also measure the intraosseous distance of the femur as it exits out the lateral femoral cortex, using the special spade tip which acts like a drill depth guide. This distance will be used later for flippage of the suspensory adjustable loop device (ALD) button to be utilized for femoral fixation. Next, the pin is used to pull a #2 FiberWire suture (Arthrex, Naples, FL) across the femur to serve as a shuttle suture for later passage of the femoral ALD fixation.

### Passage of Internal Brace on Tibial Side

The next step is passage of a FiberTape (Arthrex, Naples, FL) on the tibial side to serve as an IB. This is done by using an ACL tibial aiming guide (Arthrex,



**Fig 1.** Arthroscopic view of left knee from anterolateral portal of Sherman 2 type proximal anterior cruciate ligament tear with probe in anteromedial portal.

Naples, FL) positioned toward the anteromedial bundle of the still intact ACL fibers on the tibia with the attached guide sleeve placed down to bone via a small 1 cm anteromedial tibial incision. A 3.5 mm drill bit is drilled through the guide sleeve just across the medial tibial plateau, and then by hand is passed up through the intact anteromedial ACL tibial fibers. This is facilitated by use of the aiming guide pressing down on the drill bit so it more easily penetrates through the proximal ACL tissue. The drill guide sleeve on the tibia is tapped into the bone a distance of 7 mm, marked by an offset. The drill bit is removed and a TigerStick (Arthrex, Naples, FL) suture in its red sheath is passed up through the guide sleeve and the 3.5 mm drill hole and retrieved with a suture grasper on the joint side, and brought out the anterolateral portal to serve as a shuttle for the IB to be passed later. In this way, the IB is placed in the most isometric ACL position—the anteromedial bundle fibers.

### ACL Suture Placement

At this time, attention is directed toward placement of sutures in the proximal ACL fibers (Table 1). To avoid aggravating portal soft tissue entrapment, a PassPort (Arthrex, Naples, FL) cannula is placed in the anteromedial portal. A Labral Scorpion (Arthrex, Naples, FL) device is used to pass both an 0-TigerLink and an 0-FiberLink (Arthrex, Naples, FL) suture through the torn proximal ACL fibers. For brevity and clarity, when referring to the 0-TigerLink and 0-FiberLink sutures together, these will be referred to as 0-Link sutures. The free end of each suture is passed through their loops to create a cinch type suture configuration (Fig 2). For the ALD fixation technique, it is critical to specifically use these 0-Link sutures (Figs 3A and 3B), as after the cinch suture is made, there is still a short open loop distal to the cinch which is used for passage of the ALD fixation device (Fig 4A).

### Passage of ALD through 0-Link Sutures

After placing both 0-Link sutures, the next step is passage of the ALD through the distal loops in the two 0-Link sutures (Fig 5), so the proximal fixation of the ACL fibers to the femur will be done by the ALD attached to these loops, as opposed to pulling directly on the actual sutures themselves. This is done by first using a Banana Lasso (Arthrex, Naples, FL) through the anteromedial portal and passing it arthroscopically through the two distal loops of each 0-Link suture. The wire of the Banana Lasso is threaded through these two loops (Fig 4B), and the free end is then retrieved with a grasper coming through the PassPort cannula.

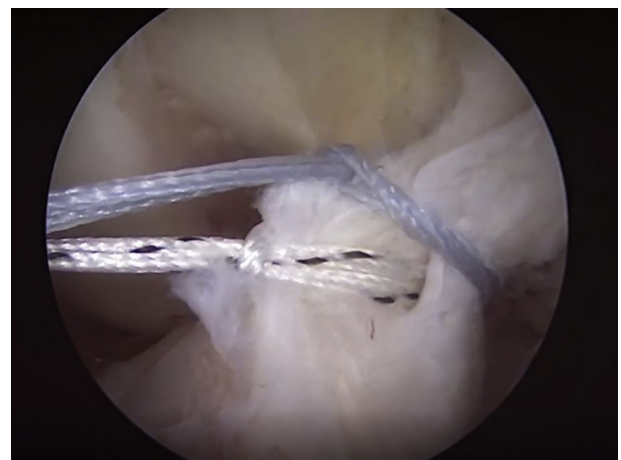
### ALD Assembly

A BTB TightRope (Arthrex, Naples, FL) ALD will be assembled, which is done outside of the joint. The BTB


**Table 1.** Pitfalls and Pearls

Pitfalls	Pearls
Difficulty in obtaining purchase in proximal ACL fibers	Switch portals when using Labral Scorpion to make it easier to place one 0-FiberLink and one 0-TigerLink in the proximal ACL fibers, spaced appropriately. Place the 0-FiberLink and 0-TigerLink sutures more toward the intact midsubstance ACL fibers medially and laterally
Difficulty with passage of IB on the tibial side	If you prefer to pass the IB within the ACL fibers, use the ACL tibial guide over the drill bit as it comes through the intact ACL fibers to help it “pop through” the proximal ACL fibers to make it easier then to pass the TigerStick shuttle suture in its red sheath. Also remember to tap in the tibial guide sleeve 7 mm so as not to lose the passageway of the 3.5 mm drill bit into the joint. Pass the 3.5 mm drill bit just at the anteromedial aspect of the ACL, not within the fibers themselves, as it is fine for the IB to be on top of the ACL fibers.
Passage of adjustable loop fixation BTB TightRope device in the joint through the distal loops of the TigerLink and FiberLink sutures	Take the loop end of the BTB TightRope (step 1) off the card and cut off the needle. Then, lengthen the loop by pulling on one of the strands. After passing the wire from the Banana Lasso through the distal loops of the two sutures in the proximal ACL fibers, place a 0-FiberLink suture through the lengthened loop of the BTB TightRope and then pass it through the looped end of the 0-FiberLink to create a cinch. Then, pass the free end of the 0-FiberLink suture through the open end of the wire, which serves as the shuttle to pass the loop of the BTB TightRope between the distal loops of the two cinch sutures that are in the ACL fibers. The advantage here is there is less friction with the 0-FiberLink suture than the wire, thereby making passage of the loop of the BTB TightRope easier.
When passing the ADL TightRope through the PassPort cannula in the anteromedial portal via the shuttle FiberWire suture from the femoral drill hole, there are a lot of sutures here, which can be disconcerting	To help with suture management, follow this sequence: 1) Keep the 0-TigerLink tibial shuttle suture for the IB out of the lateral portal where the arthroscope is located 2) Have an assistant maintain tension on the 0-TigerLink and 0-FiberLink sutures in the proximal ACL fibers out the PassPort cannula. 3) Then, pass the two white shortening strands of the ALD and the TigerWire passing suture for the ALD button through the loop of the femoral shuttle suture 4) Now, pull the button (which has the FiberTape loaded as the IB) across the joint, flipping it on the lateral femoral cortex 5) Then, retrieve the TigerStick tibial shuttle suture from the lateral portal through the PassPort cannula and shuttle the two free ends of the IB down the tibia for fixation here 6) Now, cut the free ends of the 0-TigerLink and 0-FiberLink sutures and pull the shortening strands of the BTB TightRope on the femoral side for final ACL fixation.

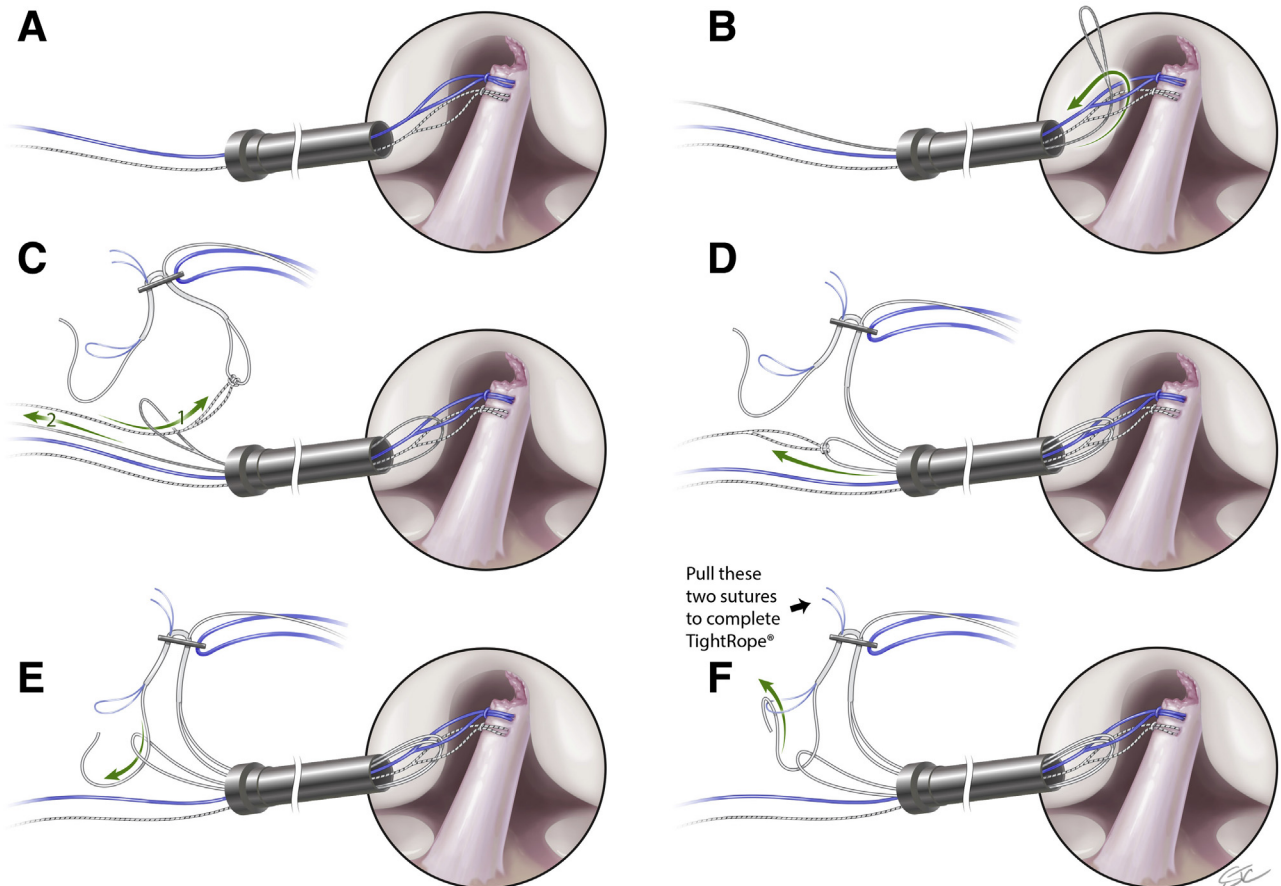
TightRope comes on a special marked card with numbers to be followed for creation of this ALD (Fig 6). The first necessary step to create the ALD is done by passing the looped end of the BTB TightRope off the special card (marked step 1) through the distal loops of the two 0-Link sutures in the joint. This is done by cutting off the attached needle from this loop and lengthening it manually. Then, a 0-FiberLink suture is placed as a cinch in this looped end of the BTB TightRope, and the free end of this suture is passed through the loop of the wire (Fig 4C). The other end of the wire is then pulled to bring the looped end of the BTB TightRope through the two distal loops of the 0-Link sutures and out the PassPort cannula (Fig 4D). This passing suture is removed from the loop, and now just following the labeled directions on the BTB TightRope card, the free suture end (step 2 on the card) is passed through the loop of the BTB TightRope (Fig 4E). Then



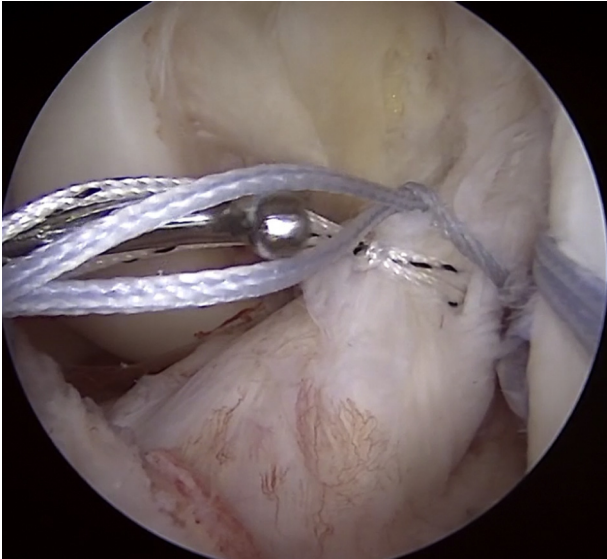
**Fig 2.** Arthroscopic view of left knee from anterolateral portal of 0-TigerLink (bottom suture) and 0-FiberLink (top suture) cinch sutures in proximal anterior cruciate ligament fibers.



**Fig 3.** A) Picture of the 0-FiberLink suture which has short closed loop available after creating cinch suture configuration; B) Picture of the 0-TigerLink suture, which also has a short closed loop available after creating cinch suture configuration.



**Fig 4.** A) 0-TigerLink and 0-FiberLink cinch sutures in proximal anterior cruciate ligament (ACL) fibers with short loops distal to cinch evident; B) Wire from Banana Lasso passed through distal loops (arrow) of both with 0-TigerLink and 0-FiberLink cinch sutures in proximal ACL fibers; C) FiberLink cinch suture attached to loop of BTB TightRope (step #1 on card) is passed through looped end of wire outside PassPort cannula (arrow 1) to shuttle this loop through the two distal loops of the 0-TigerLink and 0-FiberLink cinch sutures in proximal ACL fibers, and the wire is pulled out PassPort cannula to deliver loop (arrow 2); D) Loop of BTB TightRope now passed through the two distal loops of 0-TigerLink and 0-FiberLink cinch sutures in proximal ACL fibers exiting out PassPort cannula (arrow); E) Free suture end of BTB TightRope (step #2 on card) is now passed through the looped end of the BTB TightRope outside the PassPort cannula (arrow); F) Free suture end of the BTB TightRope is now passed through the small blue loop (step #3 on card) and pulled by the two small free end blue sutures to complete splice so this free end becomes the second shortening strand of the BTB TightRope, thus completing creation of the adjustable loop device.



**Fig 5.** Arthroscopic view of left knee from anterolateral portal of probe from anteromedial portal showing presence of two distal loops present with 0-TigerLink and 0-FiberLink cinch sutures in proximal ACL fibers.

this free suture end is passed through the small blue loop (step 3 on the card) (Fig 4F), and the two free blue suture ends are pulled to create the splice of this suture so it becomes the second shortening strand of the ALD.

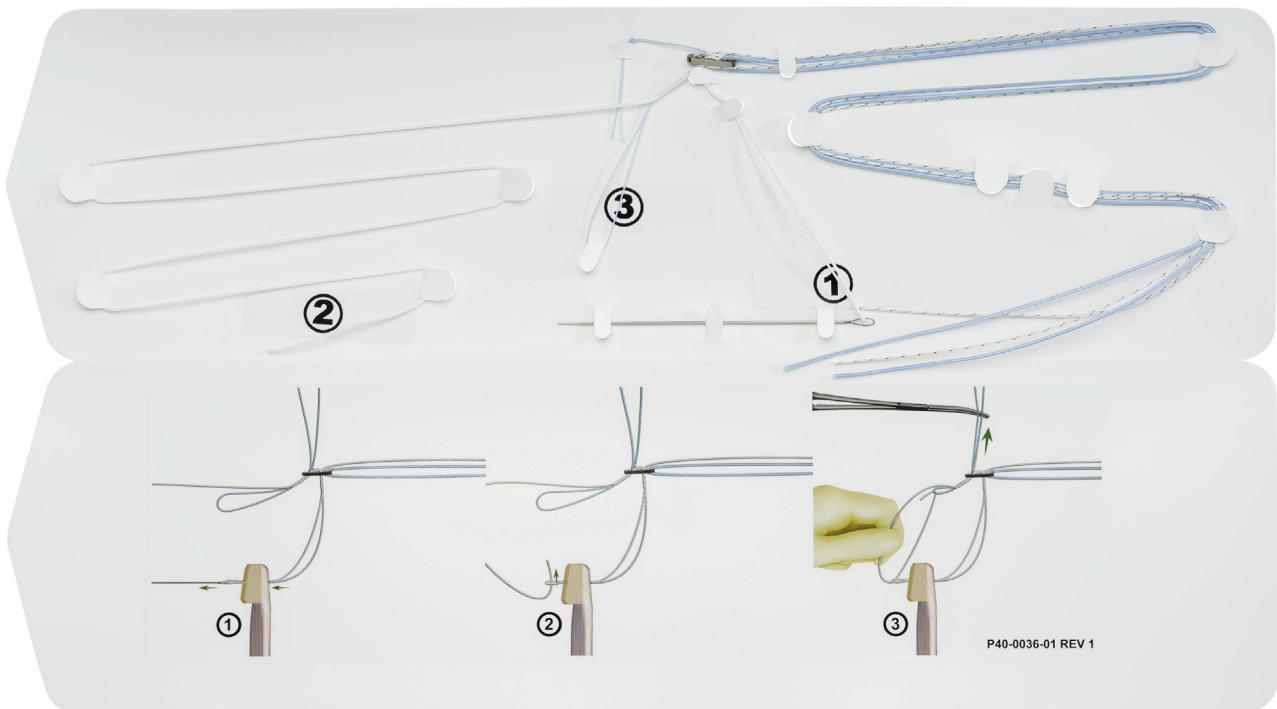
The two shortening strands of the BTB TightRope are evened out at this point as the ALD is completed.

#### Addition of Internal Brace

Next, a FiberTape is passed through the BTB TightRope to serve as an IB. This is done by passing one of the small waxed ends of the FiberTape suture centrally through the button alongside the white TightRope suture, and then the other waxed end is passed on the other side of the white TightRope suture, and then the free ends are pulled equally to bring the thicker tape over the top of the button in a horizontal mattress configuration. The free ends of the FiberTape are then on the tibial side. In this way, the IB is "independent" from the actual fixation mechanism of the shortening strands which pull on the loops of the two 0-Link cinch sutures to bring the proximal ACL tissue back up to the femur. It should be emphasized the FiberTape passed in this fashion does not interfere whatsoever with the ACL TightRope shortening strands for its tightening mechanism.

#### Passing ALD Across Femur

Now the ALD is passed with the IB across the femur. The FiberWire suture loop at the femoral socket is retrieved as a shuttle with a suture grasper through the PassPort cannula. The BTB TightRope loop is kept taut

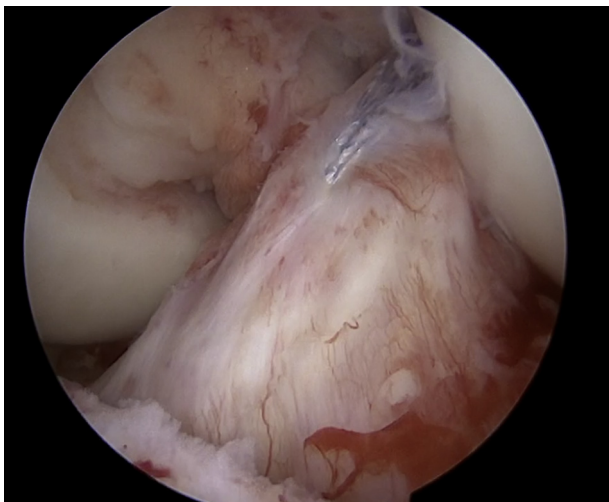


**Fig 6.** Picture of BTB TightRope card to create adjustable loop device for primary ACL repair fixation.

and the distance from the distal end of the button viewing is it would be passed out the femur is marked with the previously measured intraosseous distance of the femur. This mark facilitates the point of “flipping” of the button to avoid the need for an intraoperative x-ray. The TigerWire (Arthrex, Naples, FL) passing suture ends in the ALD button, and the two white shortening strands of the BTB TightRope are then passed through the FiberWire shuttle loop outside the PassPort cannula, and pulled across the joint into the femur “flipping” the button on the lateral femoral cortex. The two FiberTape free ends out the PassPort cannula are pulled forcefully confirming complete flippage of the BTB TightRope button on the femur, as again, the tape ends are passed through this button. Pulling tight on the FiberTape ends also ensures the button lays down securely on the lateral femoral cortex without a gap here.

### Internal Brace Fixation

Next, the two free ends of the FiberTape on the tibial side are passed through the anteromedial base of the intact native ACL fibers here. This is done by using the TigerStick shuttle suture which is retrieved through the PassPort cannula from the anterolateral portal. Attention is first directed toward fixation of the IB. This is done by drilling a 4.5 mm hole on the tibial side distal to where the TigerStick suture passes out the 3.5 mm drill hole here. This hole is then tapped, and both ends of the FiberTape are passed through the eyelet of a 4.5 mm SwiveLock Biocomposite (Arthrex, Naples, FL) anchor. Slack is taken out of both tape ends by pulling firmly. Then, holding the foot so the knee is in full extension (or hyperextension), the SwiveLock is secured to the



**Fig 7.** Completed left knee knotless primary anterior cruciate ligament repair with adjustable loop device fixation and internal brace viewing from anterolateral portal.

appropriate depth, and the tapes are cut short for knotless fixation of the IB.

### Final Fixation of ACL Repair

Next, the free ends of the TigerLink and FiberLink cinch sutures are cut, of course, distal to the cinch itself. Final fixation for the repair is done by alternating pull on the two white shortening strands of the BTB TightRope out the lateral femur, with the knee initially at 30 degrees of knee flexion. The knee is then brought into full extension (or hyperextension), and the shortening strands are pulled. Then, the knee is cycled several times from full extension (or hyperextension) to full flexion, and the shortening stands are retensioned again on the femoral side to eliminate any possible laxity or “creep” after cycling for optimal stability of the repair. This technique is considered knotless because the BTB TightRope is pulling on the loops distal to the two cinch 0-Link sutures initially placed in the torn proximal ACL fibers, so the fixation is on these loops and *not* by pulling on the cinch sutures themselves, or by tying a knot proximally to the femoral button. Pulling then on the BTB TightRope shortening strands in turn securely brings the cinch 0-Link sutures *and the* proximal ACL tissue up to the femoral wall (Fig 7).

### Rehabilitation

Early motion is instituted, beginning with a continuous passive motion (CPM) machine if feasible right after surgery. Supervised physical therapy begins on postoperative day 2 with the focus on quadriceps setting exercises and straight leg raises for full extension, along with patellar mobilization. Active knee motion is also initiated at that time. Partial weight-bearing until no limp and good leg control, which is usually 7 to 10 days. Bike starts at 2 weeks, followed by closed chain strengthening with leg press and mini-squats. Hamstring curls are also emphasized. A functional brace is utilized primarily to protect the repair because these patients do so well with minimal pain and early return of motion and overall knee function. Jogging usually is initiated at 10-12 weeks, followed by proprioceptive exercises with cutting and agility at 16-18 weeks and return to sport at 6 months.

### Discussion

Primary ACL repair has recently seen a resurgence. Advantages of saving native ACL tissue as opposed to a tendon graft reconstruction include preservation of normal ACL anatomy and potentially improved proprioception by preserving normal ACL fibers.<sup>18</sup> Furthermore, recent evidence from Vermeijden et al. indicates that individuals undergoing ACL repair can have less daily awareness of their operated knee compared with ACL reconstruction patients.<sup>19</sup> However, patient selection is critical, as proximal tears have

**Table 2.** Advantages and Disadvantages

Advantages	Disadvantages
Allows use of adjustable loop device, potentially reducing the risk of gap formation and facilitating optimal reduction of ACL tissue to the femoral wall.	Proper patient selection is key, as improper tear selection can compromise procedure if cinch sutures do not have good purchase in native torn ACL fibers.
In addition, use of ACL for repair allows for fixation in full knee extension (or hyperextension).	Assembly of adjustable loop device construct is technically demanding.
Allows augmentation with internal brace, strengthening the repair construct.	Risk of retear- but has ease of conversion to formal ACL reconstruction if need be.
Fixation is possible in full extension or hyperextension.	The procedure is so minimally invasive that patients get back knee motion very soon after surgery and “feel good” early on- so they really need to be held back from stressful activities to protect the knee for adequate healing of the primary repair.
Technique is easily amendable for use of biologic augmentation to proximal repair site.	

been shown to have the best likelihood for success (Table 2).<sup>2,6,7</sup>

In addition to proper patient selection, strength of the primary ACL repair itself is clearly another important factor to ensure a good outcome. One way to improve primary repair strength is through augmentation. One recent method of augmentation is dynamic intra-ligamentary stabilization (DIS), which utilizes an intraosseous spring-loaded screw in the tibia and has been shown to potentially restore joint kinematics to a state comparable to an ACL-intact knee.<sup>8</sup> However, concerns with this device arise from reports of increased anteroposterior (AP) translation following the procedure<sup>20</sup> and high rates of revision or nonhealing.<sup>3,21,22</sup> A recent prospective randomized clinical trial performed by Kösters et al. compared primary ACL repair with DIS to primary ACL reconstruction and found significantly increased anterior tibial translation (ATT) in the DIS group but similar failure rates between the two groups.<sup>23</sup>

Another option for augmentation involves suture tape reinforcement functioning as an internal brace (IB). A recent study was the first to report on two-year outcomes for primary repairs treated with independent suture tape IB reinforcement.<sup>11</sup> In this study, fixation of the ACL repair was done with one cinch suture tied to a femoral button with associated IB augmentation with only a 4.8% retear rate in 42 patients at two-year follow-up. Then, Jonkergouw et al. reported on their outcomes in 56 patients with at least two-year follow-up with separate suture anchor reattachment of both the anteromedial and posterolateral bundles.<sup>10</sup> They used an IB for the anteromedial bundle in some of this group and reported a 7.4% retear rate with the IB and 13.8% without its use, although they noted the overall patient numbers were underpowered. Correlating with these two published clinical papers on use of the IB was a recent biomechanical study which showed the benefit

of adding an IB to either a single or double cinch type suture configuration for a primary repair relative to decreasing overall displacement and gap formation.<sup>15</sup>

Regarding the IB use in this ALD technique, the FiberTape is passed through the ALD button, and not through the loop of the suspensory ALD, so that fixation of the IB is truly independent from fixation of the repair sutures. Therefore, this would minimize the theoretical possibility of any mechanical stress shielding of the repair itself.

Biological augmentation has also been found to enhance ACL repair. In animal models, stem cells have been shown to enhance healing in ACL injuries.<sup>24</sup> Gobbi & Whyte recently reported good to excellent long-term outcomes in a 44 patient cohort that had been treated with primary ACL repair augmented with bone marrow aspirate concentrate and platelet-rich plasma.<sup>12</sup> One technique utilizing extracellular matrix scaffolding is the bridge-enhanced ACL repair (BEAR) technique, where the scaffold used is obtained from bovine tissue and is composed of extracellular matrix proteins and collagen.<sup>25</sup> Autologous blood is added to the scaffold to soften it, where it is then conformed to the intra-articular notch to fill in the irregularities between the torn ligament ends which are brought together through transosseous sutures.<sup>25</sup> A recent two-year follow-up randomized clinical trial by Murray et al. compared 100 patients receiving either BEAR (n=65), hamstring autograft ACLR (n=33), or bone-patellar tendon-bone autograft ACLR (n=2), and they found that BEAR patients had similar outcomes an AP knee laxity to ACLR patients and superior hamstring muscle strength.<sup>13</sup>

Another way to improve strength with primary ACL repair relates to the suturing technique itself focusing on preventing gap formation, which could increase resultant laxity and failure risk, necessitating formal ACL reconstruction. The above described suture or

suture anchor primary repair techniques with either IB<sup>11</sup> or biologic augmentation<sup>25</sup> all provide static repair fixation. An intriguing alternative for primary ACL repair is for use of adjustable loop device (ALD) for primary fixation. An ALD would allow for refixation by retensioning the repair after putting the knee through a range of motion intraoperatively.<sup>26</sup> The use of an ALD for primary ACL repair was tested in an experimental model compared to use of either a single cinch or double cinch suture, or the use of a suture anchor.<sup>15</sup> This recent study found the ALD with retensioning was superior to the other three techniques and led to significantly improved stabilization and reduced gap formation, along with the highest ultimate strength compared with the other tested techniques.

In this described knotless primary ACL repair with use of an ALD, as detailed in the surgical video, the ALD is applied to the 0-FiberLink and 0-TigerLink cinch sutures placed in the native ACL fibers, taking advantage of the closed loop that is present with these particular sutures (Figs 3A and 3B). So in this technique, the BTB TightRope ALD is created by passing it through the two distal loops of the sutures so that with tensioning of the ALD shortening strands on the femur, the cinch sutures attached to the proximal ACL tissue are in turn pulled up securely to the femoral attachment site. So, there is no knot tying required. Besides the obvious advantage over other primary repair techniques with retensioning, the other critical benefit is the ability for fixation of the repair even in full knee extension. With the suture anchor technique described by DiFelice, repair fixation is typically described in at least 90° of flexion as that is necessary for placement of the anchor itself which is technically not possible toward full extension.<sup>1</sup> With the cinch suture technique described by Heusdens, tying the fixation sutures to the femoral button is also done in knee flexion, as again, it would be technically difficult to tie the knot securely to the femoral button in full extension with the soft tissue constraint of tying past the tight iliotibial band in that position.<sup>27</sup> In this described ALD technique, the shortening strands can be tightened in any degree of flexion including full extension or hyperextension, as demonstrated in the video. This is an important consideration as the normal biomechanical behavior of the ACL is lengthening 3 mm from flexion to extension, which in turn could potentially lead to gap formation at the repair site with fixation of the repair in flexion.

In addition to the advantages mentioned above, biologic augmentation for this ALD repair is possible, as the senior author has also done this same knotless primary ACL procedure by adding a demineralized bone matrix sponge soaked in bone marrow aspirate concentrate to the ALD itself. In this variation, the biologic patch is

pulled up to the femoral ACL attachment site to further enhance healing of the primary repair.

Relative to limitations with this technique, the most important is not having adequate tissue quality of the torn ACL to where good purchase is not achieved with the cinch ACL sutures, increasing the risk of suture pullout and failure. Of course, the backup would be proceeding with a formal ACL reconstruction, so it is an important part of the preoperative informed consent process to emphasize if primary repair turns out not to be feasible, then ACL reconstruction will be performed instead at the time of surgery. Similarly, there is a risk of failure of a primary ACL repair with return to full activities including sports, so patients need to be informed about that possibility, and the potential need for a later ACL reconstruction which in turn would require going through the rigorous rehabilitation process again. However, saving the normal ACL tissue with repair in a very minimally invasive way seems very advantageous over a full reconstruction drilling large bone tunnels and utilizing a tendon graft to replace this complicated ligamentous structure. Furthermore, revision ACL reconstruction after a failed repair is easy to do since bone has been preserved with just the small drill holes used on the femur and tibia, and the internal brace is very easily removed.

In conclusion, this described adjustable loop fixation for primary ACL repair has several advantages. Most importantly, it allows for intraoperative retensioning of the repair to minimize gap formation at the proximal repair site to optimize ultimate stability, which is not possible with other techniques. It is technically straightforward and allows for repair fixation easily in full extension, which again is not feasible with other previously described primary repair techniques. The ALD primary repair technique allows flexibility, as it easily incorporates needed IB reinforcement, as well as biologic augmentation, if so desired.

## References

1. DiFelice GS, Villegas C, Taylor S. Anterior cruciate ligament preservation: early results of a novel arthroscopic technique for suture anchor primary anterior cruciate ligament repair. *Arthroscopy* 2015;31:2162-2171.
2. Dabis J, Yasen SK, Foster AJ, Pace JL, Wilson AJ. Paediatric proximal ACL tears managed with direct ACL repair is safe, effective and has excellent short-term outcomes. *Knee Surg Sports Traumatol Arthrosc* 2020;28:2551-2556.
3. Kandhari V, Vieira TD, Ouanezar H, et al. Clinical outcomes of arthroscopic primary anterior cruciate ligament repair: a systematic review from the scientific anterior cruciate ligament network international study group. *Arthroscopy* 2020;36:594-612.
4. van der List JP, DiFelice GS. Primary repair of the anterior cruciate ligament: a paradigm shift. *Surgeon* 2017;15:161-168.



5. Ahmad SS, DiFelice GS, van der List JP, Ateschrang A, Hirschmann MT. Primary repair of the anterior cruciate ligament: real innovation or reinvention of the wheel? *Knee Surg Sports Traumatol Arthrosc* 2019;27:1-2.
6. Taylor SA, Khair MM, Roberts TR, DiFelice GS. Primary repair of the anterior cruciate ligament: a systematic review. *Arthroscopy* 2015;31:2233-2247.
7. van der List JP, DiFelice GS. Role of tear location on outcomes of open primary repair of the anterior cruciate ligament: a systematic review of historical studies. *Knee* 2017;24:898-908.
8. Schliemann B, Lenschow S, Domnick S, et al. Knee joint kinematics after dynamic intraligamentary stabilization: cadaveric study on a novel anterior cruciate ligament repair technique. *Knee Surg Sports Traumatol Arthrosc* 2017;25:1184-1190.
9. Ahmad SS, Schürholz K, Liechti EF, Hirschmann MT, Kohl S, Klenke FM. Seventy percent long-term survival of the repaired ACL after dynamic intraligamentary stabilization. *Knee Surg Sports Traumatol Arthrosc* 2020;28:594-598.
10. Jonkergouw A, van der List JP, DiFelice GS. Arthroscopic primary repair of proximal anterior cruciate ligament tears: outcomes of the first 56 consecutive patients and the role of additional internal bracing. *Knee Surg Sports Traumatol Arthrosc* 2019;27:21-28.
11. Heusdens CHW, Hopper GP, Dossche L, Roelant E, Mackay GM. Anterior cruciate ligament repair with independent suture tape reinforcement: a case series with 2-year follow-up. *Knee Surg Sports Traumatol Arthrosc* 2019;27:60-67.
12. Gobbi A, Whyte GP. Long-term outcomes of primary repair of the anterior cruciate ligament combined with biologic healing augmentation to treat incomplete tears. *Am J Sports Med* 2018;46:3368-3377.
13. Murray MM, Fleming BC, Badger GJ, et al. Bridge-enhanced anterior cruciate ligament repair is not inferior to autograft anterior cruciate ligament reconstruction at 2 years: results of a prospective randomized clinical trial. *Am J Sports Med* 2020;48:1305-1315.
14. Feagin JA, Abbott HG, Rokous JA. The isolated tear of the anterior cruciate ligament [abstract]. *J Bone Joint Surg Am* 1972;54:1340.
15. Bachmaier S, DiFelice GS, Sonnery-Cottet B, et al. Treatment of acute proximal anterior cruciate ligament tears-part 2: the role of internal bracing on gap formation and stabilization of repair techniques. *Orthop J Sports Med* 2020;28(8). 2325967119897423.
16. Sherman MF, Lieber L, Bonamo JR, Podesta L, Reiter I. The long-term followup of primary anterior cruciate ligament repair. Defining a rationale for augmentation. *Am J Sports Med* 1991;19:243-255.
17. Steadman JR, Rodkey WG, Rodrigo JJ. Microfracture: surgical technique and rehabilitation to treat chondral defects. *Clin Orthop Relat Res* 2001;(391 Suppl): S362-S369.
18. Dhillon MS, Bali K, Prabhakar S. *Muscles Ligaments Tendons J* 2012;2:38-43.
19. Vermeijden HD, van der List JP, O'Brien R, DiFelice GS. Patients forget about their operated knee more following arthroscopic primary repair of the anterior cruciate ligament than following reconstruction. *Arthroscopy* 2020;36: 797-804.
20. Kohl S, Evangelopoulos DS, Kohlhof H, et al. Anterior cruciate ligament rupture: self-healing through dynamic intraligamentary stabilization technique. *Knee Surg Sports Traumatol Arthrosc* 2013;21:599-605.
21. Meister M, Koch J, Amsler F, Arnold MP, Hirschmann MT. ACL suturing using dynamic intraligamentary stabilization showing good clinical outcome but a high reoperation rate: a retrospective independent study. *Knee Surg Sports Traumatol Arthrosc* 2018;26:655-659.
22. Osti M, El Attal R, Doskar W, Höck P, Smekal V. High complication rate following dynamic intraligamentary stabilization for primary repair of the anterior cruciate ligament. *Knee Surg Sports Traumatol Arthrosc* 2019;27:29-36.
23. Kösters C, Glasbrenner J, Spickermann L, et al. Repair with dynamic intraligamentary stabilization versus primary reconstruction of acute anterior cruciate ligament tears: 2-year results from a prospective randomized study. *Am J Sports Med* 2020;4:1108-1116.
24. Guo R, Gao L, Xu B. Current evidence of adult stem cells to enhance anterior cruciate ligament treatment: a systematic review of animal trials. *Arthroscopy* 2018;34:331-340.e2.
25. Murray MM, Flutie BM, Kalish LA, et al. The bridge-enhanced anterior cruciate ligament repair (BEAR) procedure: an early feasibility cohort study. *Orthop J Sports Med* 2016;4. 2325967116672176.
26. Noonan BC, Dines JS, Allen AA, Altchek DW, Bedi A. Biomechanical evaluation of an adjustable loop suspensory anterior cruciate ligament reconstruction fixation device: the value of retensioning and knot tying. *Arthroscopy* 2016;32:2050-2059.
27. Heusdens CHW, Hopper GP, Dossche L, Mackay GM. Anterior cruciate ligament repair using independent suture tape reinforcement. *Athros Tech* 2018;7:e747-e753.