

ORIGINAL RESEARCH

Emergency management of jujube pit esophageal impactions using rigid esophagoscopy in the aged

Xingmei Wei MD¹  | Jie Wang MD^{1,2} | Wen Xu MD¹

¹Department of Otorhinolaryngology Head and Neck Surgery, Beijing Tongren Hospital, Capital Medical University, Key Laboratory of Otolaryngology Head and Neck Surgery, Ministry of Education, Beijing, China

²Beijing Engineering Research Center of Audiology Technology, Beijing, China

Correspondence

Wen Xu, Key Laboratory of Otolaryngology Head and Neck Surgery, Capital Medical University, Ministry of Education, 1, Dongjiaominxiang, Dongcheng District, Beijing 100730, China.
Email: xuwendoc@126.com

Funding information

Beijing Tongren Hospital, Grant/Award Number: 2020-YJJ-ZZL-031

Abstract

Objective: To study the emergency management of esophageal jujube pit ingestion.

Study Design: Retrospective case series.

Methods: A retrospective study of 114 consecutive cases of jujube pits esophageal impaction during 3 months was performed.

Results: One hundred and fourteen cases were confirmed as jujube pit esophageal impaction using contrast-enhanced radiography. All jujube pits were retrieved using rigid esophagoscopy under general anesthesia as outpatients, except one case where a direct laryngoscope was used. In four cases, esophageal perforation was found, the patients were treated with conservative measures, and none died.

Conclusion: Jujube pit esophageal impaction is characterized by a high incidence of perforation. The conservative management of cervical perforation is effective in this study. Rigid esophagoscopy under general anesthesia is safe for jujube pit esophageal impaction.

Level of Evidence: 4.

KEYWORDS

esophageal, foreign body impaction, rigid esophagoscopy

1 | INTRODUCTION

Foreign body (FB) ingestion is a common emergency worldwide, and can be characterized by the severe complication of esophageal perforation, especially when sharp pointed objects are involved.¹

The jujube fruit is a drupe with one pit at its center. Its size varies from thumb-size to golf ball-size (approximately 42 mm) with a round or oval shape. The jujube pit has a characteristic sharp, pointed, oval shape, and can be up to 4.0 cm in the long axis.

The consumption of jujube fruits has a 4000-year history in China, and it is eaten both fresh and dried. Consumption with the pit is common in north China. Unfortunately, jujube pit ingestion can cause an impaction emergency, a frequent emergency in North China. There is a peak incidence around the Chinese Dragon Boat

Festival. To celebrate the festival, the food named *Zong zi*, made by the combination of rice and raw jujube fruit with pit, is very popular.

Robert Chisholm first introduced jujubes to America, from Europe, and they were planted in Beaufort, NC, in 1837. The consumption of jujube fruits is popular throughout Asia because of the nutritional value discovered by scientific investigation and the help of an online sales company.^{2,3} The potential risk of jujube pit impaction in the esophagus is gradually increasing with its commercial globalization. There are few studies in the English literature on the emergency management of jujube pit esophageal impaction, except for one case report of a jujube pit causing a perforated bowl in 1964.⁴ In addition, there is no standard protocol for the emergency management of esophagus perforation, especially for jujube pits.⁵

This is an open access article under the terms of the Creative Commons Attribution-NonCommercial-NoDerivs License, which permits use and distribution in any medium, provided the original work is properly cited, the use is non-commercial and no modifications or adaptations are made.

© 2021 The Authors. *Laryngoscope Investigative Otolaryngology* published by Wiley Periodicals LLC. on behalf of The Triological Society.

Therefore, to meet this shortfall, a retrospective study was conducted in 114 patients with jujube pits impacted in the esophagus.

2 | MATERIALS AND METHODS

2.1 | Patients

A total of 143 consecutive patients with esophageal foreign bodies were managed during 3 months in Beijing Tongren Hospital. One hundred and fourteen patients were diagnosed with jujube pit impaction in the esophagus and they were all given informed consent to participate in our research. The group of jujube pit esophageal impaction consisted of 40 men and 74 women, ranging in age from 19 to 88 years old. All had a history of FB ingestion, and symptoms of obvious persistent FB sensation in the root of the neck, odynophagia, and dysphagia. None of the patients had a history of esophageal disease. The detailed characteristics of the patients are shown in Table 1. Ethical approval was obtained from the Institutional Review Board at Beijing Tongren Hospital, Capital Medical University, China (No. TRECKY2017-014).

2.2 | Diagnosis

After performing a prompt and thorough history and physical examination, contrast-enhanced radiography was used to provide clues about the presence and location of the radiolucent foreign bodies. Subcutaneous emphysema in the neck is a very important symptom that indicates perforation of the cervical esophagus, and the examination should be meticulous to exclude such a problem.

Barium radiographic evaluation of the esophagus is classically used for radiolucent foreign bodies. To exclude esophageal mucosa injury with doubtful perforation, we used angiografin (76% meglumine diatrizoate compound) as the contrast agent for radiography.

Whenever perforation of the esophagus is indicated, it is imperative to use computed tomography (CT) to examine the neck and superior mediastinum. When odynophagia is the main complaint with sialorrhea and/or regurgitation, any radiography with barium or angiografin, where there is a high risk of pulmonary aspiration, is contraindicated. For those patients with no obvious history of FB ingestion and those with symptoms of dysphagia, a CT scan is also indicated.

TABLE 1 Summary of 114 cases of jujube pit esophageal impaction

Ages	Number	Associated esophageal diseases	Dysphagia	Frequency
19-35	13	No	No	11.4%
36-50	28	No	No	24.6%
51-65	41	No	No	35.9%
66-80	26	No	No	22.8%
>80	6	No	No	5.3%
Total	114			100%

2.3 | Management

Transoral rigid esophagoscopy was mainly used under general anesthesia to treat the patients. Once the shape and position of the jujube pit was confirmed, appropriate instruments, such as alligator forceps, were used. Where there were no contraindications for the use of general anesthesia, the operation was performed with a rigid esophagoscope. In those cases with chronic diseases, such as hypertension, diabetes mellitus, coronary heart disease, and mental health diseases, an emergency operation was performed under a peri-operation preparation.

2.4 | Maneuver of the rigid esophagoscope

Because both sides of the jujube pit are sharply pointed, the pits often injure the mucosa with no perforation. The key point in the procedure is turning and extracting the pit to withdraw its point while avoiding perforation. In the case of perforation of the esophagus, a nasogastric tube was simultaneously set. To avoid iatrogenic complications, such as loosening of a tooth, dislodging, or fracture of teeth or inadvertent impalement of the lip against a tooth and laceration, moist gauze was used to protect the teeth against the rigid instruments. In addition, a full examination of the esophagus was performed after removing the jujube pits to evaluate for multiple foreign bodies, esophageal injury, and underlying esophageal disorders, for example, neoplasm, stricture, or eosinophilic esophagitis.

2.5 | Postoperative management

Resumption of the oral diet depends on the esophageal mucosa. Generally, patients with no obvious mucous injury had an uneventful recovery and were discharged home with feeding starting 4 to 6 hours later. Patients for whom perforation was suspected were treated with broad-spectrum antibiotics and advised to stop oral feeding. It was imperative that continuous monitoring of the symptoms of odynophagia, chest pain, neck pain, fever, and cutaneous emphysema in the neck were performed. If perforation with small leaks in the cervical esophagus is identified, the patient should be admitted and closely monitored. They should be given intravenous, broad-spectrum antibiotics to cover the flora of the upper aerodigestive tract, total parenteral nutrition (TPN), continuous transnasal gastric decompression, and H₂-blockers or proton pump inhibitors for 7 to 10 days until

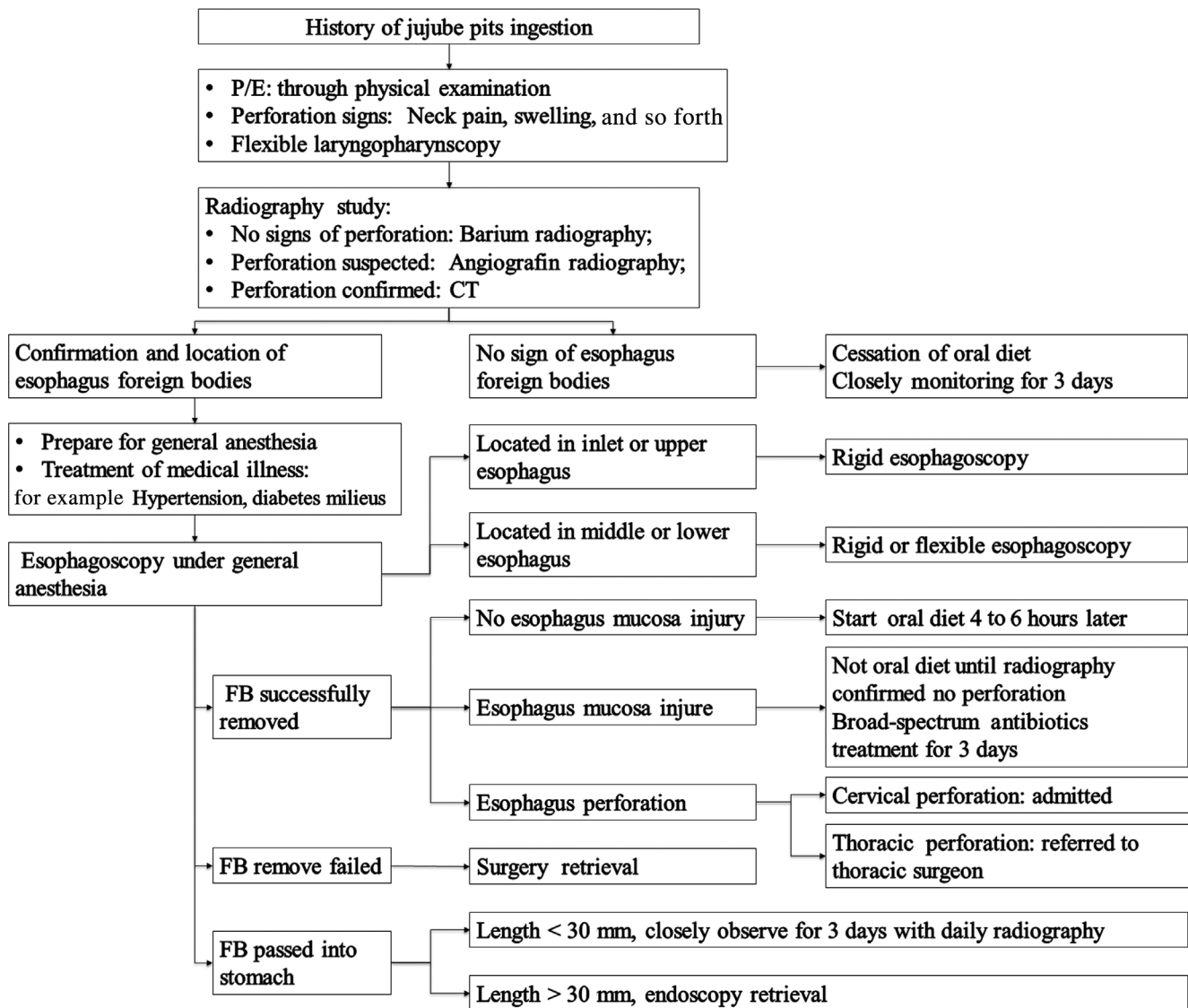


FIGURE 1 Flow chart of emergency management of jujube pit esophageal ingestion

the angiografin radiography is negative.⁶ When there is a leak in the thoracic segment, the patient is referred to a thoracic surgeon for extensive management.⁶ If there are signs of abscess formation, drainage is instantly performed and the time before the resumption of oral diet was prolonged. The flowchart of emergency management of jujube pits is shown in Figure 1.

3 | RESULTS

In this study, 143 cases of esophageal foreign bodies were found during a period of 3 months. Except of 114 case of jujube pit were confirmed, other FB ingestions were fish bones (16/143), poultry bolus (6/143), dentures (5/143) and others (2/143). As showed in Tables 1, 114 cases of jujube pit ingestion were present, comprising 79.7% (114/143) of the total. And there is a high incidence of 35.9% in people who are between 51 and 65 years old. The other two

relatively high incidences were in the age ranges of 36 to 50 and 66 to 80, which were 24.6% and 22.8%, respectively. None of these cases presented with esophageal disease or symptoms of dysphagia.

In Table 2, we show that most impactions occurred in the anatomic locations of inlet (C6-7) and upper (T1-2) segment of the esophagus with rates of 55.3% (63/114) and 33.3% (38/114), respectively. Four cases presented with esophageal perforation intra-operatively. Three of these were in the area of the inlet of the esophagus. The other case of perforation occurred in the upper segment of the esophagus. As shown in Table 3, all four cases had a long history of jujube pit ingestion over 12 hours up to 72 hours. All of four cases of esophageal perforation treated conservatively using the aforementioned methods lacked local and general complications (Table 4).

In this series (Table 2), there were only 7.9% (9/114) cases of impaction of the mid-esophagus (T3-4) segment and 3.5% (4/114) cases in the lower esophagus (T5). No perforations were found in

TABLE 2 Anatomic locations of the jujube pit ingestion and complications of esophagus perforation

Anatomic location	Number (percent)	Perforation of the esophagus (percent)
Inlet of the esophagus (C6-C7)	63 (55.3%)	3 (2.6%)
Upper esophagus (T1-T2)	38 (33.3%)	1 (0.9%)
Middle esophagus (T3-T4)	9 (7.9%)	0
Lower esophagus (T5)	4 (3.5%)	0
Total	114 (100%)	4 (3.5%)

TABLE 3 Duration of jujube pit impaction and complications

Duration	Number	Perforation of the esophagus
<12 h	110	0
12-24 h	1	1
24-48 h	2	2
48-72 h	0	0
>72 h	1	1
Total	114	4

these locations. All cases confirmed with jujube pit impaction showed signs of odynophagia.

All jujube pit ingestions were removed using rigid esophagoscopy under general anesthesia, except case 1 of a large impaction in the inlet of the esophagus. This case was a 72-year-old woman who complained of swallowing a jujube pit for 3 days with progressive severe odynophagia, sialorrhea, neck pain, and fever. In this case, an emergency rigid esophagoscopy was performed under general anesthesia. Intraoperatively, we found an oval jujube pit, sized 23 mm in its long axis that was impacted in the inlet of the esophagus, and both its sharp points penetrated into the mucosa (Figure 2). After it had been extracted with the aid of a direct laryngoscope, a naso-gastric decompression tube was simultaneously set. An oral diet was not started until the radiography with angiografin showed no signs of perforation. A broad-spectrum antibiotic was given as well as TPN therapy for 7 days.

Another three cases presented with perforations during the operation, and there were signs of odynophagia and neck pain. All were cured after 7 to 10 days of continuous nasal-gastric decompression, antibiotic therapy, TPN, and proton pump inhibitors. No abscesses were found.

TABLE 4 Summary of four cases of esophageal perforations

Case	Sex/years	Duration	Location of perforation	Operation	Post-operative treatment methods & days	Complications
1	F/72	80 h	C6-7	RE + DL	C/7 days	No
2	F/58	32 h	C7-T1	RE	C/10 days	No
3	F/50	26 h	T1-2	RE	C/7 days	No
4	F/72	15 h	C7	RE	C/7 days	No

Abbreviations: C, conservative; DL, direct laryngoscopy; F, female; RE, rigid esophagoscopy.

The same team performed all procedures that were described, and the average operation time was approximately 3 minutes. There were no signs of perforation, iatrogenic complications, multiple FBs, or esophageal disease.

4 | DISCUSSION

4.1 | High incidence of jujube pit ingestion

In this study, the incidence of esophageal impaction of jujube pits is high, accounting for 79.7% of a consecutive group of 143 patients. Jujube (*Ziziphus jujube* Mill) is indigenous to China and is widely distributed in the north. Its fruits contain several constituents that are considered to have multiple bioactivities, such as anti-inflammatory, antioxidant, anti-insomnia, and immune-stimulating effects.⁷ The jujube pits are sharp and pointed as well as have a variable in size up to 40 mm in their long axis (Figure 3). In contrast, the circo-pharyngeal sphincter in the cervical esophagus is the narrowest area in the gastrointestinal tract, at approximately 14 mm in diameter.⁸ The size of the pit as well as its shape is the reason for their frequency of causing impaction. In view of the value of the jujube pit as reported in the literature,⁷ consumption of the raw jujube fruits with pits is popular in north China, especially in adult people, leading to the high incidence of jujube pit impaction management in ENT emergency.

4.2 | Signs & symptoms of jujube pit impaction

In this study, all cases with jujube pit impaction in the proximal esophagus presented with odynophagia; four cases with cervical perforation presented with continuing neck pain. These results are higher than the 70% cases of perforation presenting with neck pain that were reported by Hasimoto et al in a systematic review of the literature.⁹ The systematic review by Aronberg et al (2014) showed that esophageal perforation due to a FB presenting with odynophagia/neck pain accounted for 82.7%.⁵ Unfortunately, there is no detailed information on the cause of esophageal perforation. In view of the sharp shape of the jujube pit and characteristic of esophagus perforation, any patient presenting with odynophagia, neck pain, and a history of jujube pit ingestion should receive a detailed examination.¹

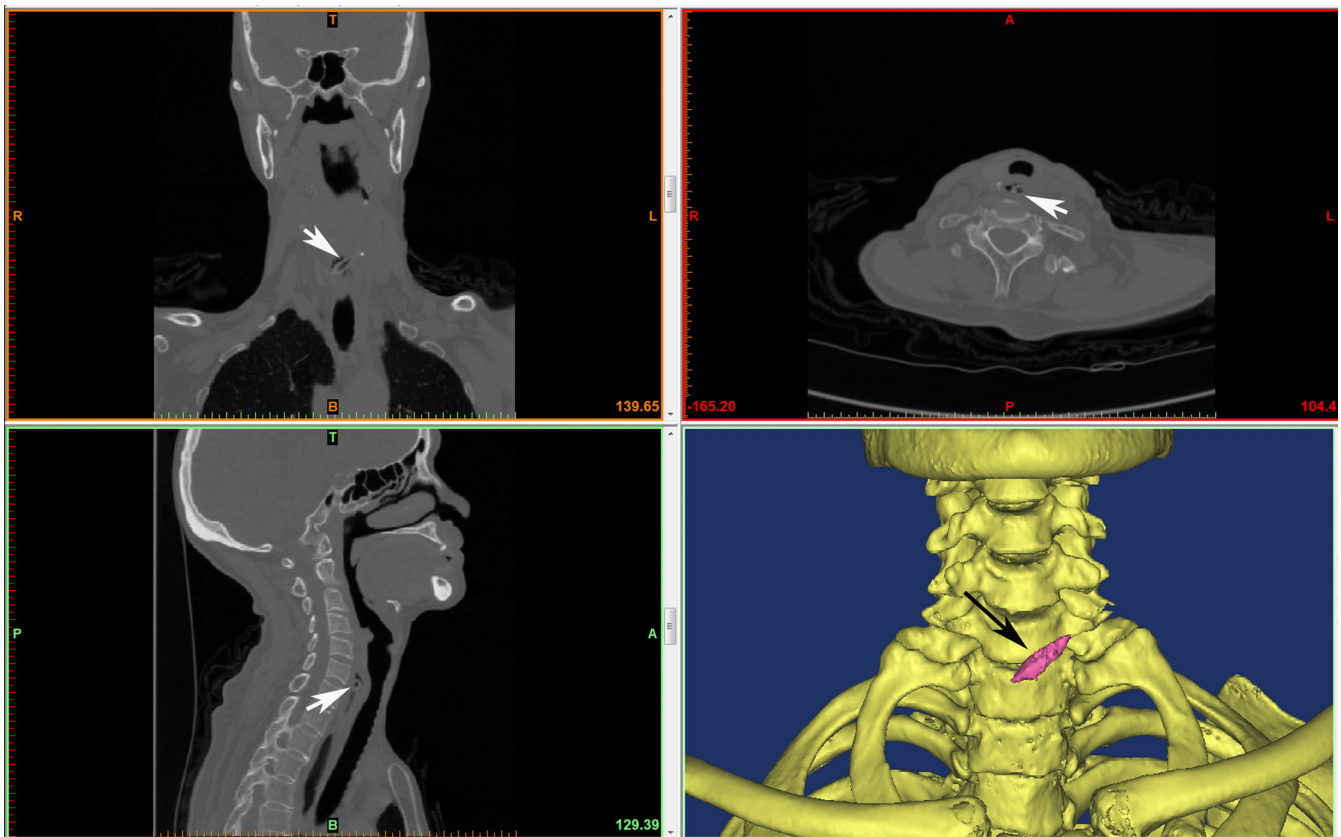


FIGURE 2 Jujube pits impacted in the inlet of the esophagus shown in CT scanning with image of axial (black arrow), sagittal (black arrow), coronal (black arrow) and 3D reconstruction (white arrow). A, anterior; B, bottom; CT, computed tomography; L, left; P, posterior; R, right; T, top

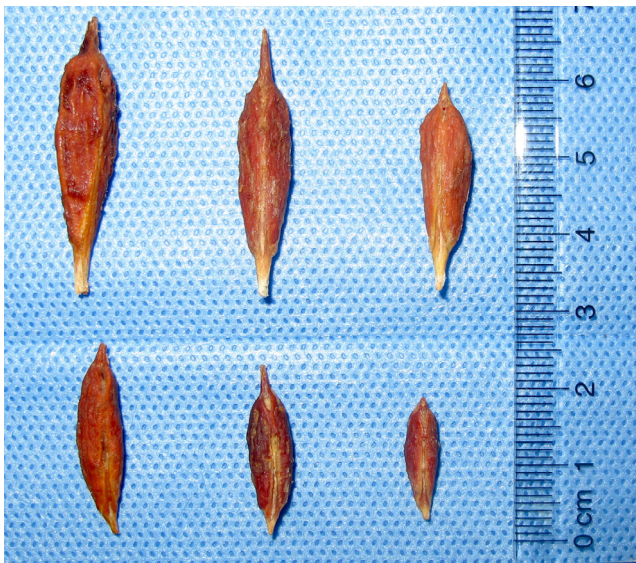


FIGURE 3 Jujube pits with various sizes

4.3 | Diagnosis and management of jujube pit impaction

Patients with a definite history of jujube pit swallowing and who present with odynophagia would indicate a jujube pit impaction in

the esophagus. Progressive severe odynophagia, dysphagia, or chest pain indicates mucosa injury or extra-esophageal infiltration. When subcutaneous emphysema in the neck is present, perforation should be suspected. In this circumstance, barium radiography is contraindicated. A contrast examination will generally be performed to define its location, which is different from that of the guidelines for managing ingested foreign bodies and food impactions published by American Society for Gastrointestinal Endoscopy (ASGE) in 2011.¹ In those guidelines, a contrast examination is generally not recommended because of the risk of aspiration. In this study, there were no cases of aspiration. We used angiografin as contrast agent in the case of sialorrhea and severe neck pain, which are signs of an object impacted in the upper inlet of the esophagus, indicating that the mucosa may be injured. The angiografin used in this study is a compound of meglumine diatrizoate with 76% of iodine, which is used in angiography. Whenever there was perforation, the angiografin leaks outlined the size and position of the perforation. Aspiration of angiografin was considered safer than barium.

In this study, all cases confirmed as jujube pit ingestion received surgical intervention using the main rigid esophagoscopy. Although 80% to 90% of the ingested objects could pass through the gastrointestinal tract in the literature, there were no cases of jujube pits passing spontaneously into the stomach in this study.¹⁰

4.4 | Rigid vs flexible esophagoscopy of jujube pit impaction

Emergency transoral esophagoscopy under general anesthesia to remove the ingested object is reliable.¹¹ However, the use of flexible or rigid esophagoscopy is still controversial.¹¹ Having the advantages of avoiding general anesthesia for majority of adults, flexible esophagoscopy reduces the cost, and has good visualization. However, in view of the sharp points of the jujube pits, which can injure the mucosa with a high likelihood of perforation, it is difficult to grasp the jujube pits with flexible esophagoscopy's small forceps. In addition, jujube pits mainly located at the entrance of the esophagus, for example, in this study, 88.6% of the jujube pit impaction cases were located around the inlet of the esophagus, and this area has the limited working space and it is restricted for the flexible esophagoscope. To obtain good visualization, air insufflation is used before the flexible endoscope enters the pyriform sinus or post cricoid area, which may result in bad visualization of the inlet of the esophagus. In contrast, though the rigid esophagoscopy has the disadvantages for needing for general anesthesia and having the risk of tooth loss, the rigid esophagoscopy can directly visualize the inlet of esophagus and provides a good view, allowing the object to be grasped and withdrawn with the sharp points trailing to avoid perforation. What is more, the rigid esophagoscopy has larger forceps that can grasp the curved outwards jujube pits.¹² The various forceps of rigid esophagoscope are showed in Figure 4, and they are chosen according to the shapes and sizes of foreign bodies. The head of most usually used alligator forceps (the leftmost one) is about 26 mm long and can hold most jujube pits. As a consequence, it is recommended that rigid esophagoscopy be used for the removal of sharp, pointed jujube pits, especially in the inlet and upper segments of the esophagus. The flexible esophagoscopy may be more suitable for cases with a small jaw, cervical deformities, severe spinal arthritis or where an unsteady cervical vertebra is suspected. There was a system review of 10 835 patients about esophageal foreign bodies and the results showed that a flexible endoscopic was for 65.1% of patients and a rigid endoscopic approach was for 16.8% of

patients, but the foreign bodies were mainly stuck by fish or chicken bones which were more liable for flexible endoscopic to grasp.¹³ Chen et al. showed that 8 out of 78 patients failed extraction using flexible endoscopy.¹⁴ Zhang et al's research about 66 patients impacted by jujube pits underwent a rigid esophagoscopy showed that 18 (27.27%) of these patients had previously undergone a flexible esophagoscopy without FB removal.¹² However, in this study, only one case (0.87%) failed and was retrieved later using a direct laryngoscope.¹

4.5 | Management of complications

Complications of perforation secondary to esophageal foreign bodies are rare; there are fewer than 2% reported in the literature.¹⁵ However, the incidence of perforation caused by jujube pits is 3.5% (4/114) and the gross perforation rate is 2.8% (4/143) in this study, which is higher than that reported in previous studies. However, the causes of esophageal perforation in the literature are extremely heterogeneous.⁵ For example, 79.7% of the foreign bodies found in this study are jujube pits. By contrast, the most frequent impaction of the esophagus in adults is a food bolus in South China, America, and other European countries.¹⁶⁻¹⁸ We found that jujube pit impaction in the esophagus is a common occurrence in normal adult, except in specific, high-risk adults, such as those with underlying esophageal disease, with the sequelae of intracranial injury, and those with dentures. The characteristics of the size and sharp points of jujube pits may explain this finding. The perforation rate seemed to correlate with the time of duration of impaction.

There were no cases of mortality or complications in this study. However, a pooled mortality of cervical perforation reviewed by Biancari et al was as high as 5.9%.¹⁹ This is partly because the causes of esophageal perforation reported in the literature are extremely heterogeneous and partly because the cervical anatomical places may limit the spread of infection and separates it from mediastinum as well as because of the limited number of cases in this study.^{19,20}

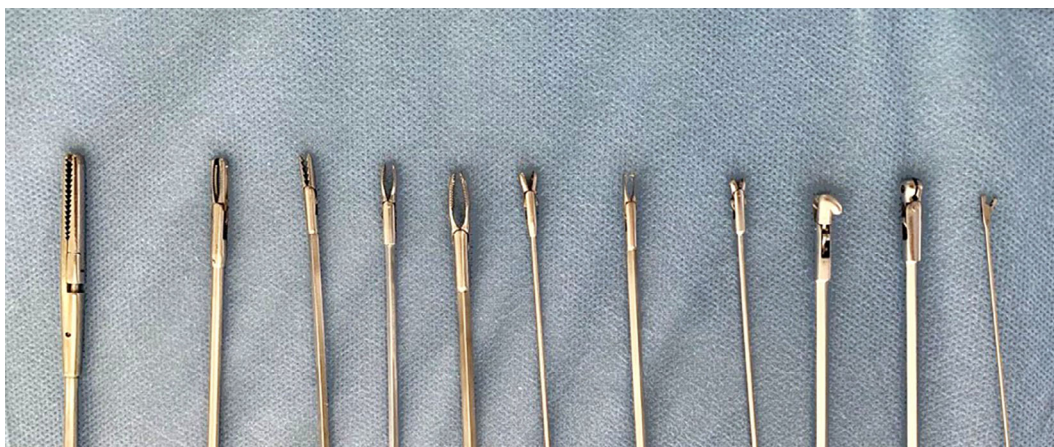


FIGURE 4 Show of various rigid forceps

5 | CONCLUSION

The pit has a characteristic sharp pointed oval shape, is prone to injure the mucosa and is difficult to retrieve, causing a high incidence of esophageal impaction and esophageal perforation. Rigid esophagoscopy would be a safe and effective method for removing jujube pits. Further study on comparison of rigid and flexible esophagoscopy is needed.

CONFLICT OF INTEREST

The authors have no personal financial or institutional interests in any of the drugs, materials, or devices described in this article.

ORCID

Xingmei Wei  <https://orcid.org/0000-0001-7188-485X>

BIBLIOGRAPHY

- Ikenberry SO, Anderson TL, Appalneni MA, et al. Management of ingested foreign bodies and food impactions. *Gastrointest Endosc*. 2011;73(6):1085-1091.
- Guo S, Duan JA, Qian D, et al. Content variations of triterpenic acid, nucleoside, nucleobase, and sugar in jujube (*Ziziphus jujuba*) fruit during ripening. *Food Chem*. 2015;167:468-474.
- Chen J, Yan AL, Lam KY, et al. A chemically standardized extract of *Ziziphus jujuba* fruit (jujube) stimulates expressions of neurotrophic factors and anti-oxidant enzymes in cultured astrocytes. *Phytother Res*. 2014;28:1727-1730. doi:10.1002/ptr.5202. [Epub ahead of print].
- Lavers GD, Feldmayer JE. Jujube. A case of perforated bowel. *Calif Med*. 1964;101:206-267.
- Aronberg RM, Punekar SR, Adam SI, Judson BL, Mehra S, Yarbrough WG. Esophageal perforation caused by edible foreign bodies: a systematic review of the literature. *Laryngoscope*. 2014;125:1-8. doi:10.1002/lary.24899. [Epub ahead of print].
- Jiang JN, Yu T, Zhang YF, Li JY, Yang L. Treatment of cervical esophageal perforation caused by foreign bodies. *Dis Esophagus*. 2012;25(7):590-594.
- Gao QH, Wu CS, Wang M. The jujube (*Ziziphus jujuba* Mill.) fruit: a review of current knowledge of fruit composition and health benefits. *J Agric Food Chem*. 2013;61(14):3351-3363.
- Benjamin S, Noguera E. Foreign bodies. In: DRJ C, ed. *The Esophagus*. 4th ed. Philadelphia: Lippincott Williams & Wilkins; 2004:340-353.
- Hasimoto CN, Cataneo C, Eldib R, et al. Efficacy of surgical versus conservative treatment in esophageal perforation: a systematic review of case series studies. *Acta Cir Bras*. 2013;28(4):266-271.
- Eisen GM, Baron TH, Dominitz JA, et al. Guideline for the management of ingested foreign bodies. *Gastrointest Endosc*. 2002;55(7):802-806.
- Gmeiner D, von Rahden BH, Meco C, Hutter J, Oberascher G, Stein HJ. Flexible versus rigid endoscopy for treatment of foreign body impaction in the esophagus. *Surg Endosc*. 2007;21(11):2026-2029.
- Zhang X, Zhang X, Tu C, Yu Q, Fu T. Analysis of the management and risk factors for complications of esophageal foreign body impaction of jujube pits in adults. *Wideochir Inne Tech Maloinwazyjne*. 2018;13(2):250-256.
- Aiolfi A, Ferrari D, Riva CG, Toti F, Bonitta G, Bonavina L. Esophageal foreign bodies in adults: systematic review of the literature. *Scand J Gastroenterol*. 2018;53(10-11):1171-1178.
- Chen T, Wu HF, Shi Q, et al. Endoscopic management of impacted esophageal foreign bodies. *Dis Esophagus*. 2013;26(8):799-806.
- Sung SH, Jeon SW, Son HS, et al. Factors predictive of risk for complications in patients with oesophageal foreign bodies. *Dig Liver Dis*. 2011;43(8):632-635.
- Li ZS, Sun ZX, Zou DW, Xu GM, Wu RP, Liao Z. Endoscopic management of foreign bodies in the upper-GI tract: experience with 1088 cases in China. *Gastrointest Endosc*. 2006;64(4):485-492.
- Athanassiadi K, Gerazounis M, Metaxas E, Kalantzi N. Management of esophageal foreign bodies: a retrospective review of 400 cases. *Eur J Cardiothorac Surg*. 2002;21(4):653-656.
- Long B, Koyfman A, Gottlieb M. Esophageal foreign bodies and obstruction in the emergency department setting: an evidence-based review. *J Emerg Med*. 2019;56(5):499-511.
- Biancari F, D'Andrea V, Paone R, et al. Current treatment and outcome of esophageal perforations in adults: systematic review and meta-analysis of 75 studies. *World J Surg*. 2013;37(5):1051-1059.
- Jones WG, Ginsberg RJ. Esophageal perforation: a continuing challenge. *Ann Thorac Surg*. 1992;53(3):5345-5343.

How to cite this article: Wei X, Wang J, Xu W. Emergency management of jujube pit esophageal impactions using rigid esophagoscopy in the aged. *Laryngoscope Investigative Otolaryngology*. 2021;6(6):1332-1338. doi:10.1002/lio2.677