

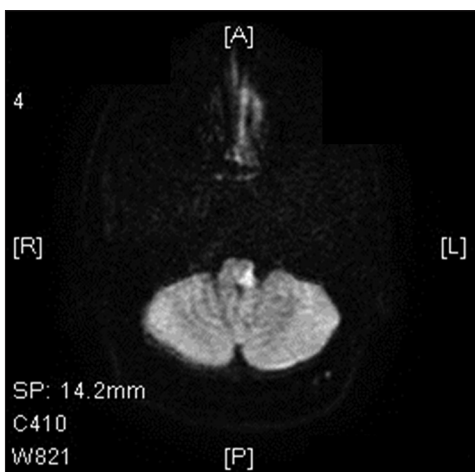
## Mobile Phone–Induced Vertebral Artery Dissection

Sir,

Mobile phones have become an essential part of our accessories. Many of the working class people such as telephone operators use mobile phones for telephonic conversations lasting several hours as a part of their daily work schedule. Many youngsters hold the mobile phone between the neck and the shoulder for long duration especially during driving and doing activities involving both the hands such as typing on a keyboard. We report one such young man who had a devastating complication of vertebral artery dissection due to prolonged telephonic conversation with his neck in the laterally flexed position.

A 28-year-old male with no premorbid illness presented to us with 4-day history of ataxia, transient diplopia, and dysphagia. Examination revealed left-sided palatal palsy, ataxia with swaying to left while walking, and impaired sensations on left side of face and right half of the body. Clinical diagnosis of left lateral medullary syndrome was made. A computed tomography of the head was done on the first day, which was normal. Magnetic resonance imaging (MRI) done the next day showed restricted diffusion at left lateral medulla [Figure 1]. He started improving from the second day.

Since there were no known vascular risk factors such as hypertension, diabetes, smoking, or heart disease, we revisited the history. The patient was working as mobile phone technician and his receptionist was on leave for a day. He was working with both his hands and receiving phone calls by holding the mobile phone in between his shoulder and left ear by laterally flexing the neck. He kept the phone in that position even when there were no calls as both the hands were occupied, probably would have kept his neck in that position for more than 6 hrs. On that day, night he developed pain around lateral aspect of neck and on getting up on the next day he found himself ataxic.

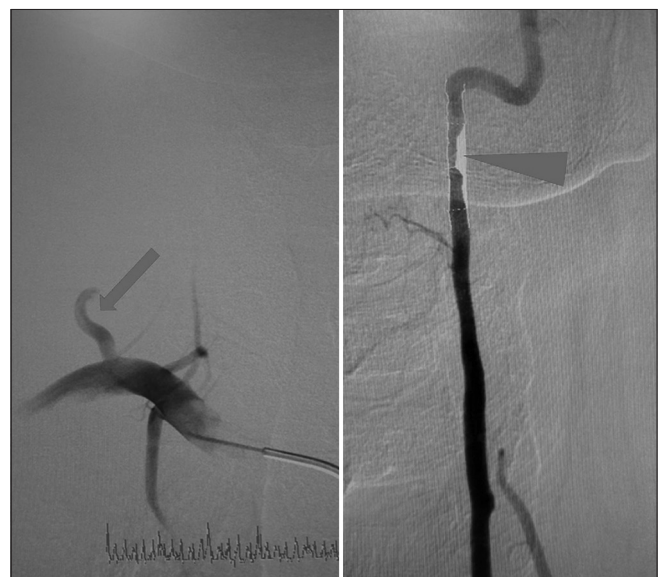

**Figure 1:** Magnetic resonance imaging brain diffusion weighted imaging showing diffusion restriction in left lateral medulla suggesting acute infarction

As MRI showed left lateral medullary infarct, clinically vertebral artery dissection was considered. Digital subtraction angiography (DSA) done showed left vertebral artery V2-V3 portion dissection distally causing around 50% stenosis and hypoplastic right vertebral artery [Figure 2]. Since patient was already improving and the stenosis was only around 50%, he was treated conservatively with heparin and later with oral anticoagulants with good recovery. Proper history obviates the need for unnecessary investigations such as those for hypercoagulable states and connective tissue diseases in young patients with stroke. DSA repeated 8 months later showed complete recanalization of the vertebral artery.

Cervical artery dissection is a known cause of stroke in young adults.<sup>[1,2]</sup> However, it is underdiagnosed.<sup>[3]</sup> It is suspected in patients with history of recent neck trauma or starting of exercises in the gym.<sup>[4]</sup> Chiropractic manipulation of the neck has been recognized as an important cause of dissection and doctors especially neurologists are very wary of this practice.<sup>[5]</sup> However, most people use the telephone between the neck and shoulder while using both the hands for some other activity, such as typing on a keyboard or driving a bike. Using mobile phones during driving can be dangerous in itself. Moreover, this prolonged lateral flexion of the neck can be disastrous as it can cause serious consequences, such as a stroke.

Mobile phones have become an essential part of human lifestyle. However, its usage has been associated with a host of health problems including eye strain, sleep disturbances, etc., Usage in the inappropriate time such as driving and position such as described above can be fatal. Public



**Figure 2:** Digital subtraction angiography showing hypoplastic right vertebral artery (arrow) and left vertebral artery showing dissection flap (arrow head)

awareness regarding proper usage of mobile phones such as advertisements in mass media and social media is the need of the hour. Mobile phone usage should be restricted as far as possible while working with both hands or headsets should be used during such activities.

### Declaration of patient consent

The authors certify that they have obtained all appropriate patient consent forms. In the form the patient(s) has/have given his/her/their consent for his/her/their images and other clinical information to be reported in the journal. The patients understand that their names and initials will not be published and due efforts will be made to conceal their identity, but anonymity cannot be guaranteed.

### Financial support and sponsorship

Nil.

### Conflicts of interest

There are no conflicts of interest.

**Arunmozhimaran Elavarasi, Thekkumpurath Moyinul Haq,  
Thekkumpurath Thahira, Chiminikkara Bineesh, Lakshmana B. Kancharla**

Department of Neurology and Interventional Neurology, EMS Memorial  
Cooperative Hospital, Perinthalmanna, Kerala, India

**Address for correspondence:** Prof. Thekkumpurath Moyinul Haq,  
EMS Memorial Co-operative Hospital, Perinthalmanna - 679 382, Kerala, India.  
E-mail: drhaq1971@yahoo.com

### REFERENCES

1. Thanvi B, Munshi SK, Dawson SL, Robinson TG. Carotid and vertebral artery dissection syndromes. *Postgrad Med J* 2005;81:383-8.
2. Schievink WI, Mokri B, Piepgras DG. Spontaneous dissections of cervicocephalic arteries in childhood and adolescence. *Neurology* 1994;44:1607.
3. Fisher CM, Ojemann RG, Roberson GH. Spontaneous dissection of cervico-cerebral arteries. *Can J Neurol Sci J Can Sci Neurol* 1978;5:9-19.
4. Anadure RK, Mohimen A, Saxena R, Sivasankar R. A study on the clinical and angiographic spectrum of spontaneous extracranial dissections in the cerebral vasculature. *J Neurosci Rural Pract* 2018;9:344-9.
5. Haldeman S, Carey P, Townsend M, Papadopoulos C. Clinical perceptions of the risk of vertebral artery dissection after cervical manipulation: The effect of referral bias. *Spine J Off J North Am Spine Soc* 2002;2:334-42.

---

This is an open access journal, and articles are distributed under the terms of the Creative Commons Attribution-NonCommercial-ShareAlike 4.0 License, which allows others to remix, tweak, and build upon the work non-commercially, as long as appropriate credit is given and the new creations are licensed under the identical terms.

**DOI:** 10.4103/aian.AIAN\_123\_19