

# Nested melanoma

Davide Zardo,<sup>1</sup> Antonio Perasole,<sup>2</sup> Cesare Massone<sup>3</sup>

<sup>1</sup>Department of Pathology, San Bortolo Hospital, Vicenza; <sup>2</sup>Consultant Histopathologist, Cerba Healthcare – RDI Limena (PD); <sup>3</sup>Division of Dermatology, EO Galliera, Genoa, Italy

---

## Pathological meeting

This case was presented at the on-line meeting on the ADOI platform held on October 27<sup>th</sup> 2021 by Dr Zardo.

Surgical pathologists attending the meeting: 18.

Surgical pathologists that reviewed the slides before the meeting: 12.

---

## Clinical data

Caucasian 29 years old female; enlarging pigmented lesion on the calf with asymmetric pigmentation. Concern of the patient. Clinical pictures not available.

---

## Histopathology

*Virtual slides are available at:*

<https://www.dropbox.com/sh/5v4ydf0o1t5x0th/AACqtKvynw mDNL6wwYrdPSp3a?dl=0>

## Description

Asymmetric, not sharply circumscribed, mostly junctional melanocytic proliferation composed predominantly by nests that are different one from another, with different shape and dimension, asymmetric disposition and with uneven distribution of pigment. The nests are expansile and push the epidermis from the bottom squeezing the stratum spinosum. The epidermis shows focal pigmented parakeratosis and pigmentation of basal keratinocytes. At one edge of the lesion, atypical melanocytes in single unit are present in the stratum spinosum. Irregular nests are present also in the superficial dermis, together with melanophages, few dendritic melanocytes and a very sparse lymphocytic infiltrate. Mild solar elastosis is present. Melanocytes with long dendrites are found also in the epidermis, within the nests (the whole description refers to Figures 1 to 8 and virtual slides). Few mitotic figures were seen.

## Immunohistochemistry

Positivity for Melan-A, BRAF-V600E and PRAME.

Heterogenous positivity for HMB-45 (some nests are positive, others are negative)

## Molecular biology

Not performed

## Premeeting survey

Virtual slides were reviewed by 12 surgical pathologists before the meeting (Table 1).

Five pathologists favored a common acquired nevus, six agreed on melanoma (three nevoid melanoma), one pathologist was uncertain.

The level of confidence was judged as low by 6 pathologists, average by four and high by two of them.

The complexity of the case was reported as “high” by 8 pathologists, “average” by two and “low” by two of them.

## Meeting real-time survey

This case was presented to 18 Italian surgical pathologists. After collegial discussion, 16 of them agreed on the diagnosis of nested (nevoid) melanoma, one favored a combined nevus and one a congenital nevus.

---

## Discussion

The term “nevoid melanoma” applies theoretically to all melanomas simulating on pathology a benign nevus.<sup>1,2</sup> The first description of melanomas that are deceitfully similar to their benign counterparts occurred in the ‘80 by Levene,<sup>3</sup> and subsequently also the definition of “minimal deviation melanoma”, “small cell melanoma” or “spitzoid melanoma” among other have been used. However, even if there is general agreement that in some cases primary melanomas and melanoma metastasis may show overlapping histopathological features with benign nevi, precise criteria and classification are still lacking.

Some authors distinguish two types of nevoid melanomas: a papillomatous subtype, and the dome-shaped, nonpapillomatous nevoid melanoma (by some also called ‘maturing naevoid’).<sup>4</sup> According to Massi and LeBoit a third category including nested melanoma should be added.<sup>5</sup> Others divide nevoid melanoma into 5 main categories according to the simulated nevus: (1) nevoid melanoma with dysplastic nevus-like pattern; (2) nevoid melanoma with congenital nevus-like pattern; (3) nevoid melanoma with Reed nevus-like pattern (4) nevoid melanoma with dermal nevus-like pattern (papillomatous or dome-shaped); and (5) nevoid melanoma with hypermelanotic nevus-like pattern.<sup>2</sup> There is general agreement not to use the definition of nevoid melanoma for those lesions with architectural and/or cytomorphological features similar to Spitz nevus, as this last may be characterized by atypical cytomorphological features. In fact, in the new WHO classification Spitz melanoma is considered as a distinct variant of melanoma.<sup>6</sup>

Nested melanoma of the elderly is a peculiar variant of superficial melanoma characterized by predominance of large, irregular, confluent nests of melanocytes simulating nested junctional nevi and belonging to the heterogeneous spectrum of nevoid melanomas.<sup>2,5,6</sup>

Criteria favouring the diagnosis of nevoid melanoma are: advanced age of patients, large size of the lesion, architectural disarray of nests regarding size, distribution and shape, and even mild spread

of single melanocytes above the dermoepidermal junction, presence of actinic elastosis. Cannonball-like irregular nests strikingly predominating over solitary melanocytes, focal pagetoid spread of melanocytes and thinning of epidermal rim surrounding the nests are peculiar features of nested melanomas.<sup>1-6</sup>

Clinical features are aspecific; dermoscopic findings are irregular globular pattern, atypical vessels and/or irregular dots/globules.<sup>7</sup>

In the case herein presented the college of pathologists agreed on the diagnosis of invasive nested (nevoid) melanoma (T1a; Breslow thickness: 0.6mm) because of asymmetry of the lesion and pigment distribution, predominance of irregular nests with varying size and shape, presence of dendritic melanocytes in the epidermis, focal pagetoid spread and mitoses.

---

## References

1. Cook MG, Massi D, Blokx WAM, et al New insights into naevoid melanomas: a clinicopathological reassessment. *Histopathology* 2017;71:943-50.
2. Saggini A, Cota C, Lora V, et al. Uncommon Histopathological Variants of Malignant Melanoma. Part 2. *Am J Dermatopathol* 2019;41:321-42.
3. Levene A. On the histological diagnosis and prognosis of malignant melanoma. *J Clin Pathol* 1980;33:101-24.
4. Idriss MH, Rizwan L, Sferuzza A, et al. Nevoid melanoma: a study of 43 cases with emphasis on growth pattern. *J Am Acad Dermatol* 2015;73:836-42.
5. Massi G, LeBoit PE. Melanoma resembling blue nevus. In: *Histological Diagnosis of Nevi and Melanoma*. 2nd ed. Berlin, Heidelberg: Springer; 2014:535-546.
6. Elder D, Scolyer R, Massi D, et al, eds. *World Health Organization Classification of Tumours. Pathology and Genetics of Skin Tumors*. 4th ed. Lyon, France: WHO IARC, 2018
7. Longo C, Piana S, Marghoob A, et al. Morphological features of naevoid melanoma: results of a multicentre study of the International Dermoscopy Society. *Br J Dermatol* 2015;172:961-7.

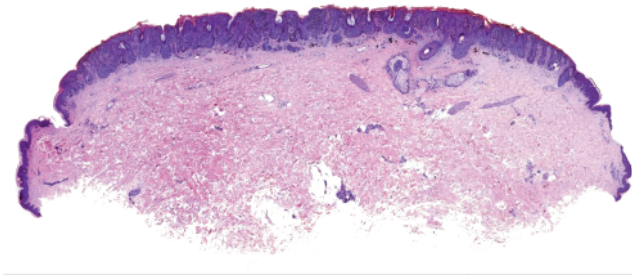


Figure 1. Asymmetric, not sharply circumscribed, mostly junctional melanocytic proliferation (H&E; 20x).

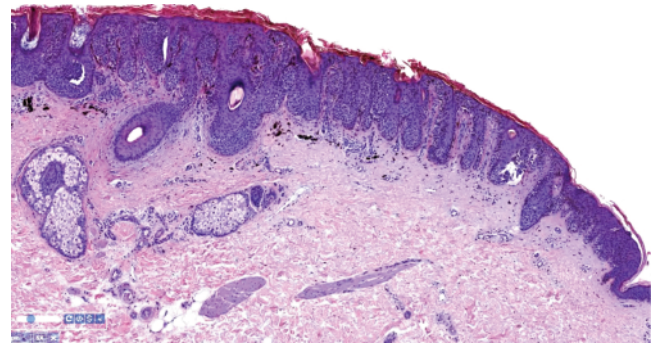


Figure 3. Right half of the lesion: nests are different one from another, with different shape and dimension, asymmetric disposition and with uneven distribution of pigment (H&E; 40x).

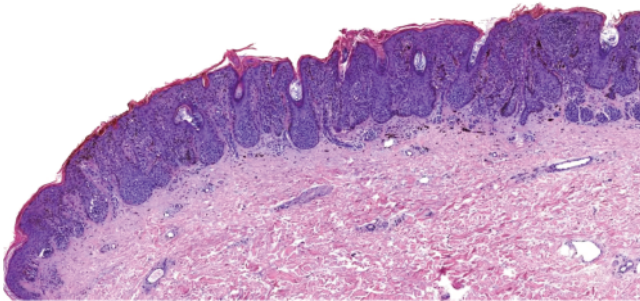


Figure 2. Left half of the lesion: nests are different one from another, with different shape and dimension, asymmetric disposition and with uneven distribution of pigment (H&E; 40x).

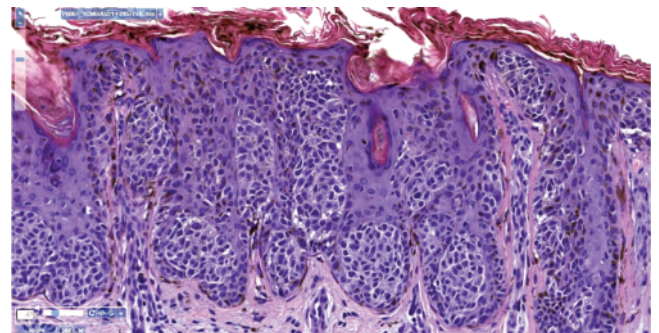


Figure 4. The nests are expansile and push the epidermis from the bottom squeezing the stratum spinosum. The epidermis shows focal pigmented parakeratosis and pigmentation of basal keratinocytes (H&E; 100x).

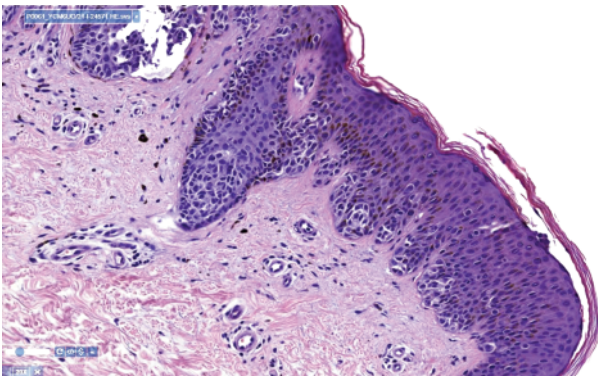


Figure 5. At one edge of the lesion, atypical melanocytes in single unit are present in the stratum spinosum (H&E; 100x).

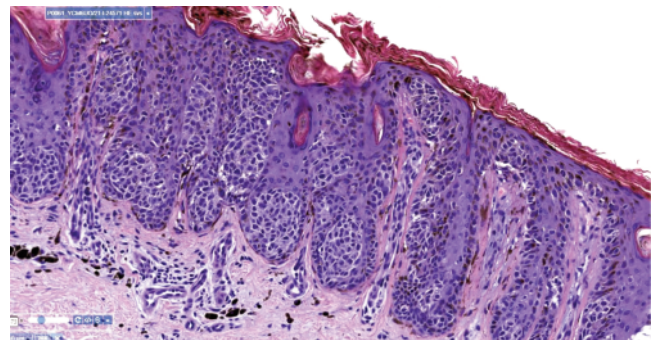


Figure 6. Irregular nests and single melanocytes in the epidermis also above the dermoepidermal junction. In the superficial dermis melanophages, few dendritic melanocytes and lymphocytes are present (H&E; 100x).

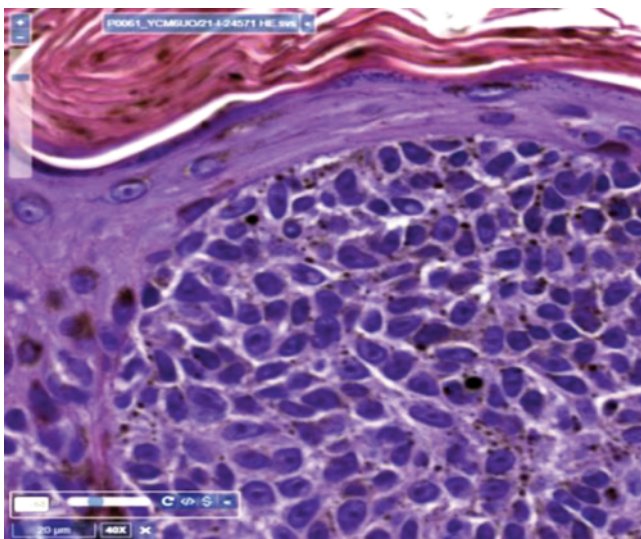


Figure 7. Irregular nests with cohesive melanocytes pushing the epidermis from the bottom (H&E; 200x).

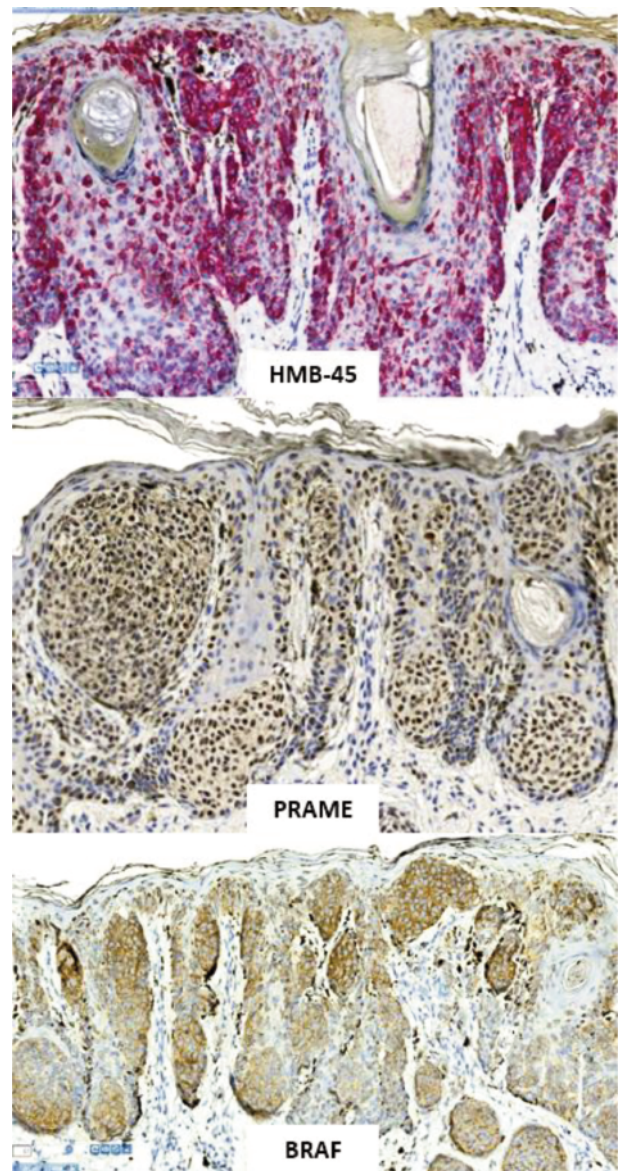
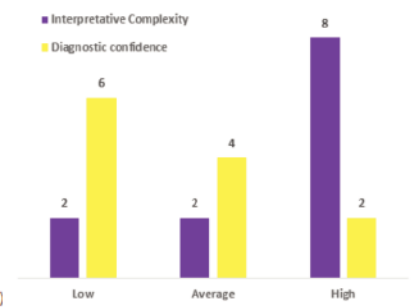
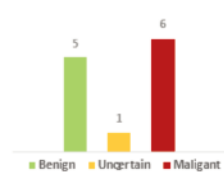


Figure 8. Positivity BRAF-V600E and PRAME; heterogenous positivity for HMB-45 (x100).

5/12 Benign	1/12 Uncertain	6/12 Malignant
Congenital melanocytic nevus (CMN)	Pigmented epithelioid melanocytoma	<b>1 Melanoma in situ</b>
Lentiginous melanocytic nevus	Atypical Spitz Tumor	Acral melanoma in situ
<b>5 Common acquired nevus</b>	Atypical pigmented Spindle cell Tumor	Lentigo maligna
Combined nevus	Proliferative nodule in CMN	Lentigo maligna melanoma
Dermal nevus	<b>1 MELTUMP</b>	<b>2 Superficial spreading melanoma</b>
Dysplastic nevus	SAMPUS	Melanoma arising in congenital nevus
BAP-1-inactivated nevus/melanocytoma	IAMPUS	Melanoma arising in acquired nevus
Nevus spilus		<b>3 Nevoid melanoma</b>
Special site nevus (of the breast, scalp, ear)		Acral Melanoma
Acral nevus		Nodular melanoma
Genital nevus		Desmoplastic Melanoma
Halo nevus		Malignant Spitz tumor (Spitz melanoma)
Meyerson nevus		Melanoma arising in blue nevus
Recurrent nevus		Mucosal lentiginous melanoma
Spitz nevus		Mucosal nodular melanoma
Reed Nevus (pigmented spindle cell nevus)		Melanoma metastasis
Mongolian spot		Tumoral Melanosis
Nevus Ito		Malignant Neoplasm, other
Nevus Ota		
Plexiform Spindle cell Nevus		
Blue nevus		
Cellular Blue nevus		
Deep penetrating nevus		
Benign Neoplasm, other		
Capsular/Nodal nevus		



Case number #/sex/age/site	Read by
I-21-17814 F63 Right flank	12
I-21-17479 M78 Forearm	12
21-I-21944 F5 Left infraorbital	13
I-21-17958 F30 Right foot	12
5833-D-2021 M30 Dorsum	9
21-I-9888 M11 Dorsum of foot	13
<b>21-I-24571 F29 Left calf</b>	<b>12</b>

Table 1. Results of the collegial discussion on the lesion – October 27, 2021.